

## SCIENTIFIC LETTER

# Radiofrequency ablation of atrial fibrillation: effectiveness and safety in 102 consecutive patients

J Pontoppidan, J C Nielsen, S H Poulsen, P T Mortensen, A K Pedersen, H K Jensen, P S Hansen

*Heart* 2005;91:1611–1612. doi: 10.1136/hrt.2004.053660

Segmental pulmonary vein isolation (SPVI) and circumferential pulmonary vein isolation (CPVI) are the two main approaches of radiofrequency ablation in patients with atrial fibrillation (AF).<sup>1,2</sup> The reported efficacy is between 60–90% depending on the approach and AF classification.<sup>3–5</sup>

The goal of this retrospective study was to review our experience with both approaches, as well as patient outcome and safety of this new treatment.

## METHODS

Between February 2001 and July 2003, 102 consecutive patients with paroxysmal or persistent AF were referred for ablation. The initial 28 patients underwent SPVI. From April 2002, 83 patients were treated with CPVI including nine patients with recurrence of AF after SPVI. We changed the approach due to a lower risk of potential pulmonary vein stenosis compared with SPVI and with an apparently comparable efficacy rate.<sup>2</sup> All patients were anticoagulated with warfarin before ablation. Transthoracic and transoesophageal echocardiography were performed to exclude structural heart disease and thrombus formation. SPVI and CPVI were performed according to the methods described by Haissaguerre *et al*<sup>1</sup> and Pappone *et al*.<sup>2</sup>

During the postablation follow up period patients received antiarrhythmic medication and warfarin for at least three months. Patients with recurrence of AF within three months were cardioverted or underwent antiarrhythmic treatment. Patients were scheduled for a visit in the outpatient clinic or at the referring hospital after three months. Holter examinations were performed in case of suspected AF symptoms. Anticoagulation and antiarrhythmic treatment were withdrawn after three months if the patient was free of symptoms. Only recurrence of symptomatic AF more than three months after ablation was regarded as significant recurrence of AF. The study was approved by the local ethics committee in Aarhus, Denmark. Written consent was obtained from the patients.

## RESULTS

### Study population

Baseline demographics did not differ between patients undergoing SPVI and the CPVI group. Overall, 70% of the patients had a history of amiodarone treatment and 67% were previously cardioverted for AF indicating that patients were highly symptomatic.

In the SPVI group, 10 patients had undergone previous ablation (nine for cavotricuspidal isthmus blocks and one for focal atrial tachycardia). Twenty seven patients in the CPVI group had previously undergone an ablation procedure (nine patients had prior SPVI, 17 patients for cavotricuspidal isthmus block, and one for focal atrial tachycardia).

### Procedure and safety

The total procedure and fluoroscopy times were longer in SPVI than in CPVI (table 1). Cardiac tamponade occurred in

one patient during SPVI and in three patients during CPVI. All patients underwent acute pericardiocentesis and were discharged without complications. One patient had transient neurological symptoms after CPVI with subsequent normal cerebral computed tomography. No patient in either group died of a procedure related cause. No clinical signs of pulmonary vein stenosis were observed during follow up.

### Clinical outcome

After SPVI, 25% of patients were free of symptoms without the use of antiarrhythmic treatment after follow up of 757 days (range 531–946 days) (table 1). Seven patients had reduced symptoms while taking antiarrhythmic medication. Of 14 patients with unchanged symptomatic AF, 11 were offered a new ablation procedure. SPVI was performed in two cases and nine patients underwent CPVI because the ablation strategy changed as previously described (these patients are included in the CPVI group).

The overall freedom from symptoms was 73% after a follow up of 366 days (range 90–518 days) after the latest CPVI procedure. Freedom from symptoms was 79% for patients with paroxysmal AF (41 of 52) and 65% for patients with persistent AF (20 of 31). In the nine patients undergoing CPVI as a second ablation procedure due to recurrence of symptoms after an initial SPVI, five patients were free of symptoms and two patients were less symptomatic.

Patients with AF recurrences had more often undergone direct current cardioversions and patients with persistent AF before ablation had a significantly higher risk of recurrence during the follow up period ( $p < 0.001$ ). Left ventricular hypertrophy and known hypertension were associated with higher risk of AF recurrence.

## DISCUSSION

The present study indicates that CPVI can be introduced in the treatment of AF in laboratories with experienced electrophysiologists with promising and reproducible outcome and safety.

The low effectiveness of SPVI in our study may be explained by the effects of a learning curve, patient selection, and difference in follow up including repeat procedures and use of antiarrhythmic medication. Our effectiveness rate for CPVI was similar to results from other centres. Some investigators have reported a success rate of up to 90% AF freedom after CPVI depending on AF classification.<sup>2–5</sup> The percentage of our patients with persistent AF (37%) is comparable with that in most studies except the study of Oral *et al*,<sup>5</sup> who studied only patients with paroxysmal AF. This limitation can explain the high effectiveness of 88% AF freedom in their study. The effectiveness of CPVI in our patients with persistent AF is similar to that reported by Pappone *et al*<sup>2</sup> (65% *v* 68%). In general, patients with persistent AF have higher risk of AF recurrence probably due to more advanced state of disease and more profound atrial

**Abbreviations:** CPVI, circumferential pulmonary vein isolation; AF, atrial fibrillation; SPVI, segmental pulmonary vein isolation

**Table 1** Procedure, safety, and outcome of segmental (SPVI) and circumferential pulmonary vein isolation (CPVI)

	SPVI (n=28)	CPVI (n=83)
<b>Procedure</b>		
Procedure time (min)	193 (55–288)	150 (75–240)
Fluoroscopy time (min)	44 (10–111)	19 (10–41)
<b>Safety</b>		
Tamponade	1 (4%)	3 (4%)
Transient ischaemic attack	0	1 (1%)
Symptoms of PVS	0	0
<b>Outcome</b>		
<b>AF-free</b>		
At follow up	7 (25%)	61 (73%)
Patients with paroxysmal AF	6 (32%)	41 (79%)
Patients with persistent AF	1 (11%)	20 (65%)
Fewer symptoms	7 (25%)	3 (4%)
Repeat pulmonary vein isolation	11 (39%)	11 (13%)
Left atrial flutter ablation	2 (7%)	3 (4%)

Values are median (range) or number (%).  
AF, atrial fibrillation; PVS, pulmonary vein stenosis.

remodelling, which can perpetuate and sustain AF. Pappone *et al*<sup>2</sup> showed that a larger area of encircled atria is associated with a reduced risk of AF recurrence, suggesting that CPVI may modify the atrial substrate. Both SPVI and CPVI are more effective in patients with paroxysmal AF, probably because they benefit from the isolation of the trigger foci in pulmonary vein stenosis and have less atrial remodelling.

The comparison between the two groups should be interpreted cautiously as the groups were different in size and follow up, and the allocation was not randomised. Additionally, each patient was managed differently regarding the postablative medication and no systematic Holter monitoring was done after the ablation.

Catheter based treatment of AF with CPVI can be introduced in laboratories with experienced electrophysiologists with a promising and reproducible outcome and safety. CPVI appears to be more effective than SPVI in treating patients with highly symptomatic and drug resistant AF. However, randomised studies comparing pulmonary vein isolation versus antiarrhythmic treatment are needed and with longer follow up periods.

#### Authors' affiliations

J Pontoppidan, J C Nielsen, S H Poulsen, P T Mortensen, A K Pedersen, H K Jensen, P S Hansen, Department of Cardiology, Skejby Hospital, University of Aarhus, Denmark

The author and co-authors have no competing interests

Correspondence to: Dr Jacob Pontoppidan, Department of Cardiology, Skejby Hospital, University of Aarhus, Brendstrupgaardsvej 100, 8200 Aarhus N, Denmark; pontoppidan@dadlnet.dk

Accepted 7 April 2005

#### REFERENCES

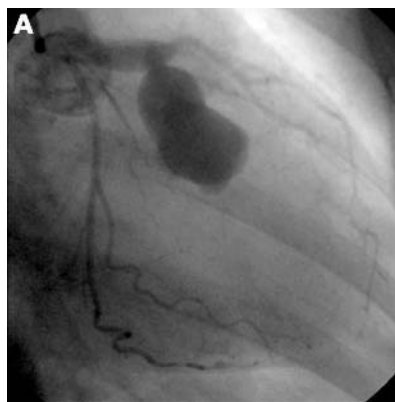
- Haissaguerre M, Jais P, Shah DC, *et al*. Catheter ablation of chronic atrial fibrillation targeting the reinitiating triggers. *J Cardiovasc Electrophysiol* 2000;**11**:2–10.
- Pappone C, Rosanio S, Oreto G, *et al*. Circumferential radiofrequency ablation of pulmonary vein ostia: a new anatomic approach for curing atrial fibrillation. *Circulation* 2000;**102**:2562–4.
- Oral H, Knight BP, Tada H, *et al*. Pulmonary vein isolation for paroxysmal and persistent atrial fibrillation. *Circulation* 2002;**105**:1077–81.
- Mansour M, Ruskin J, Keane D. Efficacy and safety of segmental ostial versus circumferential extra-ostial pulmonary vein isolation for atrial fibrillation. *J Cardiovasc Electrophysiol* 2004;**15**:532–7.
- Oral H, Scharf C, Chugh A, *et al*. Catheter ablation for paroxysmal atrial fibrillation: segmental pulmonary vein ostial ablation versus left atrial ablation. *Circulation* 2003;**108**:2355–60.

## IMAGES IN CARDIOLOGY

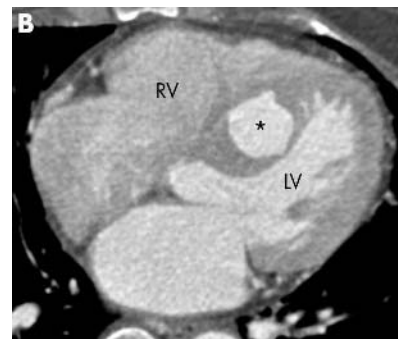doi: 10.1136/hrt.2005.066571

### Giant coronary aneurysm in the septal branch

An asymptomatic 61 year old woman was referred to our institution because of diastolic murmur. She had no illness comparable to Kawasaki disease. An abnormal cavity in the interventricular septum with the jet flowing from the left anterior descending coronary artery into the cavity was detected by Doppler echocardiography. Coronary angiography showed a 25 × 15 mm aneurysm in the septal branch of the left anterior descending artery (panel A). Multislice computed tomography showed that the minimal distance between the left ventricular cavity and the aneurysmal cavity was only 1 mm (panel B). Considering that the pressure on both sides of the aneurysmal wall must be almost the same, we have not performed surgery or catheter intervention and have placed the patient under close observation.



Left coronary angiogram. Right anterior oblique projection with caudal angulation. A giant aneurysm and dilatation of the proximal portion of the left anterior descending coronary artery are seen. The aneurysm communicates only with the septal branch and has no draining vessels. There are some protrusions on the surface of the aneurysm.



The axial image of multislice computed tomography of the patient. Note that the cavity of the aneurysm (asterisk) is separated from the left ventricle (LV) by a very thin wall with only 1 mm thickness. RV, the right ventricle.

M Motooka  
T Konishi  
Y Himura

konishit@tenriyorozu-hp.or.jp