

ORIGINAL ARTICLE

Helicobacter pylori associated gastric diseases and lymphoid tissue hyperplasia in gastric antral mucosa

X Y Chen, W Z Liu, Y Shi, D Z Zhang, S D Xiao, G N J Tytgat

J Clin Pathol 2002;55:133–137

Aim: To investigate the relation between *Helicobacter pylori* associated gastroduodenal diseases and lymphoid tissue hyperplasia in the antral mucosa and to pursue its evolution after eradication of *H pylori*.

Methods: Gastric antral biopsy specimens were obtained from 438 patients with *H pylori* positive gastroduodenal diseases (185 chronic gastritis, 69 gastric ulcer, and 184 duodenal ulcer) and 50 *H pylori* negative healthy controls. Lymphoid follicles and aggregates were counted and other pathological features were scored according to the updated Sydney system for classification of chronic gastritis. After a course of anti-*H pylori* treatment, biopsy specimens were obtained at four to six weeks, 12 months, and 24 months in the chronic gastritis patient group.

Results: The total prevalence of lymphoid follicles and aggregates in the biopsies was 79.9% (350 of 438; 95% confidence intervals (CI), 0.76 to 0.84). The prevalence and density of lymphoid follicles and aggregates were significantly different in the various gastroduodenal diseases. The highest prevalence (89.9%; 95% CI, 0.83 to 0.97) and density (0.82) of lymphoid follicles and aggregates occurred in patients with gastric ulcers. The lowest prevalence of lymphoid follicles and aggregates was found in patients with chronic gastritis (74.6%; 95% CI, 0.68 to 0.81), and the lowest density of lymphoid follicles and aggregates (0.56) was seen in patients with duodenal ulcers. The prevalence and density of lymphoid follicles and aggregates correlated strongly with the activity and severity of gastric antral mucosal inflammation. The eradication of *H pylori* resulted in a decrease in the prevalence and density of lymphoid follicles and aggregates.

Conclusion: The prevalence and density of lymphoid follicles and aggregates in gastric antral mucosal biopsies correlated closely with *H pylori* infection.

See end of article for authors' affiliations

Correspondence to:
Dr X Y Chen, Department of Pathology, Renji Hospital, Shanghai Second Medical University, Shanghai Institute of Digestive Disease, Shanghai 200001, China; xiaoyu64@public7.sta.net.cn

Accepted for publication 31 May 2001

Infection with *Helicobacter pylori* is a major cause of chronic gastritis, and may lead to the formation of gastric mucosa associated lymphoid tissue and the occasional development of primary gastric B cell lymphoma.^{1–3} The normal gastric mucosa contains very few lymphocytes in the lamina propria.^{4,5} Lymphoid follicles and aggregates are characteristic of *H pylori* associated gastritis.⁵ Lymphoid follicle prevalences between 27.4% and 100% have been reported in gastric mucosa from patients with *H pylori* associated gastritis.^{6–11}

"The normal gastric mucosa contains very few lymphocytes in the lamina propria"

To examine the relation between *H pylori* and the development of lymphoid tissue hyperplasia, we investigated the evolution of lymphoid follicles and aggregates and other histopathological features during the two year observation period after the eradication of *H pylori*. We tried to answer the following questions: (1) Is there a difference in the overall prevalence and density of lymphoid follicles and aggregates in various gastroduodenal diseases? (2) Is there a relation between lymphoid follicles and aggregates and the density of *H pylori* colonisation, severity and activity of inflammation, atrophy, and intestinal metaplasia? (3) Do lymphoid follicles and aggregates regress in number or disappear after successful eradication of *H pylori*?

METHODS

Study subjects

A total of 438 patients with *H pylori* infection were recruited from those visiting the endoscopy unit at our hospital between May 1995 and August 1996. The patients, comprising 282 men

and 156 women, age range 18 to 72 years (mean age, 41.1; SD, 10.1), were divided into three groups: (1) group 1 consisted of 185 dyspeptic patients with chronic gastritis (105 superficial chronic gastritis and 80 atrophic gastritis confirmed by endoscopy and histopathology); (2) group 2 consisted of 69 patients with endoscopically confirmed gastric ulcers; (3) group 3 consisted of 184 patients with endoscopically confirmed duodenal ulcers. Fifty *H pylori* negative dyspeptic patients with endoscopically and histologically confirmed normal gastric antral mucosa were selected as the control group.

Endoscopy and biopsy sampling

All patients underwent upper gastrointestinal endoscopy before *H pylori* eradication treatment in our hospital. Those patients with chronic gastritis underwent repeat endoscopy after treatment. According to the mapping principle of our study, during each endoscopic examination, six antral mucosal biopsies were taken from the anterior and posterior wall, and the lesser and the greater curvature within 2–3 cm from the pylorus. Additional biopsy specimens were taken from lesional areas when necessary. Two antral biopsy specimens were used for microbiological assessment (rapid urease test and culture), the others were used for histological assessment.

Histopathology

All antral biopsy specimens for histological examination were fixed in 10% formalin, embedded in paraffin wax on the

Abbreviations: CI, confidence interval; IL, interleukin; IM, intestinal metaplasia

oriented edge, and cut into 5 µm thick sequential sections. All tissue sections were stained with haematoxylin and eosin for histological examination and with a Giemsa stain for *H pylori* assessment.

The severity and activity of gastritis, atrophy, and intestinal metaplasia, in addition to *H pylori* density, were evaluated according to the updated Sydney system.⁵ The infiltration of gastric mucosa by mononuclear cells and polymorphonuclear leucocytes, atrophy, and intestinal metaplasia were graded as follows: 0, none; 1, mild; 2, moderate; 3, severe. Atrophy was defined as the loss of inherent glandular tissue, with or without replacement by intestinal-type epithelium. For optimal histological evaluation, all gastric biopsy specimens included surface epithelium and muscularis mucosae, and small pinch biopsies were excluded from our study. A total of 1660 gastric biopsy specimens were investigated and analysed. A lymphoid follicle was defined as an aggregate of lymphocytes with a germinal centre. Lymphoid aggregates were defined as accumulations of lymphocytes and plasma cells without a germinal centre. To assess the degree of lymphoid tissue hyperplasia, lymphoid follicles and aggregates in each antral biopsy specimen were counted and tabulated. The density of lymphoid follicles and aggregates (the number of biopsy specimens with lymphoid tissue hyperplasia/the number of biopsy specimens examined) represents the intensity of lymphoid tissue hyperplasia in the antral gastric mucosa.

All gastric specimens, including those from the normal control group, were investigated and scored independently by two pathologists (XYC and YS). The pathologists were blinded to any clinical information. Before starting the study, the two pathologists reached consensus about the methods of grading the features of gastritis through interactive sessions at a multi-headed microscope. Disagreements were resolved by consensus.

Helicobacter pylori assessment

The presence of *H pylori* was determined by the rapid urease test, culture, and histopathology. Patients were positive for *H pylori* when *H pylori* was detected by at least two of the above three methods. The eradication of *H pylori* infection was defined as the absence of microorganisms in both culture and tissue sections four to six weeks after cessation of treatment.

Treatment and follow up study

Eligible patients with *H pylori* positive chronic gastritis were given a seven day course of bismuth triple treatment. The patients again underwent endoscopy and biopsy at four to six weeks after completion of the treatment. Complete sets of gastric antral biopsy specimens were obtained from 35 and seven patients, respectively, who were *H pylori* negative 12 and 24 months after eradication of *H pylori*. Histopathological changes and lymphoid tissue hyperplasia were reinvestigated in those biopsy specimens.

Statistical analysis

Statistical analysis was performed using the statistical package for social science (SPSS) program. Two tailed χ^2 and Fisher exact probability and 95% confidence intervals (CI) were used when appropriate. Significance was set at $p < 0.05$.

RESULTS

The prevalence and density of lymphoid follicles and aggregates in gastroduodenal diseases

Figure 1 shows the prevalence of lymphoid follicles and aggregates in various gastroduodenal diseases. Overall, lymphoid follicles and aggregates were present in the antral mucosa of 350 (79.9%; 95% CI, 0.76 to 0.84) patients. The prevalences of lymphoid follicles and aggregates in various gastroduodenal diseases were significantly different. The highest number of lymphoid follicles and aggregates (89.9%;

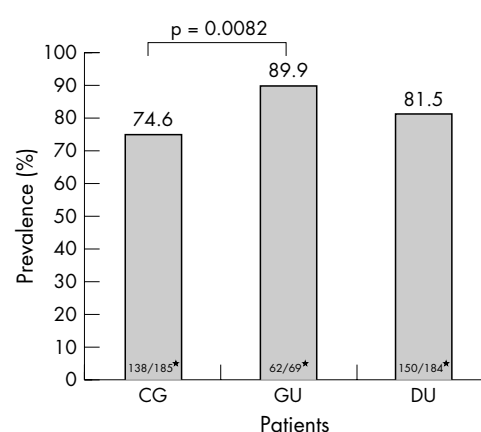


Figure 1 The prevalence of lymphoid follicles and aggregates in the antral mucosa in the different groups of patients. CG, chronic gastritis; DU, duodenal ulcer; GU, gastric ulcer. *Values are the number of patients with lymphoid follicles and aggregates/total number of patients in that group.

95% CI, 0.83 to 0.97) occurred in those patients with gastric ulcers. The lowest prevalence of lymphoid follicles and aggregates (74.6%; 138 of 185; 95% CI, 0.68 to 0.81) was found in the patients with chronic gastritis. The prevalence of lymphoid follicles and aggregates was significantly different in patients with chronic gastritis and those with gastric ulcer ($p = 0.0082$). The presence of lymphoid follicles and aggregates in the gastric antral mucosa was higher in patients with gastric ulcer than in those with duodenal ulcers, although the difference was not significant ($p = 0.109$).

A total of 1476 eligible gastric antral biopsy specimens from different groups (669 chronic gastritis, 239 gastric ulcer, and 568 duodenal ulcer) were analysed, and the number of lymphoid follicles and aggregates in each sample of gastric antral mucosa was graded from 0 to 6 (average, 0.7). The overall density of the lymphoid follicles and aggregates was 0.71 (1031 of 1476) in infected antral mucosa. The density of lymphoid follicles and aggregates in gastric antral mucosa was also significantly different in the various gastroduodenal diseases, and correlated with the prevalence of lymphoid follicles and aggregates. The highest (0.82; 196 of 239) and lowest (0.56; 318 of 568) density of lymphoid follicles and aggregates occurred in the patients with gastric ulcers and duodenal ulcers, respectively (fig 2). There were significant differences in the density of lymphoid follicles and aggregates between patients with chronic gastritis and duodenal ulcers ($p = 1.6 \times 10^{-15}$), and between those with gastric ulcers and duodenal ulcers ($p = 2.24 \times 10^{-12}$). Although the density of lymphoid follicles and aggregates was higher in the patients with gastric ulcers than in those with chronic gastritis, the difference was not significant ($p = 0.105$).

There were very few scattered lymphocytes and no lymphoid tissue hyperplasia in the antral lamina propria in the normal control group.

Relation between lymphoid follicles and aggregates and pathological features in the chronic gastritis group

Figures 3–5 show the relation between lymphoid follicles and aggregates and pathological features in the chronic gastritis group. The prevalence of lymphoid follicles and aggregates was higher in the patients with atrophic gastritis (71 of 80; 88.7%; 95% CI, 0.82 to 0.96) than in those with superficial gastritis (67 of 105; 63.8%; 95% CI, 0.55 to 0.73). The prevalence and density of lymphoid follicles and aggregates were closely correlated with the severity and activity of inflammation. With an increasing degree of chronic inflammation in the gastric antral mucosa, higher numbers and a greater density of lymphoid follicles and aggregates were

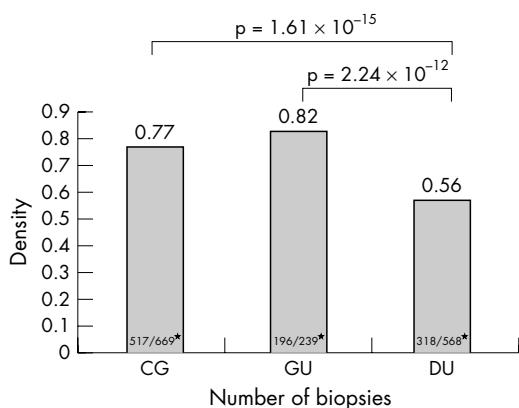


Figure 2 The density of lymphoid follicles and aggregates in the antral mucosa in the different groups of patients. CG, chronic gastritis; DU, duodenal ulcer; GU, gastric ulcer. *The number of biopsy specimens with lymphoid tissue hyperplasia/the total number of biopsy specimens in that group.

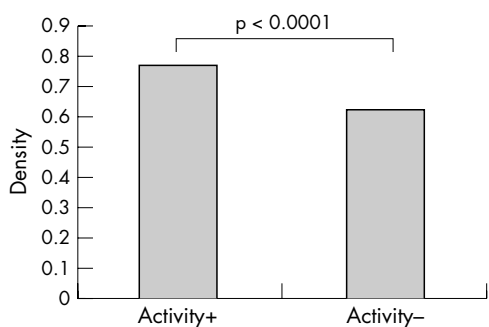


Figure 3 The relation between the density of lymphoid follicles and aggregates and disease activity in the chronic gastritis group.

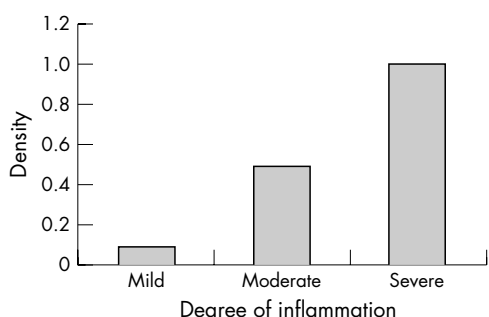


Figure 4 The relation between the density of lymphoid follicles and aggregates and the severity of inflammation in the chronic gastritis group.

detected (fig 4). Numbers of lymphoid follicles and aggregates were significantly higher in the patients with active gastritis than in those without active gastritis ($p < 0.0001$; fig 3). Correlations between the detection of lymphoid follicles and aggregates and atrophy or intestinal metaplasia were evaluated in fig 5; a higher prevalence was detected in atrophic and intestinal metaplasia mucosa ($p < 0.001$). However, a lower prevalence and density of lymphoid follicles and aggregates was found with increasing degree of atrophy and intestinal metaplasia.

Prevalence and density of lymphoid follicles and aggregates after *H pylori* eradication in chronic gastritis

Figures 6 and 7 show the changes in the prevalence and density of lymphoid follicles and aggregates in the gastric antral mucosa before treatment and four to six weeks, 12 months, and 24 months after *H pylori* eradication treatment. Eradica-

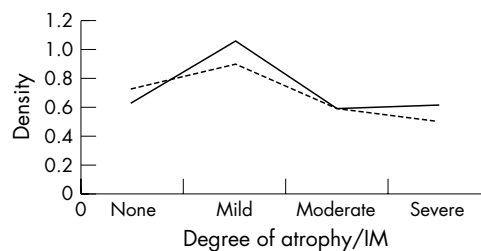


Figure 5 The relation between the density of lymphoid follicles and aggregates and atrophy or intestinal metaplasia (IM) in the chronic gastritis group. Solid line, atrophy; dotted line, IM.

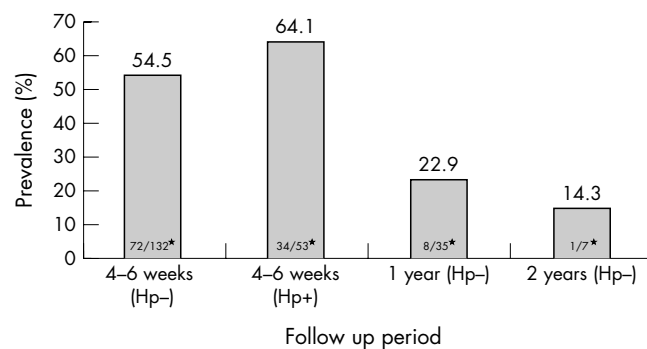


Figure 6 Changes in the prevalence of lymphoid follicles and aggregates in the antral mucosa in the chronic gastritis group during the two years of follow up. Hp+, *Helicobacter pylori* positive; Hp-, *H pylori* negative. *Values are the number of patients with lymphoid tissue hyperplasia/total number of patients in that group.

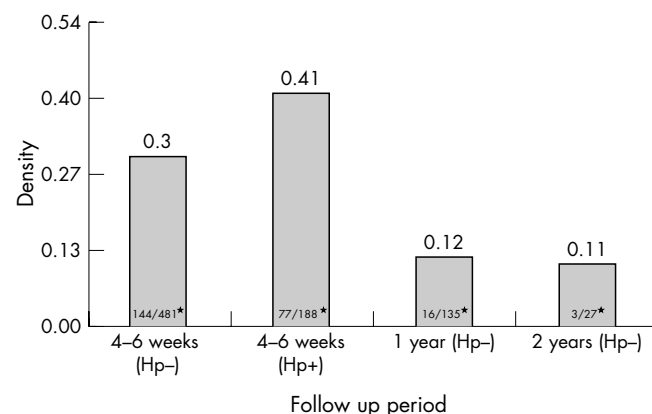


Figure 7 The changes in the prevalence of lymphoid follicles and aggregates in the antral mucosa in the chronic gastritis group during the two years of follow up. Hp+, *Helicobacter pylori* positive; Hp-, *H pylori* negative. *Values are the number of biopsy specimens with lymphoid tissue hyperplasia/total number of biopsy specimens examined in that group.

tion of *H pylori* infection resulted in a decrease of lymphoid tissue hyperplasia in the gastric antral mucosa. Eradication of *H pylori* was seen in 132 of the 185 (71.4%; 95% CI, 0.65 to 0.78) patients after triple antibiotic treatment. The prevalence of lymphoid follicles and aggregates before treatment was 74.6% (138 of 185; 95% CI, 0.68 to 0.81) and decreased to 57.3% (106 of 185; 95% CI, 0.50 to 0.64) four to six weeks after treatment ($p = 0.000447$). The number of lymphoid follicles and aggregates in the antral mucosa significantly declined in those patients without *H pylori* infection (54.5%; 95% CI, 0.41 to 0.68; $p = 0.000198$), whereas in those where *H pylori* infection remained there was only a slight decrease (95% CI, 0.56 to 0.72; $p = 0.134$) after treatment. The density of *H pylori* colonisation decreased significantly in 53 patients in whom *H pylori* infection remained four to six weeks after treatment.

Helicobacter pylori colonisation was seen in only 62 of 188 biopsy specimens in those patients.

The prevalence and density of lymphoid follicles and aggregates decreased to 22.9% (95% CI, 0.09 to 0.37) and 0.12, respectively, in 35 patients who were *H pylori* negative one year after treatment. Furthermore, a small but steady decline in the frequency (14.3%; 95% CI, -0.12 to 0.40) and density (0.11) of lymphoid follicles and aggregates was observed in the antral mucosa in seven patients who were *H pylori* negative two years after treatment.

DISCUSSION

Wyatt and Rathbone¹¹ investigated 419 pairs of antral and corporal mucosal biopsy specimens and found lymphoid follicles in 27.4% of patients with *H pylori* associated gastritis. Eidt and Stolte⁸ studied "two to three antral specimens" from 2692 patients with *H pylori* infection and detected lymphoid follicles and aggregates in 54% of those patients. Genta and Hammer⁹ found that the prevalence of lymphoid follicles was 63.8% (110 of 174) in patients with chronic gastritis and 100% in patients with *H pylori* infection. In our study, lymphoid follicles and aggregates were found in the gastric antral mucosa of 76.0% (350 of 438) of patients with various *H pylori* associated gastric diseases. These differences in prevalences between other previously published data and our study might result from several factors: (1) Biopsy sites may have been different in the various studies. It has been known for some time that the frequency of lymphoid follicles and aggregates is lower in oxyntic mucosa (14.8–44.0% lower) than that seen in antral mucosa.^{8–10} (2) The number of biopsy specimens taken varied in the different studies. In many studies where a lower prevalence of lymphoid follicles and aggregates was reported a small number (two to three) of antral biopsy specimens may have been taken. The higher rate of detection of lymphoid follicles and aggregates in the antrum in our study might be explained by the larger number (four) of antral specimens.

The highest prevalence (89.9%) and density (0.82) of lymphoid follicles and aggregates was found in those patients with gastric ulcers in a "background" of chronic gastritis. By increasing the number of biopsy specimens taken, a higher prevalence and density of lymphoid follicles and aggregates may be detected in gastric antral mucosa. Lymphoid follicles and aggregates in gastric antral mucosa might be found in 100% of *H pylori* positive patients if sufficient gastric biopsy specimens are examined, in accordance with the finding of Genta and Hammer.⁹ It is widely believed that the presence of lymphoid follicles and aggregates in gastric mucosa is a conspicuous pathological feature of *H pylori* associated chronic gastritis.

"Lymphoid tissue hyperplasia is a specific immunological reaction to *H pylori* infection"

This is remarkable considering the lack of lymphoid tissue in the normal gastric mucosa, and *H pylori* infection seems to be the major determinant in the development of gastric lymphoid tissue.^{4–5,12} The eradication of *H pylori* infection results in a decrease in lymphoid follicles and aggregates. In our study, only very few scattered lymphocytes were detected and no lymphoid tissue hyperplasia was found in the antral lamina propria in 190 biopsy specimens in the normal control group. Lymphoid follicles and aggregates in the gastric mucosa decreased rapidly after the eradication of *H pylori* infection, which corresponded well with previous data.⁶ No lymphoid tissue hyperplasia was detected in the gastric antral mucosa in 77.1% and 85.7% of patients who were *H pylori* negative one and two years after treatment in our present study. Our data confirmed that the presence and degree of colonisation with *H pylori* strongly correlates with the development and disappearance of lymphoid tissue in the stomach. After colonisation

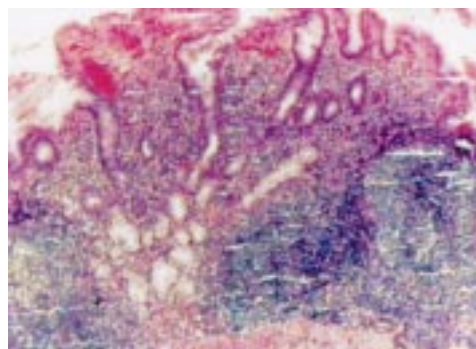


Figure 8 Severe chronic inflammation with a high prevalence of lymphoid follicles accompanying moderate to severe glandular atrophy in the gastric mucosa.

of the gastric mucosa by *H pylori*, close and persistent contact between the bacterium and the mucosa leads to a specific immune response. Lymphoid tissue hyperplasia is a specific immunological reaction to *H pylori* infection. Previous studies have shown that the proliferation of T cells and macrophages is induced by cytotoxin and *H pylori*, resulting in the release of several cytokines (interleukin 2 (IL-2) and IL-6), which leads to the proliferation of B cells and the development of lymphoid follicles and aggregates in the infected gastric mucosa. The infiltration of T cells decreased significantly when *H pylori* were eradicated or reduced in number after treatment, resulting in a reduced stimulation of B cell proliferation and the disappearance of lymphoid tissue hyperplasia in the gastric mucosa.^{13–14}

Our study confirmed the finding of Stolte and Eidt^{7,8} that there was a significant correlation between lymphoid follicles and aggregates and the severity and activity of inflammation in the gastric mucosa. Lymphoid follicle and aggregate development was maximal in the infected antral mucosa in patients with severe active chronic gastritis (fig 8). There was a progressive decline in the infiltration of chronic inflammatory cells in the antral mucosa with increasing degree of atrophy and intestinal metaplasia. With the regression of inflammation in the advanced stage of chronic gastritis, fewer numbers of lymphoid follicles and aggregates were detected. The main reasons for this loss of lymphoid follicles and aggregates are: (1) Because *H pylori* only colonised the gastric epithelium, the organisms were absent from the areas of intestinal metaplasia that are usually present in atrophic stomach. (2) The hypochlorhydric environment is an unfavourable one for the growth of *H pylori*. (3) Acidic glycoproteins secreted by metaplastic epithelium may provide a more hostile environment for *H pylori* than the natural glycoproteins of the normal mucosal layer. (4) The replacement of gastric epithelium and glandular tissue by intestinal-type epithelium leads to lower numbers of specific receptors for *H pylori*.¹⁵ (5) Intestinal epithelium is more resistant to *H pylori* infection than gastric epithelium because of the relatively higher concentration of specific IgA.¹⁶ All the above reasons might prohibit *H pylori* from attaching to intestinal-type cells.

In conclusion, there was a close correlation between lymphoid tissue hyperplasia and morphological changes, such as the severity and activity of chronic gastritis, atrophy, intestinal metaplasia, and colonisation by *H pylori*. Lymphoid tissue hyperplasia caused by *H pylori* infection decreased quickly after eradication of the infection, declining at a slow and steady rate, but did not disappear during the two years of follow up.

ACKNOWLEDGEMENT

This work was supported in part by a grant from the Dutch government and the Royal Dutch Academy of Sciences (Dutchigas Hp Project).

Take home messages

- The prevalence and density of lymphoid follicles and aggregates in gastric antral mucosal biopsies correlated closely with *Helicobacter pylori* infection
- Lymphoid tissue hyperplasia caused by *H pylori* infection decreased quickly after eradication of the infection

Authors' affiliations

X Y Chen, Y Shi, Department of Pathology, Renji Hospital, Shanghai Second Medical University, Shanghai Institute of Digestive Disease, Shanghai 200001, China

W Z Liu, D Z Zhang, S D Xiao, Department of Gastroenterology, Shanghai Second Medical University

G N J Tytgat, Department of Gastroenterology, Academic Medical Center, University of Amsterdam, Meibergdreef 9, 1105 A2, Amsterdam, The Netherlands

REFERENCES

- 1 **Wotherspoon A**, Doglioni C, Diss T, *et al*. Regression of primary low-grade B-cell gastric lymphoma of mucosa-associated lymphoid tissue type after eradication of *Helicobacter pylori*. *Lancet* 1993;**342**:575–9.
- 2 **Isaacson PG**. Recent developments in our understanding of gastric lymphomas. *Am J Surg Pathol* 1996;**20**(suppl 1):s1–7.
- 3 **Mazzuchelli L**, Blaser A, Kappeler A, *et al*. BCA-1 is highly expressed in *Helicobacter pylori*-induced mucosa-associated lymphoid tissue and gastric lymphoma. *J Clin Invest* 1999;**104**:R49–54.
- 4 **Owen DA**. Normal histology of the stomach. *Am J Surg Pathol* 1986;**10**:48–61.
- 5 **Dixon MF**, Genta RM, Yardley JH, *et al*. Classification and grading of gastritis, the update Sydney system. *Am J Surg Pathol* 1996;**20**:1161–81.
- 6 **Genta RM**, Hammer HW, Graham DY. Gastric lymphoid follicles in *Helicobacter pylori* infection: frequency, distribution, and response to triple therapy. *Hum Pathol* 1993;**24**:577–83.
- 7 **Stolte M**, Eidt S. Lymphoid follicles in antral mucosa: immune response to *Campylobacter pylori*? *J Clin Pathol* 1989;**42**:269–71.
- 8 **Eidt S**, Stolte M. Prevalence of lymphoid follicles and aggregates in *Helicobacter pylori* gastritis in antral and body mucosa. *J Clin Pathol* 1993;**46**:832–5.
- 9 **Genta RM**, Hammer HW. The significance of lymphoid follicles in the interpretation of gastric biopsy specimens. *Arch Pathol Lab Med* 1994;**118**:740–3.
- 10 **Zaitoun AM**. The prevalence of lymphoid follicles in *Helicobacter pylori* associated gastritis in patients with ulcers and non-ulcer dyspepsia. *J Clin Pathol* 1995;**48**:325–9.
- 11 **Wyatt JI**, Rathbone BJ. Immune response of the gastric mucosa to *Campylobacter pylori*. *Scand J Gastroenterol* 1988;**142**(suppl):44–9.
- 12 **Veenendaal RA**, Gotz JM, Lamers BHW. Mucosa inflammation and disease in *Helicobacter pylori* infection. *Scand J Gastroenterol* 1996;**218**(suppl):86–91.
- 13 **Xiang Z**, Bugndi M, Rappuoli R, *et al*. *Helicobacter pylori* host responses in peptic ulceration. *Lancet* 1993;**342**:900–1.
- 14 **Ren Z**, Pang G, Lee R, *et al*. Circulating T-cell response to *Helicobacter pylori* infection in chronic gastritis. *Helicobacter* 2000;**5**:135–41.
- 15 **Lingwood CA**, Wasty G, Han H, *et al*. Receptor affinity purification of a lipid-binding adhesion from *Helicobacter pylori*. *Infect Immun* 1993;**61**:2474.
- 16 **Tsutsumi Y**, Nagura H, Wataube K. Immune aspects of intestinal metaplasia of the stomach: an immunohistochemical study. *Virchows Arch A Pathol Anat Histopathol* 1984;**403**:345.

Browsing made easy

Collections

With a single click Collections allows you to find all articles that have been published in your chosen subject. Select from over 200 clinical and non-clinical topic collections and/or cross search other specialist journals, the BMJ and Cochrane Reviews

www.jclinpath.com