

## CASE REPORT

# Colonic carcinoma with granulomatous (sarcoid) reaction

J D Coyne

*J Clin Pathol* 2002;**55**:708–709

A 74 year old man had a right hemicolectomy for a caecal adenocarcinoma. Microscopic examination also revealed non-caseating epithelioid granulomas within the adjacent stroma and some of these granulomas contained centrally located malignant cells. Granulomatous inflammation was not present within the lymph nodes and the importance of this rare occurrence is discussed.

Granulomatous reactions occurring within lymph nodes draining carcinomas are a well known but uncommon occurrence.<sup>1</sup> More rarely, granulomas may occur within the stroma of malignancies, a variety of which have been reported including breast, renal, and hepatocellular carcinomas.<sup>2–4</sup> However, the occurrence of granulomas within the stroma of colonic carcinomas appears to be much more rare, with only a single case reported in the Japanese literature.<sup>5</sup> This case is, to the best of my knowledge, the first case reported in the English literature.

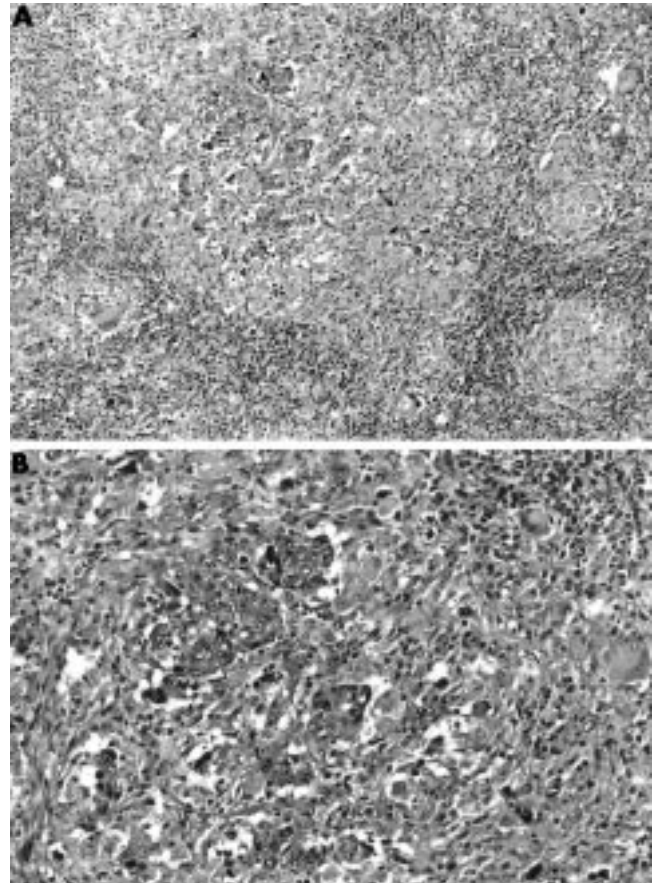
### CASE HISTORY AND PATHOLOGY

A 74 year old man was assessed for rectal bleeding, constipation, and weight loss. Six years previously he had a 5 cm moderately dysplastic tubulovillous adenoma removed from the rectum. Colonoscopy revealed three sessile polyps each measuring 2 mm maximum dimension, which were excised from the rectum, proximal sigmoid, and hepatic flexure. In the caecum there was a 45 mm ulcerating tumour encircling the ileocaecal valve with an adjacent 3 mm pedunculated polyp. A 12 mm sessile polyp was also present. A right hemicolectomy was subsequently performed and the patient made an uneventful recovery. Six months later the patient is alive, well, and regaining weight. An abdominal ultrasound showed a normal liver with no focal abnormality. There was no clinical indication of inflammatory bowel disease.

The specimen consisted of caecum and right colon measuring 18 cm in length with a 4 cm piece of terminal ileum. At the ileocaecal valve there was an ulcerated tumour measuring 3.3 × 2.0 cm, which extended through the wall into the adjacent fat.

“The granulomatous reaction may be a response to necrotic material (that is, a foreign body inflammatory response) or an immunological reaction”

Microscopic examination showed an infiltrating poorly differentiated colonic carcinoma extending into the serosal fat. Focally, there was a granulomatous reaction within the stroma of and adjacent to the carcinoma, and some of the granulomas contained centrally located malignant cells (fig 1). One of 10 lymph nodes contained metastatic mucinous carcinomas, although mucinous elements were not identified in the primary carcinoma. Elsewhere there were several tubulovillous adenomas showing moderate dysplasia. Ziehl-Neelsen stains were negative.



**Figure 1** (A) Stromal granulomatous response adjacent to the carcinoma. (B) Granuloma containing centrally located malignant cells.

### DISCUSSION

The occurrence of non-caseating granulomas occurring in lymph nodes draining malignant neoplasms is a well documented phenomenon, with cervical and breast carcinomas thought to be the most likely to elicit this response.<sup>1,2</sup> Less commonly, non-caseating epithelioid granulomas and metastatic malignancy occur simultaneously within lymph nodes, but this distinctly unusual phenomenon has been described only with metastatic nasopharyngeal carcinoma, seminoma, and malignant melanoma.<sup>6,7</sup> An equally rare phenomenon is that of a granulomatous response occurring within the stroma of a variety of carcinomas, including breast, renal, and hepatocellular carcinomas.<sup>2–4</sup> A single previous case of sigmoid colon cancer with a sarcoid stromal reaction was described in the Japanese literature.<sup>5</sup> However, despite the rarity of these last cases, granulomatous inflammation has been described in association with microinvasive breast carcinomas (predominantly in situ carcinomas with invasive foci measuring < 1 mm) and in relation to microscopic foci of colonic carcinoma within perivascular mesenteric fat.<sup>8,9</sup> The granulomatous reaction may be a response to necrotic material (that

**Take home messages**

- The occurrence of granulomas within the stroma of colonic carcinomas is extremely rare and this is the first case reported in the English literature
- The granulomatous response within draining lymph nodes may be a response to soluble tumour related antigens and the stromal reaction may be a T cell mediated immunological response to cell surface antigens

is, a foreign body inflammatory response) or an immunological reaction, with the granulomatous response within draining lymph nodes representing a response to soluble tumour related antigens and the stromal reaction representing a T cell mediated immunological response to cell surface antigens. Our patient, in whom Crohn's disease and tuberculosis were clinically and immunohistochemically excluded, further supports the contention that this is a very early immunological response to surface antigens.

**ACKNOWLEDGEMENTS**

Thanks to Mrs S Thompson for excellent secretarial assistance and Dr A Curry for the photomicrographs.

**Authors' affiliations**

**J D Coyne**, Withington Hospital, Nell Lane, West Didsbury, Manchester M20 2LR, UK

Correspondence to: Dr J D Coyne, Withington Hospital, Nell Lane, West Didsbury, Manchester M20 2LR, UK; john.coyne@smuht.nwest.nhs.uk

Accepted for publication 22 November 2001

**REFERENCES**

- 1 **Gregori HB**, Othersen HB, Moore MP. The significance of sarcoid-like lesions in association with malignant neoplasms. *Am J Surg* 1962;**104**:577-86.
- 2 **Oberman H**. Invasive carcinoma of the breast with granulomatous response. *Am J Clin Pathol* 1987;**88**:719-21.
- 3 **Watterson J**. Epithelioid granulomas associated with hepatocellular carcinoma. *Arch Pathol Lab Med* 1982;**106**:538-9.
- 4 **Campbell F**, Douglas-Jones A. Sarcoid-like granulomas in primary renal cell carcinoma. *Sarcoidosis* 1993;**10**:128-31.
- 5 **Hirano T**, Furukawa H, Kawakami Y, *et al*. A case of sigmoid colon cancer with sarcoid reaction [in Japanese]. *Surgical Therapy* 1994;**71**:477-9.
- 6 **Blackshaw A**. Metastatic tumour in lymph nodes. In: Stansfield AG, ed. *Lymph node biopsy interpretation*. London: Churchill-Livingstone, 1987:380-97.
- 7 **Coyne JD**, Banerjee SS, Menasce LP, *et al*. Granulomatous lymphadenitis associated with metastatic malignant melanoma. *Histopathology* 1996;**28**:470-2.
- 8 **Coyne JD**, Haboubi NY. Micro-invasive breast carcinoma with granulomatous stromal response. *Histopathology* 1992;**20**:184-5.
- 9 **Coyne JD**, Haboubi NY. Invasive carcinoma with a granulomatous stromal response. *Histopathology* 1994;**25**:397-400.

**ECHO****Nasal swabs are the painless way to diagnose viral respiratory infection**

Please visit the Journal of Clinical Pathology website [www.jclinpath.com] for link to this full article.

Children should find the sampling procedure for acute respiratory infection much less painful, after a small study has shown for the first time that nasal swabs are suitable and provoke much less discomfort than nasopharyngeal swabs.

Detection of influenza virus was very similar for nasal swabs and nasopharyngeal swabs by direct immunofluorescence (27% v 29% positive, respectively) and enzyme assay (26% v 28% positive). Detection of respiratory syncytial virus was identical, at 20% for both samples. The difference in sensitivity and specificity of nasal and nasopharyngeal swabs and in their positive and negative predictive values was negligible or non-existent.

Pain scores according to crying time (25 children), or assessment by Oucher score (12) or facial coding (14) were all significantly lower with nasal swabs.

Paired samples were obtained with a lower nasal swab and a high nasopharyngeal swab from opposite nostrils of 199 children (median age 1.5 years, range 11 days-13.8 years) with suspected acute respiratory infection. Each was examined by direct immunofluorescence and enzyme assay for influenza and by direct immunofluorescence for respiratory syncytial virus. Pain was measured by duration of crying for children aged under 3 years or by standard Oucher pain scale and a validated facial coding system in older children.

Acute respiratory infection is the commonest cause of childhood illness. One recent study found these two sampling methods equally effective for detecting influenza virus, though the pain they cause has not been studied before.

▲ *Archives of Disease in Childhood* 2002;**86**:372-373.