

## CASE REPORT

# Isolated EBV lymphoproliferative disease in a child with Wiskott-Aldrich syndrome manifesting as cutaneous lymphomatoid granulomatosis and responsive to anti-CD20 immunotherapy

N J Sebire, S Haselden, M Malone, E G Davies, A D Ramsay

*J Clin Pathol* 2003;56:555–557

Patients with primary immunodeficiencies such as the Wiskott-Aldrich syndrome (WAS) are prone to develop Epstein-Barr virus (EBV) related lymphoproliferative disorders (LPDs). EBV LPD is most frequently seen in patients receiving immunosuppressive treatment after organ transplantation (post-transplant lymphoproliferative disorder), but can also arise in the primary immunodeficiencies. Typically, EBV LPD presents as a diffuse systemic disease with lymphadenopathy and organ involvement. A rare angiocentric and angiodescriptive form of EBV associated B cell LPD, lymphomatoid granulomatosis (LyG), has also been reported in association with WAS. LyG most commonly involves the lung, but can also be seen in brain, kidney, liver, and skin. This report describes the case of a 16 year old boy with WAS who presented with an isolated non-healing ulcerating skin lesion. Biopsy revealed an EBV related LPD with the histological features of LyG. This cutaneous lesion responded dramatically to treatment with specific anti-CD20 immunotherapy and the patient remains clinically free of LPD at 18 months.

Although Epstein-Barr virus (EBV) related lymphoproliferative disorders (LPDs) are most frequently seen in patients receiving immunosuppressive treatment after organ transplantation (post-transplant lymphoproliferative disorder; PTLD), they also occur in patients with immunodeficiencies.<sup>1</sup> EBV related LPD usually manifests as systemic disease with vague symptomatology, and often shows pulmonary involvement.<sup>2</sup> We present a case of a 16 year old boy with known Wiskott-Aldrich syndrome (WAS) who developed an unusual, non-healing, ulcerating, cutaneous lesion with the clinical and pathological features of lymphomatoid granulomatosis (LyG). Histology confirmed an angiocentric destructive lesion with a mixed infiltrate of T and B cells. The B cells showed nuclear pleomorphism and were EBV positive. There was no evidence of disease elsewhere and this cutaneous lesion responded well to treatment with anti-CD20 immunotherapy.

### CASE REPORT

A 15 year old boy with known WAS presented with an isolated, non-healing, annular 1.5 cm lesion on the left thigh. An initial punch biopsy revealed mild chronic inflammation only, with no specific features, and no organisms could be identified. He remained systemically well but the lesion increased in size to 4 cm and a further incisional biopsy was performed. This showed a focal ulcerating lesion with granulation tissue and fibrosis, and a dense angiocentric lymphocytic infiltrate

within the dermis (fig 1). Special stains for fungi, bacteria, and mycobacteria were negative. Immunostaining for CD79a, CD20, CD5, and CD3 demonstrated a mixed T and B cell population, and enabled the identification of a subpopulation of enlarged B cells with moderate nuclear pleomorphism. In situ hybridisation (ISH) for EBV showed highly localised and intense staining for Epstein-Barr encoded viral RNAs (EBERs) in the intralesional lymphocytes, but no positive cells within the surrounding apparently normal skin (fig 1). Polymerase chain reaction analysis demonstrated a clonal immunoglobulin heavy chain rearrangement in the lymphoid infiltrate using FR3 primers. Further investigations revealed no evidence of systemic LPD and the patient was treated with anti-CD20 immunotherapy (Rituximab, MabThera; Roche, Basel, Switzerland; 375 mg/m<sup>2</sup> intravenous infusion: four doses over a four week period). Three months after the initial diagnosis, a further biopsy showed persistent ulceration and an associated inflammatory reaction with dense underlying fibrosis. The larger pleomorphic lymphocytes were no longer present and immunostaining revealed some residual T cells and a complete absence of B cells. Furthermore, EBV ISH staining showed that there were no EBER positive cells present (fig 2). Follow up is now at 18 months and there is no clinical evidence of recurrent lymphoproliferative disease.

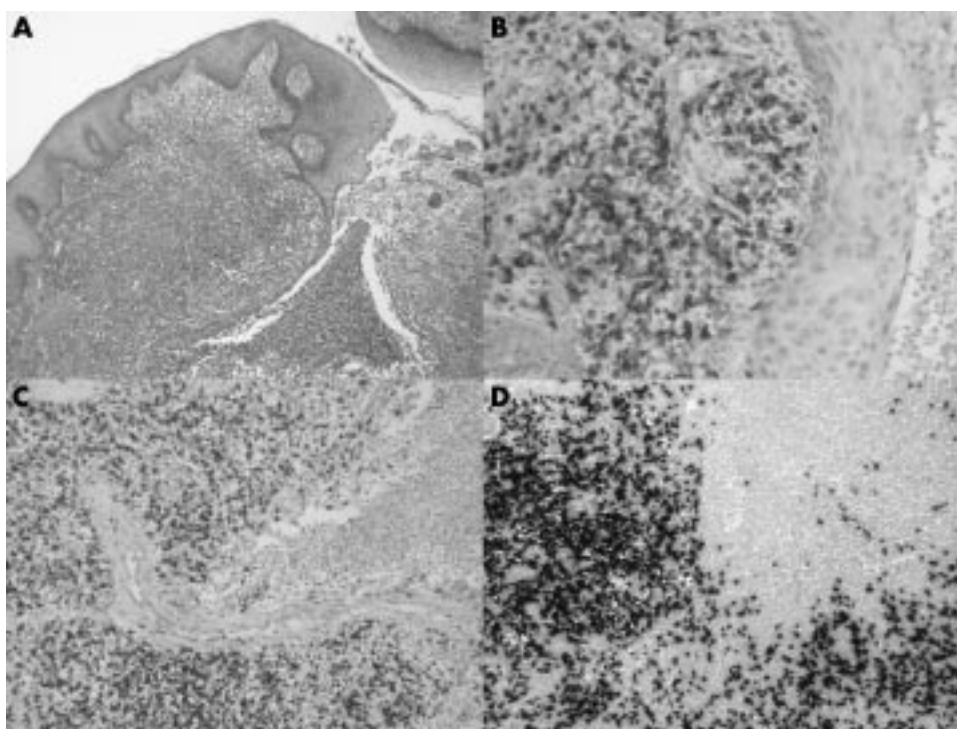
### DISCUSSION

We have presented a case of isolated cutaneous EBV related LPD with the features of lymphomatoid granulomatosis. The lesion arose in an immunocompromised patient with WAS, and treatment with immunotherapy showed a pronounced, immunohistologically demonstrable response.

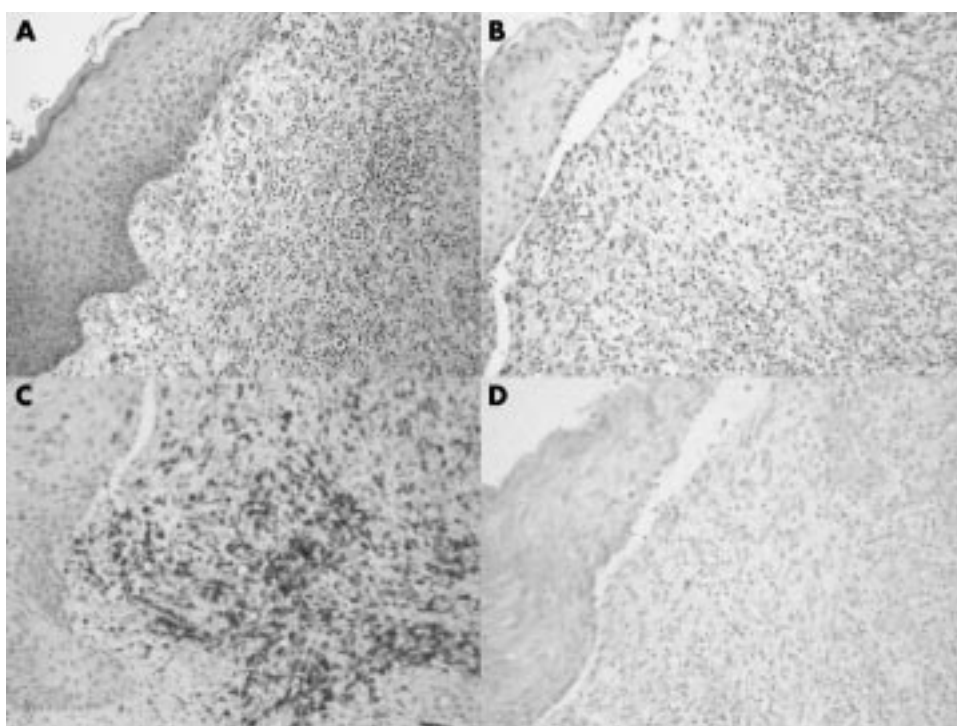
Immunosuppressed patients are prone to clinical complications of EBV infection, including both PTLD and B cell lymphoma, and EBV related LPD is a recognised complication of immunodeficiencies such as WAS.<sup>1</sup> The mechanism of this association may relate to an abnormal response of lymphocytes to EBV infection, and reduced surface expression and aberrant proteolysis of CD23 in patients with WAS, and coexistent EBV infection has been reported.<sup>3</sup>

Apparently isolated EBV related cutaneous LPD has been previously reported in patients receiving immunosuppression.<sup>4</sup> Histologically, these cases show a diffuse perivascular proliferation of large lymphocytes that express CD20, EBV latent membrane protein 1, and EBV nuclear antigen 2. In the setting of immunosuppression, the lymphoid

**Abbreviations:** EBER, Epstein-Barr encoded viral RNAs; EBV, Epstein-Barr virus; ISH, in situ hybridisation; LPD, lymphoproliferative disorders; LyG, lymphomatoid granulomatosis; PTLD, post-transplant lymphoproliferative disorder; WAS, Wiskott-Aldrich syndrome



**Figure 1** Composite photomicrograph from pretreatment skin biopsy. (A) Haematoxylin and eosin stain. (B) CD79a immunostaining for B cells. (C) CD5 immunostaining for T cells. (D) In situ hybridisation for Epstein-Barr encoded viral RNAs.



**Figure 2** Composite photomicrograph from post-treatment skin biopsy. (A) Haematoxylin and eosin stain. (B) CD79a immunostaining for B cells. (C) CD5 immunostaining for T cells. (D) In situ hybridisation for Epstein-Barr encoded viral RNAs.

proliferations are initially polyclonal, with progression to monoclonality, and can respond to a reduction in immunosuppressive treatment.<sup>4</sup> LyG is a rare form of extranodal EBV LPD in which histology shows an angiocentric and angiodestructive pattern and a mixed T and B cell infiltrate. The most common site is in the lung, but cutaneous disease is well recognised.<sup>5</sup> Predisposing conditions include organ transplantation, WAS, human immunodeficiency virus infection, and X linked lymphoproliferative syndrome. The skin lesion in our patient showed tissue destruction, an angiocentric pattern, a mixed T and B cell infiltrate, and EBER containing B cells, all of which indicated a diagnosis of LyG rather than the usual post-transplant form of LPD. In addition, molecular studies detected immunoglobulin gene rearrangement, a finding reported in most cases of LyG.<sup>5</sup>

Although primary cutaneous manifestations of EBV LPD are rare, EBV infection has been described in both cutaneous lymphoma and cutaneous manifestations of PTLD.<sup>4</sup> The mechanism by which EBV infection leads to lymphoproliferation is not clear, but involves the protection of infected cells from apoptosis, and a recent study indicates that high MDM2 protein expression by EBV infected cells may be important.<sup>6</sup> The apparent localisation of EBV infected lymphocytes to a single region of skin, as seen in our patient, is unusual. It is possible that a preexisting inflammatory or infective focus was responsible for this dermatotropism. Most PTLDs contain predominantly B cells, so the presence of a mixed B and T cell infiltrate could indicate a previous T cell inflammatory reaction. However, there was no clinical response to treatment with antibacterial or antifungal agents, and it is equally

### Take home messages

- Patients with immunodeficiencies are at risk of developing Epstein-Barr virus (EBV) related lymphoproliferative disease (LPD)
- EBV LPD can present as an isolated cutaneous lesion and may show the clinical and pathological features of lymphomatoid granulomatosis
- EBV LPD may respond dramatically to anti-CD20 immunotherapy

possible that the EBV LPD arose in the skin as a primary event, with the ulceration and associated inflammation representing secondary phenomena. EBV transformed cells express a variety of cell surface adhesion molecules,<sup>7</sup> which in certain circumstances may result in tissue localisation.

“This is the first report of the use of Rituximab in treating lymphomatoid granulomatosis, and in this patient it resulted in both clinical and pathological remission”

The treatment of choice for this patient's immunodeficiency is bone marrow transplantation,<sup>8</sup> but in the presence of EBV LPD further immunosuppression is contraindicated. In the post-transplant setting, EBV LPD can be treated with humanised anti-CD20 monoclonal antibody (Rituximab),<sup>9</sup> and this could be given before a modified bone marrow transplant. Intralesional Rituximab has been used in cutaneous B cell lymphoma.<sup>10</sup> The mode of action of Rituximab appears to relate to cytotoxic T cells, antibody dependent cellular cytotoxicity, and complement mediated cytotoxicity.<sup>11</sup> This is the first report of the use of Rituximab in treating LyG, and in this patient it resulted in both clinical and pathological remission. It is interesting to note that Rituximab was effective here, despite the presence of a large number of T cells in the infiltrate, together with the clonal population of B cells, suggesting that T cell recruitment is an important component of the disease.

In summary, we have presented a case of isolated cutaneous EBV related LPD showing the features of lymphomatoid granulomatosis arising in an immunocompromised patient with WAS. The lesion showed a pronounced, immunohistologically demonstrable response to anti-CD20 immunotherapy. Such immunotherapeutic agents will probably play

an increasing role in future treatment regimens, and this case highlights the importance of the use of immunological and molecular methods in making a precise pathological diagnosis.

### Authors' affiliations

**N J Sebire, S Haselden, M Malone, A D Ramsay**, Department of Histopathology, Great Ormond Street Hospital for Children, Great Ormond Street, London WC1N 3JH, UK

**E G Davies**, Department of Immunology, Great Ormond Street Hospital for Children

Correspondence to: Dr A D Ramsay, Department of Histopathology, Great Ormond Street Hospital for Children, Great Ormond Street, London WC1N 3JH, UK; a.ramsay@ich.ucl.ac.uk

Accepted for publication 27 January 2003

### REFERENCES

- 1 **Elenioba-Johnson KS**, Jaffe ES. Lymphoproliferative disorders associated with congenital immunodeficiencies. *Semin Diagn Pathol* 1997;**14**:35–47.
- 2 **Dodd GD**, 3rd, Ledesma-Medina J, Baron RL, *et al*. Posttransplant lymphoproliferative disorder: intrathoracic manifestations. *Radiology* 1992;**184**:65–9.
- 3 **Simon HU**, Higgins EA, Demetriou M, *et al*. Defective expression of CD23 and autocrine growth-stimulation in Epstein-Barr virus (EBV)-transformed B cells from patients with Wiskott-Aldrich syndrome (WAS). *Clin Exp Immunol* 1993;**91**:43–9.
- 4 **Iwatsuki K**, Xu Z, Ohtsuka M, *et al*. Cutaneous lymphoproliferative disorders associated with Epstein-Barr virus infection: a clinical overview. *J Dermatol Sci* 2000;**22**:181–95.
- 5 **Beatty MW**, Toro J, Sorbara L, *et al*. Cutaneous lymphomatoid granulomatosis—correlation of clinical and biological features. *Am J Surg Pathol* 2001;**25**:1111–20.
- 6 **El Mansouri S**, Martin A, Mercadier A, *et al*. High expression of MDM2 protein and low rate of p21 (WAF1/CIP1) expression in SCID mice Epstein Barr virus-induced lymphoproliferation. *J Histochem Cytochem* 1999;**47**:1315–22.
- 7 **Rincon J**, Prieto J, Patarroyo M. Expression of integrins and other adhesion molecules in Epstein-Barr virus-transformed B lymphoblastoid cells and Burkitt's lymphoma cells. *Int J Cancer* 1992;**51**:452–8.
- 8 **Filipovich AH**, Stone JV, Tomany SC, *et al*. Impact of donor type on outcome of bone marrow transplantation for Wiskott-Aldrich syndrome: collaborative study of the International Bone Marrow Transplant Registry and the National Marrow Donor Program. *Blood* 2001;**97**:1598–603.
- 9 **Milpied N**, Vasseur B, Garnier JL, *et al*. Humanized anti-Cd20 monoclonal antibody (Rituximab) in post transplant B-lymphoproliferative disorder: a retrospective analysis on 32 patients. *Ann Oncol* 2000;**11**:11351–16S1.
- 10 **Paul T**, Radny P, Krober SM, *et al*. Intralesional rituximab for cutaneous B-cell lymphoma. *Br J Dermatol* 2001;**144**:1239–43.
- 11 **Selenko N**, Majdic O, Draxler S, *et al*. CD20 antibody (C2B8)-induced apoptosis of lymphoma cells promotes phagocytosis by dendritic cells and cross-priming of CD8+ cytotoxic cells. *Leukemia* 2001;**15**:1619–26.