

PostScript

CORRESPONDENCE

If you have a burning desire to respond to a paper published in the *Journal of Clinical Pathology*, why not make use of our "rapid response" option?

Log on to our website (www.jclinpath.com), find the paper that interests you, and send your response via email by clicking on the "eletters" option in the box at the top right hand corner.

Providing it isn't libellous or obscene, it will be posted within seven days. You can retrieve it by clicking on "read eletters" on our homepage.

The editors will decide as before whether to also publish it in a future paper issue.

Recurrent urachal adenocarcinoma

Primary adenocarcinoma of the bladder accounts for less than 1% of all bladder malignancies.¹ Of these, 20-39% are urachal in origin. Urachal adenocarcinoma is more common in men and tends to present in the 5th or 6th decades, although it has been described in a 15 year old girl.² The common presenting symptoms are haematuria, pain, irritative symptoms, and mucousuria.³ We report a 37 year old woman who presented with a history of irritative voiding symptoms and a suprapubic mass. Five years earlier, she had undergone a laparotomy, partial cystectomy, and excision of a urachal tumour at another centre. Cystoscopy revealed no definite intravesical lesion, apart from a small diverticulum at the site of the previous bladder resection. A bladder biopsy showed a minimal degree of oedema and chronic inflammation, but no other abnormality. A contrast computed tomography scan revealed a mass lesion deep to the anterior abdominal wall, measuring 5 cm in diameter. It was consistent with recurrent carcinoma in the region of the urachal remnant. At laparotomy, we found a mass lesion, situated 10 cm superior to the dome of the bladder, which was attached to the posterior wall of the rectus abdominus muscle. A wide excision of the mass was performed including a large ellipse of skin and rectus muscle. A portion of the dome of the bladder was excised separately to exclude microscopic involvement, and lymph nodes from the omentum were also biopsied.

Histologically, such tumours are often mucinous in phenotype, as was the case in our patient.⁴ The tumour was multicystic and infiltrated the muscle in an expansile fashion. The epithelium showed only minor atypia, with nuclear hyperchromasia and stratification (fig 1). Comparison of the histology with the resection specimen taken five years earlier showed an identical picture, confirming this as a recurrent urachal adenocarcinoma.

The prognosis for urachal adenocarcinoma does not differ significantly from non-urachal adenocarcinoma, and is relatively poor, with



Figure 1 High power photomicrograph of a well differentiated urachal adenocarcinoma showing abundant mucin secretion (upper part).

a five year survival of 37% and a 10 year survival of 17%.⁴ This may result from the relatively late presentation and advanced stage of these tumours. The treatment is primarily surgical, with extended partial or total cystectomy, and en bloc excision of the urachal mass, urachal tract, and umbilicus advocated.⁵ These tumours are radioresistant and the results of adjuvant chemotherapy are not yet clear.³

Urachal adenocarcinoma is an uncommon malignancy that often presents late because of its location and relatively non-specific symptoms. This probably results in its poor prognosis. Adequate primary surgery and close follow up is the treatment of choice. Importantly, despite the poor published prognosis and presentation with stage III disease, our patient has survived with only a local recurrence after five years.

D Besarani, C A Purdie, N H Townell

Tayside University Hospitals NHS Trust, Ninewell Hospital, Dundee DD1 9SY, UK; cler29@hotmail.com

References

- 1 Thomas DG, Ward AM, Williams JL. A study of 52 cases of adenocarcinoma of the bladder. *Br J Urol* 1971;**43**:4-15.
- 2 Cornil C, Reynolds CT, Kikkham CJ. Carcinoma of the urachus. *J Urol* 1967;**98**:93-5.
- 3 Sheldon CA, Clayman RV, Gonzalez R, et al. Malignant urachal lesions. *J Urol* 1984;**131**:1-8.
- 4 Grignon DJ, Ro JY, Ayala AG, et al. Primary adenocarcinoma of the urinary bladder. A clinicopathologic analysis of 72 cases. *Cancer* 1991;**67**:2165-72.
- 5 Santucci RA, True LD, Lange PH. Is partial cystectomy the treatment of choice for mucinous adenocarcinoma of the urachus [review]? *Urology* 1997;**49**:536-40.

An immunodiagnostic method for the detection of Shiga-like toxinogenic *Escherichia coli* in faeces

Escherichia coli O157 is one of the most common serotypes of shiga-like toxin producing *E coli*, and has been associated with serious disease and several high profile outbreaks.¹

The Quix™ Rapid *E coli* O157 Strip Test (Universal HealthWatch Inc, Columbia, North Carolina, USA) is an immunochromatographic test that detects the O157 antigen

using a colloidal gold labelled antibody. We chose to evaluate the Quix™ Strip Test for the detection of *E coli* O157 in faecal specimens of patients with bloody diarrhoea or clinical symptoms typically associated with *E coli* O157 infection, such as haemolytic uraemic syndrome.¹

Two hundred and fifty eight consecutive patient specimens referred to our routine diagnostic laboratory with indications described above were entered into our study. Performance of the Quix™ Rapid *E coli* O157 Strip Test was compared with growth on sorbitol MacConkey agar, a method used for routine detection of *E coli* O157 in our laboratory.² The test was performed according to the manufacturer's instructions. Briefly, a sample of faeces approximately 5 mm in diameter was suspended in five drops of buffer solution. A strip was placed in the tube and the sample allowed to migrate along the strip for five minutes. The results were then read directly from the strip.

Of the 258 specimens included in our study, eight yielded *E coli* O157 on sorbitol MacConkey agar and all eight specimens were identified using the Quix™ Rapid *E coli* O157 Strip Test.

Of the 250 *E coli* O157 negative specimens, all were negative using the Quix™ Rapid *E coli* Strip Test.

We also tested a sample previously culture positive for *E coli* O157 that had been stored at 4°C for six months. This produced a positive result with the Quix strip, despite no growth on re-culture. This demonstrates that the strip test can function in the absence of viable bacteria, and therefore may be used for the retrospective study of specimens.

Limitations of the test include the high cost and inability to detect serotypes of shiga-like toxinogenic *E coli* other than O157. Few studies have assessed the frequency at which non-O157 serotypes cause disease, although a two year study in Canada reported that non-O157 shiga-like toxinogenic *E coli* were isolated from 0.7% of patient specimens.³ Further evaluation of the incidence of non-O157 shiga-like toxinogenic *E coli* would be required to determine the value of the Quix Strip Test.

The results of our limited study suggest that the strip test is highly sensitive and specific and larger scale studies may be warranted. The rapid turn around time is advantageous, providing clinicians with a prompt diagnosis, and the test may prove suitable for near patient testing. Overall, the Quix™ Rapid *E coli* O157 Strip Test was quick, accurate, and simple to use.

N J Asha, D M Gascoyne-Binzi, P M Hawkey

Leeds General Infirmary, The Old Medical School, Thoresby Place Leeds, United Kingdom, LS2 9NL, UK; nicolar@pathology.leeds.ac.uk

References

- 1 Bolton FJ, Aird H. Verocytotoxin-producing *Escherichia coli* O157: public health and microbiological significance. *Br J Biomed Sci* 1998;**55**:127-35.
- 2 March SB, Ratnam S. Sorbitol-MacConkey medium for detection of *Escherichia coli* O157:H7 associated with hemorrhagic colitis. *J Clin Microbiol* 1986;**23**:869-72.

- 3 **Griffin PM, Tauxe RV.** The epidemiology of infections caused by *Escherichia coli* O157:H7, other enterohemorrhagic *E. coli*, and the associated hemolytic uremic syndrome. *Epidemiol Rev* 1991;13:60-98.

Cartilage in bone marrow biopsy and purple granular deposits in the biopsy touch

Heparin and chondroitin sulfate are both proteoglycans. Therefore, we carried out this study to examine whether heparin-like granular deposits, which frequently impair the morphological assessment of bone marrow touch preparations, could result from the inclusion of cartilage in the bone marrow biopsy.

Touch imprints were made from bone marrow biopsies taken from the posterior superior iliac spine using Jamshidi needles.^{1,2} Bone marrow touch preparations were stained with Jenner Giemsa, and decalcified bone marrow biopsies were stained with haematoxylin and eosin.

Two hundred and twenty consecutive bone marrow touch preparations and the corresponding biopsies were evaluated for the presence of purple granular deposits and cartilage, respectively. Inspection of trephine biopsies for cartilage was done without knowledge of the touch imprint findings.

The χ^2 test was carried out to test whether granular deposits and/or bone marrow biopsy cartilage were more common in children than in adults.

One hundred and ten of the 220 touch preparations had purple granular deposits. One hundred and five cases were free of such deposits. Five cases were interpreted as equivocal with regard to granular deposits.

Samples that were positive for deposits had large numbers of fine to coarse granules, which were located extracellularly (figs 1 and 2). These could pose a significant problem in interpretation, particularly in bone marrows that were not normal or had leukaemic infiltrates. All the 110 positive cases had cartilage in the bone marrow biopsies; there was one case in which cartilage was not observed initially, but was seen when further sections were taken from the biopsy.

The five cases that were equivocal on bone marrow touch showed cartilage in the bone marrow biopsy. The touch preparation in these cases had minimal granular deposits. The findings appeared suggestive, but not definitive, for the presence of cartilage. However, their similarity with the sparsely granular appearance at the periphery of florid

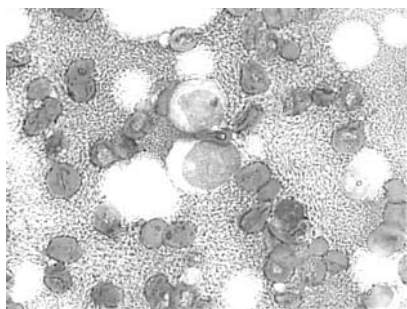


Figure 1 Purple granular deposits in a bone marrow touch preparation (Jenner Giemsa stained; original magnification, $\times 1000$).

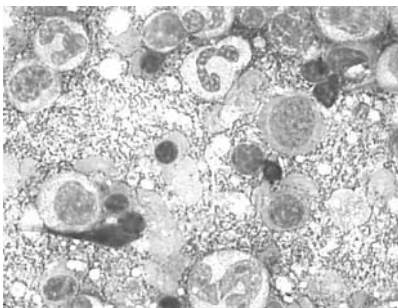


Figure 2 Purple granular deposits in a bone marrow touch preparation (Jenner Giemsa stained; original magnification, $\times 1000$).

deposits showed that the equivocal appearance, too, was probably of cartilaginous origin.

In none of the 105 cases where the bone marrow touch preparation was free of granular deposits was cartilage seen in the biopsy.

Among the 220 patients, 83 were children (≤ 15 years). Of these 83, 68 were positive for granular deposits and cartilage, whereas the remaining 15 were negative for both. When the proportion of children who had (68) or did not have (15) granular deposits was compared with the corresponding figure for adults (47 and 90, respectively), the difference, evaluated by the χ^2 test, was significant ($p < 0.0001$).

In no case were crush artefacts observed.

Purple granular deposits that obscure morphology and make the satisfactory evaluation of bone marrow touch preparations difficult or at times impossible are of common occurrence in our experience, although surprisingly, to the best of our knowledge, are not mentioned in the published literature.¹⁻³

Our results very clearly demonstrate that purple granular deposits, generally dense, in bone marrow touch preparation appear only if cartilage is included in the bone marrow biopsy. The odd case with apparently no cartilage results from the orientation of the bone marrow biopsy, such that a particular section may fail to include the cartilage. In contrast, the presence of only equivocal sparse granularity in a sample containing cartilage can be explained by the proportion constituted by, and the position of, the cartilage within the biopsy, and the way it has been touched on to a slide.

The high frequency of cartilage in the trephine bone marrow biopsy of children has been documented previously,⁴ and explains the more common occurrence of granular deposits in biopsies from children. The absence of crush artefacts on the touch preparations showed that excess force was not used when making imprints.

The importance of this observation lies in the fact that not only are bone marrow biopsies commonly performed, but the touch preparation made from them may at times be the most important resource for the evaluation of morphology, cytochemistry, or immunocytochemistry.³ This may occur, for instance, when fibrosis or a densely cellular bone marrow make the bone marrow aspiration unsatisfactory.⁴ In our cancer centre, where bone marrow biopsy with touch imprint rather than aspiration is the commonly performed procedure, this artefact at times impedes swift reporting of the bone marrows.

We conclude that purple granular deposits that impair the evaluation of bone marrow touch preparations are a result of the presence of cartilage in the bone marrow biopsy, and are seen more often in children.

Acknowledgements

Help from Dr R Gupta in this work is acknowledged.

M Anand, R Kumar, N Panikar

Unit of Laboratory Oncology, Institute Rotary Cancer Hospital; rajivekr@hotmail.com

A Karak

Department of Pathology, All India Institute of Medical Sciences, New Delhi 110029, India

References

- 1 **Brunning RD, McKenna RW.** *Tumors of the bone marrow*, Fascicle 9. Washington DC: Armed Forces Institute of Pathology, 1994.
- 2 **Koepeke JA.** *Laboratory hematology*. New York: Churchill Livingstone, 1984.
- 3 **Peterson LC, Brunning RD.** Bone marrow specimen processing. In: Knowles DM, eds. *Neoplastic hematopathology*. Philadelphia: Lippincott Williams and Wilkins, 2001:1391.
- 4 **Bain BJ, Clark DM, Lampert IA.** *Bone marrow pathology*. London: Blackwell Scientific Publication, 1996.
- 5 **Krause JR.** *Bone marrow biopsy*. New York: Churchill Livingstone, 1981.

Results of measurement of urine osmolality and sodium in the evaluation of severe hyponatraemia

Measurement of urine osmolality and urine sodium is often advocated in the evaluation of severe hyponatraemia. In a recent article in the *Journal of Clinical Pathology*, Saeed and colleagues documented the frequency with which these investigations were performed.¹ However, the results of urine biochemistry obtained in the assessment of severe hyponatraemia are rarely reported.²

We examined the computer records of 59 patients (44 women, 15 men; age range, 22-93 years) found in 2002 to have a serum sodium of less than 120 mmol/litre, in whom a urine osmolality was requested at around the same time (the total number of patients with a serum sodium of less than 120 mmol/litre during the same period was 304). Case notes were available for 34 of these patients. Figures 1 and 2 show the results of urine osmolality and sodium measurement, respectively. Serum osmolality confirmed a hypo-osmolal state in 41 of the 45 patients in whom it was measured. Of the four patients in whom a hypo-osmolal state was not confirmed, three were uraemic and one was hyperglycaemic. Cortisol was measured, either randomly or as part of a short synacthen test, in 28 patients; it was greater than 560 nmol/litre in all but two, both of whom had secondary adrenal insufficiency, one as a result of treatment with high dose steroids, and the other because of failing to comply with steroid replacement after hypophysectomy. Thyroid stimulating hormone was in the hypothyroid range in eight of 36 patients, although hyponatraemia was attributed to hypothyroidism in only two of these. Clinical information sought included volaemic status (for example, dehydration and oedema), postural hypotension, clues from the history about the likely mechanism of hyponatraemia, and how the patient was

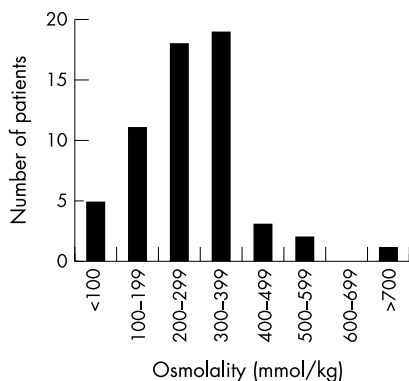


Figure 1 Distribution of urine osmolality results.

treated (for example, fluid restriction, steroids, etc).

Urine osmolality was 100 mmol/kg or more in 54 of 59 patients, and was less than 600 mmol/kg in all but one patient, who had septic shock (fig 1). These data raise several issues relating to the usefulness of urine osmolality results in the assessment of hyponatraemia. First, the results obtained from the measurement of urine osmolality merely confirm the presence of impaired water excretion in most hyponatraemic patients. Formal diagnosis of the syndrome of inappropriate secretion of antidiuretic hormone (SIADH) may require the demonstration of a urine osmolality that is inappropriately high for the serum osmolality,³ but it should be obvious clinically when water excretion is not impaired; maximally dilute urine is associated with very high urine flow rates (in excess of 500 ml/hour). Second, impaired water excretion, however it is established, does not in itself establish the mechanism of hyponatraemia. It may signify inappropriate antidiuresis, but is equally consistent with sodium depletion (the hypovolaemia resulting from sodium and water loss is a powerful non-osmotic stimulus to antidiuretic hormone secretion). Thus, knowledge of the patient's volaemic status is essential for the meaningful interpretation of urine osmolality results. Third, the ability of urine osmolality to discriminate between mechanisms of hyponatraemia may be limited, given the relatively narrow range of urine osmolality (100 to 600 mmol/kg) observed in all but six patients. However, this is speculative, and much larger numbers are required to assess whether this is the case; only two patients were identified with clear evidence of sodium depletion.

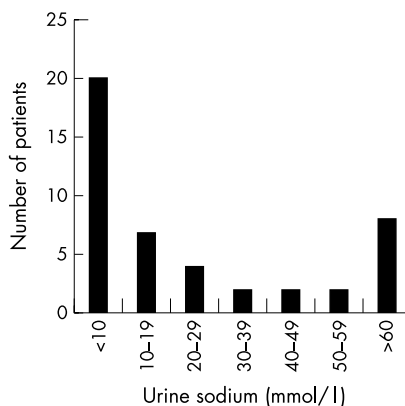


Figure 2 Distribution of urine sodium concentrations.

In 27 of 45 patients, urine sodium was less than 20 mmol/litre (fig 2). Only 12 patients had urine sodium concentrations in the range typically observed in SIADH (40 mmol/litre or more).⁴ The combination of impaired water excretion and sodium retention is characteristic of effective circulating volume depletion. Other causes of true hyponatraemia and impaired water excretion are associated with higher urine sodium concentrations (greater than 40 mmol/litre). What do these findings tell us about the prevalence of hypovolaemia in severely hyponatraemic patients? The clinical information we reviewed retrospectively (not shown) was incomplete, and it was often not possible unequivocally to attribute hyponatraemia to a specific cause or mechanism. These limitations also apply in some degree to previous surveys of hyponatraemia, including that of Saeed and colleagues.¹⁻⁵ Nevertheless, it may come as a surprise that we did not find a greater number of higher urine sodium concentrations in this population. Our findings underline the need for complete relevant information to be collected if the prevalence of different causes and mechanisms of severe hyponatraemia is to be established with any degree of accuracy, and, just as importantly, if the clinical usefulness of urine biochemistry in the evaluation of severe hyponatraemia is to be better defined.

Acknowledgement

The authors would like to acknowledge the help of Mr I Kennedy in collecting the computer data.

P-A Laloë, A Wong

Ninewells Hospital and Medical School, University of Dundee, Dundee DD1 9SY, UK

M J Murphy

Department of Biochemical Medicine, Ninewells Hospital, Dundee DD1 9SY, UK; michael.murphy@tuht.scot.nhs.uk

References

- 1 Saeed BO, Beaumont D, Handley GH, *et al*. Severe hyponatraemia: investigation and management in a district general hospital. *J Clin Pathol* 2002;**55**:893-6.
- 2 Thomas TH, Morgan DB, Swaminathan R, *et al*. Severe hyponatraemia. A study of 17 patients. *Lancet* 1978;*i*:621-4.
- 3 Bartter F, Schwartz WB. The syndrome of inappropriate secretion of antidiuretic hormone. *Am J Med* 1967;**42**:790-806.
- 4 Rose BD, Post TW. *Clinical physiology of acid-base and electrolyte disorders*, 5th ed. New York: McGraw-Hill, 2001.
- 5 Crook M, Velauthar U, Moran L, *et al*. Review of investigation and management of severe hyponatraemia in a hospital population. *Ann Clin Biochem* 1999;**36**:158-62.

CALENDAR OF EVENTS

Full details of events to be included should be sent to Maggie Butler, Technical Editor JCP, The Cedars, 36 Queen Street, Castle Hedingham, Essex CO9 3HA, UK; email: maggie.butler2@btopenworld.com

Surgical Pathology for the Practising Pathologist

16-19 January 2004, Doubletree La Posada Resort, Scottsdale, Arizona, USA
Further details: Department of Continuing Education, Harvard Medical School, PO Box 825, Boston, MA 02117-0825, USA. (Tel: +1 617 384 8600; Fax: +1 617 384 8686; Email: hms-cme@hms.harvard.edu)

Surgical Pathology for the Practising Pathologist: Selected Topics

26-29 March 2004, Sanibel Harbour Resort and Spa, Fort Myers, Florida, USA
Further details: Department of Continuing Education, Harvard Medical School, PO Box 825, Boston, MA 02117-0825, USA. (Tel: +1 617 384 8600; Fax: +1 617 384 8686; Email: hms-cme@hms.harvard.edu)

Medicare India

6-8 April 2004, Pragati Maidan, New Delhi, India
Further details: Rob Grant, Kinex Log, 5 New Quebec Street, London W1H 7DD, UK (Tel: +44 (0) 207 723 8020; Fax: +44 (0) 207 723 8060; Email: rob.grant@kinexlog.com; Website: www.medicare-expo.com or www.kinexlog.com)