

# PostScript

## CORRESPONDENCE

If you have a burning desire to respond to a paper published in the *Journal of Clinical Pathology*, why not make use of our "rapid response" option?

Log on to our website ([www.jclinpath.com](http://www.jclinpath.com)), find the paper that interests you, and send your response via email by clicking on the "eLetters" option in the box at the top right hand corner.

Providing it isn't libellous or obscene, it will be posted within seven days. You can retrieve it by clicking on "read eLetters" on our homepage.

The editors will decide as before whether to also publish it in a future paper issue.

### Molecular confirmation of invasive infection caused by *Chaetomium globosum*

Identification of the causative organism in invasive fungal infections is difficult. Accurate and reliable diagnostic methods are required in light of the increasing incidence of emerging fungal infections.<sup>1</sup> We recently described a method for speciating fungi in formalin fixed, paraffin wax embedded tissue sections.<sup>2</sup> DNA is extracted using a modification of the protocol for the TaKaRa DEXPAT™ kit (TaKaRa Biomedicals, Cambrex Biosciences, Wokingham, UK), with additional steps using lyticase and ethanol precipitation.<sup>2</sup> Amplification of the DNA is performed using panfungal primers and a method based on that described by Einsele *et al.*<sup>3</sup> Identification to species level can be achieved by Southern hybridisation with a probe that binds *Aspergillus fumigatus*, *A. flavus*, and *A. versicolor*. Polymerase chain reaction products that do not hybridise with this probe are subsequently identified by sequence analysis.<sup>2</sup>

We have used this method to confirm the diagnosis in the case of a patient with acute myeloid leukaemia and pneumonia caused by *Chaetomium globosum*. We previously reported the details of this case and discussed the associated diagnostic difficulties.<sup>4</sup> A computed tomography chest scan revealed cavitating lesions characteristic of an invasive fungal infection in the right upper lobe and a right lobectomy was performed. Histology demonstrated branching hyphae invading blood vessels that were "consistent with aspergillus". However, many filamentous fungi resemble aspergillus species histologically, and identification relies on culturing the organism from the tissue. In this case, *C. globosum* was cultured from the tissue specimen and identified six weeks later, by which time the patient had died. Moreover, such microbiological identification cannot differentiate between environmental contamination and causative organisms. Immunohistochemical staining of the tissue was subsequently carried out using a monoclonal antibody directed specifically against *A. fumigatus*, *A. flavus*, and *A. niger*. Results were

negative, confirming that the infection was not caused by these common aspergillus species. *Chaetomium globosum* is a rare pathogen but a common contaminant, so we were left with a presumptive diagnosis.

We have now achieved a definitive, molecular diagnosis of an invasive fungal infection caused by *C. globosum* in this case using the method described above. Sections from the original paraffin wax embedded tissue were cut with a sterile microtome blade and two 10 µm thick sections were subjected to DNA extraction, after discarding the outer section. A positive result was obtained after polymerase chain reaction amplification with panfungal primers, but subsequent hybridisation with the aspergillus specific probe yielded a negative result. The DNA was purified using Wizard® PCR Preps DNA purification system (Promega, Madison, Wisconsin, USA), according to the manufacturer's instructions. The DNA was commercially sequenced (Cytomyx, Cambridge, UK), after which sequence analysis was performed with the EMBOSS software package (HGMP-RC; Medical Research Council, London, UK). The sequence was identified as *C. globosum* using a BLAST search of Genbank and EMBL nucleotide sequence databases and subsequently submitted to the EMBL database (accession number AJ781794).

The *C. globosum* isolate had been added to the UK National Collection of Pathogenic Fungi as NCPF 7115. We subcultured this isolate then extracted, purified, and sequenced the genomic DNA. The sequence was identical to that of the DNA extracted from the tissue sample, confirming the causative role of this organism in our case.

With the growing population of immunocompromised patients and the broadening spectrum of antifungal agents available it is imperative that we can accurately identify the organisms causing invasive fungal infections. This case illustrates the value of molecular tools to enhance the diagnostic process.

**P J Paterson, S Seaton, T Yeghen, T D McHugh**  
Department of Microbiology, Royal Free Hospital,  
Pond Street, London NW3 2QG, UK

**J McLaughlin**  
Department of Histopathology, Royal Free Hospital

**A V Hoffbrand**  
Department of Haematology, Royal Free Hospital

**C C Kibbler**  
Department of Microbiology, Royal Free Hospital;  
kibbler@rfc.ucl.ac.uk

### References

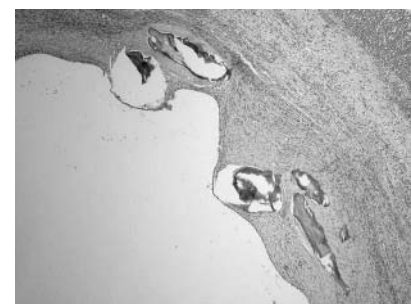
- 1 Perfect JR, Schell WA. The new fungal opportunists are coming. *Clin Infect Dis* 1996;22:S112-18.
- 2 Paterson PJ, Seaton S, McLaughlin J, *et al.* Development of molecular methods for the identification of aspergillus and emerging moulds in wax tissue sections. *Mol Pathol* 2003;56:368-70.
- 3 Einsele H, Hebart H, Roller G, *et al.* Detection and identification of fungal pathogens in blood by using molecular probes. *J Clin Microbiol* 1997;35:1353-60.
- 4 Yeghen T, Fenelon L, Campbell CK, *et al.* *Chaetomium pneumonia* in patient with acute myeloid leukaemia. *J Clin Pathol* 1996;49:184-6.

### Osseous metaplasia in a benign ovarian cyst in association with cloacal anomaly

Osseous metaplasia has been described at many sites and in association with a large number of tumours. However, previous reports of osseous metaplasia in ovarian lesions are rare, there being only three published cases, which were associated with papillary serous carcinoma, thecoma, and endometrioma.<sup>1-3</sup> We report a case of osseous metaplasia hitherto undescribed in a benign ovarian cyst in a girl with a complex urogenital malformation.

The patient was a 16 year old girl, who was diagnosed with a complex cloacal anomaly at birth, requiring posterior sagittal anorectovaginourethroplasty, followed by further lower urinary tract reconstructive procedures. At the time of surgery, normal ovaries and fallopian tubes were noted. She attained menarche at 14. Two years later she complained of lower abdominal pain and dysmenorrhoea. Ultrasound examination revealed a large cystic lesion in the right side of the pelvis. No calcification was seen on pelvic imaging and tumour markers were normal. Repeated aspiration did not result in longterm symptom relief and an open resection was performed. At surgery, a large multiseptated cyst was noted occupying most of the pelvis behind the augmented bladder on the right and crossing the midline, closely adherent to the right ovary and right fallopian tube. The right ovary was partially resected along with the cyst. Postoperative recovery was uneventful. Histological examination demonstrated a complex tubal cyst with chronic salpingitis, in addition to a simple follicular ovarian cyst, in the wall of which osseous metaplasia was noted (fig 1). The entire specimen was embedded and multiple sections examined, but there were no additional features present to suggest a teratoma.

The pathogenesis of osseous metaplasia is unclear, but in some circumstances appears to be an unusual reaction to tissue damage and repair. It is interesting that the previously reported case associated with an endometriotic ovarian cyst also occurred in an anatomically abnormal pelvis, in a supernumerary ovary.<sup>2</sup> Osseous metaplasia in a benign ovarian cyst appears to be an unusual incidental finding of unknown importance and aetiology, which is more common in



**Figure 1** Photomicrograph of a simple follicular ovarian cyst with focal osseous metaplasia in a 16 year old girl with a cloacal anomaly. Original magnification, ×40.

anatomically abnormal ovarian tissue in women of reproductive age.

**P Godbole, A Outram, N Sebire**

Departments of Paediatric Urology and Histopathology, Great Ormond Street Hospital for Children, London WC1N 3JH, UK; prasadgodbole@btinternet.com

**References**

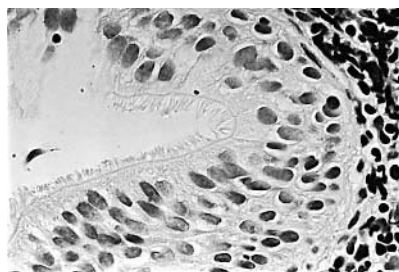
- 1 **Bosscher J, Barnhill D, O'Connor D, et al.** Osseous metaplasia in ovarian papillary serous cystadenocarcinoma. *Gynecol Oncol* 1990;**39**:228–31.
- 2 **Badawy SZ, Kasello DJ, Powers C, et al.** Supernumerary ovary with an endometrioma and osseous metaplasia: a case report. *Am J Obstet Gynecol* 1995;**173**:1623–4.
- 3 **Morizane M, Ohara N, Mori T, et al.** Ossifying luteinized thecoma of the ovary. *Arch Gynecol Obstet* 2003;**267**:167–9.

**Congenital bronchogenic cyst in the gastric mucosa**

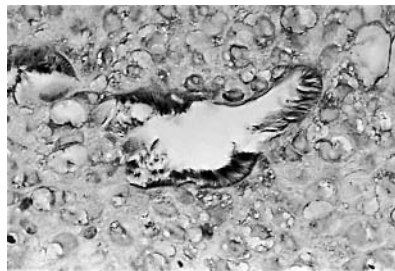Bronchogenic cysts are congenital anomalies evolving from the ventral foregut between the 3<sup>rd</sup> and the 7<sup>th</sup> prenatal weeks. They are lined with cuboidal or pseudostratified ciliated epithelium and may or may not be surrounded by elastic fibres, smooth muscle, and cartilage.

Bronchogenic cysts are divided into thoracic and abdominal.<sup>1</sup> Abdominal bronchogenic cysts are rare, particularly those located exclusively within the confines of the gastric wall. Despite the fact that Gensler and colleagues<sup>1</sup> described the first case nearly 50 years ago, only two additional cases have been reported.<sup>2,3</sup> Recently, we identified a new case of bronchogenic cyst in the gastric mucosa. The purpose of this letter is to draw attention to an important differential diagnosis between gastric congenital intramucosal cysts and acquired intramucosal cysts also lined with ciliated cells.<sup>4</sup>

A 26 year old Swedish man presented because of periodic epigastric pain. The pain began 18 months previously and was periodically treated with proton pump inhibitors. Palpation resulted in epigastric pain. Oesophageal manometry and pH were normal. Gastroscopy showed mild oesophagitis and normal gastric mucosa. Pinch biopsies revealed grade 1 oesophagitis and normal gastric mucosa without *Helicobacter pylori* infection. However, an intramucosal cyst was found in one of the biopsies from the corpus. That cyst was lined with pseudostratified epithelium built from cuboidal cells (fig 1), some of them vacuolated. Cartilaginous tissue was not found but a lymphatic follicle was present in the lamina propria. The adjacent mucosa of the fundus was normal. The cells lining the luminal aspect of the cyst had densely packed cilia (fig 1). Each cilium



**Figure 1** Gastric intramucosal bronchogenic cyst with ciliated pseudostratified epithelium (haematoxylin and eosin stain; original magnification, ×50).



**Figure 2** Gastric intramucosal bronchogenic cyst showing ciliated structures expressing tubulin B (immunohistochemical staining for tubulin B; original magnification, ×25).

was approximately 6 µm long and stained positively for tubulin B (fig 2). Staining with periodic acid Schiff diastase revealed only one positive clear cell. The aforementioned vacuolated cells were periodic acid Schiff negative. Staining for Ki67 (clone MIB1) showed no signs of epithelial proliferation.

The patient received omeprazol medication and the symptoms disappeared.

The histological lining of this bronchogenic cyst differs from other reported intramucosal gastric cysts also lacking cartilage; namely: foveolar, fundic, pyloric, intestinal metaplastic, and ciliated metaplastic cysts.<sup>4</sup> Cysts with ciliated metaplasia are usually located in the antrum and they are lined with a single row of gastric seromucinous cuboidal cells or with intestinal metaplastic goblet cells that have irregular cilia. Cysts with ciliated metaplasia evolve as a result of environmental factors, particularly in Asian patients harbouring a gastric carcinoma of the intestinal type.<sup>5,6</sup>

Gastric bronchogenic cysts are rare; a similar type of cyst has not been found in two large series comprising 1675 gastric biopsies<sup>7</sup> and 3406 resected stomachs<sup>5</sup> from patients dwelling in disparate geographical regions.

In conclusion, congenital bronchogenic cysts should be differentiated from acquired gastric ciliated cysts evolving as a consequence of environmental factors.<sup>5</sup>

**C A Rubio, A Orrego**

Department of Pathology, Gastrointestinal and Liver Pathology Research Laboratory, Karolinska Institute, 76 Stockholm, Sweden; carlos.rubio@onkpat.ki.se

**R Willén**

Department of Pathology, Uppsala University Academic Hospital, 75185 Uppsala, Sweden

**References**

- 1 **Gensler S, Seidenberg B, Rifkin H, et al.** Ciliated lined intramucosal cyst of the stomach. *Ann Surg* 1966;**163**:954–6.
- 2 **Tanenbaum B, Levowitz B, Ponce M, et al.** Respiratory choristoma of the stomach. *N Y State Med J* 1971;**71**:373–5.
- 3 **Shireman P.** Intramural cyst of the stomach. *Hum Pathol* 1987;**18**:857–8.
- 4 **Kato Y, Sugano H, Rubio CA.** Classification of intramucosal cysts of the stomach. *Histopathology* 1983;**7**:931–8.
- 5 **Rubio CA, Owen D, King A, et al.** Ciliated gastric metaplasia. A study of 3406 trectomy specimens from dwellers of the Atlantic and the Pacific basins. *J Clin Pathol* [In press.]
- 6 **Rubio CA, Stemmermann GN, Hayashi T.** Ciliated gastric cells among Japanese living in Hawaii. *Jpn J Cancer Res* 1991;**82**:86–9.
- 7 **Rubio CA, Jessurun J.** Low frequency of intestinal metaplasia in gastric biopsies from Mexican patients: a comparison with Japanese and Swedish patients. *Jpn J Cancer Res* 1992;**83**:491–4.

**VEGF-D and HIF-1α in breast cancer**

In a recent paper in the *Journal of Clinical Pathology*, Currie *et al* used immunohistochemistry on tissue microarrays to assess the expression of the hypoxia inducible factor 1α (HIF-1α) protein in breast cancer.<sup>1</sup> As we point out in a letter in this issue of the journal,<sup>2</sup> tissue microarrays are not very suitable for HIF-1α immunohistochemistry because focal perinecrotic HIF-1α staining is easily missed in the small tissue samples forming a tissue microarray. However, this perinecrotic type of HIF-1α expression is relevant in breast cancer.<sup>3</sup>

Furthermore, the authors assessed HIF-1α expression considering both the intensity and extent of nuclear and cytoplasmic reactivity. To our knowledge, there are no data supporting a functional role for cytoplasmic HIF-1α expression in breast cancer. Therefore, previous studies have only considered nuclear staining. Lastly, the authors do not describe how they arrive at a score in an individual case after considering “both the intensity and extent of nuclear and cytoplasmic reactivity”, and also the threshold used in statistical analysis is not provided. Further enlightenment on these matters would help us to appreciate the value of their findings. Perhaps, the lack of prognostic value of vascular endothelial growth factor D, which induces lymphangiogenesis, can be explained by the absence of lymphangiogenesis in invasive breast cancer.<sup>4</sup>

**P J van Diest, M M Vleugel, P van der Groep, E van der Wall**

Departments of Pathology and Medical Oncology, UMCU, Utrecht, 3508 GA, The Netherlands; p.j.vandiest@lab.azu.nl

**References**

- 1 **Currie MJ, Hanrahan V, Gunningham SP, et al.** Expression of vascular endothelial growth factor D is associated with hypoxia inducible factor (HIF-1α) and the HIF-1α target gene DEC1, but not lymph node metastasis in primary human breast carcinomas. *J Clin Pathol* 2004;**57**:829–34.
- 2 **Van Diest PJ, Vleugel MM, Van der Wall E.** Expression of HIF-1α in human tumours. *J Clin Pathol* 2005;**58**:335–6.
- 3 **Vleugel MM, Grijer AE, Shvarts D, et al.** Differential prognostic impact of hypoxia induced and diffuse HIF-1 expression in invasive breast cancer. *J Clin Pathol* 2005;**58**:172–7.
- 4 **Vleugel MM, Bos R, Van der Groep P, et al.** Lack of lymphangiogenesis during breast carcinogenesis. *J Clin Pathol* 2004;**57**:746–51.

**Expression of HIF-1α in human tumours**

We have read with interest the recent paper by Jubb *et al* on the expression of hypoxia inducible factor 1α (HIF-1α) in human tumours.<sup>1</sup> We note that they report only 5% of ductal adenocarcinomas of the breast to be HIF-1α positive. This proportion is unusually low compared with our own data and those of other workers. In our various studies, the proportion of HIF-1α positive breast cancers varied from 44% to 80%.<sup>2–4</sup> In studies from other groups, these percentages varied from 56% to 76%.<sup>5,6</sup> We believe that this discrepancy may be caused by the use of tissue microarrays. In breast cancer, HIF-1α often shows pronounced intratumour heterogeneity because of focal perinecrotic staining, which is clinically highly relevant. Even patients with only 5% of cells overexpressing



HIF-1 $\alpha$  have a much worse prognosis.<sup>3</sup> Thus, tissue arrays probably underestimate the true frequency of HIF-1 $\alpha$  overexpression in breast cancer. Hence, data from studies on HIF-1 $\alpha$  derived from tissue arrays are probably less reliable with regard to associations between HIF-1 $\alpha$  and other biomarkers and prognosis for invasive breast cancer. Therefore, we believe that conventional tumour sections are superior for the assessment of HIF-1 $\alpha$  overexpression in this type of cancer. For other cancers with a more diffuse type of staining this may be different.

#### P J van Diest

Department of Pathology, University Medical Centre Utrecht, PO Box 85500 Utrecht, The Netherlands; p.j.vandiest@lab.azu.nl

#### M M Vleugel

Department of Pathology, VU University Medical Centre, 1007 MB Amsterdam, The Netherlands

#### E van der Wall

Department of Pathology, University Medical Centre Utrecht

### References

- Jubb AM, Pham TQ, Hanby AM, *et al.* Expression of vascular endothelial growth factor, hypoxia inducible factor 1 $\alpha$ , and carbonic anhydrase IX in human tumours. *J Clin Pathol* 2004;**57**:504–12.
- Bos R, Zhong H, Hanrahan CF, *et al.* Levels of hypoxia-inducible factor-1 alpha during breast carcinogenesis. *J Natl Cancer Inst* 2001;**93**:309–14.
- Bos R, van der Groep P, Greijer AE, *et al.* Levels of hypoxia-inducible factor-1alpha independently predict prognosis in patients with lymph node negative breast carcinoma. *Cancer* 2003;**97**:1573–81.
- Vleugel MM, Greijer AE, Shvarts A, *et al.* Differential prognostic impact of hypoxia induced and diffuse HIF-1 $\alpha$  expression in invasive breast cancer. *J Clin Pathol* 2005;**58**:172–7.
- Schindl M, Schoppmann SF, Samonigg H, *et al.* Overexpression of hypoxia-inducible factor 1alpha is associated with an unfavorable prognosis in lymph node-positive breast cancer. *Clin Cancer Res* 2002;**8**:1831–7.
- Gruber G, Greiner RH, Hlushchuk R, *et al.* Hypoxia-inducible factor 1 alpha in high-risk breast cancer: an independent prognostic parameter? *Breast Cancer Res* 2004;**6**:R191–8.
- Schindl M, Schoppmann SF, Samonigg H, *et al.* Overexpression of hypoxia-inducible factor 1alpha is associated with an unfavorable prognosis in lymph node-positive breast cancer. *Clin Cancer Res* 2002;**8**:1831–7.
- Zhong H, De Marzo AM, Laughner E, *et al.* Overexpression of hypoxia-inducible factor 1alpha in common human cancers and their metastases. *Cancer Res* 1999;**59**:5830–5.
- Talks KL, Turley H, Gatter KC, *et al.* The expression and distribution of the hypoxia-inducible factors HIF-1alpha and HIF-2alpha in normal human tissues, cancers, and tumor-associated macrophages. *Am J Pathol* 2000;**157**:411–21.
- Berra E, Roux D, Richard DE, *et al.* Hypoxia-inducible factor-1 alpha (HIF-1 alpha) escapes O(2)-driven proteasomal degradation irrespective of its subcellular localization: nucleus or cytoplasm. *EMBO Rep* 2001;**2**:615–20.
- Williams CS, Leek RD, Robson AM, *et al.* Absence of lymphangiogenesis and intratumoural lymph vessels in human metastatic breast cancer. *J Pathol* 2003;**200**:195–206.
- Fox SB. Tumour angiogenesis and prognosis. *Histopathology* 1997;**30**:294–301.

### Authors' reply

We thank Professor van Diest and colleagues for their letter raising some interesting issues about hypoxia inducible factor 1 $\alpha$  (HIF-1 $\alpha$ ) in breast cancer. Our study examined vascular endothelial growth factor D (VEGF-D) expression in breast cancer and correlated expression with clinicopathological variables, with an emphasis on hypoxia markers. Van Diest *et al* suggest that tissue microarrays (TMAs) are unsuitable for the analysis of HIF-1 $\alpha$  because they may miss a particular pattern of HIF-1 $\alpha$  staining that has prognostic relevance. However, the clinical impact of these patterns is unclear because in their study HIF-1 $\alpha$  was highly associated with necrosis and grade and the survival analysis was not multivariate. Nevertheless, we agree that we identified fewer HIF-1 $\alpha$  positive tumours (17%) than van Diest *et al*, who reported 75%,<sup>1</sup> 54%,<sup>2</sup> and 44%<sup>3</sup> positivity in three studies using a 1% cutoff value, or 34% in another study when using a 5% cutoff value.<sup>4</sup> However, although van Diest *et al* suggest that others have found a similar range of HIF-1 $\alpha$  positivity (56%<sup>4</sup> and 76%<sup>5</sup>), appraisal of the published data shows that if only strong HIF-1 $\alpha$  staining is used, then

these studies show 23% HIF-1 $\alpha$  positivity. Moreover, Zhong *et al* using whole tissue sections of breast tumours reported strong HIF-1 $\alpha$  expression in only 12%.<sup>6</sup> We used a semiquantitative score of negative, weak staining, or strong staining and considered strong staining as positive (the proportion of cells was also noted (0, 0%; 1, 1–10%; 2, 11–50%; 3, 51–80%; and 4, 81–100%), but in practice when strong staining was present all the tumour cells were positive). If we re-stratify our cases using the criteria of van Diest and colleagues—nuclei that are “completely and darkly stained” and a > 1% cutoff point<sup>7</sup>—we have a positivity rate of 78%, which is within the range reported by van Diest *et al*. Indeed, because each core within a TMA can hold up to 1000 cells, we may be analysing similar amounts of tumour, but the methodology in the van Diest group's papers with regard to the number of cells, the ranges, medians, etc is unclear, so it is not possible to assess this. Thus, we think that although we may miss some HIF-1 $\alpha$  positive cases, it is probably only a small proportion, and may be compensated for by the absence of variability in staining that is common in studying large series by whole tissue sections. Furthermore, because we specifically wish to analyse the relation between molecular markers in the same region of the tumour (in the individual core/exemplar), we view the use of TMAs as an advantage.

Van Diest and colleagues also raise the issue of the subcellular localisation of HIF-1 $\alpha$ . Cytoplasmic expression of HIF-1 $\alpha$  is well recognised.<sup>6,7</sup> To ignore it appears to us premature just because it does not fit in with current models. Many so called cytoplasmic or nuclear only proteins have now been shown to shuttle to and fro between the two compartments. Indeed, it has been shown that a nuclear location is not required for HIF-1 $\alpha$  stabilisation and that HIF-1 $\alpha$  undergoes oxygen dependent proteasomal degradation in both the nucleus and the cytoplasm.<sup>8</sup>

Lastly, van Diest *et al* suggest that the lack of an association between VEGF-D and prognosis may be explained by the absence of lymphangiogenesis in breast cancer.<sup>9</sup> The notion that VEGF-D enhances lymphangiogenesis and thereby influences nodal status and prognosis is somewhat one dimensional because VEGF-D has other functions in addition to lymphangiogenesis, including lymphatic growth, lymphatic maintenance, and angiogenesis.

Thus, we think that the lack of an association is more likely the result of several factors leading to nodal metastasis, including VEGF-C, with differences in processing resulting in changes in receptor affinity. Furthermore, it is also likely that a combination of factors rather than a single factor will be clinically useful.<sup>10</sup>

#### M J Currie, V Hanrahan, S P Gunningham, H R Morrin, C Frampton, C Han, B A Robinson, S B Fox

Nuffield Department of Clinical Laboratory Sciences, John Radcliffe Hospital, University of Oxford, Oxford OX3 9DU, UK; stephen.fox@ndcls.ox.ac.uk

### References

- Bos R, van der Groep P, Greijer AE, *et al.* Levels of hypoxia-inducible factor-1alpha independently predict prognosis in patients with lymph node negative breast carcinoma. *Cancer* 2003;**97**:1573–81.
- Bos R, Zhong H, Hanrahan CF, *et al.* Levels of hypoxia-inducible factor-1 alpha during breast carcinogenesis. *J Natl Cancer Inst* 2001;**93**:309–14.

## CALENDAR OF EVENTS

Full details of events to be included should be sent to Maggie Butler, Technical Editor JCP, The Cedars, 36 Queen Street, Castle Hedingham, Essex CO9 3HA, UK; email: maggie.butler2@btopenworld.com

### Second Annual Meeting of the British Association of Gynaecological Pathologists

28 April 2005, Manchester Royal Infirmary, Manchester, UK

Further details: Mrs A Davies, Department of Histopathology, First Floor Clinical Sciences Building, Manchester Royal Infirmary, Oxford Road, Manchester M13 9WL, UK. (Tel +44 (0)161 276 8725; Fax +44 (0)161 276 6348; e-mail amanda.davies@cmmc.nhs.uk)

### Diagnostic Histopathology of Breast Disease

9–13 May 2005, Hammersmith Hospital and Imperial College, London, UK

Further details: Wolfson Conference Centre, Hammersmith Hospital, Du Cane Road, London W12 0NN, UK. (Tel +44 (0)20 8383 3117/3227/3245; Fax +44 (0)20 8383 2428; e-mail wcc@ic.ac.uk)

### Association of Clinical Pathologists' National Scientific Meeting

16–17 June 2005, Royal College of Physicians, London, UK

Further details: ACP Central Office, 189 Dyke Road, Hove BN3 1TL, UK. (Tel +44 (0)1273 775700; e-mail info@pathologists.org.uk)

### Practical Pulmonary Pathology

26–29 July 2005, Royal Brompton Hospital, London, UK

Further details: Professor B Corrin, Brompton Hospital, London SW3 6NP, UK. (Fax +44 (0)20 7 351 8293; e-mail b.corrin@ic.ac.uk)