

# Clinicopathological correlation of congenital corneal opacification using ultrasound biomicroscopy

K K Nischal, J Naor, V Jay, L D MacKeen, D S Rootman

*Br J Ophthalmol* 2002;86:62–69

**Aim:** To investigate the correlation between clinical, high frequency ultrasound biomicroscopy (UBM) and, where possible, histological findings in cases of congenital corneal opacification presenting to the departments of ophthalmology, Great Ormond Street Hospital for Children, London, and the Hospital for Sick Children, Toronto, Canada.

**Method:** 22 eyes of 13 children (age range 3–225 days) with congenitally opaque corneas were examined. UBM was performed using the ultrasound biomicroscope (Allergan-Humphrey). All eyes underwent penetrating keratoplasties (PKP) except five. The host corneas were all sent for histological examination.

**Results:** The final diagnosis in our series was Peters' anomaly in nine cases (70%), corneal dystrophy in two cases (15%), and sclerocornea in two cases (15%). The UBM findings changed the clinical diagnosis in five cases (38%). In these five cases histology was available in four and confirmed the UBM diagnosis in each case. In no case of the 13 where histology was available did it contradict the UBM findings. In two cases a hypoechoic region in the anterior stroma was seen on UBM which correlated histologically with absent Bowman's layer and oedema. In two cases UBM revealed aniridia and in one, congenital aphakia, which was not apparent clinically.

**Conclusion:** UBM examination is not only very useful in evaluating the clinical diagnosis in congenital corneal opacification, it also acts as a preoperative guide in cases undergoing PKP by detecting keratolenticular and iridocorneal adhesions and other ocular abnormalities such as aniridia and congenital aphakia. In all cases where PKP was performed the UBM diagnosis was confirmed histologically. The clinical diagnosis was incorrect in five cases. This has important implications in studies of phenotype/genotype correlation of congenital corneal opacification.

See end of article for authors' affiliations

Correspondence to:  
K K Nischal, Department of Ophthalmology, Great Ormond Street Hospital for Children, London WC1N 3JH, UK; kkn@btinternet.com

Accepted for publication 11 July 2001

High frequency ultrasound biomicroscopy (UBM) is well established as a useful tool for the examination of the anterior segment, especially in eyes with opaque corneas.<sup>1–3</sup> The prevalence of congenital corneal opacity is approximately 3/100 000 newborns and this figure increases to 6/100 000 newborns if congenital glaucoma is included.<sup>4</sup> To date there have been several single case reports of the use of UBM in the evaluation of corneal opacification.<sup>5–15</sup> Few have been about congenital corneal opacification<sup>6–12</sup> and the only one that included both UBM and histology of congenital corneal opacification<sup>8</sup> was in an adult.

We describe 13 cases of congenital corneal opacification which presented to the departments of ophthalmology, the Hospital for Sick Children, Toronto, and Great Ormond Street Hospital for Children, London, in whom clinical correlation was made with UBM findings and where possible histology. To our knowledge this is the largest such series reported to date.

## METHOD

The notes were reviewed of all cases of congenital corneal opacification presenting for the first time between December 1997 and October 1999. All cases had undergone a full clinical evaluation with or without examination under anaesthetic including anterior segment photography, high frequency UBM, and relevant serology and, in those cases where penetrating keratoplasty was performed, histopathology. In all cases a clinical diagnosis had been made before UBM was performed and then again after UBM was performed. The decision to proceed to penetrating keratoplasty was made by the principal surgeon in each centre (DSR, Toronto and KKN, London). The technique of penetrating keratoplasty was the same as that described by Ehrlich and colleagues in 1991.<sup>16</sup>

UBM was performed using the ultrasound biomicroscope (Allergan-Humphrey, San Leandro, CA, USA). Scans were performed in all cases except three, during examination under anaesthetic. A lid speculum was used to keep the eyelids open and Teargel or Viscotears (Ciba Vision) were used as the coupling agent between the transducer head and the patient's cornea. Scans were performed by two of the authors (LDM and KKN) using the same protocol. This protocol consisted of a minimum of four scans radial to the limbus and four scans parallel to the limbus at positions 12, 3, 6, and 9 o'clock. At least one scan axial to the estimated position of the pupil was also performed. Scan images were saved onto hard disc and hard copies were also made.

## RESULTS

In total, 13 cases were seen with a mean postnatal age of 32.1 days (range 3–225 days). Nine cases presented to the Hospital for Sick Children, Toronto, between December 1997 and March 1999, while four presented to Great Ormond Street Hospital for Children, London, between March 1999 and September 1999.

The clinical cases and results are summarised in Tables 1, 2, and 3.

## DISCUSSION

There have been four isolated reports of the UBM findings in sclerocornea and Peters' anomaly<sup>7 8 10 11</sup> and while one<sup>8</sup> had histology, it was in an adult. We have reported the UBM findings in 13 cases (22 eyes) of congenital corneal opacification, 12 of which presented within 3 weeks of birth. More importantly, we have correlated the UBM findings with the clinical features in all cases and the histological findings in

**Table 1** Clinical features

Case	Sex	Age at presentation	Clinical features	B/L or U/L	Systemic features	Clinical diagnosis
1 (KL)	F	3 days	Diffuse panstromal corneal clouding (see Fig 1)	B/L	Nil	Congenital glaucoma
2 (CC)	M	5 days	RE complete opaque cornea (see Fig 5)	U/L	CHARGE syndrome	Sclerocornea
3 (CC)		20 days	RE opaque enlarged cornea with stromal vascularisation ? Keratolenticular adhesion	U/L	Bilateral choanal atresia ASD, VSD, coarctation of aorta, micropenis	Peters' anomaly
4 (KP)	F	4 days	B/L dense central corneal opacities with peripheral irido-corneal adhesions	B/L	Orofacial digital syndrome Cleft lip and palate, brachycephaly, short femurs, brachydactyly, clinodactyly	Peters' anomaly
5 (MG)	M	4 days	B/L corneal opacification with a central area of relative ectasia posterior embryotoxon (see Fig 3)	B/L	Nil	Corneal ectasia
6 (SH)	F	7 days	LE central corneal opacity with irido-corneal touch	U/L	Nil	Peters' anomaly
7 (VCN)	M	7 days	B/L scleralised corneas temporally	B/L	Nil	Sclerocornea
8 (EF)	M	5 days	Opaque corneas HCD 11 mm R and 11.5 mm L	B/L	Nil	Congenital glaucoma
9 (NS)	M	7.5 months	B/L opaque corneas with evidence of scleralisation	B/L	Nil	Sclerocornea
10 (ET)	M	6 weeks	B/L diffuse opaque corneas with complete scleralisation RE and some sparing inferiorly LE	B/L	Nil	Sclerocornea
11 (TH)	M	5 months	B/L diffuse opaque corneas with microcornea and scleralisation	B/L	Intrauterine growth retardation, failure to thrive	Sclerocornea
12 (RM)	M	7 days	B/L corneal ring opacities with thinning centrally	B/L	Peters' plus syndrome	Peters' anomaly
13 (MR)	F	7 days	RE central corneal opacity LE Axenfeld anomaly but clear cornea (see Fig 4)	U/L	B/L cleft lip and palate, rhizomelia, clinodactyly, long philtrum	Peters' anomaly

HCD = horizontal corneal diameter, RE = right eye, LE = left eye, ASD = atrial septal defect, VSD = ventricular septal defect, U/L = unilateral, B/L = bilateral.

nine cases. The UBM findings changed the clinical diagnosis in five cases (see Table 3). Two cases of suspected congenital glaucoma (1 and 8) were thought to be cases of corneal dystrophies (posterior polymorphous dystrophy and congenital hereditary endothelial dystrophy) while two cases of suspected sclerocornea and the one case of corneal ectasia were found to be Peters' anomaly after UBM examination. The UBM findings in posterior polymorphous dystrophy and in congenital hereditary endothelial dystrophy have not previously been reported (see Table 2 and Fig 1). The final diagnosis in our series was Peters' anomaly in nine cases (70%), corneal dystrophy in two cases (15%), and sclerocornea in two cases (15%).

Ultrasound biomicroscopy (UBM) allows visualisation of the anterior segment to a depth of 5 mm with a resolution of approximately 50 µm<sup>1-3</sup> and gives excellent differentiation of ocular tissues because different tissues produce different amounts of beam backscatter.<sup>1</sup> Using an 80 MHz transducer Pavlin has demonstrated that UBM will differentiate corneal epithelium, Bowman's membrane and stroma but not between Descemet's membrane and the endothelial layer.<sup>1,2</sup> In our study, using a 50 MHz transducer which is the commonest commercially available UBM, the corneal epithelium and Bowman's layer appear as a single hyperechoic layer. In order to record corneal epithelium and Bowman's layer as two separate layers the transducer must be exactly perpendicular to the corneal surface and the gain must be low. Since the intracorneal structures were not the focus of our examination we did not stringently try to meet these criteria which may explain the discrepancy between our findings and those of Pavlin.<sup>1,2</sup> Beneath the corneal epithelium/Bowman complex we found the relatively hypoechoic but heterogeneous stroma and finally Descemet's membrane (DM) and endothelial layer again as a single hyperechoic layer (see Fig 2).

In cases 1 and 8 the usually contiguous reflectivity of the DM/endothelium layer seen on UBM<sup>1</sup> was found to be irregular (Fig 1A) which was confirmed on histology to be due to focal absences of Descemet's membrane with multilayering of the endothelium case 1 (Fig 1B) and absences of endothelium in case 8; a feature not previously reported to our knowledge.

In seven cases (4-7, 10, 12, 13) where the normal hyperreflectivity of the DM/endothelium was not seen in association with a central posterior corneal defect (Fig 3B, 4A), absence of DM and endothelium was confirmed histologically where available (Fig 3C, 4B).

In four cases (4, 5, 7, 12) an unusual hypoechoic region was seen in the anterior stroma on UBM examination (Fig 3B, 4A). In all these four cases (eight eyes) histology revealed an absence of Bowman's layer with oedema in the region adjacent to where Bowman's layer should have been, together with absence of Descemet's membrane (Fig 3C, 4B). In case 9 Bowman's layer was also found to be histologically absent but no hypoechoic region was seen in the anterior stroma. One possible explanation may be that there was also vascularisation of the stroma and this case had presented after 7 months while all the other cases had presented within 2 weeks of birth.

In case 6 histology revealed a thickened Bowman's layer but there was no obvious UBM correlate. However, hyperplasia or thickened Bowman's layer has previously been described.<sup>17-19</sup>

In the only clinicopathological correlation to date of clinically diagnosed sclerocornea,<sup>8</sup> the authors described a flattened cornea, diffuse scleralisation of the cornea indicated by hyperreflectivity, abnormal Bowman's layer, thickening of the peripheral cornea, with central posterior excavations involving the posterior stroma, Descemet's membrane and endothelium. Histologically all the UBM findings were confirmed and in addition Bowman's layer was noted to be absent and replaced by a few irregular patches of hyaline material. It is noteworthy that despite the presence of a central posterior corneal defect both on UBM and histologically, a

**Table 2** UBM and histology features

Case	UBM method	Clinical features	UBM features	UBM Dx	PKP	Histological features	Histology Dx
1 (KL)	EUA	Normal IOP under GA	Normal anterior segments, irregular corneal thickness with abnormal echogenicity from DM and endothelium. At its greatest corneal thickness was 2.3 mm RE and 2.2 mm LE	Corneal dystrophy	B/L	BE: vacuolation of the basal epithelium with intact Bowman's layer. Focal absence of DM with multilayering of the endothelium confirmed on EM. Immunostain positive for cytokeratin in endothelium	Posterior polymorphous dystrophy
2 (CC)	Awake		Shallow anterior chamber with keratolenticular adhesion and abnormal thick zonules	Peters' anomaly	N/A	N/A	N/A
3 (CC)	EUA	Normal IOP	Shallow anterior chamber with keratolenticular adhesion with cataract and aniridia. Zonules enmeshed with stretched or elongated ciliary processes	Peters' anomaly	N/A	N/A	N/A
4 (KP)	EUA	No evidence of glaucoma	Iridocorneal adhesions with a central posterior corneal defect. Hypoechoic region in the anterior stroma, not able to be explained at time of UBM. Features common to both eyes	Peters' anomaly	B/L	LE: variable epithelial thickness with complete absence of Bowman's layer with anterior stromal oedema; complete absence of DM and endothelium RE: Vacuolation of basal epithelium with variable thickness and irregular arrangement of the stromal lamellae. Centrally deficient DM with endothelial attenuation.	B/L Peters' anomaly
5 (MG)	EUA	RE perforated and had emergency PKP	Only LE had UBM. Aniridia and central large posterior corneal defect in the region of which the hyperreflectivity of DM seen on UBM was absent. Ciliary processes appeared stretched. Hypoechoic region in anterior stroma similar to case 4.	Peters' anomaly	B/L	LE: oedema of the basal epithelium, absent Bowman's layer, and irregular alignment of the stromal lamellae. Centrally marked thinning of stroma with absence of DM and endothelium	Peters' anomaly – most likely B/L but right host tissue only showed necrosis as it had perforated awaiting PKP
6 (SH)	EUA	No evidence of glaucoma	Central iridocorneal adhesion. Normal hyperreflectivity of DM and endothelium not seen centrally but present peripherally	Peters' anomaly	U/L	LE: variable epithelial thickness, thickened Bowman's layer with focal absence centrally, marked stromal disorganisation and irregular stromal thickness with a central mound of tissue in posterior cornea, over which DM extremely attenuated and focally absent	Peters' anomaly
7 (VCN)	EUA		Iridocorneal adhesions mainly central but also some peripheral with shallow AC. Hyperreflectivity normally seen at level of DM/endothelium not seen centrally. Hypoechoic area in anterior stroma similar to that seen in cases 4 and 5.	B/L Peters' anomaly	B/L	RE: oedema of the basal epithelium with absence of Bowman's layer. Disorganised layering of the stroma and absence of endothelium and DM LE: epithelial oedema, absent Bowman's layer, disorganised stromal layering and attenuation of endothelium with absence of DM centrally	B/L Peters' anomaly
8 (EF)	EUA	IOP: Tonopen R=37 mm Hg L=65 mm Hg IOP: Perkins R=10 mm Hg L=10 mm Hg	No evidence of iridocorneal or keratolenticular adhesions or posterior corneal defects. Cornea thickened at 2.1 mm RE and 2.3 mm LE centrally. Normal hyperreflectivity of DM/endothelium stippled with discrete discontinuities	Corneal dystrophy	B/L	BE: oedema of basal epithelium and subepithelial bullae. Marked stromal scarring with irregular layering and severe endothelial attenuation with almost complete absence. Irregular fibrous thickening of Descemet's membrane, especially posterior part but complete in some areas.	B/L congenital hereditary Endothelial dystrophy
9 (NS)	EUA	No evidence of glaucoma	Formed anterior chambers with odd fragments of iris and aphakia. No evidence of posterior corneal defect	Aphakia	B/L	RE: flattened and attenuated epithelium with absent Bowman's layer. Stroma abnormally organised, thin and vascularised. DM and endothelium could not be identified due to presence of adherent iris LE: in addition to features above subepithelial calcification	Primary aphakia Disorganised ant. segment ? Sclerocornea
10 (ET)	EUA	No evidence of glaucoma	Shallow ACs with posterior corneal defects with no keratolenticular adhesion but some iridocorneal adhesions seen, centrally especially in right eye.	Peters' anomaly	LE: autorotational keratoplasty (elsewhere)	N/A	N/A
11 (TH)	EUA	No evidence of glaucoma	Formed ACs with no corneal defect or iridocorneal or keratolenticular adhesion	Sclero-cornea		N/A	N/A
12 (RM)	Awake		Central thinning of the posterior cornea with keratolenticular and iridocorneal adhesions	Peters' anomaly	B/L	BE: absence of DM, endothelium and posterior stroma centrally with absent Bowman's layer	Peters' anomaly
13 (MR)	Awake	IOP: Perkins while feeding R=26 mm Hg L=16 mm Hg	Peripheral iridocorneal adhesions. Centrally mild posterior corneal defect with corresponding defect in anterior capsule of lens	Peters' anomaly	U/L	RE: centrally focal absence of DM and endothelium	Peters' anomaly

Cases	Eyes	Clinical diagnosis	UBM diagnosis	Histological diagnosis
1 (KL)	B/L	Congenital glaucoma	Corneal dystrophy	Posterior polymorphous dystrophy
2 (CC)	U/L	Sclerocornea	Peters' anomaly	N/A
5 (MG)	B/L	Corneal ectasia	Peters' anomaly with aniridia	Peters' anomaly
7 (VCN)	B/L	Sclerocornea	Peters' anomaly	Peters' anomaly
8 (EF)	B/L	Congenital glaucoma	Corneal dystrophy	Congenital hereditary endothelial dystrophy

feature consistent with Peters' anomaly,<sup>17 20-29</sup> the authors failed to comment on this. Additionally no comment was made about the state of the anterior stroma on UBM<sup>8</sup> but if the UBM figure is perused in the report there is a clear area of

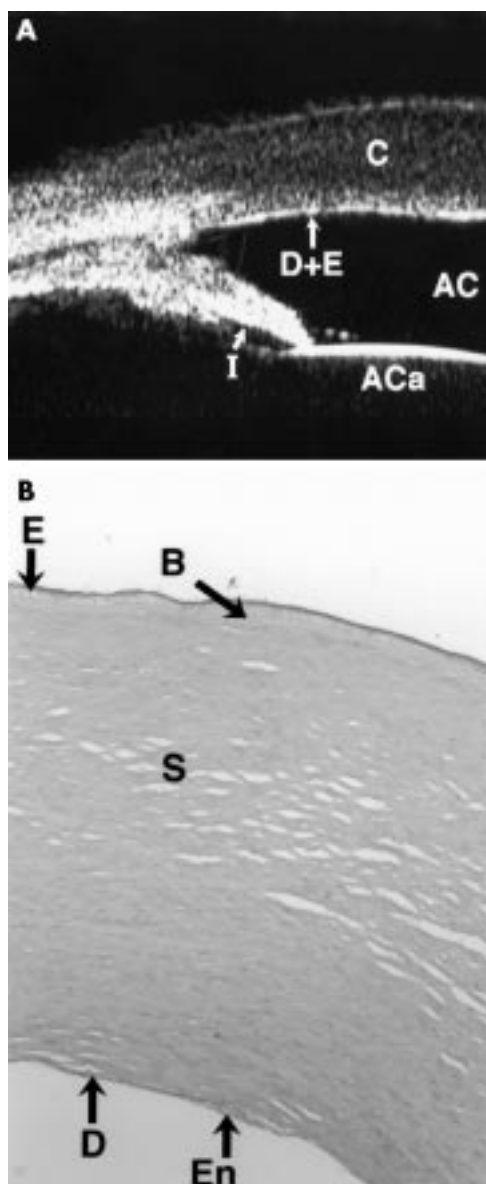
hypoechoogenicity in the anterior stroma; this is identical to our findings on UBM in cases 4, 5, 7, and 12. In this report Bowman's layer was reported to be absent also histologically.

We suggest that the presence of a hypoechoic layer in the anterior stroma just below the epithelial hyperechoic layer may be indicative of absent Bowman's layer with concomitant oedema as evidenced by the histology of our cases and that of the only other clinicopathological report.<sup>8</sup> To our knowledge, this has never been previously reported.

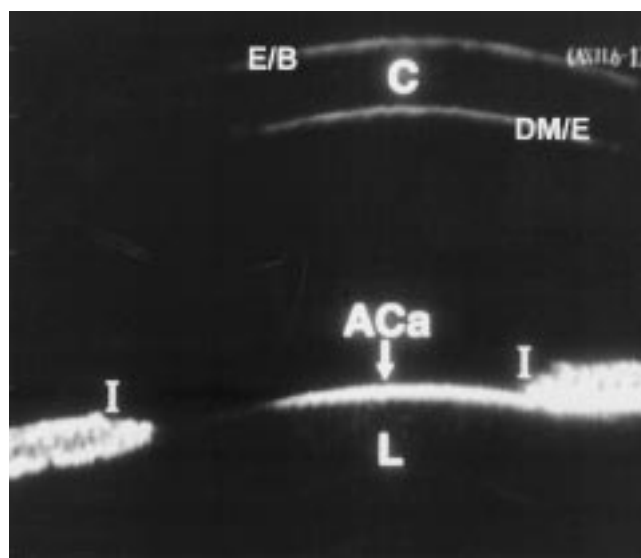
Avitabile *et al*<sup>5</sup> have studied *acquired* corneal oedemas using UBM; however, all of their studies were at least 30 days after the initial insult, at which stage the opacity of the cornea seen was most probably related to scarring rather than true acute corneal oedema. This would explain why they describe increased hyperreflectivity within the stroma.

The description of UBM in Peters' anomaly has been reported in three papers<sup>10 11 13</sup> but *none* had any correlation with histology. Azuara-Blanco *et al*<sup>13</sup> described three eyes of two patients who had had a clinical diagnosis of Peters' anomaly made without histological confirmation. Their UBM findings were similar to ours with the central posterior corneal defect described as an excavation. We agree with their description of central keratolenticular and iridocorneal adhesions as seen in cases 2, 3, 4, 6, 7, and 12 (Fig 5B). Although case 13 showed iridocorneal adhesions, these were peripheral.

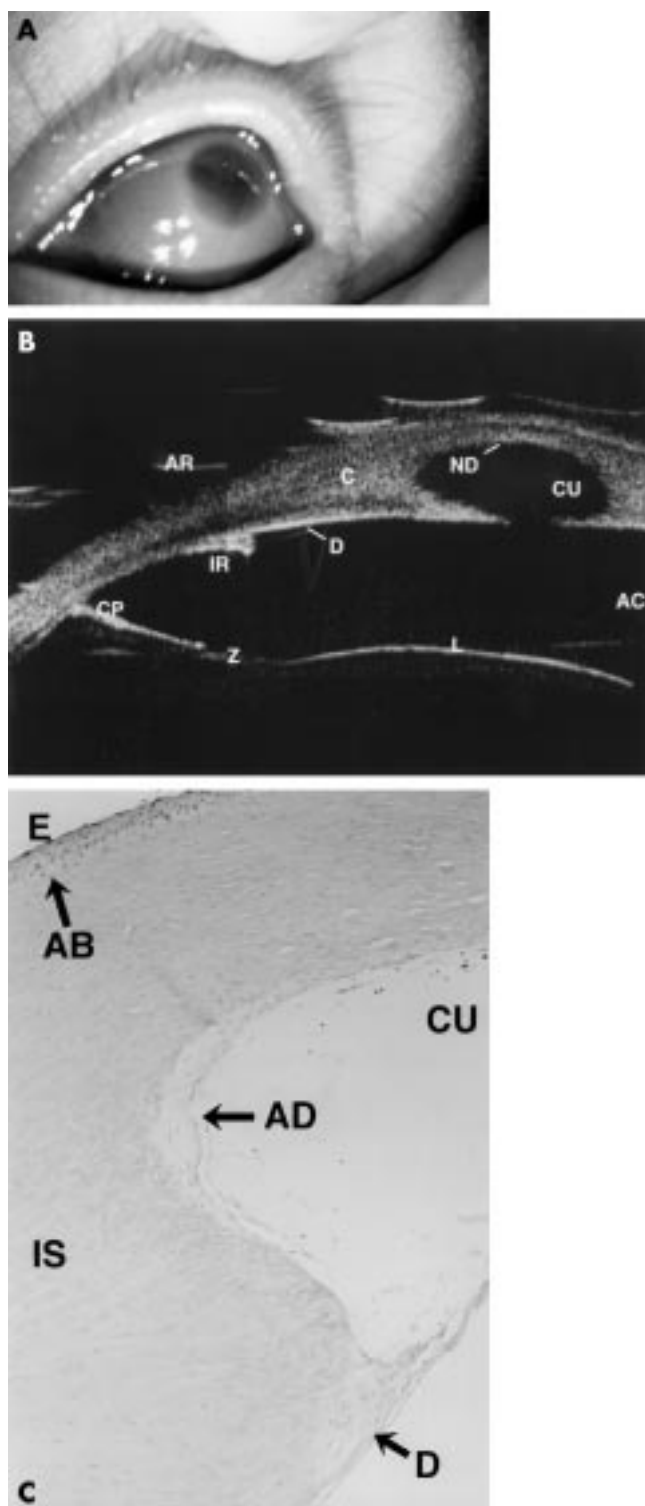
As early as 1867<sup>30</sup> the clinical condition of defect in Descemet's membrane giving rise to a central corneal opacification was attributed to defective separation of the lens from surface ectoderm. Peters<sup>31</sup> in 1906 emphasised this aetiology and in so doing gave the condition its eponymous name. There is a substantial volume of literature regarding the histology of Peters' anomaly<sup>20-29 32 33</sup> and less so for sclerocornea.<sup>26 34</sup> Regardless of the author, the hallmark of Peters' anomaly histologically is the central deficiency of the posterior stroma,



**Figure 1** (A) The UBM of case 1 shows irregular thickness of the cornea (C) and focal anomalies in the Descemet's membrane and endothelial echo (D+E) (compare with Fig 2). The pupil is dilated, and so the iris appears shorter than normal (I). The anterior chamber (AC) and the anterior capsule of the lens are also seen. The corneal thickness for the right eye was 2.3 mm centrally and 2.2 mm for the left eye centrally. A diagnosis of corneal dystrophy was made, which was confirmed histologically as being posterior polymorphous dystrophy. (B) Full thickness (x10) cornea section is shown with periodic acid Schiff (PAS) stain. There is normal epithelium (E) and Bowman's layer (B) but the Descemet's membrane (DM) is abnormally thin with multilayering of the endothelium seen (En).

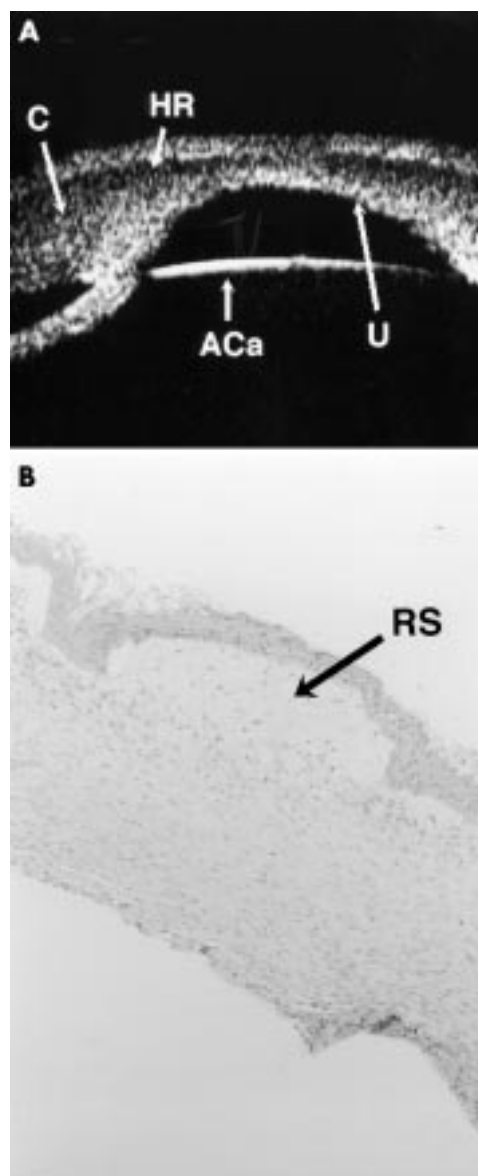


**Figure 2** UBM of a normal age-matched eye. The echogenicity from the epithelial/Bowman's layer complex (E/B), cornea (C), Descemet's membrane/endothelial complex (DM/E), anterior capsule of the lens (ACa), lens (L), and iris (I) is shown.



**Figure 3** Clinical, UBM, and histological findings in case 5. (A) Shows the corneal opacity with relative clearing centrally. (B) A composite of two UBM scans showing aniridia with an iris stump (IR), stretched ciliary processes (CP), zonules (Z), the lens (L), intact Descemet's membrane/endothelial echo (D), central defect in posterior cornea (CU), and loss of the Descemet's membrane/endothelial echo within the defect (ND). AR = artefact. C = cornea. AC = anterior chamber. (C) ( $\times 10$ ) Periodic acid Schiff (PAS) stain section of cornea is shown. This demonstrates the central defect (CU) with absent Descemet's membrane and endothelium (AD), but a thin Descemet's membrane is seen peripherally (D). Bowman's layer is absent (AB) and stromal lamellae are irregular (IS). E = epithelium. The relative clarity centrally seen in (A) is due to the gross central defect.

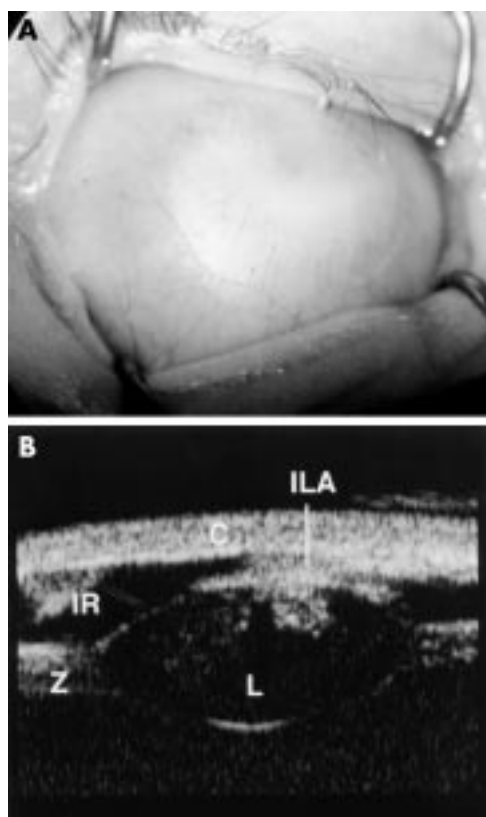
Descemet's membrane, and endothelium with or without keratolenticular and/or iridocorneal adhesions<sup>17 20-29</sup> with a



**Figure 4** UBM scans and histology of case 4. (A) Shows the cornea (C), with a hypoechoic region (HR) in the anterior stroma with a central defect in the posterior aspect of the cornea (U). The anterior capsule of the lens is seen (ACa) as a central iridocorneal adhesion. (B) Full thickness corneal section (haematoxylin and eosin stain) shows absence of Bowman's layer with marked rarefaction of the subepithelial stroma (RS), which corresponds to the hypoechoic layer seen on UBM. There is absence of Descemet's membrane and endothelium. All these histological features are consistent with a diagnosis of Peters' anomaly.

corresponding central corneal opacity clinically. Interestingly, absence of Bowman's membrane is also alluded to in a number of reports<sup>21 22 34-37</sup> but some of these reports clinically describe sclerocornea with a rudimentary presence of DM.<sup>34 36</sup>

In sclerocornea there is extension of opaque scleral tissue and fine vascular conjunctival and episcleral tissue into the peripheral cornea obscuring the limbus.<sup>26</sup> The severity of scleralisation varies from mild to complete but is usually bilateral in 90% of cases.<sup>26 38-40</sup> Histologically the corneal epithelium shows secondary changes with Bowman's layer absent in the affected areas<sup>26 34</sup> with interstitial vascularisation without inflammation and the stromal collagen fibrils are comparable to scleral collagen in size and organisation. There may be irregular absence of both endothelium and Descemet's membrane or an abnormally thinned Descemet's membrane composed of multilaminar basement membrane.<sup>26 34</sup>



**Figure 5** Clinical and UBM findings in case 2. (A) Shows complete corneal opacification thought clinically to be sclerocornea. (B) The UBM of the same case shows keratolenticular adhesion (ILA), aniridia with only an iris stump detected (IR), a small lens (L), and thickened looking zonules (Z). The cornea is also seen (C). The diagnosis post UBM was thought to be Peters' anomaly given the keratolenticular adhesion. Case 2 did not have penetrating keratoplasty performed.

It appears that Peters' anomaly and sclerocornea are most likely conditions in the same spectrum of anterior segment dysgenesis.

UBM was useful in evaluating both the cornea itself as shown above and very useful in revealing associated ocular anomalies as demonstrated most clearly by cases 5, 9, and 13.

In case 9 no evidence of a lens could be found either on UBM or posterior segment ultrasound and we feel confident that this is bilateral primary congenital aphakia. Congenital aphakia is extremely rare<sup>41-44</sup> and when associated with Peters' anomaly even rarer.<sup>41-42</sup> Controversy exists as to whether primary aphakia (failure of any lens formation as opposed to secondary type where lens forms but subsequently is resorbed) can occur with an otherwise normal anterior segment or not.<sup>43-46</sup> Clinically, sclerocornea precluded a thorough examination of the anterior segment, which could only be done using the UBM and this revealed the absence of a lens and aniridia bilaterally (Table 2). This is the first reported case of congenital aphakia in association with clinically diagnosed sclerocornea to our knowledge.

Case 13 demonstrated the presence of Axenfeld-Rieger anomaly with Peters' anomaly. The scarcity of previous reports may be due to the fact that young infants are difficult to examine and gonioscopy to look for the iridocorneal adhesions is particularly difficult if the only such findings are in the affected eye with the corneal opacification.<sup>17-20, 42, 47-49</sup> The use of UBM demonstrated the peripheral iridocorneal adhesions very clearly in our case although the fellow eye also demonstrated Axenfeld-Rieger anomaly very clearly.

Both cases 5 and 9 demonstrated the presence of aniridia which was not readily obvious prior to UBM because of the corneal opacity. Cases of aniridia and Peter's anomaly have

been previously been reported<sup>35-50</sup> and so has one case of Peters' anomaly with Wilm's tumour.<sup>51</sup> The iris in this latter report was described as being very hypoplastic.<sup>51</sup>

At least three developmental genes, PAX 6, REIG 1, and PITX 3, are involved in the development of the anterior segment of the eye.<sup>52-53</sup> There has been much investigation into the genetics of Peters' anomaly<sup>48</sup> with controversy over the role of PAX 6.<sup>52-54, 56-57</sup> PAX 6 (OMIM 106210) is a homeobox gene responsible for the control of ocular embryogenesis.<sup>52-53, 58</sup> Mutations in PAX 6 are responsible for human aniridia and it has been suggested that no locus other than chromosome 11p13 has been implicated in aniridia and that PAX 6 may be the only gene responsible.<sup>57</sup>

Doward *et al* have reported a case of Peters' anomaly in which a mutation of REIG 1 gene was found.<sup>48</sup> Mutations in the REIG 1 homeobox gene (OMIM 180500) on chromosome 4q25 have been reported in association with Rieger syndrome.<sup>48</sup> A mutation in the PITX 3 gene (OMIM 602669) on chromosome 10 has been associated with autosomal dominant Peters' anomaly, congenital cataract and other anterior segment malformations.<sup>59</sup>

We believe that the accurate description of the phenotype of congenital corneal opacification is crucial in the evolution of phenotype-genotype correlation. In our series three of five cases clinically diagnosed as sclerocornea were found on UBM and, in some cases, histologically to have Peters' anomaly. This suggests that the clinical definition of phenotype in such cases is unreliable and the water is further muddied by the fact that sclerocornea and Peters' anomaly appear to be conditions whose histological features overlap suggesting they are part of the same spectrum of disease.<sup>17-20, 29, 32-36</sup> In a series of articles in 1974 Townsend *et al*<sup>17, 20, 24</sup> tried to move away from the eponymous designations for developmental congenital corneal opacifications classifying them histologically according to the position and presence of defects in DM.

Whether the absence of Bowman's layer in cases of sclerocornea and Peters' anomaly<sup>21, 22, 34-37</sup> is a primary event or secondary to an absent Descemet's membrane and endothelium, is unclear. If it were a primary event then elucidating a genetic association would be significant. The embryogenesis of Bowman's layer occurs late (4-5 months). It is thought to be produced by both the epithelium and the anterior stroma.<sup>18</sup> If the lens is removed in the chick embryo on day 3 of gestation there is a resultant failure of the corneal stroma, DM and endothelium to develop and a greatly decreased density of Bowman's layer.<sup>18</sup> Other authors have suggested that in Peters' anomaly the epithelium may be abnormal with an absent Bowman's layer.<sup>22</sup> The central posterior defect of the cornea seen in Peters' anomaly may be as a result of failure of lens separation or due to apposition of the lens to the cornea.<sup>17, 20, 24, 26</sup> Townsend has suggested that the posterior defect could be a passive effect of pressure by a forwardly displaced lens against the cornea at a time in development when the DM was absent or still a delicate structure.<sup>17</sup> This suggests that the central corneal opacity of Peters' anomaly could be the final pathway for a number of varied pathologies, much like pulmonary fibrosis is the final pathway for conditions as varied as sarcoid, TB and cystic fibrosis.

Under these circumstances any phenotype-genotype correlation must be undertaken only with the most accurate phenotypic description available. We suggest that in the absence of histological diagnosis, the use of high frequency ultrasound should be mandatory in the description of phenotype where the anterior segment cannot be visualised. It is reasonable to suggest that the presence of Peters' anomaly with aniridia is most likely associated with a PAX 6 mutation according to Prosser and van Heyningen<sup>56</sup> while Peters' anomaly with Axenfeld-Rieger anomaly may be associated with RIEG 1 mutations.

We performed penetrating keratoplasty in nine cases (16 eyes) and one case had autologous rotational keratoplasty

elsewhere. Penetrating keratoplasty for such cases is well described,<sup>16 37 60-69</sup> while there are fewer reports of optical iridectomy and rotational keratoplasty.<sup>70 71</sup> It is noteworthy that one group of authors<sup>37</sup> named absence of Bowman's layer and, separately, absence of DM histologically as poor prognosticators; our UBM findings suggest that both these features could be determined preoperatively, thus giving the parents more information before consenting to surgical intervention. Furthermore, other authors<sup>65</sup> make the point that in most cases of Peters' anomaly the clinician has difficulty detecting keratolenticular adhesions hidden behind the dense corneal opacity and that for proper graft centration and wound entry site retroillumination must be employed.<sup>60</sup> By using UBM all surgical planning can be done before the eye is opened.

In summary then we have described the first series of clinico-ultrasonico-pathological descriptions of congenital corneal opacification. We have demonstrated that the clinical description of phenotype may be unreliable, by showing that the clinical diagnosis was changed in five out of 13 cases (38%) by the UBM findings and that in every case but one the UBM finding was confirmed histologically.

In so doing we have described a new sign in high frequency ultrasound of hypoechogenicity of the anterior stroma (subepithelium) which has been shown histologically to be due to absent Bowman's layer with associated oedema. It is necessary to emphasise that sclerocornea and Peters' anomaly are part of the same spectrum of pathology. The importance of preoperative assessment and diagnosis in cases of corneal opacity cannot be overstated and is easily undertaken with UBM even in the awake infant.

Finally, in the present climate of increasing emphasis on studies of phenotype-genotype correlation we feel we have shown that UBM examination is an invaluable adjunct in accurately defining the phenotype.

#### Authors' affiliations

**K K Nischal**, Department of Ophthalmology, Great Ormond Street Hospital for Children NHS Trust, London, and The Institute of Child Health, London UK

**J Naor, D S Rootman**, Department of Ophthalmology, Toronto General Hospital, University of Toronto, Toronto, Canada

**V Jay**, Department of Pathology, The Hospital for Sick Children, Toronto

**L D MacKeen, D S Rootman**, Department of Ophthalmology, Hospital for Sick Children, Toronto, Canada

#### REFERENCES

- Pavlin CJ, Sherar MD, Foster S. Subsurface ultrasound microscopic imaging of the intact eye. *Ophthalmology* 1990;**97**:244-50.
- Pavlin CJ, Harasiewicz K, Sherar MD, et al. Clinical use of ultrasound biomicroscopy. *Ophthalmology* 1991;**98**:287-95.
- Pavlin CJ. Interpreting technology; practical application of ultrasound biomicroscopy. *Canad J Ophthalmol* 1995;**30**:225-9.
- Bermejo E, Martinez-Frias ML. Congenital eye malformations: clinical epidemiological analysis of 1,124,654 consecutive births in Spain. *Am J Med Genet* 1998;**75**:497-504.
- Avitabile T, Russo V, Ghirlanda R, et al. Corneal oedemas: diagnosis and surgical planning with ultrasound biomicroscopy. *Ophthalmologica* 1998;**212**(Suppl 1):13-16.
- Kiryu J, Park M, Kobayashi H, et al. Ultrasound biomicroscopy of the anterior segment of the eyes of infants. *J Pediatr Ophthalmol Strabismus* 1998;**35**:320-2.
- Park M, Kiryu J, Kurimoto Y, et al. Ultrasound biomicroscopic observation of the anterior eye segment in a sclerocornea and a microcornea. *J Jap Ophthalmol Soc* 1997;**101**:69-73.
- Kim T, Cohen EJ, Schnall BM, et al. Ultrasound biomicroscopy and histopathology of sclerocornea. *Cornea* 1998;**17**:443-5.
- Funaki H, Shirakashi M, Fukuchi T, et al. A case of Peters' anomaly complicated by Axenfeld's anomaly. *Folia Ophthalmol Jap* 1996;**47**:322-5.
- Haddad AM, Greenfield DS, Stegman Z, et al. Peters' anomaly: Diagnosis by ultrasound biomicroscopy. *Ophthalmic Surg Lasers* 1997;**28**:311-12.
- Bessho K, Sawada A, Yamamoto T, et al. A case of Peters' anomaly observed by ultrasound biomicroscopy. *Jap J Clin Ophthalmol* 1998;**52**:215-18.
- Katsushima H, Maruyama I, Endo H, et al. Ultrasound biomicroscopy in a case of congenital anterior staphyloma. *Folia Ophthalmol Jap* 1997;**48**:366-70.
- Burger JJ, Katz LJ, Calhoun JH, et al. Ultrasound biomicroscopy in infantile glaucoma. *Ophthalmology* 1997;**104**:1116-19.
- Fries U, Muller HM, Heider W. Imaging (resolution and quantification) of corneal findings with ultrasound biomicroscopy. *Ophthalmologie* 1996;**93**:257-61.
- Kobayashi H, Kiryu J, Kobayashi K, et al. Ultrasound biomicroscopic measurement of anterior chamber angle in premature infants. *Br J Ophthalmol* 1997;**81**:460-4.
- Erllich CM, Rootman DS, Morin JD. Corneal transplantation in infants, children and young adults: experience of the Toronto Hospital for Sick Children, 1979-88. *Canad J Ophthalmol* 1991;**26**:206-10.
- Townsend WM, Font RL, Zimmerman LE. Congenital corneal leukomas. 2. Histopathologic findings in 19 eyes with central defect in Descemet's membrane. *Am J Ophthalmol* 1974;**77**:192-206.
- Apple DJ, Olson RJ, Jones GR, et al. Congenital corneal opacification secondary to Bowman's layer dysgenesis. *Am J Ophthalmol* 1984;**98**:320-8.
- Ohrloff C, Olson R, Apple D, et al. Congenital corneal opacity caused by hyperplasia of Bowman's membrane. *Fortschr Ophthalmol* 1984;**31**:429-32.
- Townsend WM. Congenital corneal leukomas. I Central defect in Descemet's membrane. *Am J Ophthalmol* 1974;**77**:80-6.
- Stone DL, Kenyon KR, Green WR, et al. Congenital central corneal leukoma (Peters' anomaly). *Am J Ophthalmol* 1976;**81**:173-93.
- Polack FM, Graue EL. Scanning electron microscopy of congenital corneal leukomas (Peters' anomaly). *Am J Ophthalmol* 1979;**88**:169-78.
- Nakanishi I, Brown SI. The histopathology and ultrastructure of congenital, central corneal opacity. *Am J Ophthalmol* 1971;**72**:801-12.
- Townsend WM, Font RL, Zimmerman LE. Congenital corneal leukomas. 3. Histopathologic findings in 13 eyes with noncentral defect in Descemet's membrane. *Am J Ophthalmol* 1974;**77**:400-12.
- Kupfer C, Kuwabara T, Stark WJ. The histopathology of Peters' anomaly. *Am J Ophthalmol* 1975;**80**:653-60.
- Kenyon KR. Mesenchymal dysgenesis in Peters' anomaly, sclerocornea and congenital endothelial dystrophy. *Exp Eye Res* 1975;**21**:125-42.
- Myles WM, Flanders ME, Chitayat D, et al. Peters' anomaly: a clinicopathologic study. *J Pediatr Ophthalmol Strabismus* 1992;**29**:374-81.
- Eggink CA, Mooy CM, Pinckers A. Peters' anomaly: an unusual case. *Ophthalmic Paediatr Genet* 1991;**12**:19-22.
- Offret H, Saraux H, Pouliquen Y, et al. Congenital leukomas with anomalies of the lens migration. *J Fr Ophthalmol* 1978;**1**:517-27.
- Steffan P. Beitrag zur Erklarung angeborener anomalien der Hornhaut. *Klin Monatsbl Augenheilkd* 1867;**5**:209.
- Peters A. Ueber angeborene Defektbildung der Descemetischen Membran. *Klin Monatsbl Augenheilkd* 1906;**44**:27-105.
- Wertelecki W, Dev VG, Superneau DW. Abnormal centromere-chromatid apposition (ACCA) and Peters' anomaly. *Ophthalmic Paediatr Genet* 1985;**6**:247-55.
- Johnson BL, Brown SI. Congenital epithelialisation of the posterior cornea. *Am J Ophthalmol* 1976;**82**:83-9.
- Petroutsos G, Patey A, Savoldelli M, et al. Ultrastructural and morphologic study. *J Fr Ophthalmol* 1983;**6**:769-75.
- Zaidman GW, Juechter K. Peters' anomaly associated with protruding corneal pseudo staphyloma. *Cornea* 1998;**17**:163-8.
- Redbrake C, Salla S, Becker J, et al. A rare case of bilateral congenital corneal malformations. *Acta Ophthalmol* 1993;**71**:256-61.
- Kampik A, Lund OE, Halbig W. Penetrating keratoplasty in congenital corneal opacities. *Klin Monatsbl Augenheilkd* 1986;**188**:188-92.
- Stanley JA. Congenital anomalies of the peripheral cornea. *Int Ophthalmol Clin* 1986;**26**:15-28.
- Eriksson AW, Lehmann W, Forsius J. Congenital cornea plana in Finland. *Clin Genet* 1973;**4**:301-10.
- Bloch N. The different types of sclerocornea, their hereditary modes and concomitant congenital malformations. *J Genet Hum* 1965;**14**:133-72.
- Trabucchi G, Piantanida A, Bandello F, et al. Congenital aphakia in Peters' anomaly syndrome; a case report. *Acta Ophthalmol Scand* 1997;**75**:595-7.
- Harris R, Brownstein S, Little JM. Peters' anomaly with congenital aphakia. *Canad J Ophthalmol* 1980;**15**:91-4.
- Johnson BL, Cheng KP. Congenital aphakia: a clinicopathologic report of three cases. *J Pediatr Ophthalmol Strabismus* 1997;**34**:35-9.
- Manschot WA. Primary congenital aphakia. *Arch Ophthalmol* 1963;**69**:71-7.
- Vermeij-Keers C. Primary congenital aphakia and the rubella syndrome. *Teratology* 1975;**11**:257-66.
- Hartwig NG, Vermeij-Keers C, Versteeg J. The anterior eye segment in virus induced primary congenital aphakia. *Acta Morphol Neerl-Scand* 1988/**9**;26:283-92.
- Saitoh A, Ohira A, Amemiya T. Peters' anomaly in an infant with a mild degree of Axenfeld's anomaly. *Br J Ophthalmol* 1995;**79**:862-3.
- Doward W, Perveen R, Lloyd IC, et al. A mutation in the RIEG1 gene associated with Peters' anomaly. *J Med Genet* 1999;**36**:152-5.
- Awan KJ. Peters-Rieger's syndrome. *J Pediatr Ophthalmol* 1977;**14**:112-6.
- Koster R, van Balen AT. Congenital corneal opacity (Peters' anomaly) combined with buphthalmos and aniridia. *Ophthalmic Paediatr Genet* 1985;**6**:241-6.

- 51 **Eiferman RA**. Association of Wilm's tumour with Peters' anomaly. *Ann Ophthalmol* 1984;**9**:33–4.
- 52 **Withers SJ**, Gole GA, Summers KM. Autosomal dominant cataracts and Peters anomaly in a large Australian family. *Clin Genet* 1999;**55**:240–7.
- 53 **Oliver G**, Gruss P. Current views on eye development. *Trends Neurosci* 1997;**20**:415–21.
- 54 **Azuma N**, Yamada M. Missense mutation at the C terminus of the PAX 6 gene in ocular anterior segment anomalies. *Invest Ophthalmol Vis Sci* 1998;**59**:828–30.
- 55 **Churchill AJ**, Booth AP, Anwar R, *et al*. PAX 6 is normal in most cases of Peters' anomaly. *Eye* 1998;**12**(Pt 2):299–303.
- 56 **Prosser J**, van Heyningen V. PAX6 mutations reviewed. *Hum Mut* 1998;**11**:93–108.
- 57 **Churchill A**, Booth A. Genetics of aniridia and anterior segment dysgenesis. *Br J Ophthalmol* 1996;**80**:669–73.
- 58 **Hanson IM**, Fletcher JM, Jordan T, *et al*. Mutations at the PAX6 locus are found in heterogeneous anterior segment malformations including Peters' anomaly. *Nat Genet* 1994;**6**:168–73.
- 59 **Semina EV**, Ferrell RE, Mintz-Hittner HA, *et al*. A novel Homeobox gene PITX3 is mutated in families with autosomal dominant cataracts and ASMD. *Nat Genet* 1998;**9**:167–70.
- 60 **Frueh BE**, Brown SI. Transplantation of congenitally opaque corneas. *Br J Ophthalmol* 1997;**81**:1064–9.
- 61 **Dana MR**, Moyes AL, Gomes JA, *et al*. The indications for and outcome in pediatric keratoplasty. A multicenter study. *Ophthalmology* 1995;**102**:1129–38.
- 62 **Cowden JW**. Penetrating keratoplasty in infants and children. *Ophthalmology* 1990;**97**:324–9.
- 63 **Frucht-Pery J**, Chayet AS, Feldman ST, *et al*. The effect of corneal grafting on vision in bilateral amblyopia. *Acta Ophthalmol (Suppl)* 1989;**192**:20–3.
- 64 **Brown SI**, Salamon SM. Wound healing of grafts in congenitally opaque infant corneas. *Am J Ophthalmol* 1983;**95**:641–4.
- 65 **Waring GO III**, Parks MM. Successful lens removal in congenital corneolenticular adhesion (Peters' anomaly). *Am J Ophthalmol* 1977;**83**:526–9.
- 66 **Waring GO 3d**, Laibson PR. Keratoplasty in infants and children. *Trans Am Acad Ophthalmol Otolaryngol* 1977;**83**:283–96.
- 67 **Hertle RW**, Orlin SE. Successful visual rehabilitation after neonatal penetrating keratoplasty. *Br J Ophthalmol* 1997;**81**:644–8.
- 68 **Cameron JA**. Good visual result following early penetrating keratoplasty for Peters' anomaly. *J Pediatr Ophthalmol Strabismus* 1993;**30**:109–12.
- 69 **Joseph A**, Fernandez ST, Ittyerah TP, *et al*. Keratoplasty in congenital corneal opacity. *Ind J Ophthalmol* 1980;**28**:79–80.
- 70 **Zaidman GW**, Rabinowitz Y, Forstot SL. Optical iridectomy for corneal opacities in Peters' anomaly. *J Cataract Refract Surg* 1998;**5**:719–22.
- 71 **Naumann GO**, Volcker HE, Gackle D. Ipsilateral rotational autokeratoplasty. *Klin Monatsbl Augenheilkd* 1977;**170**:488–93.

Want full access but don't  
have a subscription?

Pay per access

For just US\$25 you can have instant access to the whole website for 30 days. During this time you will be able to access the full text for all issues (including supplements) available. You will also be able to download and print any relevant pdf files for personal use, and take advantage of all the special features *British Journal of Ophthalmology* online has to offer.

[www.bjophthalmol.com](http://www.bjophthalmol.com)