

Debate

CONTROVERSIES IN OPHTHALMOLOGY

Repair of the lax medial canthal tendon

Series editors:
Susan Lightman
and Peter
McCluskey

B A O'Donnell, R L Anderson, J R O Collin, R G Fante, D R Jordan,
P Ritleng

Medial canthal tendon (MCT) laxity is a common condition, usually age related and often causing symptoms of epiphora, discharge, irritation, and redness. MCT repair is more complicated than that of its lateral counterpart because of the intimate relation with the canaliculus (Fig 1). The position and patency of the canaliculus can be affected by any surgery to the canaliculus. Because of the problems with surgical repair, surgery is often delayed until the MCT laxity is advanced (Fig 2)

For this clinical controversy, a panel of five eyelid surgeons was invited from Canada, England, France, and the United States to give their management for the symptomatic patient with MCT laxity and their surgical techniques according to the degree of laxity (Table 1).

Opinion: Richard Anderson

The lateral canthal tendon (LCT) is much weaker than the MCT and most cases of lid laxity involve the LCT more than the MCT. Therefore, most cases of lid laxity are best corrected with the lateral tarsal strip (LTS) procedure (Fig 3).^{1,2} I grade MCT laxity with the amount of lateral displacement of the punctum—that is, as mild with minimal displacement, moderate with several millimetres, or severe with displacement to the medial limbus. With mild to moderate medial ectropion or punctal eversion, I combine the LTS with a medial spindle procedure³ behind the punctum which tightens the conjunctiva and lower lid retractor to roll in the eyelid margin. I only repair the MCT if severe medial ectropion is present or lateral tendon tightening would displace the punctum too far laterally creating cosmetic or functional deformity.

For moderate to severe amounts of MCT laxity I prefer a posterior limb plication. I make a small incision behind the caruncle and an incision

Table 1 Questions regarding the lax MCT

- How much MCT laxity is required before you will repair the MCT?
- Does your decision to repair the MCT vary if the patient presents with epiphora?
- What is your preferred method of MCT repair? Do you tighten the anterior limb, posterior limb or both? What type of suture and needle, etc, are used? Do you cut/shorten the elastic canaliculus? If so, do you intubate?
- What is your management in severe cases with such gross MCT laxity that the whole inner canthus complex (including caruncle and upper and lower MCT) is distractable laterally?

below the canaliculus. I then tuck or tighten the medial canthus by securing a suture through the periosteum and posterior limb of the MCT and the medial edge of tarsus or epitarsal tissue inferior to the canaliculus. Unfortunately, any type of MCT plication involves folding or bunching of the canaliculus which may make it non functional. The suture that I prefer for canthal tendon repairs is 4/0 Vicryl (polygalactin 910, Ethicon, Somerville, NJ 08876-0151, USA) on a P2 needle (Ethicon).

Over the years I have found that the only good procedure to reposition a severely displaced or scarred medial canthus is the medial tarsal strip procedure (Fig 4).⁴ This allows for a strong fixation to periosteum resulting in a permanent repair but always requires cutting the canaliculus. I perform that procedure in cases where I feel the patient will not suffer or, in fact, may benefit from the canaliculus being obstructed.

In cases where I think tearing will be a problem, I try procedures which avoid cutting the canaliculus.

Correspondence to:
Dr Brett O'Donnell, Level 2,
Suite 3, 66 Pacific
Highway, St Leonards
2065, NSW, Australia;
brett.odonnell@island.net.au

Accepted for publication
18 September 2002

B A O'Donnell

Department of
Ophthalmology, Royal
North Shore Hospital,
Sydney 2065, Australia

R L Anderson Department of
Orbital and Ophthalmic
Plastic Surgery, John A
Moran Eye Centre,
University of Utah, 1002
East South Temple, Salt
Lake City, UT 84102, USA

J R O Collin Moorfields
Eye Hospital, City Road,
London EC1V 2 PD, UK

R G Fante Advanced
Oculoplastic Surgeons,
2005 Franklin Street, Suite
2-610, Denver, CO
80205, USA

D R Jordan The Doctors'
Building, Suite 104, 340
McLeod Street, Ottawa,
Ontario K2P 1A4, Canada

P Ritleng 10 rue du
Congrès, 06000 Nice,
France

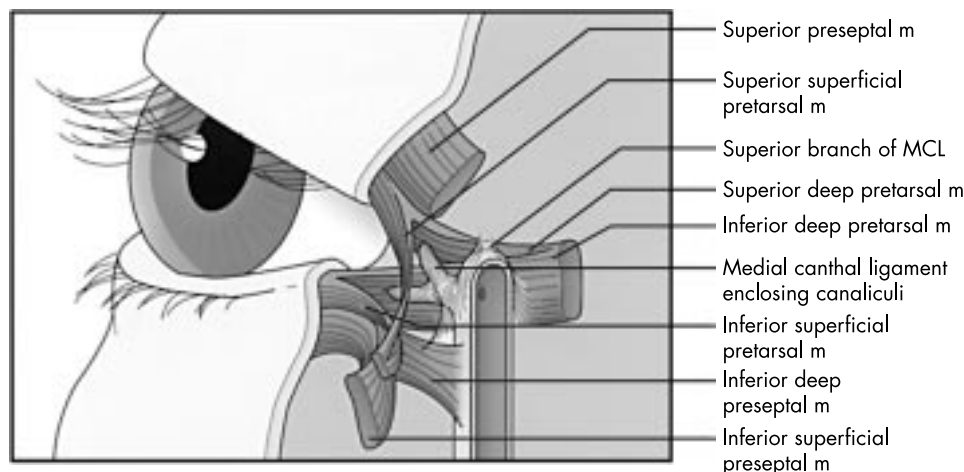


Figure 1 Anatomy of medial canthal tendon.

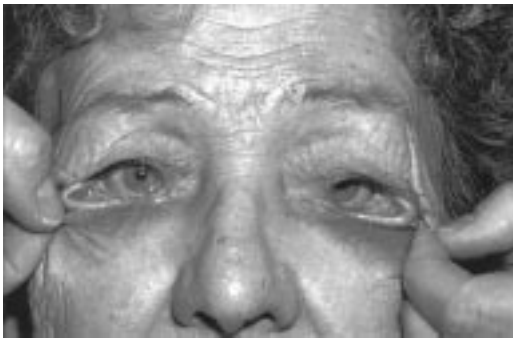


Figure 2 Severe MCT laxity.

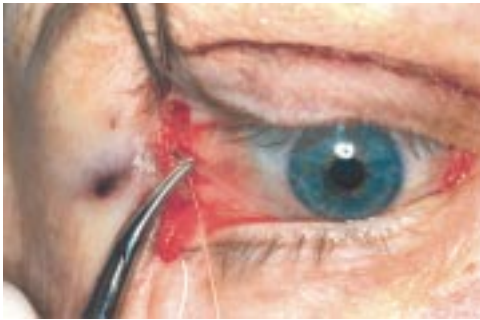

Figure 3 Lateral tarsal strip.

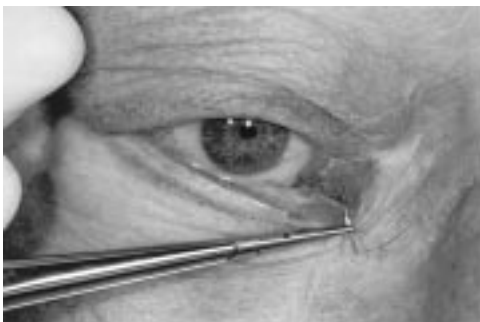

Figure 4 Medial tarsal strip.

Unfortunately, tightening or tucking the anterior limb of the MCT in involutional ectropion usually moves the eyelid anteriorly and away from the globe. I only tuck or tighten the anterior limb of the MCT when it has been anatomically disrupted as with injuries or in congenital anomalies (that is, blepharophimosis) where there is an elongated anterior limb of the MCT. Scar tissue in trauma cases and excess and fibrotic tissues in blepharophimosis cases must be excised before MCT tightening, tucking, or repositioning.

This type of condition usually only occurs following trauma or in congenital deformities such as blepharophimosis.⁵ In the rare cases of extreme involutional laxity, I make a horizontal incision over the lax MCT and either plicate the anterior limb of the MCT or cut and shorten the tendon leaving a stump at the periosteum for resuturing. In these cases either bony or periosteal fixation is required. I use a suture as above or rigid fixation with screws or wires to fixate the medial canthal tendon.

Opinion: Richard Collin

I will tighten the MCT in the symptomatic patient if the lid laxity allows the inferior lacrimal punc-

tum to be pulled over as far as, or further than, the medial corneal limbus.

If pulling the lid laterally does not allow the inferior lacrimal punctum to be pulled beyond a position midway between the superior lacrimal punctum and the medial corneal limbus, I would tighten the LCT and avoid medial canthal repair.

If the patient complained of epiphora and had an ectropion as well as MCT laxity I would want to repair the MCT with a milder degree of laxity.

If the MCT is moderately lax—that is, can be distracted to say halfway between the medial corneal limbus and the midline of the pupil, I prefer to plicate the posterior limb of the MCT with a direct suture.⁶ If the MCT laxity is more extensive than this I carry out a full thickness resection of the lid at the same time as repairing the posterior limb of the MCT under direct vision.^{6–8} If there is no tissue that will hold the suture in the region of the posterior lacrimal crest, I will consider providing a posterior fixation point either with a mini-plate, transnasal wire, Mitek screw, or if the lacrimal sac has been opened to perform a dacryocystorhinostomy, with a suture passed behind the lacrimal sac fascia.

I prefer to tighten the posterior limb as indicated above. I only tighten or repair the anterior limb⁶ if it has been injured or if the lid is going to be tightened laterally and doing so will pull the inferior lacrimal punctum to more than halfway between the superior lacrimal punctum and the medial corneal limbus—that is, I place an anterior limb medial canthal stabilising suture. I use a double armed 4/0 Prolene suture (Ethicon) with a large needle.

I only cut the canaliculus if I carry out a medial canthal resection. If I do this I marsupialise the cut inferior canaliculus and suture the open edges to the lid margin without intubation.

These patients may require a medial canthal resection as well as reformation of the posterior limb of the MCT as indicated above. If there is paralysis of the orbicularis muscle I will often, in addition, do a small Lee medial canthoplasty⁹ at the same time to support the medial end of the eyelid.

Opinion: Robert Fante

If the lower eyelid punctum is able to be distracted laterally 4 mm or less, LCT tightening is performed without addressing the MCT. For moderate MCT laxity measuring 5–6 mm, MCT tightening is generally performed only if there are other identified forces contributing to inferior eyelid displacement—for example, dermatochalasis or mild anterior lamella deficiency (that do not by themselves require additional procedures). For localised punctal ectropion with mild to moderate MCT laxity, a spindle repair of the retractors alone is sometimes adequate. For severe MCT laxity greater than 6 mm, MCT tightening is usually combined with LCT tightening.

Symptomatic epiphora with mild to moderate MCT laxity is usually successfully addressed with LCT tightening alone. For patients with epiphora and severe MCT laxity, it makes sense to attempt to improve lacrimal pump function while correcting the eyelid malposition, and I will then choose a procedure that shortens the flaccid canaliculus, restores normal punctal position, and shortens

Debate

Debate

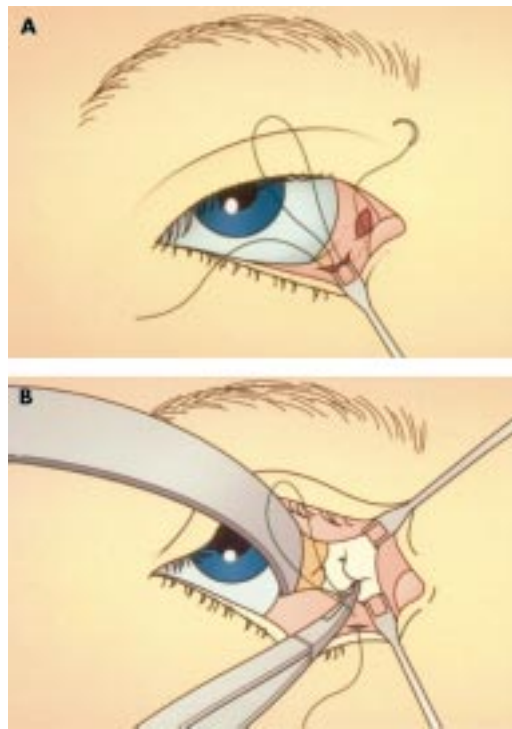


Figure 5 (A) Transcaruncular MCT plication: transconjunctival and transcaruncular placement of suture. (B) Exposure and suture through periosteum of medial orbital wall. (Reproduced with permission of Lippincott Williams & Wilkins, MD, USA.)

the MCT.¹⁰ When the patient's symptoms are more consistent with exposure keratopathy, MCT laxity is typically addressed using the guidelines in the first question and the procedure selected is usually transcaruncular plication.¹¹

Generally, I prefer the transcaruncular plication (Fig 5) to repair the posterior limb using 4-0 clear polypropylene suture on a P2 needle (Prolene D-7477, Ethicon). However with profound facial nerve paralysis I will often suspend the medial lower tarsus to the superomedial periorbital rim.¹² With lower eyelid/cheek anterior lamella cicatrix, I often use a subperiosteal midface lift and add the Mitek microanchor to secure the suture to ethmoid bone¹³ in order to maximise the strength of the transcaruncular plication.

In the presence of severe MCT laxity with an extended canaliculus and minimal elastic return, I will then shorten the canaliculus and intubate (Fig 6).

This is a difficult situation. For severe medial canthal complex laxity, some improvement can be gained using an approach including a small skin incision just medial to the insertion of the anterior limb of the MCT combined with a transcaruncular incision to gain access to the region of the posterior lacrimal crest. The fundus of the lacrimal sac superior to the common canaliculus is observed and disturbed only as necessary for fixation. A stout permanent suture is then used to solidly engage each limb of the MCT while protecting the lacrimal canaliculi. Mitek microanchors, surgical screws, or a titanium microplate is placed for secure bone fixation.¹⁴⁻¹⁶

Opinion: David Jordan

I generally do not repair the MCT laxity unless the laxity is at a severe stage—that is, at rest there is

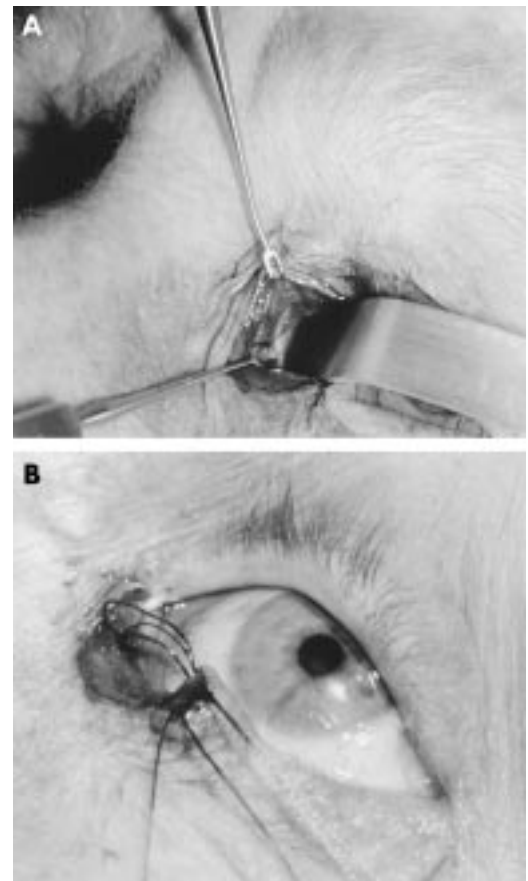


Figure 6 (A) MCT resection: exposure of the medial orbital wall. (B) Placement of sutures and canalicular tubing.

an obvious stretched appearance of the lower lid medial to the punctum with the medial lid sagging or with lateral lid distraction the punctum goes to the lateral limbus. With mild or even moderate MCT laxity, operative techniques other than surgery on the MCT itself in my view are simpler to do and very effective in correcting the patient's problem. My preferred technique for those patients with mild to moderate MCT laxity and medial ectropion is to perform a medial spindle procedure^{3 17} either on its own or in conjunction with a lateral tarsal strip procedure.¹ My decision to repair the MCT does not vary if they present with epiphora versus discharge and irritation other than doing a three snip punctoplasty if the punctum is closed. I have found this approach not only easy and straightforward but quite successful in over 99% of patients with medial mild to moderate medial lid laxity. To date, I simply have not found a simple, reliable MCT tightening procedure that works well.

With MCT laxity associated with scarring, disruption of normal contour, ectropion, and a non-functional canaliculus, or in those patients in whom occlusion of one canaliculus may be desirable, I have found the medial tarsal strip procedure (which sacrifices the lower canaliculus) to be a very useful technique.⁴

If there is profound MCT laxity I have used a MCT plication procedure. Basically I cut down on the lower limb of the MCT and plicate it using a 6-0 Vicryl suture (Ethicon). Theoretically, this technique is to preserve a functional lower canaliculus. Tendon plication shortens the affected

eyelid suspensory structures and inverts the ectropic punctum. However, canalicular kinking and injury are possible with this procedure. It is questionable how many lower canaliculi are functional following a large MCT plication. It is also difficult to place the medial canthus as posterior and medial as desired with this technique. Inadequate inversion of the ectropic punctum may also occur and a medial spindle^{3 17} may subsequently be required. I have also utilised a full thickness lid resection medial to the punctum in some cases of profound MCT laxity and have also tried microplate fixation.¹⁸ If I use the latter technique I routinely intubate the canalicular system with a silicone stent.¹⁹

In severe cases with such gross MCT laxity that the whole inner canthus complex (caruncle, upper and lower MCT) is distractible, I basically try to keep things simple. Fortunately these cases are very few and far between. If I feel the laxity is in the main limb of the MCT, I have cut down centrally over the main body and removed a section of the central limb of the MCT. Plicating sutures can also be placed along the superior or inferior limb of the MCT at the same time if needed.

Opinion: Pierre Ritleng

The inferior punctum is normally situated 1–2 mm lateral to the upper punctum. If the inferior punctum can be moved laterally more than 2 mm or 3 mm but stays medial to the medial limbus, I consider the MCT is mildly lax. Severe laxity occurs when it can be moved lateral to the medial limbus. Extreme MCT laxity allows the inferior punctum displacement to under the centre of the pupil. In most cases (95%) I prefer to perform lateral canthoplasty which is as often affected by laxity as the medial canthus. However, the postoperative displacement of the inferior punctum must stay medial to the projection of the medial limbus in cases of MCT laxity.

In my experience it is better to avoid surgery to the MCT although I frequently perform other surgical procedures on the medial canthus—sometimes in combination with lateral canthoplasty—for example, microsurgical opening of an everted, stenosed inferior punctum. I don't use three snip punctoplasty but instead triangular resection of posterior wall of the distal canaliculus and 9/0 nylon sutures between the canalicular mucosa and conjunctiva.¹⁰ A hypertrophied caruncle or lax semilunar fold, which is causing distortion of the lacrimal lake, can be resected. Blepharorrhaphy medial to the punctum will reduce medial exposure of the globe in severe paralytic ectropion. I have completely stopped

using the Lazy-T procedure which gives postoperative redness of the lid margin and the conjunctiva near the punctum, horizontal narrowing of the palpebral aperture when there is lateral canthal laxity, undercorrection, or recurrent ectropion.

I perform surgery of the anterior limb of the MCT in two instances only: post-traumatic medial canthal dystopia and moderate congenital telecanthus (with a Mustardé-plasty in blepharophimosis).²⁰ The elongated MCT anterior limb is shortened or plicated with a 5-0 Prolene suture and P3 needle (Ethicon). The disadvantage of tightening the anterior limb is that the inferior punctum will pull away from the globe altering the anatomy of the lacrimal lake. I avoid this in adults especially if there is enophthalmos.

Younger patients with severe telecanthus may require transnasal canthopexy. The MCT (anterior limb) and surrounding tissues are fixed on a non-absorbable suture which is passed through the hole of a curved needle directed as posteriorly as possible (lacrimal posterior crest). Anatomically the medial eyelids are posteriorly directed, towards the posterior lacrimal crest, under the action of Horner's muscle (posterior limb of the MCT), allowing the inferior punctum to be in contact with the globe. The anterior limb of the MCT has comparatively much less influence on correct medial eyelid position and function.²¹ For example, in my practice, I never reinsert the anterior limb of the MCT after a DCR.

I perform surgery on the posterior limb of the MCT in severe medial ectropions only. The technique¹⁰ allows shortening of the lower eyelid lateral or more often medial to the punctum with resection of the lengthened inferior canaliculus. The incision through the semilunar fold and extended onto the lower lid allows a posterior approach to Horner's muscle and the medial wall of the orbit. Two non-absorbable 5/0 Prolene sutures with a P3 needle fixate the lower tarsus to the orbital periosteum behind the posterior lacrimal crest.

In cases of severe MCT laxity with ectropion and marked epiphora, I shorten the inferior canaliculus. I always reconstruct the shortened inferior canaliculus, with four 9-0 Nylon sutures using the microscope. A bicanaliculo-nasal intubation completes the procedure because the intubation helps repair medial reattachment of the lower lid punctal alignment. A lateral canthoplasty is often performed with this more complex procedure. I never tighten both limbs of the MCT.

In summary, in mild MCT laxity, I prefer to tighten the lower lid on its lateral orbital insertion. This is easier, quicker, more effective, and durable than surgery to the MCT. I often add

Table 2 Summary of surgical approaches

Mild	Moderate	Severe
LCT repair ± medial spindle ± open punctum ± resection of caruncle/semilunar fold	Plication of MCT posterior limb or LCT repair ± medial spindle ± open punctum, ± resection of caruncle/semilunar fold	Medial tarsal strip or MCT resection (posterior limb) with canaliculus intubation/marsupialisation or MCT plication ± LCT repair

Debate

to this a posterior microsurgical punctoplasty. I perform surgery on the MCT more rarely: in severe paralytic ectropion, post-traumatic dystopia of the MCT, and in congenital telecanthus.

DISCUSSION

Convener: Brett O'Donnell

There was significant variation in the responses of the panellists and these are summarised and simplified in Table 2. All participants agree that when there is mild laxity of the MCT, tighten the LCT. Some panellists define a maximum lateral post-operative position of the punctum that should be allowed if carrying out LCT surgery, otherwise MCT surgery should be performed. For example, the postoperative punctum position should not be more than midway between the superior pupil and limbus, or medial to the medial limbus.

A variety of procedures are mentioned to improve the position of the medial eyelid: medial spindle repair or retractor tightening; and to improve functioning of the lower punctum: punctal snip or posterior opening, resection of a hypertrophic caruncle or lax plica semilunaris, and blephorrhaphy.

The threshold for MCT repair varied from 5–6 mm lateral distraction (with dermatochalasis or anterior lamella deficiency), the punctum being distractable to the medial limbus, lateral to the medial limbus, or to the lateral limbus. In other words, no agreement but most panellists will repair the MCT if the punctum is at least distractable laterally past the medial limbus.

Surgery to the anterior limb has limitations since tightening will tend to lift the medial eyelid off the globe. Anterior limb surgery is performed but in specific circumstances—for example, following trauma or for congenital telecanthus including blepharophimosis.

Posterior limb MCT surgery is the preferred option for MCT repair since this restores the posterior direction of the medial eyelid. The difficulty is what to do about the canaliculus since any surgery to the posterior limb of the MCT will affect the canaliculus. The options are plication and resection with or without canaliculus repair.

Plication spares the canaliculus but results in a concertina or shortening effect on the canaliculus with likely loss of function. It is generally used for moderate laxity. Two panellists identify a group of patients who may be unaffected by loss of the lower canaliculus. This justifies surgery whereby the MCT is repaired but the canaliculus is sacrificed and makes the decision to resect the canaliculus easier. Posterior limb resection for

severe MCT laxity with repair of the canaliculus, either by marsupialisation or intubation, is a last resort. The LCT can be repaired at the same time.

When there is preoperative epiphora, some panellists will modify their surgical approach, for example, by lowering their threshold to MCT repair, avoidance of procedures that involve cutting the canaliculus, or conversely carrying out canaliculus resection with intubation and posterior limb repair.

ACKNOWLEDGEMENTS

Thanks to Dr Mark Walland and Dr Paul Rosser who gave valuable assistance in preparation of this manuscript.

REFERENCES

- 1 **Anderson RL**, Gordy DD. The tarsal strip procedure. *Arch Ophthalmol* 1979;**97**:2192–6.
- 2 **Anderson RL**, Jordan DR. The lateral tarsal strip revisited. *Arch Ophthalmol* 1989;**107**:604–6.
- 3 **Anderson RL**, Nowinski TS. The medial spindle procedure for involutional medial ectropion. *Arch Ophthalmol* 1985;**103**:1750–3.
- 4 **Anderson RL**, Jordan DR, Thiese SM. The medial tarsal strip. *Arch Ophthalmol* 1990;**108**:120–4.
- 5 **Anderson RL**, Nowinski TS. The five-flap technique for blepharophimosis. *Arch Ophthalmol* 1989;**107**:448–52.
- 6 **Collin JRO**. *A manual of systematic eyelid surgery*. 2nd ed. London: Churchill Livingstone 1989:32–5.
- 7 **Crawford GJ**, Collin JRO, Moriarty PA. The correction of paralytic ectropion. *Br J Ophthalmol* 1984;**68**:639–41.
- 8 **McCord CD**. Canalicular resection and reconstruction by canaliculostomy. *Ophthalmic Surg* 1980;**11**:440–5.
- 9 **Lee OS**. Operation for correction of everted lacrimal puncta. *Am J Ophthalmol* 1951;**34**:575–8.
- 10 **Ritleng P**. Medial canthoplasty for treatment of severe lacrimal ectropion. *Orbit* 1989;**8**:49–56.
- 11 **Fante RG**, Elner VM. A transcaruncular approach to MCT plication for lower eyelid laxity. *Ophthalm Plast Reconstr Surg* 2001;**17**:16–27.
- 12 **Su C**, Frueh B. Medial tarsal suspension. *Ophthalmic Plast Reconstr Surg* (in press).
- 13 **Okazaki M**, et al. Medial canthoplasty with the Mitek anchor system. *Ann Plast Surg* 1997;**38**:124–8.
- 14 **Callahan MA**. Canthal fixation with a stainless steel screw: a report of ten patients. *Adv Ophthalm Plast Reconstr Surg* 1988;**7**:33–40.
- 15 **Shore JW**, Rubin PAD, Bilyk JR. Repair of telecanthus by anterior fixation of cantilevered miniplates. *Ophthalmology* 1992;**99**:1133–8.
- 16 **Francis IC**, Walsh WR, Sonnabend DH, et al. Stabilization of the posterior limb of the medial canthal tendon using biodegradable tag anchors: a cadaveric model. *Ophthalm Plast Reconstr Surg* 2001;**17**:28–35.
- 17 **Tse DT**. Surgical correction of punctal malposition. *Am J Ophthalmol* 1985;**100**:339–41.
- 18 **Howard GR**, Nerad JA, Kersten RC. Medial canthoplasty with microplate fixation. *Arch Ophthalmol* 1992;**110**:1793–7.
- 19 **Jordan DR**, Nerad JA, Tse D. The pigtail probe revisited. *Ophthalmology* 1990;**97**:512–9.
- 20 **Adenis JP**, Morax S. Pathologie orbito-palpébrale. In: *Société Française d'Ophthalmologie*. Paris: Masson, 1998:184–97.
- 21 **Ritleng P**, Bourgeon A, Richelme H. New concept of the anatomy of the lacrimal apparatus. *Anat Clin* 1983;**5**:29–34.