

PostScript

LETTERS

Intravitreal injection of triamcinolone acetonide as treatment for chronic uveitis

Chronic intraocular inflammation such as chronic uveitis can lead to cystoid macular oedema, papilloedema, and vitreous opacities temporarily or permanently reducing visual acuity. Chronic uveitis has usually been treated by topical or systemic application of steroids. Topical treatment, however, often has not been sufficiently effective to suppress intraocular inflammation and to reduce cystoid macular oedema. Systemic treatment with steroids inevitably leads to secondary side effects such as systemic suppression of the whole immune system and Cushing's syndrome. Taking into account that the eye comprises only 0.01% of the whole body volume, and considering that for achieving high concentrations of a drug at its site of action it is best to apply it directly into the region of required action, we describe the clinical outcome in a patient receiving an intravitreal injection of a crystalline cortisone.

Case report

A 17 year old woman suffering from chronic idiopathic uveitis in both eyes for 5 years had been treated topically, peribulbarly, and systemically with corticosteroids. As a steroid responder, she had developed secondary ocular hypertension. Steroid induced cataract in her right eye was operated on by phacoaspiration, transpupillary anterior vitrectomy, and posterior chamber lens implantation. To reduce the systemic side effects of steroid treatment, systemic cyclosporin A had been added to the treatment scheme since January 1998. In February 2000, she presented again with a severe uveitis with papilloedema and cystoid macular oedema. Despite intensive topical treatment with steroids given hourly, and systemic acetazolamide, visual acuity remained in the range 0.10-0.16. To avoid the side effects of systemic steroid treatment and to achieve high and longstanding concentrations of steroids in the eye, we injected 20 mg crystalline triamcinolone acetonide into the vitreous cavity of the right eye in July 2000 with topical anaesthesia.

Within the next 5 weeks, visual acuity increased to 0.5. Intraocular pressure increased to a maximum of 38 mm Hg, and was reduced to the normal range with topical antiglaucomatous medication. Four months after the injection, the steroid crystals were resorbed, visual acuity returned to the preoperative level of 0.1, and with topical steroids given, intraocular pressure decreased to values of less than 23 mm Hg without further antiglaucomatous medication.

Comment

In ophthalmology, corticosteroids applied topically or systemically are well known and have widely been used to suppress intraocular inflammation. Based on experimental studies performed by Machermer, Peyman and others, as well as on clinical observations, intravitreal injections of triamcinolone acetonide have increasingly been reported as treatment for

intraocular neovascular, oedematous, or inflammatory diseases. These include diffuse diabetic macular oedema, proliferate diabetic retinopathy, neovascular glaucoma, exudative age related macular degeneration, and uveitis.¹⁻⁵ In agreement with these previous studies, the results of the present report suggest that the intravitreal injection of triamcinolone acetonide may be an additional option in the treatment of chronic uveitis. Future studies may address which types of uveitis intravitreal steroid injection are best for, and whether the use of intravitreally implanted slow release devices⁶ can decrease the recurrence rate of uveitis for a longer period than a single intravitreal injection dose.

Proprietary interest: none.

R F Degenring, J B Jonas

Department of Ophthalmology, Faculty for Clinical Medicine Mannheim, Ruprecht-Karls-University Heidelberg, Germany

Correspondence to: Dr R Degenring, Universitäts-Augenklinik, Theodor-Kutzer-Ufer 1-3, 68167 Mannheim, Germany; robert.degenring@augen.ma.uni-heidelberg.de

Accepted for publication 17 June 2002

References

- 1 Machermer R, Sugita G, Tano Y. Treatment of intraocular proliferations with intravitreal steroids. *Trans Am Ophthalmol Soc* 1979;**77**:171-80.
- 2 Jonas JB, Söfker A. Intraocular injection of crystalline cortisone as adjunctive treatment of diabetic macular edema. *Am J Ophthalmol* 2001;**132**:425-7.
- 3 Antcliff RJ, Spalton DJ, Stanford MR, et al. Intravitreal triamcinolone for uveitic cystoid macular edema: an optical coherence tomography study. *Ophthalmology* 2001;**108**:765-72.
- 4 Young S, Larkin G, Branley M, et al. Safety and efficacy of intravitreal triamcinolone for cystoid macular edema in uveitis. *Clin Exp Ophthalmol* 2001;**29**:2-6.
- 5 Martidis A, Duker JS, Puliafito CA. Intravitreal triamcinolone for refractory cystoid macular edema secondary to birdshot retinochoroidopathy. *Arch Ophthalmol* 2001;**119**:1380-3.
- 6 Jaffe GJ, Ben-nun J, Guo H, et al. Fluocinolone acetonide sustained drug delivery device to treat severe uveitis. *Ophthalmology* 2000;**107**:2024-33.

Ophthalmodynamometric estimation of cerebrospinal fluid pressure in pseudotumour cerebri

Measurement of the cerebrospinal fluid pressure usually requires a lumbar puncture or craniotomy to get direct access to the cerebrospinal fluid space. These techniques, however, are invasive and so carry the risk of complications such as infections and damage to the neural structures. Furthermore, owing to the leakage of cerebrospinal fluid during the puncture, the cerebrospinal fluid pressure will be altered in the moment the measurement is performed. It is, therefore, desirable to have a non-invasive method allowing the estimation of the intracerebral pressure without requiring a direct access to the brain or spinal cord. We describe a patient in whom ophthalmodynamometry strongly suggested an increased

intracerebral pressure which was confirmed by eventual direct measurement.

Case report

A 12 year old female patient presented with acute vomiting, massive headache, and bilateral abducens nerve palsy. Visual acuity was 20/20 in both eyes, and visual fields were unremarkable, except for an enlarged blind spot. Both optic discs showed a prominence of 0.5 mm (right eye) and 0.6 mm (left eye) as measured by confocal laser scanning tomography. Intraocular pressure measured 18 mm Hg. With topical anaesthesia, a Goldmann contact lens fitted with a pressure sensor mounted into its holding ring was put onto the cornea (Fig 1). Pressure was asserted onto the globe by slightly pressing the contact lens, and the pressure value at the time when the central retinal vein started pulsating was noted. The measurements of this new technique of ophthalmodynamometry were repeated nine times in both eyes.

The central retinal vein collapse pressure as the sum of the ophthalmodynamometric value plus the intraocular pressure, measured 103 relative units right eye and 98 relative units left eye. These values were significantly higher than normal values (6.1 (SD 8.4) relative units) determined previously in normal subjects (own data). Direct measurement of cerebrospinal fluid pressure by lumbar puncture performed about 5 hours later revealed a value of 107 cm water column (equivalent to 82.3 mm Hg). In combination with other clinical findings, the diagnosis of pseudotumour cerebri was made.

Comment

The central retinal vein is the only structure whose appearance depends on its inner pressure, and which runs through the cerebrospinal fluid space and which is accessible from outside the body without any invasive procedure being performed. After exiting the eye through the optic disc, the central retinal vein goes through the retrobulbar part of the optic nerve before it traverses the subarachnoidal and subdural spaces of the optic nerve and pierces the optic nerve meninges. The pressure in the central retinal vein is thus at least as high as the cerebrospinal fluid pressure. The central retinal vein collapse pressure may be measurable by ophthalmodynamometry since the vein will start to pulsate, if the sum



Figure 1 Photograph showing the Goldmann contact lens with a pressure sensor mounted into the holding ring of the contact lens and connected to a display.

of intraocular pressure plus an external pressure exerted onto the eye equals the diastolic pressure of the central retinal vein.¹⁻⁴ The intraocular pressure can be determined by applanation tonometry, and the additional pressure exerted onto the globe can be measured by the ophthalmodynamometer. In the ophthalmodynamometers used in the 1960s and 1970s, determinations of the central retinal vein pressure were often difficult or almost impossible so that the central retinal vein pressure has usually not been measured.⁵ The new ophthalmodynamometer used in the present study (Fig 1) may overcome some of the problems associated with the old ophthalmodynamometers. In a previous study on the reproducibility of the new technique, the variation of the central retinal vein collapse pressure was 15.9% (SD 11.9%). The present study suggests that, in patients with markedly increased intracerebral pressure, the new, Goldmann lens associated, ophthalmodynamometer may provide information about the intracerebral pressure by estimating the central retinal vein collapse pressure. It may be helpful for the neuro-ophthalmological diagnosis of diseases associated with increased intracerebral pressure.

Proprietary interest: none.

J B Jonas, B Harder

Department of Ophthalmology, Faculty of Clinical Medicine Mannheim, University of Heidelberg, 68167 Mannheim, Germany

Correspondence to: Dr J Jonas, Universitäts-Augenklinik, Theodor-Kutzer-Ufer 1-3, 68167 Mannheim, Germany; Jost.Jonas@augen.ma.uni-heidelberg.de

Accepted for publication 14 July 2002

References

- Meyer-Schwickerath R, Kleinwachter T, Firsching R, et al. Central retinal venous outflow pressure. *Graefes Arch Clin Exp Ophthalmol* 1995;**233**:783-8.
- Morgan WH, Yu DY, Cooper RL, et al. Retinal artery and vein pressures in the dog and their relationship to aortic, intraocular and cerebrospinal fluid pressures. *Microvasc Res* 1997;**53**:211-21.
- Firsching R, Schutze M, Motschmann M, et al. Venous ophthalmodynamometry: a noninvasive method for assessment of intracranial pressure. *J Neurosurg* 2000;**93**:33-6.
- Draeger J, Rumberger E, Hechler B. Intracranial pressure in microgravity conditions: non-invasive assessment by ophthalmodynamometry. *Aviat Space Environ Med* 1999;**70**:1227-9.
- Wunsh SE. Ophthalmodynamometry. *N Engl J Med* 1969;**281**:446.
- Jonas JB. Reproducibility of ophthalmodynamometric measurements of the central retinal artery and vein collapse pressure. *Br J Ophthalmol* 2003 (in press).

Treatment of atopic blepharitis by controlling eyelid skin water retention ability with ceramide gel application

Atopic blepharitis is one of the major ocular complications of atopic dermatitis (AD).^{1,2} It has been pointed out that atopic patients have dry skin accompanied by barrier disruption and water deficiency. Previously, we assessed the water retention ability of eyelid skin by measuring the water content and water evaporation rate from the eyelid in patients with atopic blepharitis.³ The water content positively correlated and water evaporation

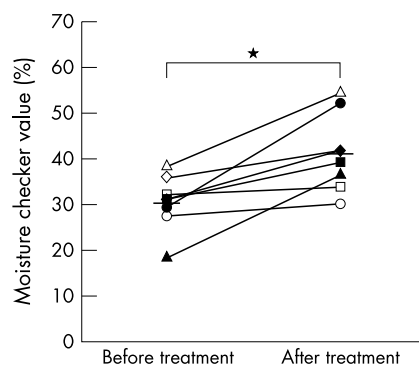


Figure 1 The change in water contents of eyelid skin. Water content indicated by moisture checker value is significantly increased after ceramide gel application (bars indicate average value, $p < 0.025$).

from the eyelid negatively correlated with the severity of blepharitis.³

Ceramide comprises about 30% of stratum corneum lipids, which have an important role in both the water retention and barrier function of the skin.⁴ Ceramide abnormalities in several skin disorders, such as AD, have been reported.^{5,6} Decreased levels of ceramides may be attributable to the insufficient water retention of the skin in AD. Apytt Gel (Zenyaku Kogyo, Tokyo, Japan) is a product containing galactosyl ceramides extracted from horses as a major moisturising ingredient. In this study, we assessed the efficacy and safety of this gel product in patients with mild atopic blepharitis by measuring the water retention ability of the eyelid skin before and after prescription.

Methods and results

Sixteen lids of eight patients (five males and three females, 7-35 years old, average age 16.0 (SEM 8.4) years) diagnosed as having AD by dermatologists, according to Hanifin and Rajka's criteria,⁷ were examined. Because ceramide gel has no anti-inflammatory effect, cases with severe inflammation were excluded from this investigation. After informed consent was obtained, patients were instructed to place Apytt Gel on their eyelids two to five times a day after washing their faces. Assessment of clinical findings using measurement of water retention ability were performed as previously described³ before and 4 weeks after the beginning of application. Statistical analysis was carried out by non-parametric tests (Wilcoxon test). A p value of 0.05 or less was considered statistically significant.

Water content of eyelid skin was significantly increased after treatment (30.6% (6.0%) before treatment, 41.2% (8.5%) after treatment; $p < 0.025$) (Fig 1). Water evaporation values were significantly decreased after treatment ($4.5 (1.4) \times 10^{-7}$ g/cm²/s before treatment, $3.5 (0.9) \times 10^{-7}$ g/cm²/s after treatment; $p < 0.05$) (Fig 2). No slit lamp findings indicating toxicity were observed during the course of the study.

Comment

As the eyelid is a borderline lesion between dermatology and ophthalmology with influences on ocular homeostasis, dermatologists often hesitate in prescribing sufficient medication to the eyelids. The assessment and treatment of atopic blepharitis is therefore an important aspect of ophthalmological examination in atopic patients.

Ceramide gel treatment for 4 weeks significantly improved the water retention ability of

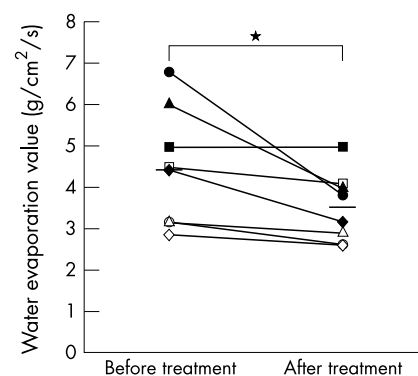


Figure 2 The change in water evaporation rate from eyelid skin. Water evaporation value is significantly decreased after ceramide gel application (bars indicate average value, $p < 0.05$).

eyelid skin of patients with mild atopic blepharitis. Among various moisturising products, the application of the ceramide gel is reasonable, because ceramide deficiency has been reported in the skin of atopic patients. Ceramide gel alleviates dryness without stickiness, and patients experience little discomfort. Comfort during application is thought to be one of the important factors for the compliance of patients. Some patients interrupt application of ointments, such as petrolatum (Vaseline), to the eyelid because of stickiness or because the shiny appearance around the eyes is cosmetically conspicuous. Although strong anti-inflammatory drugs are necessary in acute exacerbations of atopic blepharitis, moisturising of the skin using ceramide gel application represents a useful supplementary therapy during periods of relatively light inflammation.

Acknowledgement

The authors wish to thank Ms Mie Sasaki and Ms Saori Nishijima for their assistance in taking measurements of water evaporation from eyelid skin.

Financial support: none.

Proprietary interest: none.

N Asano-Kato, K Fukagawa, Y Takano, T Kawakita, K Tsubota, H Fujishima
Department of Ophthalmology, Tokyo Dental College, Japan

S Takahashi
Department of Dermatology

Correspondence to: Naoko Asano-Kato, MD, Department of Ophthalmology, Tokyo Dental College, Chiba, Japan, 5-1-13 Sugano, Ichikawa-shi, Chiba 272-8513, Japan; naokato@bc.iiij4u.or.jp

Accepted for publication 15 July 2002

References

- Garrity JA, Liesegang T. Ocular complications of atopic dermatitis. *Can J Ophthalmol* 1984;**19**:21-4.
- Beltrani VS. The clinical spectrum of atopic dermatitis. *J Allergy Clin Immunol* 1999;**104**:S87-98.
- Asano-Kato N, Fukagawa K, Tsubota K, et al. Quantitative evaluation of atopic blepharitis by scoring of eyelid conditions and measuring the water content of the skin and evaporation from the eyelid surface. *Cornea* 2001;**20**:255-9.
- Brod J. Characterization and physiological role of epidermal lipids. *Int J Dermatol* 1991;**30**:84-90.

- 5 **Imokawa G**, Abe A, Jin K, *et al*. Decreased level of ceramides in stratum corneum of atopic dermatitis: an etiologic factor in atopic dry skin? *J Invest Dermatol* 1991;**96**:523–6.
- 6 **Jin K**, Higaki Y, Takagi Y, *et al*. Analysis of beta-glucocerebrosidase and ceramidase activities in atopic and aged dry skin. *Acta Derm Venereol (Stockh)* 1994;**74**: 337–40.
- 7 **Hanifin JM**, Rajka G. Diagnostic features of atopic dermatitis. *Acta Derm Venereol (Stockh)* 1980;**92**:44–7.

An unusual tumour of the lacrimal gland

Lacrimal gland swelling is usually due to an inflammatory or neoplastic process. We report an oncocytoma as the cause of lacrimal gland swelling and review the literature. Oncocytoma of the lacrimal gland is extremely rare and has been described only three times before.

Case report

A 72 year old man experienced periodic swelling of his right eyelid over a period of 9 months. For 2 months he complained of vertical diplopia. He had a past medical history of chronic obstructive airways disease and a past ocular history of early cataract, asteroid hyalosis of the vitreous body, and primary open angle glaucoma.

On examination visual acuity of both eyes was 0.50. External examination showed a right hypotropia. There was a 3 mm of proptosis of the right eye. Eye movements in that eye were restricted in all directions. Slit lamp evaluation showed bilateral mild cataract. Intraocular pressures were normal (12 and 10 mm Hg respectively). Funduscopy examination yielded cup:disc ratios of 0.8. Computed tomography (CT) of orbit (Fig 1) showed an extraconally solid space occupying mass in the lacrimal fossa. The tumour displaced the right eye inferomedially. The tumour was thought to arise from the lacrimal gland. A fine needle aspiration cytology demonstrated proliferation of oncocytic cells. The tumour was removed in toto via a lateral orbitotomy. The operation and the postoperative period were uncomplicated.

Histological macroscopic description yielded a spherically shaped, partially encapsulated tissue (measuring 2.8 × 3.0 × 1.9 cm). After preparation it had a homogeneous brownish tuberiform aspect. Microscopic examination (Fig 2) showed fibrous tissue with focally pre-existing remnants of lacrimal gland tissue. There was a sharply demarcated tumour composed of tubular structures lined by large cells. These transformed epithelial cells consisted of eosinophilic, granular cytoplasm with round to oval shaped relative small nuclei and nucleoli. No evidence of

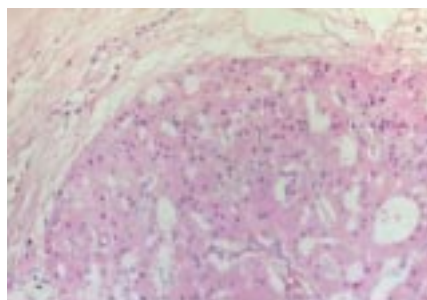


Figure 2 Microscopic image showing oncocytic cells in the lacrimal gland.

angioinvasive growth was seen. A diagnosis of a radically removed oncocytoma was made.

Postoperative visual acuity of the right eye was reduced because of poor tear secretion confirmed on Schirmer testing and slit lamp examination showed filamentary keratopathy. Lubricating eye drops were prescribed and collagen punctal plugs were inserted in the superior and inferior puncta. Diplopia and the motility disturbance diminished. Follow up to date is 1½ years and no regrowth has been assessed.

Comment

Oncocytomas (synonyms: oxyphilic adenomas or oncocytic adenomas) are benign, epithelial tumours arising in the ductal cell lining of apocrine glandular structures. In an oncocytoma the oncocytes can form nests, cords, and tubules. Oncocytes can be found among the epithelial cells of various normal organs.¹ Oncocytomas occur frequently and have been described in salivary, thyroid, parathyroid, buccal mucosa, breast, kidney, pharynx, and larynx. If they occur near the eye, they are generally located in caruncle, lacrimal sac, accessory lacrimal glands of the conjunctiva and rarely in the lacrimal gland. For unknown reasons oncocytic lesions begin to appear in early adulthood and proliferate with age.²

Most lacrimal gland masses represent inflammatory disease, either responding to antibiotics or anti-inflammatory medication. Various malignant tumours of the lacrimal gland have been described varying from lymphoproliferative disorders to epithelial neoplasms. Approximately 50% of epithelial tumours are benign mixed tumours (pleomorphic adenomas) and about 50% are carcinomas. In rare cases a lacrimal gland mass is found to be an oncocytoma, as described in our case and in three other cases in the literature,^{3,4} or as an oncocytic carcinoma.^{4,6}

Beskid and Zarzcka³ described a 39 year old woman with an oncocytoma of the lacrimal gland. Riedel *et al*⁴ reported a 1.5 year old African girl with an oncocytoma of the lacrimal gland. This is the only case in the literature that reported on an oncocytoma in childhood. Riedel *et al*⁴ also reported a 76 year old woman with an oncocytoma of her lacrimal gland, that presented with a 2 month period of swelling of her lacrimal fossa without proptosis. After excision there was no regrowth during a follow up period of 3.5 years. Proliferations of oncocytic cells can also show malignant features and become malignant oncocytomas. A 58 year old man reported by Riedel⁴ had a malignant oncocytoma (synonym: oxyphilic adenocarcinoma) of the lacrimal gland. He had a 3 month history of proptosis of his eye and diplopia. On presentation the tumour had intracranial extension.

Despite radical resection and postoperative radiation therapy, he died 6 months later from liver metastases. Dorello *et al*⁵ described a similar case of a 59 year old patient with an oncocytic carcinoma of the lacrimal gland with intracranial extension. The patient died approximately 2 years after development of his clinical symptoms (exophthalmos and diplopia), despite orbital exenteration and radiation therapy. A 81 year old woman reported by Biggs⁶ had a 6 month history of proptosis due to an oncocytic adenocarcinoma of the lacrimal gland. No follow up information was given.

In summary, a 72 year old man was found to have an oncocytoma of the lacrimal gland. Oncocytoma has to be added to the differential diagnosis of lacrimal gland swelling.

L J C Hartman, M P Mourits

Department of Ophthalmology, University Medical Center, Heidelberglaan 100, Utrecht, Netherlands

M R Canninga-van Dijk

Department of Pathology

Correspondence to: Dr Hartman; l.hartman@wanadoo.nl

Accepted for publication 16 July 2002

References

- 1 **Sutula FC**. Tumors of the lacrimal gland and sac. In: Albert MA, Jacobiec FA, eds. *Principles and practice of ophthalmology*. 1st ed. Philadelphia: Saunders, 1994:1955.
- 2 **Balogh K**. The head and neck. In: Rubin E, Farber JL, eds. *Pathology*. 1st ed. Philadelphia: Lippincott, 1988:1279.
- 3 **Beskid M**, Zarzcka M. Przypadek onkocytoma gruczolu Lzowego. *Klin Oczna* 1959;**29**:311–15.
- 4 **Riedel K**, Stefani FH, Kampik A. Onkozytome der okulären adnexe. *Klin Monatsbl Augenheilkd* 1983;**182**:544–8.
- 5 **Dorello U**. Carcinoma oncocitario della ghiandola lacrimale. *Riv ONO* 1961;**36**:452–61.
- 6 **Biggs SL**, Font RL. Oncocytic lesions of the caruncle and other ocular adnexae. *Arch Ophthalmol* 1977;**95**:474–8.

Morning glory disc anomaly: an atypical case

When optic disc elevation is encountered on funduscopy examination, the first concern is whether it represents true disc oedema. We present a patient who was urgently referred to us by a retinal specialist because of unilateral "disc swelling." Further evaluation suggested that the patient had a congenital optic disc anomaly that was atypical in appearance, but most likely a variant of the morning glory disc anomaly (MGDA).

Case report

A 40 year old African-American woman with no visual complaints went to her local optometrist for a routine eye examination. At the optometrist's office she was told that "in the back of her right eye she had a dark spot with a ring around it" and was referred to a retinal specialist. The retinal specialist found a mildly decreased visual acuity and a "swollen disc" in the right eye and the patient was referred for neuro-ophthalmic consultation. To her knowledge, she previously had never had a dilated funduscopy examination.

Best corrected visual acuity was 20/30 distance and J1 near in the right eye and 20/20 distance and J1+ near in the left eye. There was a 0.9 log unit right relative afferent pupillary defect. Her colour vision, external

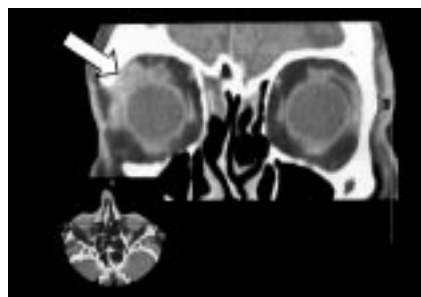

Figure 1 CT scan showing tumour in the right orbit (arrow). Axial slice shows proptosis of the right eye.

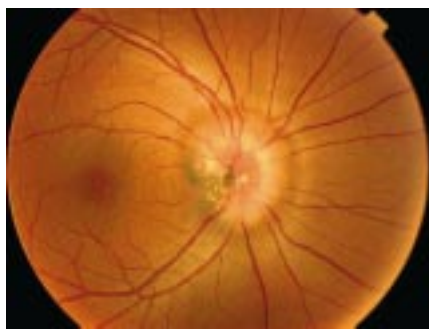

Figure 1 Photograph of the patient's right optic disc. An elevated annulus of apparent fibrogial tissue surrounds most of the disc although it appears to spare part of the papillomacular bundle. An excavation of retina and retinal pigment epithelium surrounding the optic disc can be appreciated from about 12 o'clock to 7 o'clock.

examination, slit lamp biomicroscopy, intraocular pressures, and motility were all normal in both eyes. Funduscopic examination was normal in the left eye with an optic nerve cup to disc ratio of 0.4. The appearance of her right optic nerve (Fig 1) was that of an elevated ring around the centre of the disc, interrupted from about 7 o'clock to 9 o'clock by an area of pigmentation. The vasculature was mildly obscured as it crossed the elevation. There was no venous engorgement, haemorrhage, cotton wool spots, or exudate. Funduscopic examination gave the appearance of a peripapillary excavation of retina and retinal pigment epithelium surrounding the elevated ring from about 12 o'clock to 7 o'clock. The macula and periphery were normal. Automated perimetry showed an enlarged blind spot and a relative superior altitudinal defect on the right and a full field on the left.

Fluorescein angiography showed staining of optic nerve tissue but no leakage of fluorescein outside the disc margin, confirming the absence of true disc swelling (Fig 2). Magnetic resonance imaging of the brain and orbits with gadolinium showed no pathology. B-scan ultrasonography excluded optic disc drusen. Optical coherence tomography (OCT) of the optic nerve showed the elevated annulus of tissue seen on fundus examination and also showed a peripapillary excavation of the retinal pigment epithelium (RPE) adjacent to the optic nerve (Fig 3). This was thought to be most consistent with MGDA.

Comment

Morning glory disc anomaly is a congenital anomaly of the optic disc that is typically uni-

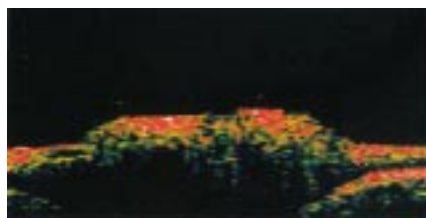


Figure 3 Optical coherence tomography (OCT) of the patient's right optic nerve. Representative OCT shows retinal pigment epithelium lining an excavation surrounding the optic nerve, characteristic of morning glory syndrome.

lateral (for review see Brodsky¹). The majority of patients have a visual acuity between 20/200 and counting fingers in the affected eye, although cases with 20/20 vision and no light perception have been reported. It is more common in females than males and is less common in African-Americans than white people.²⁻⁴ This condition is not typically an inherited condition or part of a multisystem genetic disorder, although it has been reported as part of the renal-coloboma syndrome⁵ and trisomy 4q.⁶

The term "morning glory syndrome" was coined for its ophthalmoscopic resemblance to the morning glory flower.⁷ In MGDA the optic nerve lies centrally within an excavation of the posterior globe. The size of the excavation varies from being relatively small, as in this particular case, to cases in which the excavation encompasses the macula, termed macular capture. In most cases there is a central fibrous tuft that obscures the central part of the disc⁸ and a variable amount of peripapillary pigment.

While MGDA is usually diagnosed by funduscopic examination alone, our case was atypical and not diagnosed immediately for several reasons: the patient had good visual acuity in the affected eye; she was African-American; there was no central fibrous tuft; and there was only a mild amount of peripapillary pigmentation. It is likely that our patient's visual acuity was spared because of relative sparing of the papillomacular bundle (Fig 1). Indeed, the peripapillary annulus of tissue surrounding the optic nerve spared a small area temporally from about 7 to 9 o'clock. In this region there was some pigment disturbance, but little if any apparent fibrosis, compared to the rest of the optic nerve. While a previous study of eight patients⁹ suggested there was "no correlation between optic disc configuration and visual acuity" there was no patient in that study with a documented visual acuity better than 20/100.

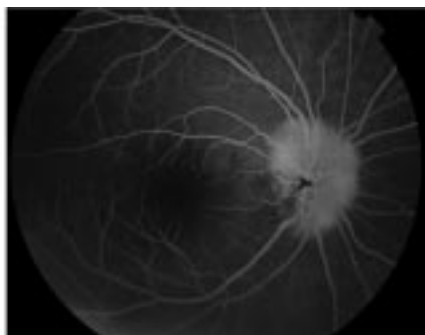
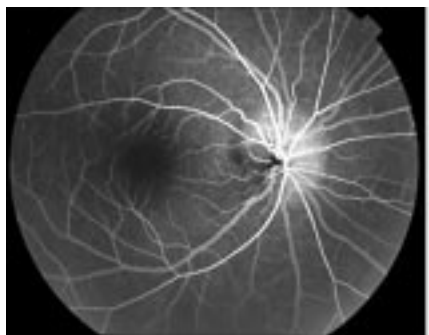


Figure 2 Fluorescein angiography of the patient's right eye. Both early (left; 32.6 seconds after injection) and late (right; 6 minutes and 14 seconds after injection) images show no evidence of fluorescein leakage outside the disc margin.

Another atypical feature of our patient is the small amount of peripapillary pigment seen in the affected eye. The only area of pigmentation is between 7 and 9 o'clock. The remaining clock hours have elevated fibrovascular tissue but no visible pigment. This finding is not unexpected, as the visible peripapillary pigment in MGDA dissipates over time. This decrease in peripapillary pigment over time is believed to be secondary to a metaplasia of hamartomatous RPE into fibrogial tissue and hyperplasia of the fibrogial tissue. Our patient was 40 years old at diagnosis of MGDA and it is possible that she had more peripapillary pigment when she was younger. It is also possible that the peripapillary excavation of this patient was larger when she was younger, as the glial hyperplasia tends to progressively elevate the disc over time.¹⁰

There is controversy regarding the aetiology of MGDA. Some believe it is a form of optic disc coloboma.^{11,12} This theory is supported by evidence that MGDA is seen along a continuum of other optic disc anomalies including coloboma in the renal coloboma syndrome.⁵ Based on the findings of a scleral defect, vascular anomalies, central glial tuft, and adipose and smooth muscle tissue in histopathological specimens, it has been hypothesised that MGDA may be a primary mesenchymal disorder or an abnormality in the relative growth between the mesoderm and ectoderm.^{8,9} Another theory proposes that an abnormal enlargement of the distal optic stalk during eye development allows the inner layer of the optic cup to enter, causing an excavation at the entry site.³ One problem with determining the aetiology has been the lack of clinical confirmation (primarily a lack of fundus photography) in previous histopathological reports.^{8,13-16} In this report we present OCT data that confirm these pathological findings in MGDA. Common to all of the histopathological reports is a layer of RPE that lines the peripapillary excavation. This histological feature is confirmed in the present case with OCT, which shows RPE extending posteriorly within the peripapillary scleral excavation as it approaches the optic nerve (Fig 3). We are currently evaluating other patients with MGDA using OCT and comparing these findings with the OCT appearances of other optic nerve anomalies, including optic disc coloboma.

MGDA is sometimes associated with a basal encephalocele¹⁷⁻²¹ and up to a third of patients with MGDA will develop a retinal detachment.^{2,4,22} Hence, the first step in the management of MGDA is recognising these associated conditions. Our patient did not have the characteristic facial features (flattened nasal bridge or cleft lip) nor did she have any neurological, endocrine, or respiratory symptoms to suggest she had a basal encephalocele and an magnetic resonance imaging confirmed its absence. Funduscopic examination showed no evidence of retinal detachment, and she will be followed carefully for this potential complication.

Although this is an atypical case, with no central fibrous tuft and little peripapillary pigment, this patient demonstrates the peripapillary excavation characteristic of MGDA. To our knowledge this is the first report of OCT of an eye with MGDA and confirms previous histopathological reports of MGDA showing RPE lining the central peripapillary excavation. Ongoing studies at our institution are using OCT to quantify the changes that occur with MGDA over time and to compare the features of MGDA with those of other optic nerve anomalies, including optic disc coloboma.

Acknowledgements

This manuscript was supported in part by a departmental grant (Department of Ophthalmology) from Research to Prevent Blindness, Inc, New York, New York, and by core grant P30-EY06360 (Department of Ophthalmology) from the National Institute of Health, Bethesda, Maryland. NJN is a recipient of a Research to Prevent Blindness Lew R Wasserman Merit Award.

Some of the data in this paper have been previously published in abstract form at the Association for Research in Vision and Ophthalmology (ARVO) annual conference in 2002.

C A Baer, T M Aaberg Sr

Department of Ophthalmology, Emory University School of Medicine, Atlanta, GA, USA

N J Newman

Departments of Ophthalmology, Neurology, and Neurological Surgery

Correspondence to: Nancy J Newman, MD, Neuro-ophthalmology Unit, Emory Eye Center, 1365B Clifton Road, NE, Atlanta, GA 30322, USA; ophntjn@emory.edu

Accepted for publication 5 July 2002

References

- 1 **Brodsky MC**. Congenital optic disc anomalies. *Surv Ophthalmol* 1994;**39**:89–112.
- 2 **Haik BG**, Greenstein SH, Smith ME, *et al*. Retinal detachment in the morning glory syndrome. *Ophthalmology* 1984;**91**:1638–47.
- 3 **Pollock S**. The morning glory disc anomaly: contractile movement, classification, and embryogenesis. *Doc Ophthalmol* 1987;**65**:439–60.
- 4 **Steinkuller PG**. The morning glory disc anomaly: case report and literature review. *J Pediatr Ophthalmol Strabismus* 1980;**17**:81–7.
- 5 **Dureau P**, Attie-Bitach T, Salomon R, *et al*. Renal coloboma syndrome. *Ophthalmology* 2001;**108**:1912–6.
- 6 **Nucci P**, Mets MB, Babianelli EB. Trisomy 4q with morning glory anomaly. *Ophthalmic Pediatr Genet* 1990;**2**:143–5.
- 7 **Kindler P**. Morning glory syndrome: unusual congenital optic disc anomaly. *Am J Ophthalmol* 1970;**69**:376–84.
- 8 **Dempster AG**, Lee WR, Forrester JV, *et al*. The 'morning glory syndrome': a mesodermal defect? *Ophthalmologica* 1983;**187**:222–30.
- 9 **Traboulsi EI**, O'Neill JF. The spectrum in the morphology of the so-called "morning glory disc anomaly". *J Pediatr Ophthalmol Strabismus* 1988;**25**:93–8.
- 10 **Beyer WB**, Quencer RM, Osher RH. Morning glory syndrome: a functional analysis including fluorescein angiography, ultrasonography, and computerized tomography. *Ophthalmology* 1982;**89**:1364–7.
- 11 **Gardner TW**, Zaporackas ZG, Naidich TP. Congenital optic nerve colobomas: CT demonstration. *J Comp Ass Tomog* 1984;**8**:95–102.
- 12 **Mafee MF**, Jampol LM, Langer BG, *et al*. Computed tomography of optic nerve colobomas, morning glory anomaly, and colobomatous cyst. *Radiol Clin N Am* 1987;**25**:693–9.
- 13 **Cogan DG**. Coloboma of the optic nerve with overlay of the peripapillary retina. *Br J Ophthalmol* 1978;**62**:347–50.
- 14 **Manschot WA**. Morning glory syndrome: a histopathological study. *Br J Ophthalmol* 1990;**74**:56–8.
- 15 **Pedler C**. Unusual coloboma of the optic nerve entrance. *Br J Ophthalmol* 1961;**45**:803–7.
- 16 **Rack JH**, Wright GF. Coloboma of the optic nerve entrance. *Br J Ophthalmol* 1966;**50**:705–9.
- 17 **Caprioli J**, Lesser RL. Basal encephalocele and morning glory syndrome. *Br J Ophthalmol* 1971;**71**:423–5.
- 18 **Goldhammer Y**, Smith JL. Optic nerve anomalies in basal encephalocele. *Arch Ophthalmol* 1975;**93**:115–18.
- 19 **Hope-Ross M**, Hohnston SS. The morning glory syndrome associated with sphenothalamic encephalocele. *Ophthalmic Pediatr Genet* 1990;**2**:147–53.
- 20 **Koenig SP**, Naidich TP, Lissner G. The morning glory syndrome associated with sphenoidal encephalocele. *Ophthalmology* 1982;**89**:1368–72.
- 21 **Pollock JA**, Newton TH, Hoyt WF. Transsphenoidal and transthemoidal encephaloceles: a review of clinical and roentgen features in 8 cases. *Radiology* 1968;**90**:442–53.
- 22 **Takeda A**, Hida T, Kimura C, *et al*. A case of bilateral morning glory syndrome with total retinal detachment. *Folia Ophthalmol Jap* 1981;**32**:1179–81.

Idiopathic anterior hyaloid vessels

Anterior hyaloidal fibrovascular proliferation (AHFP), the growth of vessels across the anterior hyaloid face from an origin in anterior retina,¹ was first described in phakic eyes after diabetic vitrectomy surgery,² but is also reported following cataract surgery in diabetics.³ Complications include cataracts, vitreous haemorrhage, tractional retinal detachment, ciliary body detachment, and phthisis bulbi.¹ We present the first report of this entity occurring in a non-diabetic patient without previous ophthalmic surgery.

Case report

A 20 year old Asian man presented with acute right sided visual loss. There was no history of ocular trauma or family history of note. He was systemically well. Visual acuity was 6/12 right eye, 6/5 left. Vessels were visible on the right posterior lens capsule, associated with localised cataract and anterior vitreous opacity (Fig 1A). Clinical examination revealed no other ocular abnormality, but the temporal periphery of the right retina was obscured. Anterior segment fluorescein angiography confirmed perfusion of the vessels (Fig 1B). Posterior segment fluorescein angiography

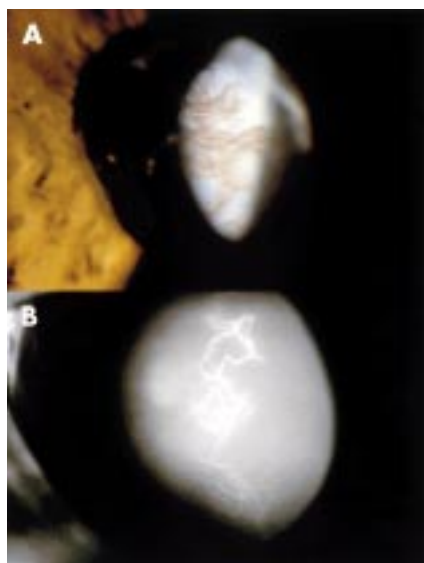


Figure 1 Right eye. (A) Abnormal vessels on temporal aspect of posterior capsule associated with localised cataract and anterior vitreous opacity. (B) Anterior segment fluorescein angiography confirming perfusion of vessels.

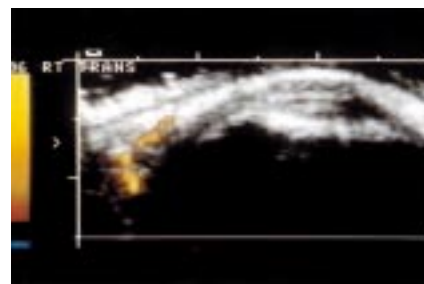


Figure 2 B-scan ultrasonography with Doppler showing a feeder vessel.

was of poor quality in the right eye and revealed no fundus or peripheral abnormality in the left eye. Fluorescein angiography of the patient's only surviving parent was normal. Fasting blood glucose, *Toxocara/Toxoplasma* serology, haemoglobin electrophoresis, and skull/chest radiographs were normal. Doppler studies indicated a probable feeder vessel derived from anterior retina but no evidence of tumour or other pathology (Fig 2).

Progressive cataract reduced visual acuity to 6/24 within 2 weeks of presentation. Phacoemulsification surgery was performed, followed by closure of the abnormal vessels with krypton laser (568 nm). Nd:YAG capsulotomy was performed 6 weeks after surgery. Two weeks later, fibrinous anterior uveitis and vitritis developed which resolved with topical steroid medication. A year later, vessels persisted in the rolled capsular edge, and opacification of the anterior hyaloid necessitated Nd:YAG laser discission. Two and a half years after presentation, he is asymptomatic with 6/9 visual acuity in the right eye.

Comment

In most instances of retinal neovascularisation, an angiogenic stimulus, such as capillary non-perfusion or inflammation, can be identified.⁴ In this case, no evidence was found of capillary non-perfusion, or any, other than postoperative, inflammation.

A number of specific diagnoses were considered. No temporal traction on vascular arcades or optic disc was seen in the affected eye, and peripheral retinal vasculature was normal, where seen in the affected eye, and in the fellow eye. There was no history of low birth weight or prematurity as in retinopathy of prematurity. There was no family history, and the retinal peripheries of the parent were normal, which makes dominant exudative vitreoretinopathy unlikely. No inflammation, other than post-surgical, was identified in anterior or posterior segment, and visible pars plana appeared normal. *Toxocara* and *Toxoplasma* serology was negative. There was no visible peripheral retinal vasculitis or systemic evidence of sarcoidosis or multiple sclerosis. No evidence of ocular trauma was found, and no foreign body was identified radiographically. The patient is not diabetic, screening for haemoglobinopathy was negative, and there were no ophthalmoscopic or angiographic signs of retinal vascular occlusion. No evidence of a hyperviscosity syndrome was found.

The patient's age, sex, and race are typical of patients suffering from idiopathic peripheral vaso-occlusive retinopathy (Eales' disease), but the absence of retinal vasculitis, vitreous and retinal haemorrhage, and the unilateral nature of disease, are less characteristic. No sign of tumour was apparent on ultrasonography, and no evidence of arteriovenous malformation was found in the eye or body. He had

no features of incontinentia pigmenti or facioscapulohumeral muscular dystrophy. The diagnosis therefore remains uncertain.

Treatment was mandated on the basis of visual loss. Vitreoretinal opinion preferred phacoemulsification surgery to pars plana vitreolensectomy because of the absence of definable vitreous or peripheral retinal disease. The vessels were closed with laser before capsulotomy to avoid haemorrhage, as has occurred after capsulotomy in diabetic patients with AHFP.³

J G F Dowler, J S Mehta, A M Landers, A M P Hamilton

Medical Retinal Service, Moorfields Eye Hospital, City Road, London EC1V 2PD, UK

Correspondence to: Mr J S Mehta; jodmehta@hotmail.com

Accepted for publication 8 July 2002

References

- 1 Lewis H, Abrams GW, Foos RY. Clinicopathologic findings in anterior hyaloidal fibrovascular proliferation after diabetic vitrectomy. *Am J Ophthalmol* 1987;**104**:614–8.
- 2 Lewis H, Abrams GW, Williams GA. Anterior hyaloidal fibrovascular proliferation after diabetic vitrectomy. *Am J Ophthalmol* 1987;**104**:607–13.
- 3 Ulbig MR, Hykin PG, Foss AJ, et al. Anterior hyaloidal fibrovascular proliferation after extracapsular cataract extraction in diabetic eyes. *Am J Ophthalmol* 1993;**115**:321–6.
- 4 Jampol LM, Ebroon DA, Goldbaum MH. Peripheral proliferative retinopathies: an update on angiogenesis, etiologies and management. *Surv Ophthalmol* 1994;**38**:519–40.

Iris pigment epithelial cyst induced by topical administration of latanoprost

Latanoprost is an ester prodrug analogue of prostaglandin $F_{2\alpha}$ that enhances uveoscleral outflow and reduces intraocular pressure.¹ Several adverse side effects associated with topical administration of latanoprost have been described.^{2,3} Iris cyst can be primary or secondary; the secondary iris cysts are usually caused by trauma, intraocular surgery, inflammation, and prolonged use of strong miotic agents, etc.⁴ We report one female patient, with advanced chronic angle closure glaucoma, who developed an iris cyst in her left eye 9 months after topical administration of latanoprost in both her eyes.

Case report

A 67 year old female patient initially presented with advanced chronic angle closure glaucoma in 1994. Laser iridotomy was performed on both her eyes in April 1994. After then, both eyes were treated with 2% pilocarpine and β blocker to maintain her intraocular pressures in the low teens. Because she preferred to use monotherapy, latanoprost had been used once a day at bedtime since July 2000. The intraocular pressures were maintained between 12 and 15 mm Hg with latanoprost monotherapy. No abnormal responses except mild hyperaemia of the conjunctiva were noticed during follow up examinations. Unfortunately, in May 2001 (about 9+ months after latanoprost monotherapy), it was noticed that the iris of her left eye bulged forward between 7 o'clock and 8 o'clock. The lesion was gradually increasing its size, and in September 2001 an iris

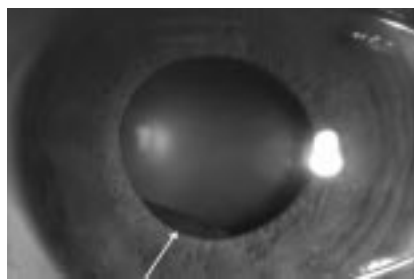


Figure 1 Slit lamp photography of the patient's left eye was taken after 12+ months of topical administration of latanoprost. In the inferonasal quadrant (see the arrow), an iris cyst appeared as a dark brown mass between the pupillary border and the anterior surface of the lens.

pigment epithelial cyst was found at the posterior iris surface through a mid-dilated pupil (Fig 1). Latanoprost was then discontinued and her antiglaucomatous medication was changed to dorzolamide and β blocker twice a day in both eyes. The iris cyst gradually decreased in size and completely disappeared from the pupil margin in February 2002 (Fig 2). During the follow up period of 4 months, there have been no visual complications or signs of recurring cyst.

Comment

Our report demonstrates another case of rare adverse side effects of latanoprost involving the iris. Although no ultrasonic biomicroscopy was used to follow up this case, the slit lamp biomicroscopy strongly suggested that the patient had a secondary pigment epithelial cyst arising from the posterior surface of the iris. The iris cyst developed in her left eye about 9+ months after topical administration of latanoprost in her both eyes, and it progressively decreased in size and completely disappeared 5 months after topical latanoprost was discontinued. The iris cyst in our case took more time to develop and a longer time to disappear than previously reported.³ We propose that if it took more time to develop an iris cyst after topical administration of latanoprost, it would need more time for the iris cyst to regress.

The topical latanoprost was administered to her both eyes, but only her left eye developed the iris cyst. We propose that both her eyes might have different sensitivity to the development of an iris cyst when exposed to topical latanoprost. (If her right eye was exposed to latanoprost for a longer time, an iris cyst might occur later.) Although cysts of uveal tissue might occur after uveitis,³ no definite

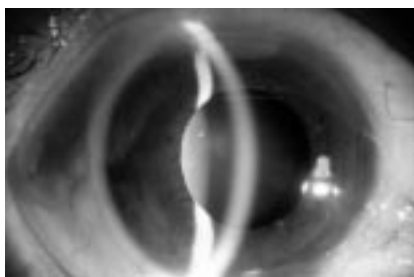


Figure 2 Slit lamp photography of the patient's left eye was taken 5 months after discontinuation of latanoprost. The iris cyst has disappeared and the anterior chamber is of normal depth.

symptoms and signs of uveitis were noticed in our patient during the follow up period. The most likely cause of this adverse side effect may be the increasing uveoscleral outflow on topical use of latanoprost; increasing uveoscleral outflow leads to an enhanced aqueous flow through the ciliary muscle and the intraepithelial space of the posterior iris. The iris cyst can occur at anytime during topical administration of latanoprost. Ophthalmologists should be aware of this possible rare side effect of topical administration of latanoprost.

I C Lai, M T Kuo, I M C Teng

Department of Ophthalmology, Chang-Gung Memorial Hospital, Kaohsiung, 123 Tai-Pei Road, Niao-Sung Hsiang, Kaohsiung Asien, Taiwan

Correspondence to: Ing-Chou Lai; e12014@adm.cgmh.org.tw

Accepted for publication 17 July 2002

References

- 1 Toris CB, Camras CB, Yablonski ME. Effects of PHXA41, a new prostaglandin $F_{2\alpha}$ analog, on aqueous humor dynamics in human eyes. *Ophthalmology* 1993;**100**:1297–304.
- 2 Rowe JA, Hattenhauer MG, Herman DC. Adverse side effects associated with latanoprost. *Am J Ophthalmol* 1997;**124**:683–5.
- 3 Krohn J, Hove VK. Iris cyst associated with topical administration of latanoprost. *Am J Ophthalmol* 1999;**127**:91–3.
- 4 Eagle JR, RC. Congenital, developmental and degenerative disorders of the iris and ciliary body. In Albert DM, Jacobiec FA, eds. *Principle and practice of ophthalmology: clinical practice*. 1st ed. Philadelphia: Saunders, 1994:367–88.
- 5 Gentile RC, Leibmann JM, Tello C, et al. Ciliary body enlargement and cyst formation in uveitis. *Br J Ophthalmol* 1996;**80**:895–9.

Paravertebral primitive neuroectodermal tumour presenting with Horner's syndrome

We describe a peripheral primitive neuroectodermal tumour (PPNET) arising from the cervical paravertebral region of a 34 year old woman, who presented with Horner's syndrome and a cervical radiculopathy. PPNETs are rare malignant small round cell tumours. This appears to be the first documented case of localised PPNET with Horner's syndrome at initial presentation.

Case report

A 34 year old woman presented with acute left scapula pain, numbness of her left forearm, a left upper lid ptosis, and left hemifacial anhidrosis. Her symptoms disappeared spontaneously within a fortnight, but returned 2 months later with greater intensity. Examination then revealed wasting of the small muscles of her left hand with reduced power in the distribution of C8 and T1; there was loss of light touch and pinprick in the C8 dermatome. The presence of left 1 mm upper lid ptosis, miosis, hemifacial anhidrosis, and 1 mm lower lid ("upside down") ptosis was highly suggestive of a preganglionic left Horner's syndrome (Fig 1A). Magnetic resonance imaging (MRI) of the neck showed a large mass arising from the T1, T2 intervertebral foramen extending into the root of the left side of the neck and the region of the apex of the left lung (Fig 1B).

A diagnostic biopsy was performed through a posterolateral approach, excising the extradural component of the tumour within the

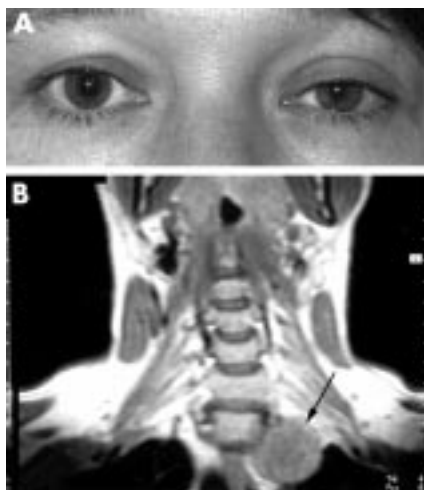

Figure 1 (A) Left Horner's syndrome with left upper lid ptosis, miosis, and "upside down" lower lid ptosis. (B) Magnetic resonance imaging of neck (coronal section), showing a mass arising from between the first and second thoracic intervertebral foramen, extending into the root of the left side of the neck and the left pulmonary apical region (arrow).

nerve root canal. Histology revealed a malignant round cell tumour consistent with a peripheral primitive neuroectodermal tumour (PPNET, Fig 2). Immunohistochemical studies demonstrated positivity for focal vimentin, cytokeratins, synaptophysin, and MIC-2, but were negative for GFAP (glial fibrillary acidic protein), S100, desmin, and the lymphoid markers LCA, CD3, and CD20. Staging investigations showed no evidence of metastatic disease and therefore the diagnosis of localised PPNET was made.

The patient received chemotherapy as primary treatment followed by radiotherapy and has been in remission since. A year later she was referred to our unit for correction of her left ptosis, and underwent left anterior levator resection with a satisfactory result. Four years following her initial diagnosis she remains free of recurrent disease.

Comment

Horner's syndrome is caused by an oculosympathetic deficit to the pupillodilator and superior and inferior tarsal retractor muscles.¹⁻³ It is manifest by upper lid ptosis, ipsilateral miosis, apparent enophthalmos due to lower lid ("upside down") ptosis, and often facial anhidrosis.⁴ The presence of all these features in our patient, together with the left facial anhidrosis, was indicative of a preganglionic lesion, since the sympathetic facial sweat fibres branch distal to the superior cervical sympathetic ganglion and central neurological tract signs were absent.^{2,3} Preganglionic Horner's syndrome is frequently associated with neoplasms of the pulmonary apex, mediastinum, or neck, as illustrated by the location of the PPNET seen in our patient (Fig 1B).

PPNET is a rare malignant small round cell tumour that can affect any age group but is thought to peak in adolescence, with no sex predilection.⁵ The most common location is the thoracopulmonary region, followed by the head and neck. Extrasosseous Ewing's sarcoma is now considered a form of PNET, through immunohistochemical, ultrastructural, and histogenetical similarities.⁶ Both tumours express elevated levels of glycoprotein p30-32, a

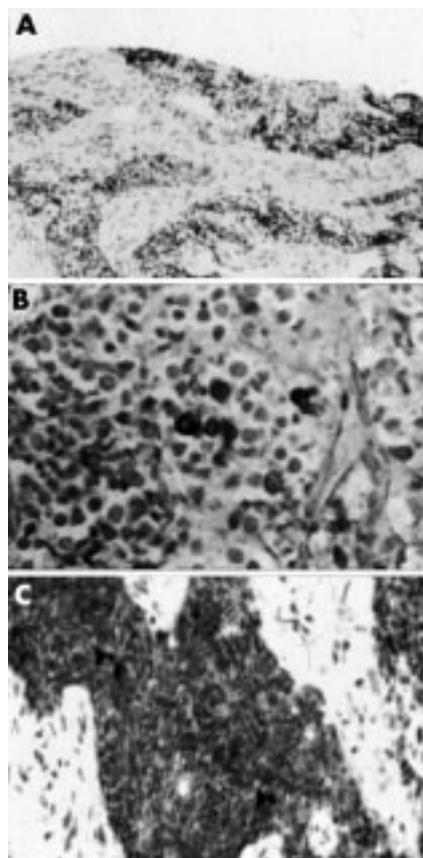


Figure 2 Histology of excised cervicothoracic extradural mass taken January 1998 showing (A) round tumour cells with numerous frequent mitoses infiltrating fibrovascular stroma (haematoxylin and eosin $\times 140$); (B) immunohistochemical reactivity of tumour cell cytoplasm with vimentin stain (Dako Ltd, UK; 1:40) $\times 710$; (C) focal cytoplasmic dot-like staining with synaptophysin immunohistochemistry (arrowheads) (Dako Ltd, UK; 1:100).

product of the MIC-2 gene, in a unique and highly selected fashion, as well as specific translocations involving a gene on chromosome 22q12. Indeed, the tumour cells of our patient exhibited immunohistochemical reactivity for MIC-2, consistent with a PPNET.

The association of Horner's syndrome with C8/T1 cervical radiculopathy is classically seen in Pancoast's syndrome, which is due to superior sulcus tumours of the lung that involve the chest wall and spinal column.⁷ The presentation of PPNET with Pancoast's syndrome has been reported previously, but in this case the tumour had massively infiltrated the left thorax with widespread metastases, resulting in death at 17 weeks following initial diagnosis.⁸ In contrast, our patient presented with Horner's syndrome at a relatively early stage of the disease, since the PPNET was localised with no evidence of metastatic spread. The malignant nature of this tumour highlights the importance of comprehensively investigating any patient with Horner's syndrome, especially when associated with cervical radiculopathy.

Acknowledgement

We thank Dr Maria Thom, MRCPATH, Division of Pathology, Institute of Neurology, London, for her assistance and permission in the preparation of pathological figures.

D N Parmar, N Lim, N Joshi
Chelsea and Westminster Hospital, 369 Fulham
Road, London SW10 9NH, UK

Correspondence to: D N Parmar, Moorfields Eye
Hospital, City Road, London EC1V 2PD, UK

Accepted for publication 22 July 2002

References

- 1 **Kawasaki A.** Physiology, assessment, and disorders of the pupil. *Curr Opin Ophthalmol* 1999;**10**:394-400.
- 2 **Amonoo-Kuofi HS.** Horner's syndrome revisited: with an update of the central pathway. *Clin Anat* 1999;**12**:345-61.
- 3 **Wilhelm H.** Neuro-ophthalmology of pupillary function—practical guidelines. *J Neurol* 1998;**245**:573-83.
- 4 **Nielsen PJ.** Upside down ptosis in patients with Horner's syndrome. *Acta Ophthalmol (Copenh)* 1983;**61**:952-7.
- 5 **Jones JE, McGill T.** Peripheral primitive neuroectodermal tumors of the head and neck. *Arch Otolaryngol Head Neck Surg* 1995;**121**:1392-5.
- 6 **Batsakis JG, Mackay B, el-Naggar AK.** Ewing's sarcoma and peripheral primitive neuroectodermal tumor: an interim report. *Ann Otol Rhinol Laryngol* 1996;**105**:838-43.
- 7 **York JE, Walsh GL, Lang FF, et al.** Combined chest wall resection with vertebrectomy and spinal reconstruction for the treatment of Pancoast tumors. *J Neurosurg* 1999;**91**(1 Suppl):74-80.
- 8 **Meyer T, Herrmann C, Hiddemann W, et al.** Pathology and clinical aspects of peripheral neuroectodermal tumours. *Deutsch Med Wochenschr* 1993;**118**:1442-6.

Association of keratoconus and Avellino corneal dystrophy

Keratoconus is an idiopathic, progressive, non-inflammatory ectasia of the axial cornea. Its association of other systemic disorders or ocular disease have been reported, but its specific origin remains unknown. Recently, Munier and associates detected that four types of autosomal dominant corneal dystrophy result from mutation in the human transforming growth factor β induced gene (β IGH3), the product of which has shown to be the protein keratoepithelin (R555W mutation for Reis-Bückler's corneal dystrophy, R124C mutation for lattice corneal dystrophy type I, and R124H mutation for Avellino corneal dystrophy).¹ Molecular genetic analysis of various corneal dystrophies, which had previously presented an insuperable challenge to clinical diagnosis, now clearly demonstrates the distinct phenotypes.² We report a rare case of bilateral keratoconus in association with Avellino corneal dystrophy diagnosed by molecular genetic analysis.

Case report

A 35 year old man had complained blurred vision in both eyes for several years. His general health was good and there was no history of atopic disease, connective tissue disease, or ocular trauma. His familial history was unknown.

His best corrected visual acuity was RE 20/50 and LE 20/100. Slit lamp examination revealed bilateral non-inflammatory corneal thinning with protrusion of the central thinning areas. Fleischer ring was found in both corneas. Central corneal thickness was 428 μ m on the right and 421 μ m on the left measured by ultrasonic pachymetry. There was also clinical evidence of granular corneal dystrophy in both eyes. Discrete grey-white opacities and star-shaped spicular opacities

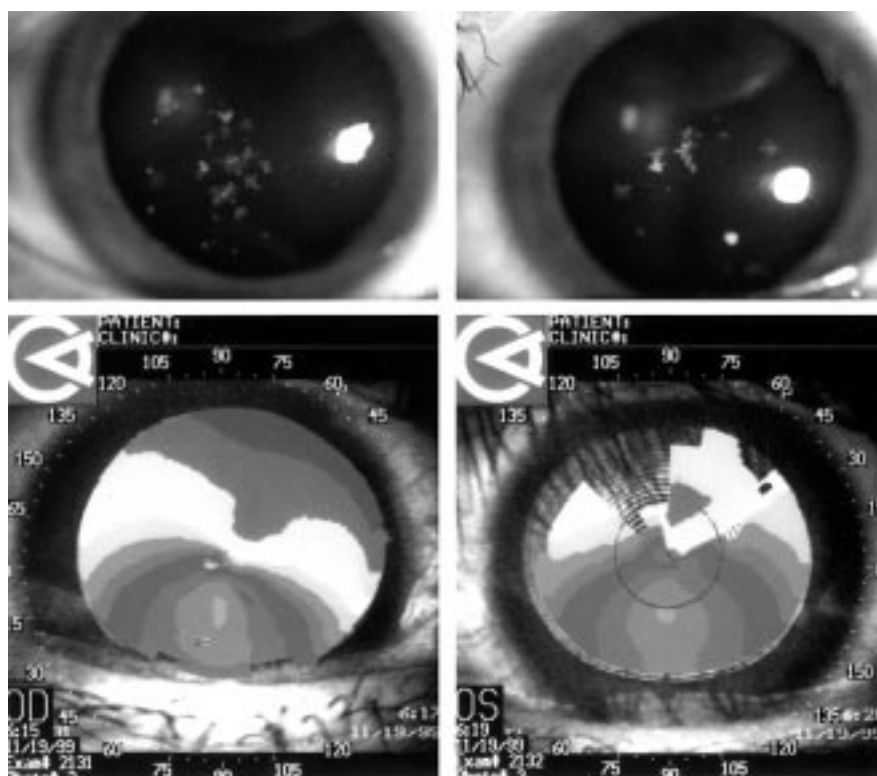


Figure 1 Slit lamp photographs RE (top left) and LE (top right) show discrete grey-white opacities and star-shaped spicular opacities in anterior stroma. (Bottom left and right) Computed corneal topography shows inferior steepening resulting in the diagnosis of keratoconus.

were seen in anterior stroma (Fig 1, top). Computed corneal topography showed inferior steepening consistent with the diagnosis of keratoconus (Fig 1, bottom). With rigid gas permeable contact lenses his visual acuity corrected to 20/20 right and 20/25 left. The remainder of the ocular examination was unremarkable.

After obtaining informed consent, we collected venous blood from the patient and extracted genomic DNA. Using appropriate primers,¹ we amplified exons 4 and 12 of the β IGH3 gene by polymerase chain reaction (PCR) and directly sequenced the products. We detected a heterozygous G→A transition in codon 124 that results in a substitution from arginine to histidine in this patient (Fig 2). These genetic findings were consistent with Avellino corneal dystrophy.

Comment

To our knowledge, this is the first molecular genetic report of a bilateral association of keratoconus with Avellino corneal dystrophy.

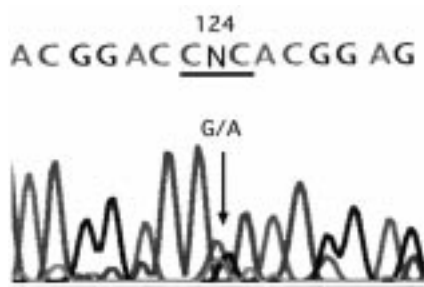


Figure 2 Results of direct sequencing analysis of the exon 4 of β IGH3 gene. Heterozygous G→A transition is seen at the second position of codon 124 (arrow).

There is only one case report in the literature of a patient with keratoconus associated with Avellino corneal dystrophy. Sassani and associates reported the bilateral association of keratoconus and Avellino corneal dystrophy, which was diagnosed histopathologically.³ On the other hand, there are five reports with keratoconus associated with granular corneal dystrophy.⁴⁻⁸ However, those cases were diagnosed clinically, not histopathologically or genetically.⁴⁻⁷ A clinical diagnosis of the different types of corneal stromal dystrophy is difficult, especially for granular corneal dystrophy and Avellino corneal dystrophy.⁹ Some cases previously reported as granular corneal dystrophy might be actually cases of Avellino corneal dystrophy.

The involvement of genetic factors has been reported in keratoconus, but its hereditary pattern was not identified. A gene for at least one form of hereditary keratoconus has been mapped to human chromosome 21.¹⁰ In our case, it is unclear whether a genetic factor had a role in the simultaneous development of keratoconus and Avellino dystrophy. There may be some linkage between the genes responsible for these two abnormalities. In our case, molecular genetic analysis clearly demonstrated the presence of distinct phenotype, which had not previously presented clinically.

The authors have no proprietary interest in any aspects of this work.

S Igarashi

Department of Ophthalmology, Asahikawa Medical College, Asahikawa, Japan

Y Makita

Department of Public Health, Asahikawa Medical College, Asahikawa, Japan

T Hikichi, F Mori, K Hanada, A Yoshida,
Department of Ophthalmology, Asahikawa Medical College, Asahikawa, Japan

Correspondence to: Sho Igarashi, MD, Department of Ophthalmology, Asahikawa Medical College, Midorigaoka Higashi 2-1-1, Asahikawa 078-8510, Japan; sho@asahikawa-med.ac.jp

Accepted for publication 23 July 2002

References

- Munier FL, Korvatska E, Djemai A, et al. Kerato-epithelin mutations in four 5q31-linked corneal dystrophies. *Nat Genet* 1997;**15**:247-51.
- Klintworth GK. Advances in the molecular genetics of corneal dystrophies. *Am J Ophthalmol* 1999;**128**:747-54.
- Sassani JW, Smith SG, Rabinowitz YS. Keratoconus and bilateral lattice-granular corneal dystrophies. *Cornea* 1992;**11**:343-50.
- Yoshida H, Funabashi M, Kanai A. Histological study of the corneal granular dystrophy complicated by keratoconus. *Folia Ophthalmol Jpn* 1980;**31**:218-23.
- Koomoto R, Koomoto M, Moriyama H. One case of granular corneal dystrophy associated keratoconus and esotropia. *Folia Ophthalmol Jpn* 1984;**35**:2002-7.
- Vajpayee RB, Snibson GR, Taylor HR. Association of keratoconus with granular corneal dystrophy. *Aust NZ J Ophthalmol* 1996;**24**:369-71.
- Mitsui M, Sakimoto T, Sawa M, et al. Familial case of keratoconus with corneal granular dystrophy. *Jpn J Ophthalmol* 1998;**42**:385-8.
- Wallensack G, Green WR, Temprano J. Keratoconus associated with corneal granular dystrophy in a patient of Italian origin. *Cornea* 2002;**21**:121-2.
- Kocak-Altintas AG, Kocak-Midillioglu I, Akarsu AN, et al. BIGH3 gene analysis in the differential diagnosis of corneal dystrophies. *Cornea* 2001;**20**:64-8.
- Rabinowitz YS, Zu L, Yang H, et al. Keratoconus: non-parametric linkage analysis suggests a gene locus near the centromere of chromosome 21. *Invest Ophthalmol Vis Sci* 1999;**40**:S564.

Presence of vitronectin in neovascularised cornea of patient with gelatinous drop-like dystrophy

Gelatinous drop-like corneal dystrophy (GDLD) is a rare autosomal recessive disorder that is most often seen in Japan. This bilateral dystrophy usually presents in the first decade of life and is associated with a decrease of visual acuity. Typically, a mulberry-like opacity is present with protuberant subepithelial mounds that grow with age. Corneal neovascularisation (NV) also accompanies advanced cases.¹ Corneal transplantation is the major therapeutic option for GDLD, but because NV can significantly increase the risk of graft rejection, a better understanding of the mechanism(s) for the corneal NV would be valuable.

Case report

A 39 year old Japanese man with GDLD was studied. His right eye had band-shaped corneal opacities in the interpalpebral area with a number of gelatinous prominences, and vascular invasions from the superior limbus into the clear cornea (Fig 1A). Because the visual acuity of the right eye had decreased to 20/800, penetrating keratoplasty was performed, and the diagnosis of GDLD was confirmed by characteristic histopathological findings of amyloid deposits beneath the corneal epithelium and mutation of the *MISI* gene.²

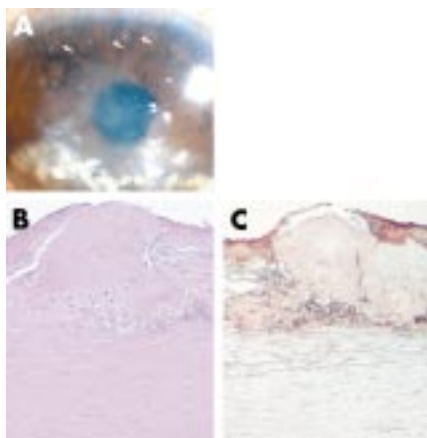


Figure 1 (A) Slit lamp photographs of the right cornea of a 39 year old man with gelatinous drop-like dystrophy (GDL), demonstrating subepithelial raised lesions with a mulberry-like appearance and band-shaped opacities occupying the inferior cornea. There is also neovascular infiltration from the superior limbus of the cornea, some of the vessels are indicated by arrows. (B) Light microscopic photograph of a corneal button section surgically excised from the 39 year old man. Histological section of this cornea shows eosinophilic amorphous material in the subepithelial region, and the overlying epithelium was degenerated. Note the prominent inflammatory infiltrate (haematoxylin and eosin, original magnification $\times 200$). (C) Immunostaining of GDL cornea with vitronectin showing immunopositivity in the infiltrating leucocytes and basal epithelial cell layer. Diffuse staining for vitronectin is also found in the deposits. Anti-vitronectin also appears to stain the superficial layer of corneal epithelial cells, although we cannot totally rule out the possibility that this might represent an edge artefact (haematoxylin counterstain, original magnification $\times 200$).

It was recently reported that vitronectin, a multifunctional extracellular matrix adhesion molecule, is often a component of the abnormal extracellular deposits in various age related human diseases such as age related macular degeneration and amyloidosis. This suggested that similar pathways may be involved in the aetiologies of other age related diseases.³ Because the disease state of GDL deteriorates with age, we hypothesised that similar vitronectin related pathways may also be associated with GDL, and examined whether vitronectin was expressed in the GDL cornea by immunohistochemistry.

An antibody directed against vitronectin (Santa Cruz Biotechnology, Santa Cruz, CA, USA) exhibited intense reactivity with the infiltrating leucocytes and corneal epithelium around the deposits. Substantial levels of vitronectin protein were also present in the deposits (Fig 1B, C).

Because the production of new extracellular matrix proteins has a crucial role in supporting cell proliferations that are necessary for new blood vessel growth,⁴ and because vitronectin receptors, such as integrin $\alpha v \beta 3$ and $\alpha v \beta 5$, are involved in angiogenesis,⁴ we further hypothesised that the accumulated vitronectin in the GDL cornea may also have a role in the accompanying corneal NV.

We therefore examined the angiogenic potential of vitronectin using an in vivo corneal assay.⁵ Five μ l hydron pellets (Inter-

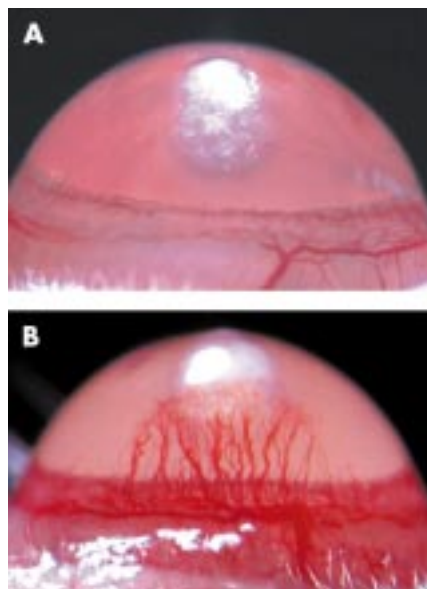


Figure 2 Representative photographs showing the effect of vitronectin on in vivo angiogenesis in rat cornea. Hydron pellets were formulated and implanted into rat corneas. After 7 days, vessels in the region of the pellet implant were photographed. Pellets contained PBS (A) or vitronectin (B). Six rats were used to assess the effect of vitronectin and neovascularisation was observed in all six replicates.

feron Sciences, New Brunswick, NJ, USA) containing 1 μ g of mouse vitronectin (Invitrogen, Carlsbad, CA, USA) were implanted to the cornea of anaesthetised male Sprague-Dawley (S-D) rats and, after 7 days, the animals were killed, and the corneal vessels were photographed. Vitronectin elicited a strong angiogenic response, but administration of phosphate buffered saline (PBS) alone did not (Fig 2).

Comment

These results provide the first evidence for the expression of vitronectin in the cornea with GDL, and for the in vivo induction of angiogenesis by vitronectin. The results indicate that vitronectin may have a role in corneal NV in patients with GDL. Therefore, further studies exploring mechanisms of corneal NV mediated by vitronectin-integrin system, and how mutation of *MISI* leads to accumulation of vitronectin with more samples, may eventually offer a novel insight in understanding the aetiology of corneal NV associated with GDL.

Acknowledgements

This work was supported in part by grants from Sumitomo Life Social Welfare Services Foundation (SY), Japan National Society for the Prevention of Blindness (AY), and Japan Eye Bank Association (AY).

S Yoshida, A Yoshida, T Ishibashi

Department of Ophthalmology, Kyushu University Graduate School of Medicine, Fukuoka, 812-8582, Japan

Y Kumano, T Matsui

Ohshima Hospital of Ophthalmology, Fukuoka, 812-0036, Japan.

Correspondence to: Shigeo Yoshida, MD, PhD, Department of Ophthalmology, Kyushu University Graduate School of Medicine, Fukuoka, 812-582, Japan; usyosi@yahoo.com

Accepted for publication 12 August 2002

References

- 1 Smolin G. Corneal dystrophies and degenerations. In: Smolin G, Thoft RA, eds. *The cornea*. Boston: Little, Brown, 1995:499-533.
- 2 Yoshida S, Kumano Y, Yoshida A, et al. Two brothers with gelatinous drop-like dystrophy at different stages of the disease: role of mutational analysis. *Am J Ophthalmol* 2002;**133**:830-2.
- 3 Mullins RF, Russell SR, Anderson DH, et al. Drusen associated with aging and age-related macular degeneration contain proteins common to extracellular deposits associated with atherosclerosis, elastosis, amyloidosis, and dense deposit disease. *Faseb J* 2000;**14**:835-46.
- 4 Stuppach DG, Cheresch DA. ECM remodeling regulates angiogenesis: endothelial integrins look for new ligands. *Sci STKE* 2002;**2002**:PE7.
- 5 Yoshida S, Ono M, Shono T, et al. Involvement of interleukin-8, vascular endothelial growth factor, and basic fibroblast growth factor in tumor necrosis factor alpha-dependent angiogenesis. *Mol Cell Biol* 1997;**17**:4015-23.

Factor XII deficiency and recurrent sixth nerve palsy

Factor XII deficiency is associated with thrombosis.¹⁻³ Severe deficiency increases an individual's prothrombotic tendency but with a mild reduction in levels there is less certainty.⁴ We present a case of recurrent sixth cranial nerve palsy due to severe factor XII deficiency. To our knowledge, this is the first reported case of a recurrent cranial nerve palsy associated with factor XII deficiency.

Case report

A 58 year old white male presented with an acquired constant inconstant horizontal diplopia. He had had a previous episode of horizontal diplopia of 3 weeks' duration 6 months previously with spontaneous resolution and a further similar episode 18 years before that but had been otherwise well. He was not hypertensive or diabetic, of normal weight and a non-smoker, and without any cardiovascular disease. There was no family or personal history of venous or arterial thrombosis. On examination he was found to have bilateral sixth nerve palsies without any associated headache or papilloedema. Detailed magnetic resonance imaging with contrast and lumbar puncture opening pressure and investigation was normal.

Owing to the recurrent nature of the nerve palsy and the initial young age of presentation, a further prothrombotic examination was undertaken. Laboratory investigations showed a normal full blood count, plasma viscosity, liver function tests, glucose, homocysteine, prothrombin time, and fibrinogen assay. There was a significantly prolonged activated partial thromboplastin time of 74.7 seconds (normal range 24-32), which was still abnormal on repeat testing (90 seconds). Further laboratory studies demonstrated severe factor XII deficiency which was consistent on repeated testing (<1% of normal levels) but otherwise normal levels of protein S, protein C, antiphospholipid antibodies, factor VIII, von Willebrand factor, and the factor V Leiden mutation or prothrombin G20210A allele were not found.

He was fitted with Fresnel prisms to relieve his diplopia and was followed up 3 weeks later. By that time his diplopia had completely resolved and he had full abduction in both eyes.

Comment

With this recurrent and resolving pattern of cranial nerve palsy in a patient with no other risk factors for arteriosclerosis and a normal magnetic resonance image and lumbar puncture, the most likely predisposing factor in this case is his prothrombotic state associated with severe factor XII deficiency.

Severe factor XII deficiency is a genetic determinant for thrombosis.^{2,3} It is not associated with any other clinical manifestations and prolonged activated thromboplastin time is a consistent finding in any level of factor XII deficiency. The only previously reported ophthalmic complications of factor XII deficiency are two cases of central retinal vein occlusion in patients without any vasculopathic risk factors.⁵ Assay for factor XII is not routinely done on thrombophilia screening protocols. It has been suggested that the frequency of factor XII deficiency (1.5–3%)⁶ is high enough to warrant the inclusion of factor XII assays in routine thrombophilia screening.⁷ Detailed thrombophilia screening of healthy populations may produce an identifiable abnormality in 10% but clearly 10% of the population are not clinically affected in their lifetime. Therefore the need for additional management should be assessed according to the presence of concurrent risk factors in an algorithmic fashion.⁸ Since his cranial nerve palsy resolved quickly and there was no family history of vascular thrombosis he was treated empirically with aspirin, although there is no evidence to support its benefit in this condition.

**A Kipioti, O C Backhouse, P M Jacobs,
M R Howard**

Department of Ophthalmology, York District
Hospital NHS Trust, York, UK

Correspondence to: A Kipioti, Eye Department,
Clarendon Wing, Leeds General Infirmary,
LS2 9NS, UK; finakipioti@doctors.org.uk

Accepted for publication 12 August 2002

References

- 1 Lee GR. *Wintrobe's clinical haematology*. 10th ed. Philadelphia: Williams and Wilkins, 1999:688–9, 1708–9.
- 2 Halbmayer WM, Mannhalter C, Feichtinger C, et al. The prevalence of factor XII deficiency in 103 orally anticoagulated outpatients suffering from recurrent venous and/or arterial thromboembolism. *Thromb Haemost* 1992;**68**:285–90.
- 3 Mannhalter C, Fischer M, Hopmeier D, et al. Factor XII activity and antigen concentrations in patients suffering from recurrent thrombosis. *Fibrinolysis* 1987;**1**:259–63.
- 4 Zeerleder S, Schloesser M, Redondo M, et al. Reevaluation of the incidence of thromboembolic complications in congenital Factor XII deficiency—a study on 73 subjects from 14 Swiss families. *Thromb Haemost* 1999;**82**:1240–6.
- 5 Speicher L, Philipp W, Kunz FJ. Factor XII deficiency and central retinal vein occlusion. *Lancet* 1992;**340**:237.
- 6 Halbmayer WM, Haushofer A, Schon R, et al. The prevalence of moderate and severe FXII (factor XII) deficiency among the normal population: evaluation of the incidence of FXII deficiency among 300 healthy blood donors. *Thromb Haemost* 1994;**71**:68–72.
- 7 Winter M, Gallimore M, Jones DW, et al. Should factor XII assays be included in thrombophilia screening? *Lancet* 1995;**346**:52.

8 Laffan M, Tuddenham E. Assessing thrombotic risk. *BMJ* 1998;**317**:520–3.

Unilateral proptosis: the role of medical history

The most common cause of bilateral and unilateral exophthalmus among adults is Graves' disease. Unilateral exophthalmus, although frequently seen in connection with thyroid diseases, has a much larger differential diagnosis than bilateral exophthalmus. With unilateral presentation one should think of orbital pseudotumour, orbital cellulitis, cavernous sinus thrombosis, or intraorbital neoplasms.¹

Graves' ophthalmopathy (GO) usually is associated with Graves' hyperthyroidism (GH) although the temporal relation to thyroid disease is not consistent. It has been estimated that 77% of GO patients are hyperthyroid, 21% euthyroid, and 2% hypothyroid.² The mean absolute interval between GH and GO is 3.3 years in men and 3.6 years in women. Two thirds of patients present with orbital symptoms within 18 months of diagnosis of thyroid disease.³

The following cases of Graves' ophthalmopathy are described because of their unusual presentation: a long interval between thyroid disease and the development of predominantly unilateral Graves' ophthalmopathy. Both cases were seen at the department of ophthalmology of the University Hospital Groningen, Netherlands.

Case 1

A female patient born in 1922 became hyperthyroid with minimal eye signs with possibly some lid retraction in 1948. She was treated by thyroidectomy and became clinically euthyroid. In 1980 her thyroid function and antibodies were tested because of complaints of dizziness. Thyroid hormones were within normal ranges and thyroperoxidase (TPO) colloid and antiparietal cell antibodies (APCA) were negative.

In January 1983 she presented with complaints of sharp pains in both eyes, a feeling of pressure, and an exophthalmus of her right eye. On ocular examination there were no abnormalities except for exophthalmus of the right eye. Hertel exophthalmometer values were 24 mm right eye and 19 mm left eye. In December 1983 signs and symptoms worsened. Examination at that time showed an obvious retraction of the upper eyelid of the right eye. The exophthalmus was stable. There was diplopia caused by a right hypotropia in primary position of 1.5 degrees with restriction of elevation. A computed tomograph (CT) scan showed enlargement of all external eye muscles of the right eye without involvement of the tendons. During this exacerbation laboratory testing showed thyroid hormone levels within normal ranges and again TPO and colloid antibodies tests were negative. The diplopia resolved without treatment.

Case 2

A male patient born in 1944 was diagnosed with hypothyroidism in 1979. Thyroid hormones were abnormal. FT4 was decreased, TSH was increased, antibodies against colloid were positive, and APCA and TPO antibodies were negative. Because of this primary hypothyroidism levothyroxine therapy was started and he gradually became euthyroid. His ocular history mentioned a disorder of the central retinal pigment epithelium and glaucoma which was treated with timolol.

In August 2000 he presented with unilateral proptosis and progressive loss of vision. Ocular examination showed chemosis and oedema of the eyelids in both eyes. Visual acuity was 20/60 right eye and 20/30 left eye. Pupillary reflexes were normal and symmetrical. Clinically and biochemically he presented as euthyroid. A CT scan showed bilateral enlargement of the eye muscles, more marked on the right side. He was treated with 60 mg prednisone daily.

One month later visual acuity of the right eye dropped further and he was referred to our hospital. Ocular examination showed marked soft tissue signs, worse in the right eye, bilateral chemosis, and unilateral exophthalmus of 26 mm in the right eye. Visual acuity was reduced to counting fingers in the right eye. Colour vision was diminished and there was a relative afferent pupillary defect in the right eye. He had restrictions of the eye movements of the right eye when looking upwards, downwards, and in adduction. Thyroid hormone levels were again within normal ranges. He was admitted and methylprednisone 250 mg four times a day intravenously and radiotherapy (10 × 2 Gy) were started. Antibody testing showed borderline thyroglobulin and TPO antibody titres. Results of TSH receptor antibody testing could not be traced.

As visual function was not restored within a reasonable time another CT scan was performed which showed enlargement of all recti muscles of right eye and in lesser extent of the left eye with signs of compression of the right optic nerve. An orbital decompression through a Caldwell-Luc approach was performed on the right side. Postoperatively, visual acuity of the right eye improved to 20/30 and proptosis in the right eye was reduced by 8 mm. A strabismus convergens of the right eye was the main side effect.

In April 2001 a bilateral medial recession and a recession of the inferior rectus of the right eye were performed to treat the strabismus convergens. Binocular single vision was achieved in the primary position with some diplopia at extremes of gaze.

Comment

Unilateral proptosis as a result of Graves' disease cannot be rejected as a diagnosis, even 20 or 30 years after the onset of thyroid disease. Only one retrospective study among 557 patients mentioned intervals up to 25 years without giving exact numbers and underlying thyroid disease.³ For hypothyroidism and GO one study suggests intervals exceeding 15 years.⁴

Thyroid hormone testing should be performed to rule out abnormalities in thyroid hormone levels although thyroid status does not seem important as the active phase of ophthalmopathy can occur during hyperthyroidism, hypothyroidism, and euthyroidism.⁴ Thyroid antibody testing may be supportive for the diagnosis. A CT scan can be essential in further analysis showing enlargement of extraocular muscles with sparing of the tendons.³ It is also known that a CT scan can demonstrate contralateral eye muscle involvement in 50–90% of patients with clinically unilateral eye involvement.⁶

Our two patients illustrate that the medical history is important in evaluating proptosis. One should always think of Graves' disease as a possible cause of unilateral exophthalmus even though a patient may have had thyroid disease more than 20 years earlier.

N Kamminga, N M Jansonius, J W R Pott
Department of Ophthalmology, University Hospital
Groningen, Netherlands

T P Links
Department of Endocrinology

Correspondence to: Jan W R Pott, P O Box 30 001
Groningen, 9700 RB, Netherlands;
j.w.r.pott@ohk.azg.nl

Accepted for publication 14 August 2002

References

- 1 **Kennerley Bankes JL.** *Clinical ophthalmology. A text and colour atlas.* 3rd ed. London: Churchill Livingstone, 1994:94–101.
- 2 **Prummel MF.** Medical management of Graves' ophthalmopathy. Thesis. University of Amsterdam, 1992:7–38.
- 3 **Kendler DL, Lippa J, Rootman J.** The initial clinical characteristics of Graves' orbitopathy vary with age and sex. *Arch Ophthalmol* 1993;**111**:197–201.
- 4 **Brownlie BEW, Newton OAG, Singh SP.** Ophthalmopathy associated with primary hypothyroidism. *Acta Endocrinol* 1975;**79**:691–9.
- 5 **Trokel SL, Jakobiec FA.** Correlation of CT-scanning in pathological features of ophthalmic Graves' disease. *Ophthalmology* 1981;**88**:553–64.
- 6 **Burch HB, Wartofsky L.** Graves' ophthalmopathy: current concepts regarding pathogenesis and management. *Endocr Rev* 1993;**14**:747–93.

Unusual presentation of cat scratch disease in HIV+ patient

Intraocular cat scratch disease may present with different clinical features including neuroretinitis, retinitis, retinal infiltrates, arterial and vein occlusions. Most of the cases show spontaneous recovery without therapy.¹

There are only few reports of intraocular cat scratch disease in HIV+ patients. We report an unusual case of cat scratch disease presenting as helioid unifocal choroiditis in an HIV+ patient that showed good response to systemic therapy.

Case report

A 30 year old homosexual HIV+ man was referred to the uveitis department complaining of blurred vision in the left eye. He was taking zidovudine, lamivudine, ritonavir, and saquinavir. His last CD4+ count was 128 cells $\times 10^6/l$ and viral load 1 300 000.

His visual acuities were 6/6 in the right eye and counting fingers in the left. There was no inflammation in the anterior chambers or in the vitreous. Ophthalmoscopy revealed a

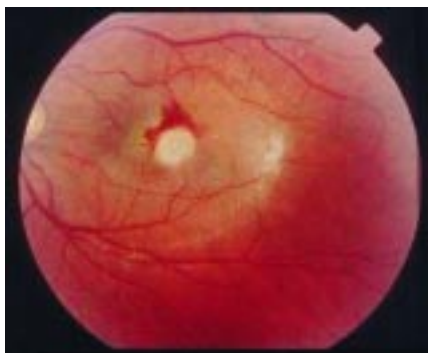

Figure 1 Fundus photograph of yellowish chorioretinal lesion surrounded by fluid and haemorrhages.

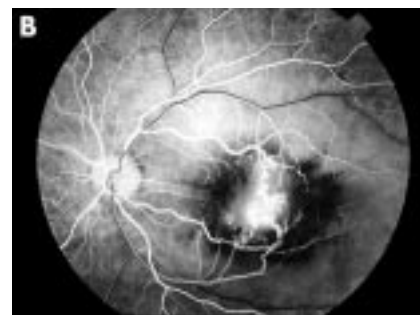
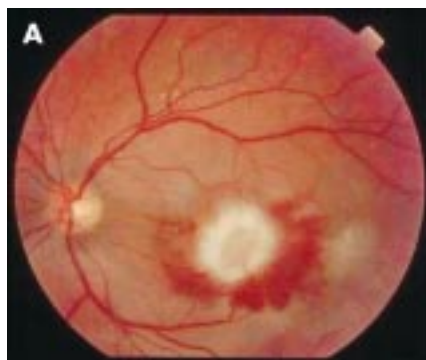
Figure 2 (A) Fundus photograph at second visit, yellowish lesion increased. (B) Arteriovenous phase fluorescein angiogram showing an angiomatous-like lesion.

yellowish choroidal lesion surrounded by fluid and haemorrhages in the macula of the left eye (Fig 1). Fluorescein angiography showed an angiomatous lesion corresponding to those seen clinically. Blood tests were ordered including VDRL, toxoplasmosis serology, Lyme disease serology, ELISA for toxocarasis and were all negative. Computed tomography (CT) scan and serum studies were unremarkable. Blood sample was sent to CDC Atlanta for *Bartonella* serology. Since clinical diagnosis was cat scratch disease and most patients show good recovery without treatment we decided not to treat before results of blood tests. We kept examining the patient every week with ophthalmoscopy and fluorescein angiography (Fig 2A, B). The lesion progressively increased in size but he did not show visual acuity deterioration.

A month after presentation the lesion had increased and four small lesions appeared in the right eye. His visual acuity dropped to hand movements. Although we did not have the results of *Bartonella* serology, we decided to give him ciprofloxacin. *Bartonella henselae* serology was positive for IgG, 1:256, and IgM negative.

Fifteen days after treatment was started the lesions in the right eye disappeared and the macular lesion in the left eye resolved completely.

Comment

There is a well established association between neuroretinitis and cat scratch disease although many different clinical presentations have been described.¹ Ormerod *et al*¹ described two patients with small areas of retinitis and arteriolar occlusions. Pollock and Kristinsson² described one patient with cat scratch disease and helioid unifocal choroiditis. Hong *et al*³ first described this syndrome when they reported six young patients with a solitary round yellow chorioretinal lesion associated with subretinal fluid. There was no association with inflammatory or infectious diseases. Fish *et al*⁴ reported a case of peripapillary angiomatosis associated with neuroretinitis. Our patient presented with clinical features of helioid unifocal choroiditis but after angiogram we could see an angiomatous-like lesion.

The treatment of ocular cat scratch disease remains controversial. Pollock and Kristinsson² reported a case that improvement in visual acuity from 6/12 to 6/6 occurred after 3 weeks without treatment. One of the cases described by Ormerod showed some benefit after treatment although his recovery was very slow. The second patient showed improvement without treatment. Warren *et al*⁵ reported an HIV+ patient

with cat scratch disease whose lesion enlarged without treatment. Once the diagnosis of *Bartonella* was confirmed by polymerase chain reaction of the retina sample, the patient was started on systemic antibiotics with good results. Considering that spontaneous recovery could occur we decided not to treat until our patient showed deterioration in the left eye and involvement in the fellow eye.

Ophthalmologists should be aware of this unusual presentation of cat scratch disease with helioid unifocal choroiditis and angiomatous-like lesions. Although larger series and control studies are needed, HIV+ patients with intraocular manifestations of cat scratch disease may benefit from systemic treatment with antibiotics.

A L L Curi, W R Campos, L Barbosa, M A Lana-Peixoto, F Oréfice

Federal Fluminense University/Federal University of Minas Gerais, Brazil

Correspondence to: Dr Andre Luiz Landi Curi, R Francisco Dutra, 163/701 Icaraí Niterói, RJ, 24220-150, Brazil; curiall@yahoo.com

Accepted for publication 18 August 2002

References

- 1 **Ormerod LD, Skolnick KA, Menosky MM, et al.** Retinal and choroidal manifestation of cat-scratch disease. *Ophthalmology* 1998;**105**:1024–31.
- 2 **Pollock SC, Kristinsson J.** Cat-scratch disease manifesting as helioid unifocal choroiditis. *Arch Ophthalmol* 1998;**116**:1249–50.
- 3 **Hong PH, Jampol LM, Dodwell DG, et al.** Unifocal helioid choroiditis. *Arch Ophthalmol* 1997;**115**:1007–13.
- 4 **Fish RH, Hogan RN, Nightingale SD, et al.** Peripapillary angiomatosis associated with cat-scratch neuroretinitis. *Arch Ophthalmol* 1992;**110**:323.
- 5 **Warren K, Goldstein E, Hung VS, et al.** Use of retinal biopsy to diagnose *Bartonella* (Formerly *Rochalimaea*) *henselae* retinitis in an HIV-infected patient. *Arch Ophthalmol* 1998;**116**:937–40.

Simultaneous translocation of the macula and underlying retinal pigment epithelium during macular translocation surgery in a patient with long standing myopic neovascular maculopathy

Limited macular translocation has been reported to be a promising treatment for some patients with choroidal neovascularisation.^{1–4} Although this technique has the advantage of being less invasive, there is documentation of

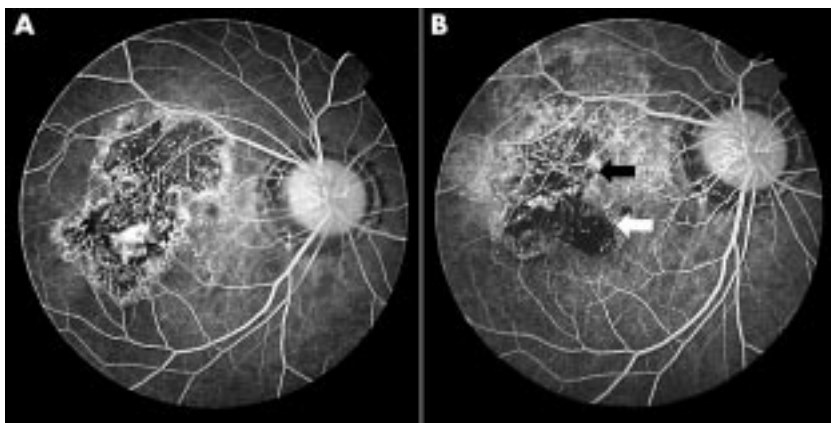


Figure 1 (A) A preoperative fluorescein angiogram shows myopic choroidal neovascularisation with marked atrophy of the surrounding retinal pigment epithelium. An area of relatively healthy retinal pigment epithelium is shown inferonasal to the fovea. (B) A fluorescein angiogram taken 3 months after the surgery demonstrates a sharply delineated blockage of choroidal fluorescence in the translocated macular area (white arrow). The original macular area shows hypofluorescence with larger choroidal vessels well visualised (black arrow). This finding may indicate that the retinal pigment epithelium of the original macular region has been torn away and subsequent atrophy of the underlying choriocapillaris has occurred.

various complications that have been experienced with its use.⁵⁻⁸ In this report, we describe an unusual complication associated with limited macular translocation in a patient with long standing choroidal neovascularisation.

Case report

A 35 year old woman was referred to our department because of a gradual decrease in visual acuity in her right eye. At the first visit, her best corrected visual acuity was right eye, 20/40, with a refractive error of -17.5 dioptres in the spherical equivalent. Clinical and angiographic examinations showed a juxtafoveal choroidal neovascularisation. During the subsequent follow up period, choroidal neovascularisation and surrounding retinal pigment epithelial atrophy gradually expanded and involved the subfoveal region (Fig 1A). We gave the patient detailed information on the available therapeutic options, including macular translocation, but she chose conservative follow up rather than surgical intervention. Three years after her first visit, the visual acuity in her right eye worsened to 20/100. At that time, the patient decided to have surgical treatment. With her consent, limited macular translocation was performed on her right eye, as described previously.⁴ Postoperatively, fluorescein angiography

showed an extrafoveal neovascular membrane with a foveal shift of 0.7 disc diameter (Fig 1B). Sharply demarcated hypofluorescence in the macular area was also demonstrated. Biomicroscopic examination revealed a slightly hyperpigmented lesion underneath the translocated macula, which corresponded to the area of hypofluorescence. A horizontal optical coherence tomography (Humphrey Systems, San Leandro, CA, USA) section taken through the translocated macula displayed highly reflective double layers (Fig 2A). These findings may indicate that the abnormal subfoveal retinal pigment epithelium, which adhered tightly to the overlying neurosensory retina, probably because of the long history of neovascular maculopathy, was translocated with the macula during surgery. Two reflective bands observed on an optical coherence tomography image may have corresponded to the native retinal pigment epithelium and abnormal retinal pigment epithelium translocated with the macula. Indocyanine green angiography findings supported this speculation (Fig 2B).

Despite sufficient foveal displacement, the patient's visual acuity has not improved. During a follow up period of 15 months, it has remained at the same level as her preoperative vision.

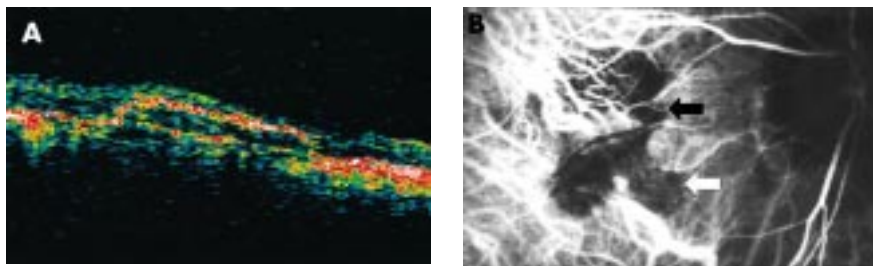


Figure 2 (A) A horizontal optical coherence tomography section taken through the translocated macula displays highly reflective double layers underneath the fovea that probably correspond to the native retinal pigment epithelium and simultaneously translocated retinal pigment epithelium. (B) A postoperative indocyanine green angiogram shows well visualised larger choroidal vessels in the original macular area probably caused by the absence of the retinal pigment epithelium-choriocapillaris complex (black arrow). The relative hypofluorescence in the translocated macular area may represent blockage of choroidal fluorescence by the translocated retinal pigment epithelium (white arrow).

Comment

In many eyes with choroidal neovascularisation, the macula can easily be separated from the subjacent fibrovascular tissue. In some eyes with long standing choroidal neovascularisation, however, the outer portion of neurosensory retina may adhere firmly to the subjacent tissue. In such cases, an inner portion of fibrovascular tissue may be torn off and translocated with overlying neurosensory retina during macular translocation. The underlying healthy retinal pigment epithelium covered with the translocated abnormal tissue may not be able to fulfil its physiological roles on the overlying neurosensory retina, and good functional recovery of the translocated macula is unlikely to be achieved. As documented here, simultaneous translocation of the underlying abnormal retinal pigment epithelium associated with long standing choroidal neovascularisation can occur during limited macular translocation and result in an unsatisfactory visual outcome. When patients are deciding whether to consent to surgical intervention with limited macular translocation in such cases, they should be informed of the benefits and risks of the treatment, with due consideration of this complication.

M Ichibe, K Imai, M Ohta, Y Oya, T Yoshizawa, H Abe

Department of Ophthalmology, Niigata University School of Medicine, Niigata, Japan

Correspondence to: Dr Ichibe, Department of Ophthalmology, Niigata University School of Medicine, 1-757 Asahimachi, Niigata 951-8510, Japan; ichibem@med.niigata-u.ac.jp

Accepted for publication 22 August 2002

References

- 1 De Juan E Jr, Loewenstein A, Bressler NM, et al. Translocation of the retina for management of subfoveal choroidal neovascularization. II: a preliminary report in humans. *Am J Ophthalmol* 1998;**125**:635-46.
- 2 Fujikado T, Ohji M, Saito Y, et al. Visual function after foveal translocation with scleral shortening in patients with myopic neovascular maculopathy. *Am J Ophthalmol* 1998;**125**:647-56.
- 3 Fujii GY, Humayun MS, Pieramici DJ, et al. Initial experience of inferior limited macular translocation for subfoveal choroidal neovascularization resulting from causes other than age-related macular degeneration. *Am J Ophthalmol* 2001;**131**:90-100.
- 4 Ichibe M, Imai K, Ohta M, et al. Foveal translocation with scleral imbrication in patients with myopic neovascular maculopathy. *Am J Ophthalmol* 2001;**132**:164-71.
- 5 American Academy of Ophthalmology. Macular translocation. *Ophthalmology* 2000;**107**:1015-18.
- 6 Fujii GY, Pieramici DJ, Humayun MS, et al. Complications associated with limited macular translocation. *Am J Ophthalmol* 2000;**130**:751-62.
- 7 Fujii GY, De Juan E Jr, Zarbin MA, et al. Unintentional transplantation of autologous retinal pigment epithelium during limited macular translocation. *Retina* 2001;**21**:380-2.
- 8 Ohji M, Fujikado T, Kusaka S, et al. Comparison of three techniques of foveal translocation in patients with subfoveal choroidal neovascularization resulting from age-related macular degeneration. *Am J Ophthalmol* 2001;**132**:888-96.

Fungal and bacterial chronic endophthalmitis following cataract surgery

Endophthalmitis, although rare, is one of the most vision threatening complication of cataract surgery. The majority of these infections

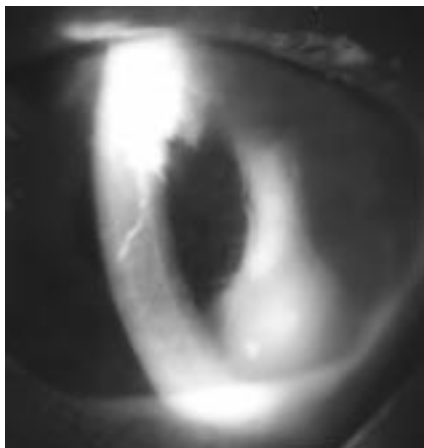


Figure 1 Anterior segment photograph of the left eye showing a hypopyon and a crystalline keratopathy.

are bacterial in the Western world. The occurrence of fungal endophthalmitis after cataract surgery is rare as well as polymicrobial infections.¹

We report a case of chronic postoperative endophthalmitis caused by bacterial and fungal pathogenic agents.

Case report

A 73 year old woman was referred for pain and redness in the left eye. Her past history was remarkable for an extracapsular cataract extraction in the left eye with a posterior chamber intraocular lens implant that had been performed in Turkey in 1998. The patient had recurrent episodes of decreased vision and ocular pain in the postoperative course and was treated with peribulbar injections of corticosteroids over 2 years. On presentation, visual acuity was hand movements in the left eye. Slit lamp examination of the left eye showed a white corneal infiltrates involving the superior and nasal quadrant (Fig 1). There was a moderate anterior chamber reaction and a 1 mm hypopyon. The implant was in good position and no residual cortical material was seen. The vitreous showed 2+ cells. Intraocular pressure was normal. Examination of the right eye was normal except for a mild nuclear cataract. The diagnosis of chronic infectious endophthalmitis was suspected.

The aqueous cultures were sterile for bacteria and fungi. Intravitreal injections of vancomycin and amikacin were performed. Postoperatively, the patient was given intravenous ciprofloxacin, piperillin, and topical fortified ticarcillin, gentamicin, and vancomycin drops. The eye showed no improvement during the next 3 weeks and the patient subsequently underwent removal of the implant and capsular bag which grew *Candida parapsilosis*, *Corynebacterium striatum*, and *Staphylococcus epidermidis*.

Intravitreal injection of amphotericin B (5 µg, weekly), topical amphotericin B (7 mg/ml eye drops every 2 hours), and oral fluconazole (400 mg a day) were then added to the patient's regimen. A decrease in intraocular inflammation and corneal infiltrates was noted after 1 month of treatment that was stopped by the patient. Six months later, visual acuity of the left eye was no light perception and biomicroscopic examination showed panophthalmitis. The patient refused medical treatment and enucleation was performed.

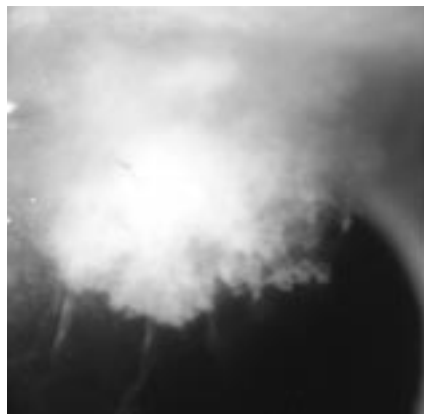


Figure 2 Higher magnification showing crystalline keratopathy.

Comment

Species of candida, other than *Candida albicans*, are normal flora of cutaneous and mucocutaneous surfaces and are only rarely incriminated as agents of clinical disease in immunocompetent hosts. *Candida parapsilosis* is in fact one of the most common fungi cultured from the normal human external eye.² However, it can cause infectious crystalline keratopathy or, more typically, suppurative stromal keratitis. *Candida parapsilosis* has also been reported as a cause of small epidemics of postoperative endophthalmitis.³ In the present case, *Candida parapsilosis* could be considered as a true pathogenic organism because of its localisation, in the capsular bag, and also because antifungal therapy was effective.

On the other hand, *Staphylococcus* and *Corynebacterium* species are frequently identified in postoperative endophthalmitis.¹

This case is, to our knowledge, the first documented report of bacterial and fungal endophthalmitis following cataract surgery. The use of broad spectrum antibiotics, the administration of steroids, and the increased number of patients with local or systemic immunosuppression could explain the development of such infections which are frequent in post-traumatic endophthalmitis but extremely rare after cataract surgery.^{1,4} However, cross contamination by hospital personnel may also account for increase in yeast infections in certain environments. A recent survey of hospital personnel revealed that 70% of nurses and non-nursing hospital personnel carried yeasts on their hands, particularly subungual spaces, with *Candida parapsilosis* being those most frequently recovered.⁵

This case demonstrates the atypical presentation and the poor prognosis of polymicrobial endophthalmitis. Identification of all the organisms is essential before the onset of therapy, emphasising the need for complete microbiological evaluation of any postoperative endophthalmitis.

T Bourcier, S Scheer, C Chaumeil, C Morel, V Borderie, L Laroche

Quinze-Vingts National Center of Ophthalmology, Paris, France

Correspondence to: Tristan Bourcier; bourcier@quinze-vingts.fr

Accepted for publication 28 August 2002

References

- 1 **Kunimoto DY**, Das T, Sharma S, *et al*, and the Endophthalmitis Reseach Group.

Microbiologic spectrum and susceptibility of isolates: Part I. Postoperative endophthalmitis. *Am J Ophthalmol* 1999;**128**:240–2.

- 2 **Weems JJ Jr**. *Candida parapsilosis*: epidemiology, pathogenicity, clinical manifestations, and antimicrobial susceptibility. *Clin Infect Dis* 1992;**14**:756–66.
- 3 **Fox GM**, Joondeph BC, Flynn HW Jr, *et al*. Delayed-onset pseudophakic endophthalmitis. *Am J Ophthalmol* 1991;**111**:163–73.
- 4 **Kunimoto DY**, Das T, Sharma S, *et al*, and the Endophthalmitis Reseach Group. Microbiologic spectrum and susceptibility of isolates: Part II. Posttraumatic endophthalmitis. *Am J Ophthalmol* 1999;**128**:242–4.
- 5 **Strausbaugh LJ**, Sewell DL, Ward TT, *et al*. High frequency of yeast carriage on hands of hospital personnel. *J Clin Microbiol* 1994;**32**:2299–300.

MAILBOX

If you have a burning desire to respond to a paper published in the *BJO*, why not make use of our "rapid response" option?

Log on to our website (www.bjophthalmol.com), find the paper that interests you, and send your response via email by clicking on the "eLetters" option in the box at the top right hand corner.

Providing it isn't libellous or obscene, it will be posted within seven days. You can retrieve it by clicking on "read eLetters" on our homepage.

The editors will decide as before whether to also publish it in a future paper issue.

Surgical performance for specialties undertaking temporal artery biopsies: who should perform them?

We read with interest the paper by Galloway and colleagues which suggests that ophthalmologists are best suited to perform temporal artery biopsies.¹ We recently completed a retrospective study of all the temporal artery biopsies performed at four teaching hospitals (Hammersmith Hospital, Charing Cross Hospital, St Mary's Hospital and The Western Eye Hospital) in north London between January 1998 and January 2002. Ninety one patients underwent 92 biopsies. Of these, 15 were positive for temporal arteritis implying a 16% positive biopsy rate which is compatible with Galloway *et al's* results. Ophthalmologists performed 54 biopsies (59%) while general and vascular surgeons (GVS) performed 38 biopsies (31%). Both groups had similar positive biopsy rates—ophthalmologists 10/54 (19%) and GVS 5/28 (13%). In an analysis of the ability to perform biopsies, the ophthalmologists had two failed biopsies (one specimen—no artery identified and one specimen—crushed artery) while the GVS group had one failed biopsy (no artery identified). The average artery length was 13.0 mm (range 5–21 mm) for the ophthalmologists and 14.0 mm (range 7–22 mm) for the GVS group.

We disagree with Galloway and colleagues' assertions that ophthalmologists are best suited to performing temporal artery biopsies as our study found that both groups of

surgeons obtained similar lengths of artery and had similar positive biopsy rates. We note that in their study, while the vascular surgeons only performed two of the 41 biopsies, the average length of specimen obtained was 22.5 mm, thus suggesting that the vascular surgeons may well be the best group to perform these biopsies. In Charing Cross Hospital, the vascular surgeons routinely use a Doppler ultrasound probe to help detect and demarcate the superficial temporal artery before biopsy and this practice has been advocated by other studies to help improve the yield of the biopsy.^{2,3} In our study, all the biopsies performed by ophthalmologists were done as extra cases in theatre and seven cases had to be performed outside normal working hours as emergencies because of lack of theatre time. The fact that ophthalmologists performed 59% of biopsies may be due to the fact that all four hospitals had large neurological and rheumatological units attached to them. We feel that both ophthalmologists and general and vascular surgeons are equally capable of performing temporal artery biopsies and that guidelines should be designed locally to decide who should perform the biopsies. More importantly, the follow up of these patients should be clearly stated and be ideally under the care of the rheumatologists.

K Fong, V Ferguson

The Western Eye Hospital, Marylebone Road, London NW1 5YE

Correspondence to: Dr Kenneth Fong; fongcsk@yahoo.co.uk

References

- 1 **Galloway GD**, Klebe B, Riordan-Eva P. Surgical performance for specialties undertaking temporal artery biopsies: who should perform them? *Br J Ophthalmol* 2002;**86**:250.
- 2 **Brosig J**, Holtkamp A, Clemens S. Possibilities and limits in the imaging of extracranial vessels with conventional ultrasonography. *Klin Monatsbl Augenheilkd* 1997;**211**:301–5.
- 3 **Hunder GG**, Weyand CM. Sonography in giant-cell arteritis. *N Engl J Med* 1997;**337**:1385–6.

Major complications of endoscopic sinus surgery: a comment

We were pleased to read the informative article by Rene *et al.*¹ The authors refer to "Ododi cells" as, "aerated posterior ethmoid air cells along the optic canal." Could it be that they meant to refer to the cells as "Onodi cells"? Onodi described a number of variations of posterior ethmoid anatomy.² Endoscopic sinus surgeons refer to the pattern of extracranial pneumatization of the ethmoid lateral or superolateral to the sphenoid, where the posterior ethmoid is indented by the optic canal, as an Onodi cell.³ More recently it has been suggested that this cell is better characterised as a "sphenoidal" cell.⁴

The main significance of the Onodi or sphenoidal cell is that while sinus surgeons expect to find the optic nerve in the sphenoid sinus, they are not routinely looking for it in the posterior ethmoid. Consequently, the chance of iatrogenic injury is likely to be higher in patients with Onodi cells and even higher in patients with extensively pneumatized Onodi cells.⁵ The exact incidence of Onodi cells is unclear. Endoscopic dissection studies suggest an incidence as high as 39%⁵ or 42%.³ CT imaging studies suggest a lower incidence of 7%.⁵ Driben *et al*⁶ feel that the

likelihood of a sphenoidal cell increases with increasing obliquity of the anterior sphenoid wall. Racial factors may also have a role as Onodi cells appear to be more common in Asian patients.⁶

Every effort should be made to identify sphenoidal cells preoperatively and to be aware of intraoperative clues such as anterior sphenoid wall alignment, which may point to the presence of an Onodi cell. Attention to these important details will increase the likelihood of uncomplicated endoscopic sinus surgery at the sphenoidal junction.

S M Graham

Department of Otolaryngology-Head and Neck Surgery

K D Carter

Oculoplastic and Orbital Service, Department of Ophthalmology and Visual Sciences, University of Iowa, Iowa City, IA, USA.

Correspondence to: Scott M Graham, MD, University of Iowa Hospitals and Clinics, Department of Otolaryngology-Head and Neck Surgery, 200 Hawkins Drive, 21201 PFP, Iowa City, IA 52242-1093, USA; scott-graham@uiowa.edu

References

- 1 **Rene C**, Rose GE, Lenthal R, *et al.* Major orbital complications of endoscopic sinus surgery. *Br J Ophthalmol* 2001;**85**:598–603.
- 2 **Onodi A**. The optic nerve and the accessory sinuses of the nose: a contribution of canalicular neuritis and atrophy of the optic nerve of nasal origin. *Ann Otol Rhinol Laryngol* 1908;**17**:1–116.
- 3 **Kainz J**, Stammberger H. Danger areas of the posterior rhinobasis: an endoscopic and anatomical surgical study. *Acta Otolaryngol* 1992;**112**:852–61.
- 4 **Kennedy DW**. International conference on sinus disease: terminology, staging, therapy. *Ann Otol Rhinol Laryngol* 1995;**104**(suppl 167):7–16.
- 5 **Driben JS**, Bolger WE, Robles HA, *et al.* The reliability of computerized tomographic detection of the Onodi (sphenoidal) cell. *Am J Rhinol* 1998;**12**:105–11.
- 6 **Yeoh KH**, Tan KK. The optic nerve in the posterior ethmoid in Asians. *Acta Otolaryngol (Stockh)* 1994;**114**:329–36.

Trabeculectomy augmented with antimetabolites with a viscocanalostomy technique for the management of open angle glaucoma

In a small randomised, prospective study, O'Brart and co-workers¹ attempted to prove that trabeculectomy (n=25) provided better intraocular pressure (IOP) control than viscocanalostomy (n=23). However, we have serious concerns about the methodology of this study that need to be addressed.

Viscocanalostomy is characterised by the injection of viscoelastic into Schlemm's canal.² However, this was not performed in half of the patients randomised to this group. This would be as inappropriate as using an antimetabolite in only half the patients in the trabeculectomy group, and then comparing this entire group to the viscocanalostomy group. Although the authors do state that the subgroup of patients with intracanalicular viscoelastic injection was inferior to trabeculectomy, this cohort consisted only of 12 patients and it is not known how many had completed follow up after 18 months. Surely, these small numbers are insufficient to draw such conclusions.

We are also concerned that the use of intraoperative antimetabolites in the trabeculectomy group added a major confounding variable in this study. This is particularly perplexing as the authors' viscocanalostomy technique primarily relied on subconjunctival filtration, as evidenced by their triangular scleral flap design and looser suturing technique in which only three 10/0 nylon sutures were used. Furthermore, their excellent early success rate of viscocanalostomy (95% at 6 months), the presence of filtering blebs in their successful viscocanalostomy procedures, the lack of one in their failures, and the need for postoperative bleb needling and 5-fluorouracil injections all indicate this. The use of mitomycin-C and 5-fluorouracil improves the success rate of glaucoma filtering surgery by reducing episcleral fibrosis,³ and probably explains the difference in success rates in this study. We wonder what the results would have been had the use of intraoperative antimetabolites been used in all groups, or if none was used at all.

In contrast with the authors' technique, we employ Stegmann's approach to viscocanalostomy in using a parabolic superficial flap secured tightly with five sutures in a relatively water tight fashion.² Although low lying blebs may develop, most patients achieve IOP lowering through multiple alternate pathways including uveoscleral, through Schlemm's canal, and subconjunctival.⁴ Certainly in higher risk cases, we feel that there is a role for antimetabolites in non-penetrating surgery, and have found it to be safer than when used with trabeculectomy.

It should be mentioned that quite often we do rely on subconjunctival filtration in non-penetrating procedures (that is, deep sclerectomy) but advocate the use of a collagen wick⁵ or hyaluronic acid⁶ implant with an intraoperative antimetabolite in higher risk cases to obtain optimal IOP control.

Fibrosis and loss of permeability of the trabeculo-Desemet's window (TDW) is a well described cause of postoperative elevation in IOP after non-penetrating glaucoma surgery. Postoperative Nd:YAG goniopuncture of the TDW in these cases is a relatively easy adjunctive procedure and may be needed in up to 41% of non-penetrating procedures.⁷ It has been reported to successfully lower postoperative IOP in over 80% of cases.⁷ Yet, we are dismayed that the authors decided not to attempt laser goniopuncture in those viscocanalostomy cases with postoperative IOP elevations because "such interventions clearly convert a 'non-penetrating' technique into a penetrating, full thickness procedure." We vehemently disagree with this line of reasoning as we feel goniopuncture is an extremely useful adjunctive procedure and converting to a penetrating (not "full thickness") procedure in the safety of the controlled postoperative period is completely reasonable. This is akin to suture lysis in trabeculectomy. Would the authors feel that performing suture lysis constitutes conversion of a guarded trabeculectomy into a full thickness unguarded trabeculectomy and thus cannot be fairly compared? Although goniopuncture was performed in only three eyes at 18 months, we wonder what results would have been obtained if this was done in all cases with uncontrolled IOPs at any point in the postoperative period.

Although we are critical of this study, we applaud O'Brart and colleagues for attempting to investigate this evolving area of glaucoma surgery. Although they may have shown that trabeculectomy with the use of an antimetabolite is superior to a modified form

of viscocanalostomy dependent on subconjunctival filtration without the use of an antimetabolite, this study unfortunately does not fairly compare the efficacy of Stegmann's viscocanalostomy technique versus trabeculectomy. Non-penetrating glaucoma surgery certainly has an improved safety profile and surely as future well designed controlled studies become available, the efficacy of these procedures compared to trabeculectomy will become clearer.

I I K Ahmed, C Kranemann

University of Toronto, Toronto, Ontario, Canada

Correspondence to: I I K Ahmed, 43 Bywood Drive, Toronto, Ontario M9A 1M1; ike.ahmed@utoronto.ca

References

- 1 **O'Brart DPS**, Rowlands E, Islam N, *et al.* A randomised, prospective study comparing trabeculectomy augmented with antimetabolites with a viscocanalostomy technique for the management of open angle glaucoma uncontrolled by medical therapy. *Br J Ophthalmol* 2002;**86**:748–54.
- 2 **Stegmann R**, Pienaar A, Miller D. Viscoanalostomy for open-angle glaucoma in black African patients. *J Cataract Refract Surg* 1999;**25**:316–22.
- 3 **Skuta GL**, Beeson CC, Higginbotham EJ, *et al.* Intraoperative mitomycin-C versus postoperative 5-fluorouracil in high-risk glaucoma filtering surgery. *Ophthalmology* 1992;**99**:438–44.
- 4 **Chiou A**, Mermoud A, Underdahl JP, *et al.* An ultrasound biomicroscope study of eyes after deep sclerectomy with collagen implant. *Ophthalmology* 1998;**105**:746–50.
- 5 **Mermoud A**, Schnyder CC, Sickenberg M, *et al.* Comparison of deep sclerectomy with collagen implant and trabeculectomy in open-angle glaucoma. *J Cataract Refract Surg* 1999;**25**:323–31.
- 6 **Sourdille P**, Santiago P-Y, Villain F, *et al.* Reticulated hyaluronic acid implant in nonpenetrating trabeculectomy. *J Cataract Refract Surg* 1999;**25**:332–9.
- 7 **Mermoud A**, Karlen ME, Schnyder CC, *et al.* Nd:YAG goniopuncture after deep sclerectomy with collagen implant. *Ophthalmic Surg Lasers* 1999;**30**:120–5.

Argon laser and trichiasis

We were interested to read the approach taken by Sahni and Clark¹ to facilitate the effective argon laser treatment of trichiasis. They have ably reviewed the complications of trichiasis, the different forms of management of trichiasis, the advantages of argon laser treatment in the management of trichiasis, the technique of argon laser trichiasis therapy, and the limitations of lash laser therapy.

We take issue with the authors in two areas. Firstly, the almost certain consequence of using a duration of laser treatment of 0.1 second is that if the laser “takes,” the lash will disappear within the space of a few laser shots, effectively precluding the destruction of that particular lash follicle. We have particularly made it a point that when teaching trainees the technique of lash laser, we ensure that the energy burst lasts long enough to commence visible lash destruction as well as destruction of the subcutaneous lash, as the burn is directed towards the lash follicle. Thus we always use a duration of several seconds, or even continuous energy, and aim to achieve initiation of effective lash destruction above the lid level after the first shot, or certainly within three shots. Thus, 1–3 second duration bursts may be required, depending on the individual lash. Just a few more shots will effectively and completely destroy the subcutaneous lash and its follicle.

Secondly, the article by Bartley and Lowry quoted by the authors, describes using a “drop of ink from a fountain pen” to facilitate lash laser.² Presumably in the interests of sterility, Sahni and Clark have used the ink from a “blue skin marker pen” to allow improved absorption of argon laser energy. While use of a fresh marker pen for each patient may be relatively efficient, it could not be regarded as cost effective. By contrast, in a procedure described by us in 1994,³ we found that transferring a tiny drop of the patient's own blood, whether still liquid or already coagulated, to the lash base on the lid margin is a simple, rapid, cheap, safe, and highly effective method of getting the laser reaction started when the lashes are pale. We have found that the required amount of blood is invariably present on the patient's own lid skin at the site of local anaesthetic infiltration. We usually transfer it by picking it up with a sterile drawing up needle. This is achieved remarkably easily on the laser slit lamp, which allows adequate magnification for the accurate siting of the transferred blood.

G A Wilcsek, I C Francis

The Ocular Plastics Unit, Prince of Wales Hospital, and the University of New South Wales, Randwick, Sydney, Australia

Correspondence to: Ian C Francis; if@student.unsw.edu.au

References

- 1 **Sahni J**, Clark D. Argon laser and trichiasis: a helpful tip. *Br J Ophthalmol* 2001;**85**:761.
- 2 **Bartley GB**, Lowry JC. Argon laser treatment of trichiasis. *Am J Ophthalmol* 1992;**113**:71–4.
- 3 **Ghabrial R**, Francis IC, Kappagoda MB. Autologous blood facilitation of lid laser treatment. *Aust NZ J Ophthalmol* 1994;**22**:218.

Management of age related macular degeneration: still room for improvement

The aim of Mitchell *et al*'s study¹ in collaboration with the Macular Disease Society (MDS) was to assess the perceived quality of health care of people with macular disease in the United Kingdom. The study was performed in 1999 and took the form of a retrospective audit by postal survey of 2000 members of the MDS. I performed a similar but smaller study in collaboration with the MDS 7 years earlier.² This also took the form of a retrospective audit by postal survey of 200 members of the MDS. The aim was to assess the clinical management of patients with age related macular degeneration (ARMD) in the United Kingdom from the patients' perspective. The final response rate was 79% (similar to 77% of Mitchell *et al*) and patients had attended over 105 ophthalmic units throughout the United Kingdom. Mitchell *et al* omitted this earlier study from their discussion but comparison of the two studies raises some noteworthy points.

The prevention³ and treatment⁴ of ARMD remains far from ideal both for the majority of patients and their ophthalmologists. Members of the MDS are likely to be a highly motivated study group and it is not clear how their views will reflect the views of patients as a whole with ARMD. However, both studies highlighted the fact that lack of information and advice on ARMD is a significant cause of dissatisfaction for these patients. Mitchell *et al* asked if the diagnostic consultation with the eye specialist was satisfactory: 59% responded

“yes” and 41% “no.” The two most common reasons given for a negative answer were the attitude of the specialist and lack of information and advice (43.5% and 43.4% respectively of those answering this question). The earlier study specifically asked whether patients were given written information on ARMD, were informed about support groups or informed about relevant radio programmes by the eye department.² Only 6% received written information, 14% were given details of support groups, and 3% details of relevant programmes. By definition 100% of the study group would have liked to have been informed of the existence of the Macular Disease Society by the eye unit. However, nine different sources were cited for discovering the MDS; over 80% from radio and magazines with only 12% from the ophthalmic unit. Unfortunately, despite that fact that the two studies are separated by 7 years, any temporal comparison has to be undertaken with caution. The protocol of both surveys included questionnaires being sent to members of the MDS chosen at random from the MDS mailing list. It is therefore conceivable that a proportion of the original study group also formed part of the second, larger study group. What is clear though, is that despite the fact that patients want information on ARMD and the fact that there are readily available sources (for example, free information booklets on ARMD from the Royal College of Ophthalmologists or Royal National Institute for the Blind), ophthalmic units throughout the United Kingdom are still failing routinely to provide such information to their patients.

L J Howe

Moorfields Eye Hospital, City Road, London EC1V 2PD, UK; lucy.robson@btopenworld.com

References

- 1 **Mitchell J**, Bradley P, fytche T, *et al.* Perceived quality of health care in macular disease: a survey of members of the Macular Disease Society. *Br J Ophthalmol* 2002;**86**:777–81.
- 2 **Howe LJ**. Clinical management of age-related macular degeneration: room for improvement. *Eye* 1995;**9** (suppl.):42–6.
- 3 **Hall NF**, Gale CR. Prevention of age related macular degeneration. *BMJ* 2002;**325**:1–2.
- 4 **Wormald R**, Evans J, Smeeth L, *et al.* Photodynamic therapy for neovascular age related macular degeneration. *Cochrane Database of Systemic Reviews* (3):CD002030, 2001.

Standardised clinical photography in ophthalmic plastic surgery

We read with keen interest the path breaking article by Calista *et al* regarding the successful treatment of an eyelid squamous cell carcinoma with intralesional cidofovir.¹ The dramatic response of this highly malignant lesion to such a non-invasive form of therapy is remarkable and certainly worth further clinical evaluation. However, we would like to raise a few crucial issues pertaining to the documentation of this case.

The authors have presented an extreme close up of the affected eye in Figure 1, which highlights the pretreatment appearance of the lesion quite adequately. However, the post-treatment photograph (Fig 2) is almost half the magnification of Figure 1. Therefore, although there is an indisputable reduction in the size of the tumour, the two clinical photographs are not strictly comparable since a decrease in magnification results in visual clues that lead to the lesion being perceived as smaller in size.

Secondly, the pretreatment view (Fig 1) has been taken in primary gaze and reveals a right lower lid retraction as well as the semblance of a mild lid notch. In contrast, the post-treatment view (Fig 2) has been photographed on the left and slight downgaze and does not show either of the above findings. Now, it is difficult to discern whether there is an actual disappearance of these pretreatment findings or it is due to the inherent lack of comparability of these pictures because of their being in totally different positions of gaze, which is compounded by the magnification factor mentioned earlier. It would be of immense benefit to the readers if the authors could kindly clarify these points of discrepancy, which have arisen due to dissimilar photographs.

It is imperative that extremely high standards of clinical photography be maintained in plastic surgery/oncology and photographs be taken with similar parameters to ensure valid pretreatment and post-treatment comparisons that accurately reflect the results.^{2,3} The standards and recommendations for clinical photography have been widely documented and should be universally practised.⁴ These include using the same camera lens, settings, lighting, film, magnification, and patient position to ensure reproducibility and comparisons.² Even small variations in the pictures may cause drastic changes in the clinical and research value of photography and, unless stringent criteria are met, the photographs may lose their relevance and overall impact.⁵

M S Bajaj, N Pushker, A Mahindrakar, R Balasubramanya

Correspondence to: Mandeep S Bajaj, RP Centre, All India Institute of Medical Sciences, Ansari Nagar, New Delhi 110029, India; msbajaj32@hotmail.com

References

- 1 **Calista D**, Riccioni L, Coccia L. Successful treatment of squamous cell carcinoma of the lower eyelid with intralesional cidofovir. *Br J Ophthalmol* 2002;**86**:932-33.
- 2 **DiBernardo BE**, Adams RL, Krause J, et al. Photographic standards in plastic surgery. *Plast Reconstr Surg* 1998;**102**:559-68.
- 3 **Talamas I**, Pando L. Specific requirements for preoperative and postoperative photos used in publication. *Aesthetic Plast Surg* 2001;**25**:307-10.
- 4 **Yavuzer R**, Smirnes S, Jackson IT. Guidelines for standard photography in plastic surgery. *Ann Plast Surg* 2001;**46**:293-300.
- 5 **Jemec BI**, Jemec GB. Photographic surgery: standards in clinical photography. *Aesthetic Plast Surg* 1986;**10**:177-80.

Entonox as an analgesic agent

We read with great interest the paper on Entonox as an analgesic agent by Cook *et al.*¹ We congratulate the authors for their work. However, we would like to clarify certain aspects of the study.

We recently performed a randomised, placebo controlled, double blind study with 100 patients on the analgesic effect of Entonox for pain relief during local anaesthetic injections in minor eyelid procedures (accepted for publication). We administered Entonox for 30 seconds in our study and found no statistically significant difference in the pain scores between the control and the study groups. No side effects were reported but in our pilot study, where the patients were given Entonox for 60 seconds, all the Entonox group patients reported light headedness and required prolonged observation before being discharged.

We attributed our results of lack of statistically significant pain relief with Entonox to less than 50 seconds' administration of Entonox. Waud *et al.*² have shown that optimal administration of Entonox should cover 50 seconds, based on theoretical calculations for effective pain relief. Based on the above experience, we would like to know if the authors administered Entonox throughout the laser treatment and, if so, did it not interfere with the laser delivery since the inhalation process is likely to be associated with head movements? If the Entonox was given for a shorter duration, we need to know the duration of administration since that would be of practical benefit to the readers.

The authors have concluded that Entonox is useful in young patients, those undergoing re-treatments, and in patients who have previously not been able to tolerate the full treatment. We would like to know how the authors came to this conclusion, as there is no mention of the type of patients selected for their study.

S Sandramouli, M Kurli

Wolverhampton and Midland Counties Eye Infirmary, Compton Road, Wolverhampton WV3 9QR, UK

Correspondence to: Mr S Sandramouli; smouli@tinyonline.co.uk

References

- 1 **Cook HL**, Newsom RSB, Mensah E, et al. Entonox as an analgesic agent during panretinal photocoagulation. *Br J Ophthalmol* 2002;**86**:1107-8.
- 2 **Waud BE**, Waud DR. Calculated kinetics of distribution of nitrous oxide and methoxy flurane during intermittent administration in obstetrics. *Anaesthesiology* 1970;**32**:306-16.

Mechanism of ophthalmic artery occlusion following pars plana vitrectomy

Saito *et al* present a patient with Terson's syndrome and dense vitreous haemorrhage who underwent pars plana vitrectomy and was noted postoperatively to have developed an ophthalmic artery occlusion.¹ They propose that the ophthalmic artery was occluded by the spontaneous release of an embolus from an atheromatous plaque in the internal carotid artery. This seems unlikely in a 39 year old man without a previous history of symptomatic atherosclerotic disease. Although the authors identified plaques in the patient's carotid artery by ultrasound, these can be seen in 11% of asymptomatic males under age 40 and may therefore be an incidental finding in this case.²

An alternate explanation for the patient's ocular findings is trauma from the retrobulbar injection. Intravascular injection into the ophthalmic artery has been reported as a complication of retrobulbar anaesthesia.³ It is possible that either an intravascular injection or simply needle tip trauma resulted in thrombus formation with obstruction of flow in the ophthalmic artery. It should also be noted that although acute ophthalmic artery occlusion is the presumed diagnosis, the same findings could result from simultaneous obstructions of the retinal and choroidal circulations⁴, also a potential consequence of errant retrobulbar injection. The possibility that the patient's chorioretinal disturbance could have been iatrogenic highlights the importance of a thorough preoperative discussion with patients about the risks and benefits of different

methods of delivering anaesthesia for ophthalmic surgery.

J M Stewart

Ophthalmology, University of California, San Francisco, CA, USA; ne62@yahoo.com

References

- 1 **Saito W**, Yamamoto S, Takeuchi S, et al. Ophthalmic artery occlusion following pars plana vitrectomy in a patient with Terson's syndrome. *Br J Ophthalmol* 2002;**86**:1063-4.
- 2 **Sun Y**, Lin CH, Lu CJ, et al. Carotid atherosclerosis, intima media thickness and risk factors—an analysis of 1781 asymptomatic subjects in Taiwan. *Atherosclerosis* 2002;**164**:89-94.
- 3 **Morgan CM**, Schatz H, Vine AK, et al. Ocular complications associated with retrobulbar injections. *Ophthalmology* 1988;**95**:660-5.
- 4 **Brown GC**, Magargal LE, Sergott R. Acute obstruction of the retinal and choroidal circulations. *Ophthalmology* 1986;**93**:1373-82.

Dynamics of corneal endothelial cell death in organ culture

We read with interest the remarks of Crowston *et al.*¹ on our article.² We showed that the TUNEL technique revealed a far higher percentage of endothelial cells (ECs) irreversibly engaged in a cell death process than that obtained by trypan blue staining.

The two techniques were performed sequentially: after observation of trypan blue staining, corneas were immediately fixed in formaldehyde for TUNEL. Crowston *et al* suggest that the trypan blue itself and/or the time spent outside the organ culture medium before fixing in formaldehyde may have caused an artefactual increase in the percentage of TUNEL positive ECs. Two arguments counter this remark.

(1) The trypan blue staining procedure is identical to that used, during endothelial examination(s) of grafts, in all European cornea banks that use organ culture during endothelial examination(s) of grafts. Neither the low concentration of trypan blue (0.4%) nor the short exposure time (about 1 minute) nor the short incubation in the presence of 0.9% NaCl has ever been incriminated in the over-mortality of ECs in routine practice.³ Moreover, the innocuity of injections of trypan blue into the anterior chamber, a common feature during cataract surgery, has been well demonstrated.⁴

(2) The time spent outside the organ culture medium before fixing in formaldehyde, a period required for vital staining and microscopic examination of the endothelium, lasts only a few minutes. The cornea remains under the microscope for about 1 minute only, the time needed for image acquisition. Such rapidity is possible by using a prototype automatic analyser of the endothelium, which we developed and have recently published.⁵ This is very probably insufficient time for DNA fragmentation to occur at the level we observed. Moreover, the fixing of the endothelial layer in 10% formaldehyde is immediate, and prevents any continuation of fragmentation phenomena. On balance, it is highly unlikely that the succession of markings is responsible for the discrepancy between the positivity percentages of the two techniques. In addition, we chose not to perform the two techniques simultaneously on paired corneas or on the halves of one cornea because we wanted to superimpose the two stains on the same cornea and thus obtain a double cell staining.

The second remark by Crowston *et al* is particularly interesting. We too were surprised by the high percentage of TUNEL positive ECs (mean 12.7%, SD 16.4). This may imply that all the cells died within 8 days, which was evidently not the case. We believe this apparent contradiction can be explained by the following theory. The TUNEL staining is positive during a relatively long window (24–48 hours⁵). The TUNEL index, measured at a given moment, provides a global view of all the cells with fragmented DNA. However, the DNA fragmentation may be at different stages, and the cells very likely spread according to a Gaussian distribution. Therefore the cells, which are TUNEL positive at a given moment, will not all die instantaneously and simultaneously. Only the cells furthest to the right on the curve will die in the very short term, and it is probably these that are liable to be revealed by trypan blue. If it were possible to perform TUNEL on two consecutive days, the percentage of positive cells revealed would probably be very similar, but a large majority of the positive cells recorded on the second day would have already been counted on day one. It is, however, undeniable that the cells that are TUNEL positive at a given moment will all die eventually. In other words, we believe that, at the end of storage, corneas contain a number of ECs engaged in an irreversible cell death process far more extensive than the highly unreliable trypan blue staining technique suggests.

G Thuret, C Chiquet, L Campos, P Gain

Cell Death and Neoplasia Laboratory EA 3063, University Hospital, St Etienne, France

Correspondence to: Gilles Thuret; gilles.thuret@univ-st-etienne.fr

References

- 1 **Crowston JG**, Healey PR, Maloof A, *et al*. Quantifying corneal endothelial cell death. *Br J Ophthalmol* 2002;**86**:1068.
- 2 **Gain P**, Thuret G, Chiquet C, *et al*. Value of two mortality assessment techniques for organ cultured corneal endothelium: trypan blue versus TUNEL technique. *Br J Ophthalmol* 2002;**86**:306–10.
- 3 **Sperling S**. Evaluation of the endothelium of human donor corneas by induced dilation of intercellular spaces and trypan blue. *Graefes Arch Clin Exp Ophthalmol* 1986;**224**:428–34.
- 4 **Norn MS**. Per operative trypan blue vital staining of corneal endothelium. Eight years' follow up. *Acta Ophthalmol* 1980;**58**:550–5.
- 5 **Gain P**, Thuret G, Kodjikian L, *et al*. Automated tri-image analysis of stored corneal endothelium. *Br J Ophthalmol* 2002;**86**:801–8.
- 6 **Mesner PW**, Epting CL, Hegarty JL, *et al*. A timetable of events during programmed cell death induced by trophic factor withdrawal from neuronal PC12 cells. *J Neurosci* 1995;**15**:7357–66.

NOTICES

Role of optometry in Vision 2000

The latest issue of *Community Eye Health* (No 43) discusses the mobilisation of optometry to deal with uncorrected refractive error, which is now a major cause of functional blindness.

For further information please contact: Journal of Community Eye Health, International Centre for Eye Health, Institute of Ophthalmology, 11–43 Bath Street, London EC1V 9EL, UK (tel: +44 (0)20 7608 6910; fax: +44 (0)20 7250 3207; email: eyesource@ucl.ac.uk; web site: www.jceh.co.uk). Annual subscription (4 issues) UK£25/US\$40. Free to workers in developing countries.

International Centre for Eye Health

The International Centre for Eye Health has published a new edition of the *Standard List of Medicines, Equipment, Instruments and Optical Supplies* (2001) for eye care services in developing countries. It is compiled by the Task Force of the International Agency for the Prevention of Blindness. Further details: Sue Stevens, International Centre for Eye Health, 11–43 Bath Street, London EC1V 9EL, UK (tel: +44 (0)20 7608 6910; email: eyesource@ucl.ac.uk).

Second Sight

Second Sight, a UK based charity whose aims are to eliminate the backlog of cataract blind in India by the year 2020 and to establish strong links between Indian and British ophthalmologists, is regularly sending volunteer surgeons to India. Details can be found at the charity web site (www.secondsight.org.uk) or by contacting Dr Lucy Mathen (lucymathen@yahoo.com).

Specific Eye Conditions (SPECS)

Specific Eye Conditions (SPECS) is a not for profit organisation which acts as an umbrella organisation for support groups of any conditions or syndrome with an integral eye disorder. SPECS represents over fifty different organisations related to eye disorders ranging from conditions that are relatively common to very rare syndromes. We also include groups who offer support of a more general nature to visually impaired and blind people. Support groups meet regularly in the Boardroom at Moorfields Eye Hospital to offer support to each other, share experiences and explore new ways of working together. The web site www.eyecconditions.org.uk acts as a portal giving direct access to support groups own sites. The SPECS web page is a valuable resource for professionals and may also be of interest to people with a visual impairment or who are blind. For further details about SPECS contact: Kay Parkinson, SPECS Development Officer (tel: +44 (0)1803 524238; email: k@eyecconditions.org.uk; web site: www.eyecconditions.org.uk).

16th Annual Meeting of German Ophthalmic Surgeons

The 16th Annual Meeting of German Ophthalmic Surgeons will be held 8–11 May 2003 in Nürnberg, Germany, Messezentrum. Organised by the Professional Association of German Ophthalmologists Ophthalmic Surgery Group the conference will cover cataract surgery, refractive surgery, glaucoma surgery, vitreoretinal surgery, corneal surgery, eye surgery in developing countries, and orbita,

lacrimal and lid surgery. Further details: MCN Medizinische Congress organisation Nürnberg AG, Zerzabelshofstr 29, 90478 Nürnberg, Germany (tel: +49 911 3931621; fax: +49 911 3931620; email: doc@mcnag.info; web site: www.doc-nuernberg.de).

3rd British Oculoplastic Surgery Society Meeting

The 3rd British Oculoplastic Surgery Society Meeting will be held 18–19 May 2003 in Birmingham, UK. For further details please contact the Secretary of the British Oculoplastic Surgery Society Jane Olver (tel: +44 (0)121 424 5464; fax: +44 (0)121 424 4464; email: MartiDi@heartsol.wmids.nhs.uk; web site: www.bopss.org).

13th Meeting of the EASD Eye Complication Study Group

The 13th Meeting of the EASD Eye Complication Study Group will be held on the 23–25 May 2003, in Prague, Czech Republic. The scientific programme includes keynote lectures from Professor John H Fuller (UK) on The epidemiology of diabetic retinopathy; Dr P Martin van Hagen (The Netherlands) on Growth factors and diabetic retinopathy; Professor Terezie Pelikanova (Czech Republic) on Pathophysiology of diabetic microvascular complications; Dr Tomas Sosna (Czech Republic) on Risk and protective factors of diabetic retinopathy.

Three travel grants of €1000 each, sponsored by GlaxoSmithKline for young scientists (under 35 years at the time of the meeting). Applications should be made with the submission of abstracts. The deadline for abstracts is 14 February 2003.

Further details: Ortopedicke Centrum, s.r.o., Strekovské nabrezi 51, 400 03 Usti nad Labem, Czech Republic (tel: +420 47 521 6588; fax: +420 47 533 40 77; email: ortcentrum-ul@volny.cz; web site: www.ortopedicke-centrum.cz).

Detachment Course with international faculty on: Retinal and Vitreous Surgery with Case Presentations preceding the Annual Meeting of Iranian Society of Ophthalmology

The detachment course with international faculty on: Retinal and Vitreous Surgery with Case Presentations preceding Annual Meeting of Iranian Society of Ophthalmology will be held on 29–30 November 2003 and 1–4 December 2003 respectively, at the Razi Conference Center, Hemmat Hyw, Tehran, Iran. Further details: Scientific programme: Prof Ingrid Kreissig, University of Tuebingen, Schleichstr. 12, Breuningerbau, 72076 Tuebingen, Germany (tel: +49 7071 295209; email: ingrid.kreissig@med.uni-tuebingen.de). Local organisation: Dr Arman Masheyekhi, Dr Siamak Moradian, Dept of Ophthalmology, Labbanfinejad Medical Center, Pasdaran Ave, Boostan 9, Tehran, 16666, Iran (fax: +98 21 254 9039; email: labbafi@hotmail.com).