

# PostScript

## LETTERS

If you have a burning desire to respond to a paper published in *BJO*, why not make use of our "rapid response" option?

Log on to our web site ([www.bjophthalmol.com](http://www.bjophthalmol.com)), find the paper that interests you, and send your response via email by clicking on the "eLetters" option in the box at the top right hand corner.

Providing it isn't libellous or obscene, it will be posted within seven days. You can retrieve it by clicking on "read eLetters" on our homepage.

The editors will decide as before whether to also publish it in a future paper issue.

### Acetazolamide, alternate carbonic anhydrase inhibitors and hypoglycaemic agents: comparing enzymatic with diuresis induced metabolic acidosis following intraocular surgery in diabetes

We describe a case of acetazolamide induced acidosis associated with the precipitation of a hyperosmolar state in a diabetic patient 6 weeks after routine phacoemulsification. While renal tubular acidosis is well reported with acetazolamide, this case suggests that a direct diuresis induced acidosis can also have significant effects, producing serious complications when acetazolamide is prescribed to a diabetic patient, and those with renal impairment, with important implications for prescribing.

#### Case report

A 47 year old female patient underwent technically uncomplicated left phacoemulsification with intraocular lens implant in 2002. Medical history included insulin dependent diabetes since 1971. She had treated, stable proliferative diabetic retinopathy, relatively mild diabetic nephropathy (proteinuria with a stable creatinine in the region of 140  $\mu\text{mol/l}$  for several months), and mild diabetic autonomic neuropathy. Serum urea had been slightly raised in the past, though had normalised. Serum electrolytes were also within normal limits. The patient was compliant with instructions and blood glucose had been well controlled over many years with regular subcutaneous insulin, no episodes of ketoacidosis or a non-ketotic hyperosmolar state.

Six weeks after cataract surgery she developed left cystoid macular oedema. Confirmed by fundus fluorescein angiography, treatment was started with topical ketorolac and frequency of postoperative topical steroid increased. Treatment was later started with acetazolamide 250 mg orally twice a day, with instructions to drink lots of sugar free fluids to compensate for the diuretic effect. Arrangements were made for regular monitoring of her electrolyte status.

The patient started to progressively deteriorate over the next few days, reporting a massive diuresis. She required emergency admission 6 days after starting treatment. Biochemical results are shown in table 1. Subcutaneous insulin was administered and acetazolamide discontinued. A sliding scale of insulin and intravenous saline drip were commenced to resuscitate her. Full blood count was normal, with no evidence of neutrophilia. Arterial blood gas analysis is shown in table 2. This shows that she had a metabolic acidosis. Arterial blood pH 7.3 after initial resuscitation implies that she was even more acidotic before fluid resuscitation. The hyperglycaemia, absence of ketones, and raised osmolality led to the diagnosis of hyperglycaemic hyperosmolar non-ketotic syndrome (HONK).

The patient stabilised rapidly overnight, with normal blood gases, blood glucose, and an improving serum creatinine of 141  $\mu\text{mol/l}$  by the next day. A sliding scale was discontinued 2 days following admission, when she was recommenced on a subcutaneous insulin regimen and discharged as an inpatient.

#### Comment

This case suggests that the diuretic induced mechanism for acetazolamide acidosis can be a cause of severe metabolic acidosis in susceptible patients, and that the diuresis can be severe enough to precipitate a life threatening diabetic crisis. Carbonic anhydrase inhibitors such as acetazolamide affect the metabolism of carbonic acid, bicarbonate, and carbon dioxide within the proximal tubule cell, inducing a slight diuresis.<sup>1</sup> It is rare for severe metabolic acidosis to develop outside advanced renal failure, chronic dialysis, in the elderly and those on nephrotoxic drugs.<sup>2-6</sup> While the patient's renal impairment was only moderate with serum creatinine at 140  $\mu\text{mol/l}$ , when acutely unwell it approached 150  $\mu\text{mol/l}$ , a level which would have necessitated referral to a renal specialist to plan end stage renal replacement therapy.<sup>2-4-5</sup> This is because patients with diabetic nephropathy tend to do less well than those with other causes of renal impairment and, in fact, renal dialysis may in any case be

required at relatively low levels of creatinine such as less than 200  $\mu\text{mol/l}$ .<sup>5</sup>

Most reports in the literature do not specify the underlying pathophysiological mechanism causing metabolic acidosis with acetazolamide. Some cases have been suspected to be the result of a biochemical effect operating at an enzymatic level to increase urinary loss of bicarbonate producing a metabolic acidosis—for example, renal tubular acidosis, and potentially also lactic acidosis, damage to the tricarboxylic acid cycle, ketosis and inhibition of pyruvate carboxylase.<sup>2-7</sup> However, the biochemical results in this patient, together with the rapidity of acidosis, do not suggest a tubular origin for the acidosis.<sup>2</sup> Instead the patient displayed an alternative mechanism that accounts for the metabolic acidosis. This was causing the physiological effect of diuresis causing loss of excess body water in a diabetic patient. Further, there was no history of biguanide use; metformin is an oral hypoglycaemic agent that can cause lactic acidosis to the extent that it is contraindicated with a creatinine level of 150  $\mu\text{mol/l}$  or more.

Basic physiological work suggests that a diuresis induced acidosis can be a significant factor with acetazolamide.<sup>8</sup> Biochemical results in this patient directly correspond to those obtained when healthy subjects have been given three 250 mg doses of acetazolamide.<sup>8</sup> Acute clinical doses of the drug cause a change in body fluid compartments leading to a moderate isosmotic hypovolaemia with an intracellular volume expansion as well as metabolic acidosis.<sup>8</sup> Three 250 mg doses of acetazolamide in healthy men are associated with a significant 1.7 litres reduction in body water, compartmentalised as a significant reduction in extracellular water and increase in intracellular water.<sup>8</sup> In this patient such a diuresis would have been significant enough when occurring over a few days to produce enough loss of body water to precipitate dehydration and lactic acidosis despite her drinking large volumes of fluids. Physiological stress of this nature is a well known stimulus that can precipitate a diabetic crisis in a susceptible patient, the massive rise in blood glucose largely accounting for the high osmolality in the patient. Hyperglycaemic hyperosmolar non-ketotic syndrome (HONK) does occur, although less commonly than ketoacidosis, in insulin dependent diabetics.<sup>9</sup> This makes plausible the postulate that acetazolamide was the culprit. Theoretically, a diabetic ketoacidosis is also possible, though we are unaware of specific reports to date in this context. HONK is arbitrarily defined as serum osmolality >320 mOsm/kg and a blood glucose level >33 mmol/l, without excessive ketones, and

Table 1 Biochemistry on admission

	Serum glucose	Serum Na <sup>+</sup>	Serum K <sup>+</sup>	Serum urea	Serum creatinine	Urine ketones*	Serum osmolality†
Patient	55 mmol/l	135 mmol/l	4.0 mmol/l	14.1 mmol/l	149 $\mu\text{mol/l}$	0	357 mOsm/kg
Normal reference range	3-6 mmol/l	135-145 mmol/l	3.5-5.0 mmol/l	2-8 mmol/l	60-120 $\mu\text{mol/l}$		

\*Normally no ketones are detected on stick testing of urine.

† $2[\text{Na}^+ + \text{K}^+] + \text{urea} + \text{glucose}$ , using serum concentrations; dangerous if outside 240-330 mOsm/kg.

**Table 2** Arterial blood gases on admission

	pH	pCO <sub>2</sub>	pO <sub>2</sub>	Base deficit (excess)†
Patient	7.3	3.4 kPa	15 kPa	-10.3 mmol/l
Normal reference range	7.35-7.45*	4.5-6.0 kPa	12-15 kPa	

\*Life threatening at and beyond 7.2 and 7.6.

†Normal >23 mmol/l; <-3 mmol/l = metabolic acidosis, >+3 mmol/l = metabolic alkalosis, -3 mmol/l to +3 mmol/l = mild metabolic acidosis, severe metabolic alkalosis, or mixed metabolic disturbance.

was clearly induced by the stress of diuresis in this patient, with which it is associated. It would also have compounded the patient's existing dehydration. Mortality from HONK can be as high as 40% despite hospital admission.<sup>9</sup>

It is possible that the precise mechanism of metabolic acidosis seems not to have been considered in most case reports as treatment was, in many ways, unaffected. Alternately, it may be that the effect reported in this case is extremely rare. However, the clinical findings in this case are supported directly by correlation with the findings of basic physiological work on the pharmacodynamics of acetazolamide, together with work on the pathophysiology of HONK.<sup>8,9</sup> This suggests that the observations made on this case are certainly of much broader significance and raise an issue of concern about the drug's prescription in both diabetes and renal failure. While manufacturer's recommendations for acetazolamide in Britain include contraindications to its use in supranal dysfunction, they do not issue cautions for its use in diabetics. Thus this case's principal value lies in evaluating current prescribing practice, particularly as diabetics are a very common group of patients in ophthalmic practice, and acetazolamide is not uncommonly prescribed in many different areas of clinical ophthalmology, as well as by other clinicians. Until further data are forthcoming, including data on newer slow release formulations, good practice should be to prescribe the drug with especial caution in diabetics, particularly for those conditions, including this case, where its prescription is not routine. In the context of its use in diabetes it is also certainly worth comparing acetazolamide with other carbonic anhydrase inhibitors. One of the other carbonic anhydrase inhibitors that have been used in clinical ophthalmology is methazolamide. The latter is associated with a less profound reduction in intraocular pressure, but also less acidosis.<sup>6,10</sup>

This case should also serve as a reminder that patients with any level of renal impairment are a group that are vulnerable to acetazolamide toxicity. The data sheet and electronic medicines compendiums state that acetazolamide is contraindicated in marked kidney and liver dysfunction, supranal gland failure, and hyperchloraemic acidosis. The *British National Formulary* is less specific and states that it is contraindicated in renal impairment. We would suggest that diabetic patients with a creatinine level of 140 µmol/l are at quite high risk of nephrotoxic drug reactions, though caution should be exercised in even mild renal impairment.

F H Zaidi, P E Kinnear

Department of Ophthalmology, Charing Cross, Chelsea and Westminster Hospital, London, UK

Correspondence to: Farhan H Zaidi, Department of Ophthalmology, Imperial College London, Charing Cross and Hammersmith Hospitals, London, UK; fhz12@hotmail.com

doi: 10.1136/bjo.2003.027490

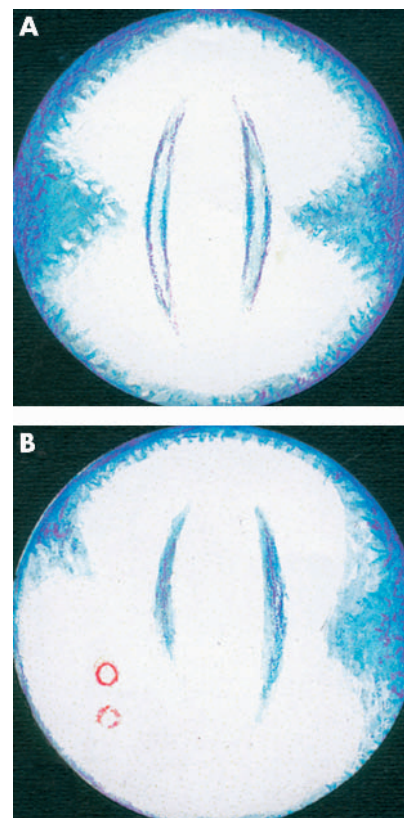
Accepted for publication 3 July 2003

## References

- Greger R, Lohmann E, Schlatter E. Action of diuretics at the cellular level. *Clin Nephrol* 1992;**38**(Suppl 1):S64-8.
- Elinav E, Ackerman Z, Gottehrer NP, et al. Recurrent life-threatening acidosis induced by acetazolamide in a patient with diabetic type IV renal tubular acidosis. *Ann Emerg Med* 2002;**40**:259-60.
- Gabay EL. Metabolic acidosis from acetazolamide therapy. *Arch Ophthalmol* 1983;**101**:303-4.
- Chapron DJ, Gomolin IH, Sweeney KR. Acetazolamide blood concentrations are excessive in the elderly: propensity for acidosis and relationship to renal function. *J Clin Pharmacol* 1989;**29**:348-53.
- De Marchi S, Cecchin E, Tesio F. Intraocular pressure changes during hemodialysis: prevention of excessive dialytic rise and development of severe metabolic acidosis following acetazolamide therapy. *Ren Fail* 1989;**11**:117-24.
- Sporn A, Scothorn DM, Terry JE. Metabolic acidosis induced by acetazolamide. *J Am Optom Assoc* 1991;**62**:934-7.
- Filippi L, Bagnoli F, Margollicci M, et al. Pathogenic mechanism, prophylaxis, and therapy of symptomatic acidosis induced by acetazolamide. *J Invest Med* 2002;**50**:125-32.
- Brechue WF, Stager JM, Lukaski HC. Body water and electrolyte responses to acetazolamide in humans. *J Appl Physiol* 1990;**69**:1397-401.
- Levine SN, Sanson TH. Treatment of hyperglycaemic hyperosmolar non-ketotic syndrome. *Drugs* 1989;**38**:462-72.
- Stone RA, Zimmerman TJ, Shin DH, et al. Low-dose methazolamide and intraocular pressure. *Am J Ophthalmol* 1977;**83**:674-9.

## The art of retinal detachment surgery: a photoessay

Subjective visual experience has been described previously in patients undergoing intraocular surgery, and may occur during either topical anaesthesia or regional anaesthesia (peribulbar, retrobulbar, subtenons).<sup>1-7</sup> Published reports suggest most or all patients undergoing cataract extraction under local anaesthesia will report some visual symptoms when questioned immediately after their procedures. These symptoms are common therefore and range from perception of light, photopsia, colours, and movement, through to more formed visual sensations such as patterns, instruments, and surgeon's fingers/hands/detail. It is not surprising that patients undergoing vitreoretinal surgery



**Figure 1** (A) "Now we are going to shine a very bright light into your eye" ... and indeed it was bright. The light pulsed gently and sparkled at the edges where the heavenly blue began. (B) It was outshone by an even brighter light ... more pulsations and shimmerings of an intense whiteness followed and two glowing red circles appeared, the lower one seeming to be a secondary image or reflection of the upper one.

under local anaesthesia might also experience visual symptoms.

We present illustrations and comments (figs 1-4) made by an artist who underwent retinal detachment surgery. He presented with macula-on retinal detachment successfully repaired by vitrectomy, cryotherapy, and 20% SF<sub>6</sub> gas performed by peribulbar anaesthesia. They provide an interesting insight into previously unreported visual experience during vitreoretinal surgery. As visual symptoms are both common, and may be perceived to be frightening in a small percentage of patients,<sup>2</sup> we reinforce the view that informed patient consent procedures should include the possibility of visual experience during vitreoretinal surgery under local anaesthesia.

B J Vote, M B Eckstein

Department of Ophthalmology, Sussex Eye Hospital, Brighton, UK

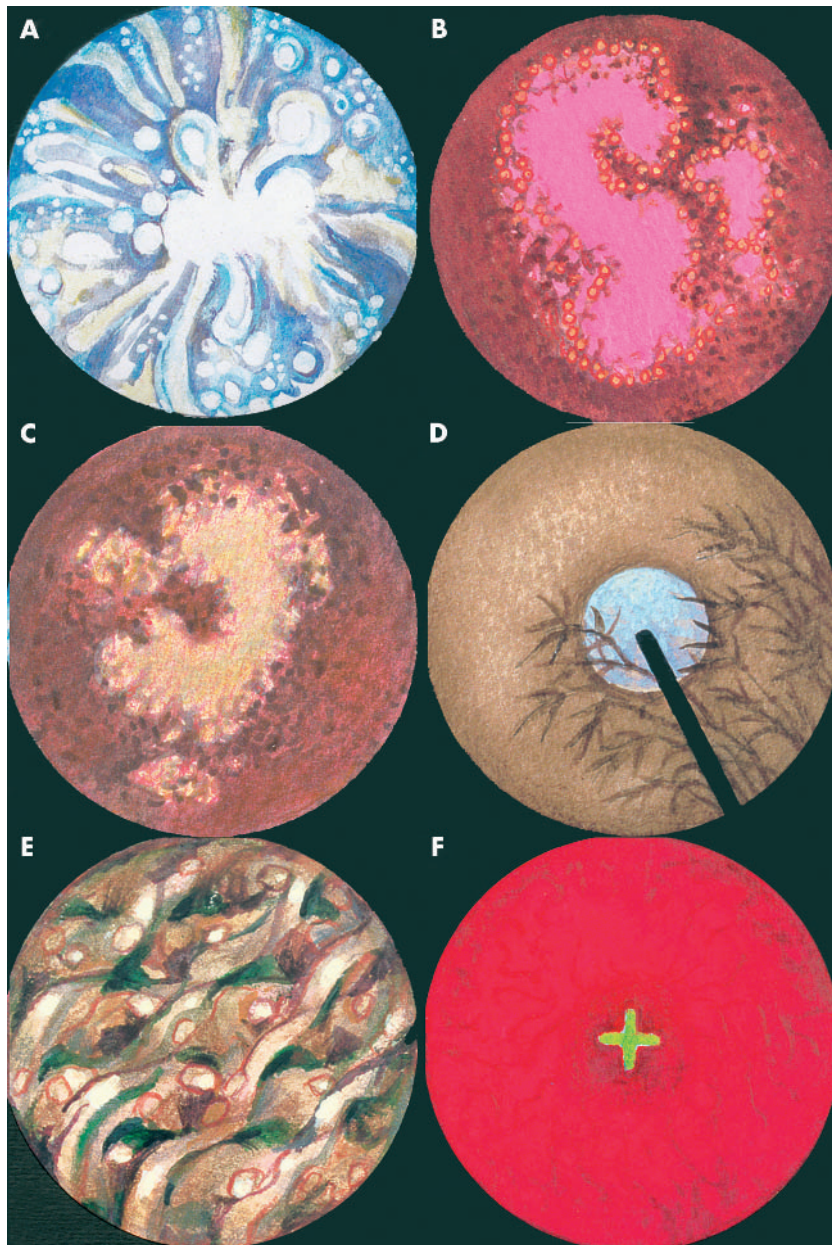
Correspondence to: Mr B J Vote, Department of Ophthalmology, Sussex Eye Hospital, Brighton BN2 5BF, UK; eye.vote@blueyonder.co.uk

Disclaimer: the authors have no financial interest in this manuscript.

doi: 10.1136/bjo.2003.029504

Accepted for publication 18 August 2003



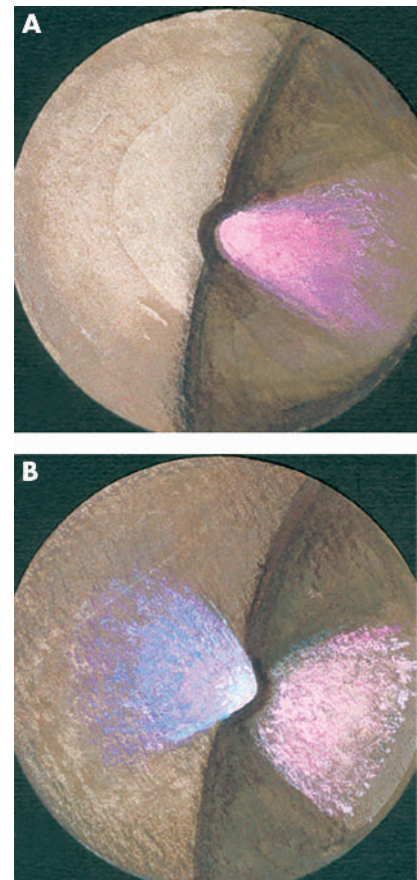


**Figure 2** (A) From time to time liquid was splashed on to the eye, producing quite remarkable starbursts of bubbles and comet trails of light. (B) The brilliant light faded and was replaced by deliquescent magenta coloured shapes, glowing like neon, constantly forming and reforming and with sparks coruscating round the edges ... a real firework display. (C) Quite suddenly the fireworks gave way to this darker mood ... the shapes still forming and reforming but more slowly, no longer glowing, but in a complementary colour to that of the previous image ... a muted lime yellow. (D) Next came perhaps the most extraordinary and delightful of all the images ... this near perfect facsimile of a Chinese silk painting of bamboos gently swaying, as if in a slight breeze, in front of a full moon. (E) Alas, the "Chinese painting" gave way to the appearance of "long whiskers"—rather like huge stray eyelashes—moving slowly but sometimes jerkily, at the top right of the field of vision. (F) Darker than this, richly beautiful and gently blurred, this next image somehow resembled a shallow stream. Clear water rippled over sunlit pebbles and water plants, long streamers of which gently swayed in the movement of the water. Sunlight flickered gently over everything—in many ways, a surprisingly realistic image. (G) This very powerful yet momentary image occurred towards the end of the operation. The incandescent green cross burned powerfully like an electric filament ... an inspection light perhaps?

## References

- 1 Prasad N, Kumar CM, Patil BB, *et al.* Subjective visual experience during phacoemulsification cataract surgery under sub-Tenon's block. *Eye* 2003;17:407–9.
- 2 Au Eong KG, Low CH, Heng WJ, *et al.* Subjective visual experience during phacoemulsification and

- intraocular lens implantation under topical anaesthesia. *Ophthalmology* 2000;107:248–50.
- 3 Au Eong KG, Lee HM, Lim AT, *et al.* Subjective visual experience during extracapsular cataract extraction and intraocular lens implantation under retrobulbar anaesthesia. *Eye* 1999;13:325–8.
- 4 Au Eong KG, Lim TH, Lee HM, *et al.* Subjective visual experience during phacoemulsification and



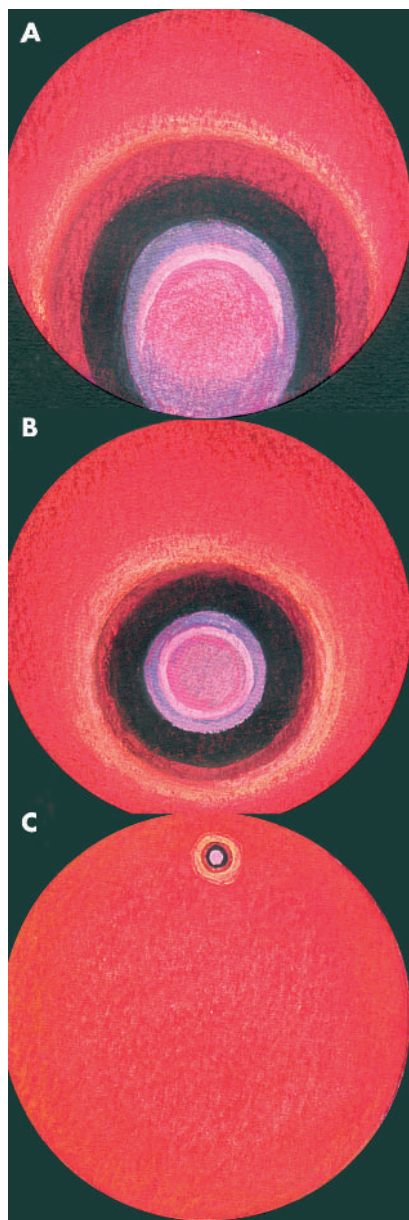
**Figure 3** (A) After an initial period of impenetrable "fog", the gas bubble gradually receded so as to allow me to see over the top of it. In these illustrations the bubble has receded to roughly halfway down the field of vision and I am lying on my left hand side with both eyes closed. The room is only semi-darkened. The pink light is very beautiful and emanates from a tiny convexity in the upper edge of the gas bubble. (B) The room is in complete darkness. The display is even more beautiful. Now it is a tiny concavity in the upper surface of the bubble that allows the violet "flare" of light to emerge.

intraocular lens implantation using retrobulbar anaesthesia. *J Cataract Refract Surg* 2000;26:842–6.

- 5 Newman DK. Visual experience during phacoemulsification cataract surgery under topical anaesthesia. *Br J Ophthalmol* 2000;84:13–15.
- 6 Tranos PG, Wickremasinghe SS, Sinclair N, *et al.* Visual perception during phacoemulsification cataract surgery under topical and regional anaesthesia. *Acta Ophthalmol Scand* 2003;81:118–22.
- 7 Murdoch IE, Sze P. Visual experience during cataract surgery. *Eye* 1994;8:666–7.

## Apolipoprotein E polymorphism in patients with cataract

Based on similarities in epidemiology and biochemistry, it has been suggested that cataract and Alzheimer's disease (AD) share the same aetiological mechanisms. Comorbidity of cataract and AD in trisomy 21 (Down's syndrome) is well known<sup>1,2</sup> and both diseases are characterised by aggregated proteins exhibiting excessive glycation and racemisation of aspartyl residues.<sup>3</sup> Several AD



**Figure 4** (A) Considerable time has now elapsed and the gas bubble has diminished a great deal. This is my view of it with the eye closed and in strong sunlight. (B) This illustrates still further diminution of the bubble and its detachment from the edge of the field of vision. (C) Eventually the gas bubble became minuscule, and reversed its position in the visual field of vision before disappearing altogether.

related proteins—amyloid precursor protein (APP),  $\beta$  amyloid ( $A\beta$ ), and presenilin (PS)—are expressed in the lens<sup>3,5</sup> and  $A\beta$  is accumulated in the cytosol of lens fibres in cataractous lenses of people with AD.<sup>6</sup>

Human apolipoprotein E (apoE) exists in three major isoforms encoded by distinct alleles (APOE  $\epsilon 2$ ,  $\epsilon 3$ , and  $\epsilon 4$ ). The different APOE alleles have been studied in relation to several human age related diseases: inheritance of the  $\epsilon 4$  allele is a strong risk factor for AD and influences  $A\beta$  metabolism.<sup>7,8</sup> The purpose of this study was to investigate the APOE  $\epsilon 2/\epsilon 3/\epsilon 4$  polymorphism in patients with cataract.

**Table 1** APOE allele frequencies for control and cataract groups

APOE allele*	Observed frequency					
	Controls (n = 374)	Cataracts			All cases (n = 1004)	
		Nuclear (n = 154)	Cortical (n = 310)	Posterior subcapsular (n = 238)	Mixed (n = 302)	
$\epsilon 2$	0.112	0.110	0.113	0.071	0.126	0.107
$\epsilon 3$	0.773	0.792	0.774	0.832	0.768	0.789
$\epsilon 4$	0.115	0.097	0.113	0.097	0.106	0.105

n, number of alleles.  
\* $p > 0.05$  for all alleles when comparing controls and cataracts (all cases) or cataract subgroups. 95% confidence intervals of all odds ratios included 1.0 (no difference).

**Table 2** APOE genotype distributions for control and cataract groups

APOE genotype	Observed frequency					
	Controls (n = 187)	Cataracts			All Cases (n = 502)	
		Nuclear (n = 77)	Cortical (n = 155)	Posterior subcapsular (n = 119)	Mixed (n = 151)	
$\epsilon 2/\epsilon 2$	0.011	0.013	0.013	0.017	0.020	0.016
$\epsilon 2/\epsilon 3$	0.182	0.156	0.181	0.101	0.179	0.157
$\epsilon 2/\epsilon 4$	0.021	0.039	0.019	0.008	0.033	0.024
$\epsilon 3/\epsilon 3$	0.588	0.636	0.587	0.697	0.596	0.624
$\epsilon 3/\epsilon 4$	0.187	0.156	0.194	0.168	0.166	0.173
$\epsilon 4/\epsilon 4$	0.011	NO	0.006	0.008	0.007	0.006

$p > 0.05$  for all genotypes when comparing controls and cataracts (all cases) or cataract subgroups. 95% confidence intervals of all odds ratios included 1.0 (no difference).  
NO, not observed.

After informed consent, patients with senile cataract and control individuals were recruited from two ophthalmic clinics in Tartu and the south Estonian area. The study was approved by the ethics committee at the University of Tartu, Estonia. Before surgery, the type of cataract was determined using biomicroscopy and ophthalmoscopy. Secondary cataracts were excluded. The case group included 502 patients; 77 with nuclear, 155 with cortical, 119 with posterior subcapsular, and 151 with mixed opacities. Mean age was 72.0 (SD 8.7) years (range 47–93 years) and 348 (69.3%) were women. The control group consisted of 187 individuals without cataract, uveitis, or glaucoma. Mean age was 65.8 (SD 6.9) years (range 43–90 years) and 136 (72.7%) were women. The power of the study was  $>99\%$  as calculated according to Altman<sup>9</sup> on the basis of APOE  $\epsilon 4$  allele frequencies in a recent study on AD.<sup>10</sup>

The APOE alleles and genotypes were determined as previously described.<sup>11</sup> The allele and genotype frequencies of cataract cases and controls were compared using a two tailed Fisher's exact test, and odds ratios (ORs) and 95% confidence intervals (CIs) were calculated.<sup>9</sup> All statistical analyses were performed using SYSTAT as software (SPSS Inc, Chicago, IL, USA). Statistical significance was defined as  $p < 0.05$ .

APOE allele and genotype frequencies found in this study are well in accordance with those reported in other Northern European populations.<sup>12</sup> No significant differences were seen between the control and cataract groups for any of the APOE alleles (table 1) or APOE genotypes (table 2). Neither were there any differences between the control group and the specific cataract subgroups. In order to prevent the data from being influenced by age differences between

the groups studied, age matched control individuals were selected and compared with the cataract group and vice versa, without resulting in any significant changes in APOE allele or genotype frequencies.

Alzheimer's disease and cataract both exhibit large aggregates of aberrant proteins, senile plaques composed of  $A\beta$  and neurofibrillary tangles containing the cytoskeletal protein tau in the former case, and light scattering high molecular weight aggregates of crystallins in the latter. Together with several other diseases characterised by protein aggregates, such as amyloidosis and prion diseases, the term "conformational disease" has been created, suggesting a common aetiology.<sup>3,13</sup>

The APOE  $\epsilon 4$  allele is a strong risk factor for AD, and it is believed that in neuronal tissue, apoE is important for mobilisation and redistribution of lipids, and for maintenance and repair of neuronal cell membranes.<sup>14</sup> However, in age related macular degeneration (AMD)—a condition characterised by accumulation of extracellular deposits termed drusen, containing among other things neutral lipids, cholesterol, and apoE—the  $\epsilon 4$  allele appears to confer protection, whereas the  $\epsilon 2$  allele is associated with a moderately increased risk of AMD.<sup>15,16</sup> The APOE  $\epsilon 4$  allele also seems to play a protective role during embryogenesis,<sup>17</sup> suggesting different effects of the gene early and late in life.

To our knowledge, this is the first study to investigate the APOE polymorphism in cataract patients. No differences in the distribution of APOE alleles and genotypes could be seen between controls and cataract patients in spite of a large number of participants and a very high power. This indicates that if there is a common pathogenic mechanism for cataract and AD, it does not involve the



APOE polymorphism. Of course the results need to be confirmed by other groups before the APOE polymorphism can be regarded as insignificant in cataractogenesis. Bearing in mind the similarities between cataract and AD is very important, however, as progress in aetiological research of one disease may contribute to elucidating the pathogenesis of the other.

### Acknowledgements

This work was supported by grants from the Swedish Medical Research Council (projects #02226, #5932, and #12103), the Sahlgrenska University Hospital, the Göteborg Medical Society, Stiftelsen Kronprinsessan Margaretas Arbetsnämnd för Synskadade, De Blindas Vänner, Stiftelsen Hjalmar Svenssons forskningsfond, and Tore Nilsons Stiftelse för Medicinsk Forskning.

#### M Zetterberg

Institute of Clinical Neuroscience, Section of Ophthalmology, Sahlgrenska University Hospital, Göteborg University, Mölndal, Sweden

#### H Zetterberg, M Palmér, L Rymo, K Blennow

Department of Clinical Chemistry and Transfusion Medicine, Sahlgrenska University Hospital, Göteborg University, Göteborg, Sweden

#### G Tasa, E Juronen, S Veromann

Department of Human Biology and Genetics, University of Tartu, Tartu, Estonia

#### P Teesalu

Department of Ophthalmology, University of Tartu, Tartu, Estonia

#### M Zetterberg, J-O Karlsson

Department of Anatomy and Cell Biology, Medical Faculty, Göteborg University, Göteborg, Sweden

#### K Höglund, K Blennow

Institute of Clinical Neuroscience, Department of Experimental Neuroscience, Sahlgrenska University Hospital, Göteborg University, Göteborg, Sweden

Correspondence to: Dr Madeleine Zetterberg, Institute of Clinical Neuroscience, Section of Ophthalmology, Sahlgrenska University Hospital, SE-431 80 Mölndal, Sweden; madeleine.zetterberg@anatecell.gu.se

doi: 10.1136/bjo.2003.032698

Accepted for publication 1 September 2003

### References

- 1 da Cunha RP, Moreira JB. Ocular findings in Down's syndrome. *Am J Ophthalmol* 1996;**122**:236–44.
- 2 Lott IT. Down's syndrome, aging, and Alzheimer's disease: a clinical review. *Ann N Y Acad Sci* 1982;**396**:15–27.
- 3 Harding J. Cataract, Alzheimer's disease, and other conformational diseases. *Curr Opin Ophthalmol* 1998;**9**:10–13.
- 4 Frederikse PH, Zigler Jr JS. Presenilin expression in the ocular lens. *Curr Eye Res* 1998;**17**:947–52.
- 5 Frederikse PH, Garland D, Zigler J Jr, et al. Oxidative stress increases production of  $\beta$ -amyloid (A $\beta$ ) in mammalian lenses, and A $\beta$  has toxic effects on lens epithelial cells. *J Biol Chem* 1996;**271**:10169–74.
- 6 Goldstein LE, Muffat JA, Cherny RA, et al. Cytosolic  $\beta$ -amyloid deposition and supranuclear cataracts in lenses from people with Alzheimer's disease. *Lancet* 2003;**361**:1258–64.
- 7 Holtzman DM, Bales KR, Tenkova T, et al. Apolipoprotein E isoform-dependent amyloid deposition and neuritic degeneration in a mouse model of Alzheimer's disease. *Proc Natl Acad Sci U S A* 2000;**97**:2892–7.
- 8 Corder EH, Saunders AM, Strittmatter WJ, et al. Gene dose of apolipoprotein E type 4 allele and the risk of Alzheimer's disease in late onset families. *Science* 1993;**261**:921–3.
- 9 Altman DG. *Practical Statistics for Medical Research*. First edition. London: Chapman and Hall/CRC, 1991.
- 10 Johansson A, Hampel H, Faltraco F, et al. Increased frequency of a new polymorphism in the cell division cycle 2 (cdc2) gene in patients with Alzheimer's disease and frontotemporal dementia. *Neurosci Lett* 2003;**340**:69–73.
- 11 Blennow K, Ricksten A, Prince JA, et al. No association between the  $\alpha$ 2-macroglobulin ( $\alpha$ 2M) deletion and Alzheimer's disease, and no change in  $\alpha$ 2M mRNA, protein, or protein expression. *J Neural Transm* 2000;**107**:1065–79.
- 12 Eichner JE, Dunn ST, Perveen G, et al. Apolipoprotein E polymorphism and cardiovascular disease: a HuGE review. *Am J Epidemiol* 2002;**155**:487–95.
- 13 Carrell RW, Lomas DA. Conformational disease. *Lancet* 1997;**350**:134–8.
- 14 Mahley RW. Apolipoprotein E: cholesterol transport protein with expanding role in cell biology. *Science* 1988;**240**:622–30.
- 15 Souied EH, Benlian P, Amouyel P, et al. The epsilon4 allele of the apolipoprotein E gene as a potential protective factor for exudative age-related macular degeneration. *Am J Ophthalmol* 1998;**125**:353–9.
- 16 Klaver CCW, Kliffen M, van Duijn CM, et al. Genetic association of apolipoprotein E with age-related macular degeneration. *Am J Hum Genet* 1998;**63**:200–6.
- 17 Zetterberg H, Palmér M, Ricksten A, et al. Influence of the apolipoprotein E e4 allele on human embryonic development. *Neurosci Lett* 2002;**324**:189–92.

### Mitomycin C in sebaceous gland carcinoma with pagetoid spread

Sebaceous gland carcinoma is a rare eyelid tumour comprising less than 1% of all eyelid malignancies.<sup>1</sup> It commonly arises from the meibomian glands of the tarsus, but may also arise from the glands of Zeis or from the sebaceous glands of caruncle.<sup>2</sup> It can present in a nodular or diffuse infiltrative form. The latter form with intraepithelial (pagetoid) invasion has poor prognosis as a result of delay in diagnosis as well as more extensive involvement of ocular tissues. Topical application of mitomycin C, a non-cell cycle specific alkylating agent, has been advocated for pagetoid spread of sebaceous gland carcinoma.<sup>3</sup> We report the use of mitomycin C as adjuvant therapy in a patient with completely excised sebaceous gland carcinoma and pagetoid spread.

### Case report

A 78 year old man was referred to the oculoplastic clinic with epiphora and irritation of right eye for 2 years. There was no previous ocular or medical history. Clinically he had a unilateral right upper lid entropion with tarso-conjunctival cicatrisation (fig 1) and bilateral dermatochalasis. The patient

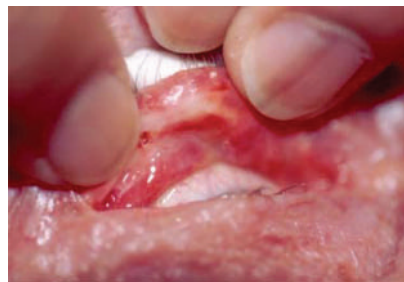

Figure 1 Upper lid tarso-conjunctival scarring.

underwent bilateral blepharoplasty and biopsy of right upper lid tarsal plate and conjunctiva. The biopsy confirmed sebaceous gland carcinoma with pagetoid invasion of the conjunctival epithelium (fig 2).

He had a full thickness wedge excision of the right upper lid with tarsoconjunctival biopsies. These showed sebaceous gland carcinoma to the margin of the excision with pagetoid invasion of the conjunctiva and epidermis of the lid margin. A wider excision of the lid and further conjunctival biopsies were performed with frozen section revealing complete excision of the tumour. Reconstruction of the posterior lamellae was achieved using a hard palate graft and the anterior lamellae was repaired by a myocutaneous flap with post auricular skin graft and a bilobed flap medially.

Conjunctival map biopsies were clear of tumour 1 and 6 months post excision. In view of pagetoid spread, the patient was commenced on three cycles of topical mitomycin C 0.02% four times a day. Each cycle consisted of 2 weeks of mitomycin C and 2 weeks off therapy. Corneal epithelial toxicity and ulceration was noted with mitomycin C therapy, requiring preservative free lubricants and lateral tarsorrhaphy. Two years after excision of tumour, the patient remains disease free.

### Comment

Intraepithelial invasion in sebaceous gland carcinoma is noted to occur in 41–80% of cases.<sup>1,4</sup> Diagnosis may be delayed as the presenting symptoms are often benign and non-specific such as blepharoconjunctivitis. Diagnosis requires biopsy of the abnormal area and conjunctival map biopsies in the presence of intraepithelial invasion.<sup>3,5</sup> Various treatments have been used for pagetoid invasion including surgical excision with cryotherapy, external beam radiotherapy, and orbital exenteration.<sup>6</sup> Eyes with pagetoid invasion are more likely to undergo exenteration.<sup>7</sup>

In our case the suspicion of malignancy was raised because of the unilaterality of the clinical features. Our patient underwent extensive excision of the tumour with tumour free conjunctival biopsies. Mitomycin C as adjuvant treatment was commenced as a result of the difficulty in clinically assessing for recurrence with pagetoid invasion. Mitomycin C was associated with moderate epithelial toxicity which was self limiting.

Mitomycin C is a non-cell cycle specific alkylating agent which acts to inhibit cell proliferation, and is used successfully in the treatment of corneal intraepithelial neoplasia.<sup>8</sup> This is only the second reported article where mitomycin C has been used in the

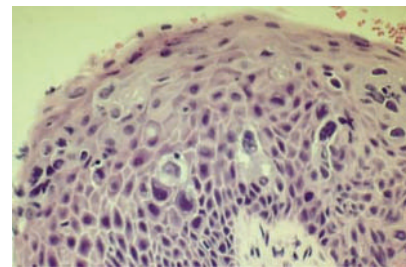


Figure 2 Conjunctival biopsy demonstrating intraepithelial invasion of malignant cells.

treatment of sebaceous gland carcinoma. In the pilot study by Shields *et al*<sup>3</sup> there was complete resolution of tumour with no recurrences over 12 month follow up. Mitomycin C as adjuvant treatment in pagetoid spread of sebaceous gland carcinoma may reduce the need for more invasive treatment options.

**K Tumuluri, G Kourt, P Martin**

Department of Oculoplastic and Orbital Surgery, Sydney Eye Hospital, Sydney, Australia

Correspondence to: Dr Georgina Kourt, Eye Associates, 149 Macquarie Street, Sydney 2000, Australia; ginaharr@ozemail.com.au

doi: 10.1136/bjo.2003.034215

Accepted for publication 26 September 2003

**References**

- 1 **Doxanas MT, Green WR.** Sebaceous gland carcinoma: review of 40 cases. *Arch Ophthalmol* 1984;**102**:245-9.
- 2 **Cook B, Bartley G.** Treatment options and future prospects for the management of eyelid malignancies. *Ophthalmology* 2001;**108**:2088-100.
- 3 **Shields CL, Naseripour M, Shields J, et al.** Topical mitomycin C for pagetoid invasion of the conjunctiva by eyelid sebaceous gland carcinoma. *Ophthalmology* 2002;**109**:2129-33.
- 4 **Rao NA, Hidayat AA, McLean JW, et al.** Sebaceous carcinoma of the ocular adnexa: a clinicopathologic study of 104 cases with five year follow-up data. *Human Pathol* 1982;**13**:113-22.
- 5 **Putterman AM.** Conjunctival map biopsy to determine pagetoid spread. *Am J Ophthalmol* 1986;**102**:87-90.
- 6 **Kass LG, Hornbliss A.** Sebaceous carcinoma of the ocular adnexa. *Surv Ophthalmol* 1989;**33**:477-90.
- 7 **Chao AN, Shields CL, Krema H, et al.** Outcome of patients with periocular sebaceous gland carcinoma with and without conjunctival intraepithelial invasion. *Ophthalmology* 2001;**108**:1877-83.
- 8 **Frucht-Pery J, Sugar J, Baum J, et al.** Mitomycin C treatment for conjunctival-corneal intraepithelial neoplasia: a multicenter experience. *Ophthalmology* 1997;**104**:2085-93.

**A questionnaire survey of patient acceptability of optic disc imaging by HRT II and GDx**

Glaucoma is an insidious condition which remains asymptomatic until very advanced with nerve damage occurring before detectable visual field loss.<sup>1</sup> Early detection and treatment result in a better prognosis with retardation of progression.<sup>2</sup>

The Heidelberg retinal tomograph (HRT II (Heidelberg Engineering, Germany) and the GDx Nerve fibre analyser (Laser Diagnostic Technologies Inc, San Diego, CA, USA) are instruments which use scanning laser technology to diagnose and monitor the progression of glaucoma.

We conducted a questionnaire survey of subjects undergoing imaging by these methods in a primary care setting to compare patient acceptability of the two tests.

**Methods**

Seventy new patients referred with a possible diagnosis of glaucoma were asked to complete a questionnaire about their experience of optic disc imaging. Informed consent was obtained and the study had approval from the Moorfields Eye Hospital research and ethics committee. None of the subjects had

**Table 1 Demographic and diagnostic data**

Demographic features	(n = 67)
Male	34 (50.7%)
Female	33 (49.3%)
Age (years)	Mean 57.1, SD 14.3, range 18-85
Diagnosis	
Primary open angle glaucoma	12 (18%)
Glaucoma suspect	18 (27%)
Ocular hypertension	16 (24%)
Non-glaucomatous optic neuropathy	3 (4.5%)
Normal	15 (22%)
No diagnosis given	3 (4.5%)

undergone disc imaging previously. Subjects underwent sequential disc imaging by experienced technicians using HRT II then GDx or vice versa in approximately equal numbers. Only subjects who had vision of at least 6/12 and who had successful imaging by both methods were included.

The questionnaires consisted of two identical sets of six direct questions using a size 14 font (Appendix 1). Questionnaires were completed immediately after imaging to reduce the potential for recall bias. Statistical significance was determined using Binomial and McNemar's tests.

**Results**

Sixty seven questionnaires were completed. Demographic and diagnostic data are shown in table 1 and patient responses in table 2. The majority of patients found both tests agreeable with regards to each characteristic under study other than chin rest comfort. Sixteen patients found the HRT II comfortable but not the GDx, compared with just one patient finding the GDx comfortable but not the HRT II (p = 0.0003). Despite this,

there were slightly more patients reporting that the HRT II chin rest only was uncomfortable (p = 0.052). Nine patients found that imaging with GDx but not HRT II took too long compared with no patients finding the HRT II but not GDx too long (p = 0.0039). Similar numbers of patients reported that only one of the imaging techniques was too bright. Nineteen patients had trouble fixating with the GDx but not the HRT II compared with just three patients having trouble fixating with HRT II but not GDx (p = 0.009).

Despite these differences, 28 subjects (42%) stated no preference for either imaging technique. Of the 39 subjects who did state a preference, 31 (79%) preferred HRT II compared with eight (21%) who preferred GDx (p = 0.0003, Binomial test). Twenty of the 31 subjects (65%) who chose HRT II did so because it was of a shorter duration, five of the 31 (16%) said that it was more comfortable, and six of the 31 (19%) said that it was easier to perform the test. Four of the eight subjects (50%) who chose GDx did so because it was easier, two (25%) said that it was more comfortable and two (25%) did not give a reason.

**Comment**

Diagnostic and screening tests should be safe, specific, sensitive, and acceptable to patients. The HRT and GDx have cited sensitivities of 0.42-0.88 and 0.64-0.96 and specificities of 0.84-0.90 and 0.74-0.96 respectively.<sup>3-9</sup>

Most patients found both tests to be fairly acceptable. Twenty eight (42%) subjects stated no preference but of those who did, a significant proportion of patients preferred HRT II over GDx. The most common reason given was a shorter test duration implying that acquisition time may have an impact on acceptability. Examination with the GDx may be longer because of the external fixation target, which a greater proportion of subjects found difficult to focus on. In contrast, the HRT II has an internal fixation target.

**Table 2 Patient responses**

Question	p Value (McNemar's)	
1. Was the test comfortable? (n = 65)	0.0003	
	HRT	No
GDx	Yes 46	1
	No 16	2
2. Was the light too bright? (n = 58)	0.3877	
	HRT	No
GDx	Yes 2	4
	No 8	44
3. Was the chin rest uncomfortable? (n = 65)	0.0522	
	HRT	No
GDx	Yes 26	8
	No 19	12
4. Was the test too long? (n = 65)	0.0039	
	HRT	No
GDx	Yes 1	9
	No 0	55
5. Did you have trouble keeping your eye still? (n = 65)	0.0009	
	HRT	No
GDx	Yes 14	19
	No 3	29



Although the HRT II was found to be a more comfortable test, a higher proportion found the HRT II chinrest to be uncomfortable possibly because of the forward sloping angulation.

We did not correlate patient preference with image acquisition time. More open questions may have helped to find the reasons for certain preferences. We were unable to determine the strength of preference from the collected data. Our study was also not randomised but roughly equal numbers had either HRT II or GDx first. We do not feel that there was a significant order effect. As our patients were new referrals, their responses were not biased by familiarity with previous tests. Patients underwent both tests sequentially on the same day by trained technicians reducing the likelihood of prolonged acquisition time due to inexperienced operators. All patients had good vision so locating the target was not an issue. Additional work examining the factors which affect acquisition time (for example, refractive error, presence of media opacity, pupil size) is needed to further understand patient preference.

It is uncertain if the differences in preference between the two tests will have a significant impact on patient satisfaction and compliance with clinic visits as a whole. Other factors, such as waiting time and comfort of waiting room, will have to be examined as well.

In conclusion, our study highlights the importance of both test characteristics and comfort in instrument design. It is hoped that manufacturers take into account these factors in the design of the next generation of glaucoma imaging devices.

## Appendix 1

The questions were:

1. Was the test comfortable? Yes or No?
2. Was the light too bright? Yes or No?
3. Was the chin rest uncomfortable? Yes or No?
4. Was the test too long? Yes or No?
5. Did you have trouble keeping your eye still? Yes or No?
6. (a) Which test did you prefer? HRT or GDx? (b) Why?

**E Tay, P Andreou, W Xing, C Bunce, T Aung, W A Franks**  
Glaucoma Service, Moorfields Eye Hospital, London, UK

Correspondence to: E Tay, Moorfields Eye Hospital, City Road, London EC1V 2PD, UK; dr\_eugenetay@yahoo.com

doi: 10.1136/bjo.2003.034975

Accepted for publication 29 September 2003

No financial interest or support.

## References

- 1 **American Academy of Ophthalmology Preferred Practice Pattern Committee Glaucoma Panel.** Primary open angle glaucoma. San Francisco, CA: American Academy of Ophthalmology, 1996.
- 2 **Jay J, Allen D.** The benefit of early trabeculectomy versus conventional management in primary open angle glaucoma relative to severity of disease. *Eye* 1989;3:528-35.
- 3 **Mikelberg FS, Parfitt CM, Swindale NV, et al.** Ability of the Heidelberg retina tomograph to detect early glaucomatous visual field loss. *J Glaucoma* 1995;4:242-7.
- 4 **Lester M, Mikelberg FS, Drance SM.** The effect of optic disc size on diagnostic precision with the Heidelberg Retinal Tomograph. *Ophthalmology* 1997;104:545-8.
- 5 **Poinosawmy D, Tan JC, Bunce C, et al.** The ability of the GDx nerve fibre analyser neural network to diagnose glaucoma. *Graefes Arch Clin Exp Ophthalmol* 2001;239:112-27.
- 6 **Kamal DS, Bunce C, Hitchings RA.** The use of the GDx to detect retinal nerve fibre thickness between normal, ocular hypertension and early glaucoma. *Eye* 2000;14:367-70.
- 7 **Weinreb RN, Zangwill L, Berry CC, et al.** Detection of glaucoma with scanning laser polarimetry. *Arch Ophthalmol* 1998;116:1583-90.
- 8 **Chopin NT, Lundy DC.** The sensitivity and specificity of scanning laser polarimetry in the detection of glaucoma in a clinical setting. *Ophthalmology* 2001;108:899-904.
- 9 **Tjon-Fo-Sang M, Lemij HG.** The sensitivity and specificity of nerve fibre layer measurements in glaucoma as determined with scanning laser polarimetry. *Am J Ophthalmol* 1997;123:62-9.

## A novel mutation in the alternative splice region of the PAX6 gene in a patient with Peters' anomaly

The *PAX6* gene is involved in ocular embryogenesis. This gene seems to be the master control gene for morphogenesis of the eye. Mutations in the *PAX6* gene have been detected in various ocular anomalies suspected to have bilateral genetic backgrounds during development, including aniridia, Peters' anomaly,<sup>1</sup> and foveal hypoplasia.<sup>2</sup>

In 1994, a sporadic case of Peters' anomaly and a small family with a range of anterior segment malformations, including Peters' anomaly, were shown to have a mutation of the *PAX6* gene.<sup>1</sup> More recently, Azuma *et al* reported a subject with Peters' anomaly having a missense mutation in the alternative splice region of the *PAX6* gene in 1999.<sup>3</sup> Here we report a novel *PAX6* gene mutation in a patient with Peters' anomaly.

## Case report

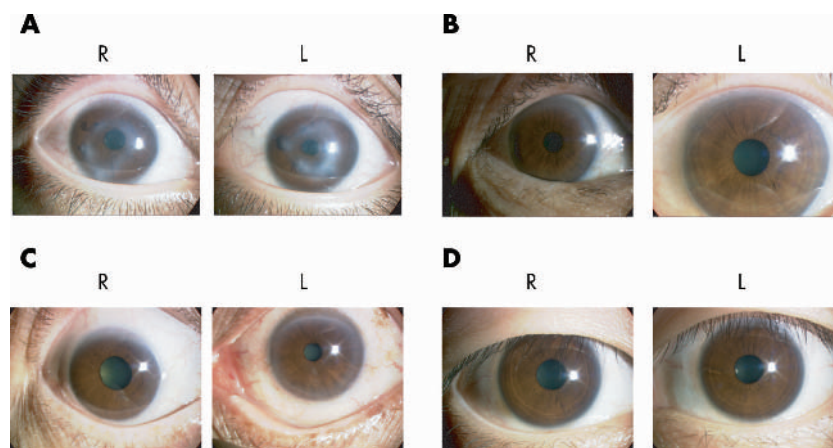
The present study had the approval of Kyoto Prefectural University of Medicine ethics committee and was conducted in accordance with the World Medical Association Declaration of Helsinki. Genomic DNA samples were isolated from the whole blood of patients and their relatives after informed consent. Each exon of the *PAX6* gene and its immediate flanking sequence were amplified by polymerase chain reaction (PCR). Purified amplified fragments were subjected to sequenced using an ABI Prism 3100 genetic analyser (Applied Biosystems, Foster City, CA, USA). To confirm the sequence of mutations, the SNaPshot method<sup>4</sup> was performed.

Of the four patients studied, we detected a novel missense mutation in one patient. The patient, a 20 year old girl, had bilateral Peters' anomaly showing corneal opacity with iridocorneal adhesion and nystagmus (fig 1). The fundus of both eyes could not be seen because of corneal opacity. No systemic associations with Peters' anomaly were identified. Sequence analyses revealed a heterozygous mutation as A/G at the 38th position which resulted in Q13R substitution in the *PAX6* gene. No mutation was found in her parents and elder brother, which is consistent with the fact that they show no abnormal findings on clinical examination (fig 2).

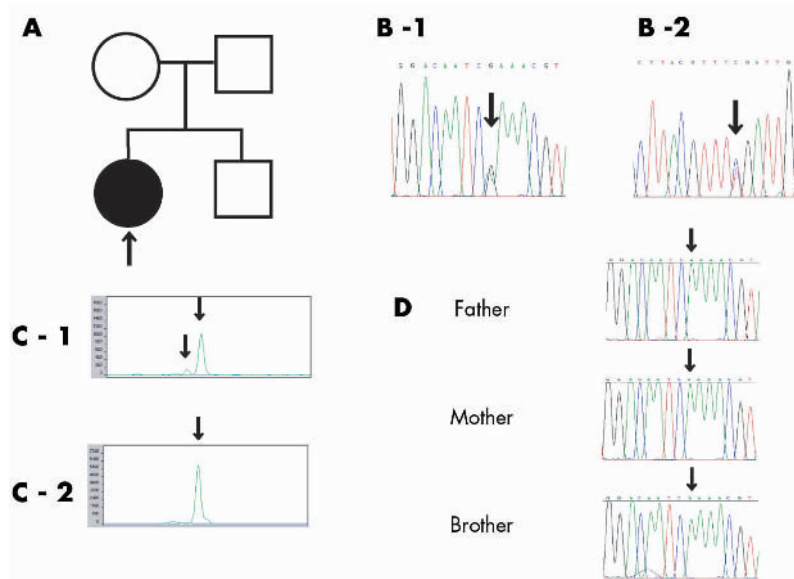
## Comment

We have identified one missense mutation in the alternative splice region (exon5a) of the *PAX6* gene in a subject with Peters' anomaly. This missense mutation was the substitution from glutamine to arginine at the 13th codon, which is the second reported position in the exon5a.

The Pax family of developmentally regulated transcription factors share an amino terminal DNA binding motif known as the paired domain. The paired domain has a bipartite structure with a highly conserved N-terminal subdomain (NTS) and C-terminal subdomain, which bind distinctive consensus sequences, and the insertion of exon5a into



**Figure 1** Photographs show the anterior segment region. (A) The anterior segment of the patient. She had bilateral Peters' anomaly and showed corneal opacity with iridocorneal adhesion and nystagmus. The best corrected visual acuity was 20/100 (right) and 20/200 (left). The fundus of both eyes could not be seen because of corneal opacity. (B) The anterior segment of patient's father. (C) The anterior segment of patient's mother. (D) The anterior segment of patient's elder brother. No congenital ocular abnormalities of anterior segment region were found in her parents or elder brother.



**Figure 2** (A) Pedigree of the patient (arrow). All of the members represented here were examined. Solid symbol indicates Peters' anomaly and open symbols indicate normal phenotype. Sequence analysis revealed a heterozygous mutation in the alternative splicing region in the patient. However, no mutation was found in her parents or elder brother. (B) Direct sequencing of PAX6 PCR product from the patient with Peters' anomaly showed an A/G heterozygosity at the 38th position which resulted in Q13R in exon 5a (arrow). (B-1) Electropherogram of forward sequence of PAX6 exon 5a. (B-2) Electropherogram of reverse sequence of PAX6 exon 5a. (C) The result of SNaPshot method. (C-1) The patient represents double peaks with green corresponding to A and blue corresponding to G, indicating heterozygous mutation at the base position of 38 which is consistent with sequencing results. (C-2) Normal subjects represent a single peak corresponding to A indicating no mutation at the position. (D) Direct sequencing of PAX6 PCR product from the patient's relatives indicates that they do not have the same mutation.

the N-terminal subdomain abolishes the DNA binding activity of the NTS.<sup>5</sup>

Interestingly, in 1999, Azuma *et al* proved that the mutation in the NTS of the paired domain partially restored the DNA binding activity of the NTS, using functional analyses.<sup>3</sup> In addition, because the amino acids glutamine and arginine belong to hydrophilic and basic amino acid respectively, they have different electronic charges. Therefore, this amino acid substitution may affect the structure of the PAX6 protein and then change DNA binding activity of the paired domain. In other words, such a single amino acid substitution is an important motif as the paired domain such as we have found may severely damage the normal protein function. In fact, except for aniridia, other missense mutations that result in a serious congenital eye disease such as Peters' anomaly or foveal hypoplasia, also exist in the paired domain. The typical clinical presentation with a missense mutation in a highly conserved and functionally important region suggests there is a reasonable likelihood that this sequence variant is caused by the patient's phenotype. Our report adds a novel and potentially structurally significant mutation in the PAX6 gene to the present spectrum of mutations.

Y Nanjo, S Kawasaki, K Mori, C Sotozono,  
T Inatomi, S Kinoshita

Kyoto Prefectural University of Medicine, 465 Kajicho  
Kawaramachi Kamigyo-ku Kyoto, 602-0841, Japan

Correspondence to: Ms Yukako Nanjo, Kyoto  
Prefectural University of Medicine, 465 Kajicho  
Kawaramachi Kamigyo-ku Kyoto, 602-0841, Japan;  
ynanjo@eye.ophth.kpu-m.ac.jp

Accepted for publication 2 October 2003

## References

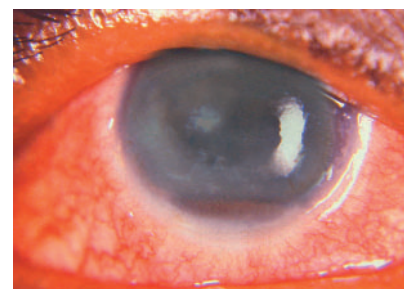
- Hanson IM, Fletcher JM, Jordan T, *et al*. Mutations at the PAX6 locus are found in heterogeneous anterior segment malformations including Peters' anomaly. *Nature Genet* 1994;6:168-73.
- Azuma N, Nishino S, Yanagisawa H, *et al*. PAX6 missense mutation in isolated foveal hypoplasia. *Nature Genet* 1996;13:141-2.
- Azuma N, Yamaguchi Y, Handa H, *et al*. Missense mutation in the alternative splice region of the PAX6 gene in the eye anomalies. *Am J Hum Genet* 1999;65:656-63.
- Saiki RK, Gelfand DH, Stoffel S, *et al*. Primer-directed enzymatic amplification of DNA with a thermostable DNA polymerase. *Science* 1988;239:487-91.
- Epstein JA, Glaser T, Cai J, *et al*. Two independent and interactive DNA-binding subdomains of the Pax6 paired domain are regulated by alternative splicing. *Genes Dev* 1994;8:2022-34.

## Tuberculous intraocular infection presenting with pigmented hypopyon: a clinicopathological case report

Tuberculosis still remains a major cause of morbidity and mortality today. Globally the incidence of this disease is increasing by eight million new cases annually and is a cause of death for two to three million patients every year.<sup>1</sup> The ocular manifestations of tuberculosis are diverse, and depend on the immunological, bacteriological, and epidemiological variables.<sup>2</sup> Individuals with compromised immune status usually present

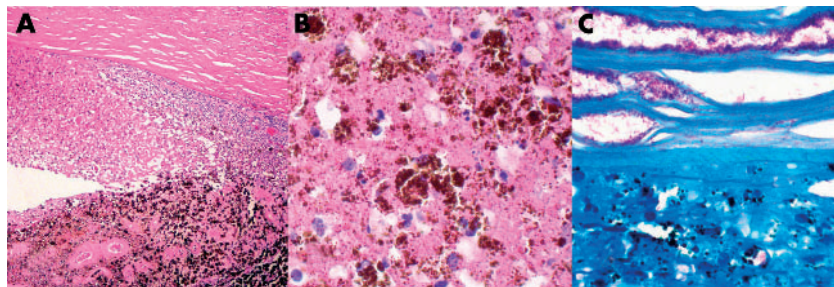
with atypical presentations.<sup>3</sup> This clinicopathological report of a patient treated with immunosuppressive agents shows intraocular tuberculosis presenting with pigmented hypopyon.

A 38 year old female patient with a history of polyarthralgia, anaemia, hypertension, and an impaired renal function with a possible clinical diagnosis of systemic lupus nephropathy underwent renal biopsy, which disclosed membranous glomerulonephropathy with peripheral granular deposits of IgG, Clq, and IgM on immunofluorescence. Her erythrocyte sedimentation rate was elevated (74 mm in the first hour) and she had positive antinuclear antibody; negative rheumatoid factor, VDRL, HIV, and tuberculin skin test (PPD). She was treated with intravenous cyclophosphamide 1 g per day once every month for 3 months and corticosteroids 30 mg/day. At the time of the third intravenous injection of cyclophosphamide, she noticed deterioration of vision in the right eye. On examination, right eye visual acuity was hand movements close to face. The conjunctiva was congested and the cornea was oedematous. The anterior chamber was shallow, and a 3 mm pigmented hypopyon was noted (fig 1). The left eye was unremarkable and the vision was 6/6. Blood and urine cultures showed no growth, and smears of anterior chamber fluid were negative for bacteria and fungi. Oral ciprofloxacin (500 mg twice per day) was started in addition to topical corticosteroids and mydriatics. A week later, the pigmented hypopyon had increased to 5 mm; it was aspirated and submitted for cultures and staining. Ziehl-Nielsen's stain revealed several acid fast bacilli (AFB). The cultures were positive for AFB and the Tuberculosis Research Centre in Chennai, India, identified the organisms as *Mycobacterium tuberculosis* based on pigment production, positive niacin, and catalase test. The patient was re-examined for evidence of systemic tuberculosis. Her PPD was negative and there were no radiological or clinical evidence of extraocular tuberculosis. Despite treatment with four antituberculous drugs (rifampicin 450 mg, isoniazid 300 mg, ethambutol 800 mg, and pyrazinamide 1500 mg), and oral steroids (20 mg) for her polyarthralgia, the patient developed multiple scleral abscesses and lost the remaining vision. She underwent enucleation of the right eye and was continued on antituberculous agents for 6 months. She was continued on tapering dose of systemic corticosteroids for 3 months following a fourth intravenous cyclophosphamide injection. She was followed for two more years and there were no signs of disseminated tuberculosis during that time.



**Figure 1** The right eye shows oedematous cornea with presence of pigmented hypopyon.





**Figure 2** (A) Haematoxylin and eosin stain reveals necrosis of iris and inflammatory exudates in the anterior chamber. (B) The anterior chamber exudate displays several melanophages and necrotic cells (haematoxylin and eosin). (C) Ziehl-Nielsen's stain shows a myriad of acid fast bacilli in the deep corneal stroma and in the anterior chamber exudates.

Histopathological examination of the enucleated eye showed infiltration of acute inflammatory cells and macrophages in the posterior half of the corneal stroma (fig 2). The anterior chamber was filled with pigment containing necrotic cells, macrophages, and proteinaceous exudate. The iris and ciliary body were necrotic and were infiltrated by pigment laden histiocytes. The sclera revealed necrosis with infiltration of acute inflammatory cells. The vitreous cavity contained proteinaceous exudate without significant inflammatory cell infiltration. Acid fast stains disclosed an abundance of AFB deep in the corneal stroma, in the anterior chamber exudates, and in the necrotic iris (fig 2). Histopathological diagnosis was tuberculous necrotising keratouveitis.

### Comment

In this case, the pigmented hypopyon was made up of melanophages. Darkly pigmented hypopyon may appear in eyes harbouring necrotic uveal melanomas in endogenous endophthalmitis caused by *Listeria monocytogenes* and *Serratia marcescens*.<sup>4,5</sup> The cause of dark hypopyon in the endophthalmitis cases was assumed to be a dispersion of melanin from the necrotic iris.<sup>5</sup> The present case also showed necrotic iris and dispensed melanin granules in the anterior chamber, suggesting a common underlying pathology for the formation of pigmented hypopyon. To the best of our knowledge this is the first known case of pigmented hypopyon in a biopsy and culture proved intraocular tuberculosis, and highlights the need for anterior chamber fluid analysis in arriving at the diagnosis.

The clinical spectrum of ocular tuberculous infection includes chronic uveitis, interstitial keratitis, scleritis, sclerouveitis, optic neuritis, choroiditis, retinitis, chorioretinitis, and panophthalmitis.<sup>2,3,6</sup> Hypopyon is rarely noted in tuberculosis. Ni *et al* presented cases of intraocular tuberculous with turbid, haemorrhagic, greyish yellow exudate in the anterior chamber in one case, and fibrinous hypopyon in three other cases.<sup>7</sup> Hypopyon may appear in rifabutin treated patients who had *Mycobacterium avium* complex infection.<sup>8</sup> In all instances, the hypopyon was not darkly pigmented. The clinical and histopathological features suggest that the ocular infection could be endogenous; however, systemic evaluation did not disclose extraocular focus. The presence of large numbers of acid fast organisms in the histological sections suggests that the organisms could be atypical mycobacteria. However, the cultures showed that the organisms were *Mycobacterium tuberculosis*. Presence of such large numbers of the

organisms in the ocular tissue could be from treatment induced immunosuppression.<sup>9</sup>

### Acknowledgements

We thank the Tubercular Research Center (TRC) Chennai, Tamilnadu for conducting biochemical tests for *Mycobacterium tuberculosis*.

**S R Rathinam**

Aravind Eye Hospital, Madurai, India

**N A Rao**

A Ray Irvine Ocular Pathology Laboratory, Doheny Eye Institute, Los Angeles, CA, USA

Correspondence to: S R Rathinam, Aravind Eye Hospital and Postgraduate Institute of Ophthalmology, 1 Anna Nagar Madurai 625 020, Tamil Nadu, India; rathinam@aravind.org

doi: 10.1136/bjo.2003.029124

Accepted for publication 27 September 2003

Supported in part by Research to Prevent Blindness Inc, New York, NY, USA and core grant EYO3040 from the National Institute of Health, Bethesda, MD and Aravind Medical Research Foundation, Tamil Nadu, India

### References

- 1 Raviglione MC, Snider DE Jr, Kochi A. Global epidemiology of tuberculosis. Morbidity and mortality of a worldwide epidemic. *JAMA* 1995;**273**:220–6.
- 2 Dunn JP, Helm CJ, Davidson PT. Tuberculosis. In: Pepose JS, Holland GN, Wilhelmus KR, eds. *Ocular infection and immunity*. St. Louis: Mosby, 1996:1421–9.
- 3 Helm CJ, Holland GN. Ocular tuberculosis (major review). *Surv Ophthalmol* 1993;**38**:229–52.
- 4 Reese AB, Archila EA, Jones IS, *et al*. Necrosis of malignant melanoma of the choroid. *Am J Ophthalmol* 1970;**69**:91–104.
- 5 Elliott D, O'Brien TP, Green WR, *et al*. Elevated intraocular pressure, pigment dispersion and dark hypopyon in endogenous endophthalmitis from *Listeria monocytogenes*. *Surv Ophthalmol* 1992;**37**:117–24.
- 6 Biswas J, Madavan HN, Gopal L, *et al*. Intraocular tuberculosis. Clinicopathologic study of five cases. *Retina* 1995;**15**:461–8.
- 7 Ni C, Palpale JJ, Robinson JL, *et al*. Ocular tumors and other ocular pathology: a Chinese-American collaborative study. *Int Ophthalmol Clin* 1982;**22**:103–24.
- 8 Fineman MS, Vander J, Regillo CD, *et al*. Hypopyon uveitis in immunocompetent patients treated for *Mycobacterium avium* complex pulmonary infection with rifabutin. *Retina* 2001;**21**:531–3.
- 9 Zamir E, Hudson H, Ober R, *et al*. Massive mycobacterial choroiditis during HAART: another immune-recovery uveitis. *Ophthalmology* 2002;**109**:2144–8.

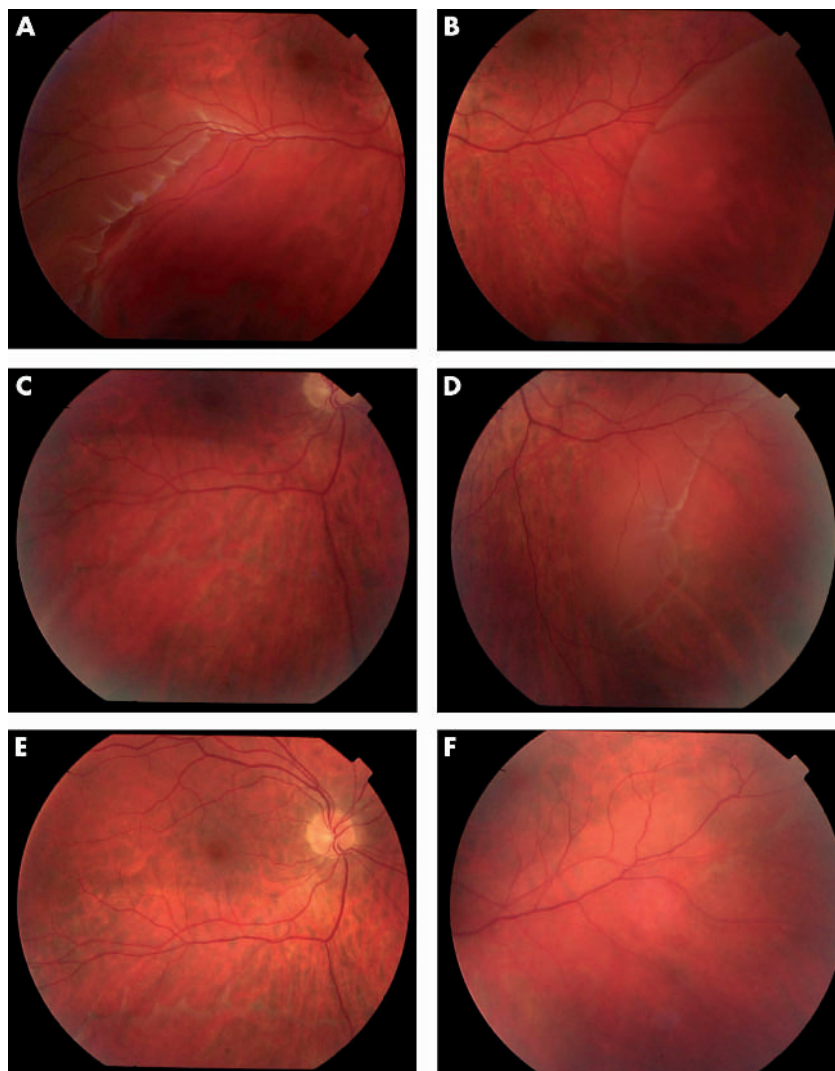
## Spontaneous stabilisation of symptomatic schisis detachments

Acquired retinoschisis affects 7% of people aged >40 years and is bilateral in 85%.<sup>1,2</sup> Although retinoschisis is generally asymptomatic and stable, retinal detachment can supervene in one of three ways. Two of these are rare, are associated with posterior vitreous detachment (PVD), and justify surgical correction; thus, a retinal tear and detachment may originate within non-schitic retina or open breaks in the inner leaf of a schisis may allow fluid vitreous to be recruited into the cyst and thence to pass through breaks in the outer leaf, causing it to separate from the retinal pigment epithelium (RPE) over a wide area. The third mechanism—"schisis detachment"—is quite common (for example, 9% prevalence in Byer's series<sup>3</sup>) and reflects the opening of outer leaf breaks alone. No fluid vitreous gains access to the cyst or subretinal space whether or not inner leaf breaks are present. Schisis detachments remain relatively localised owing to the viscous nature and limited volume of cyst fluid,<sup>3</sup> and the action of the RPE pump can eventually lead to reattachment of the retina and collapse of the cyst. Byer's natural history studies resulted in his recommending that surgery for schisis detachments be limited to eyes with symptomatic progression.<sup>2,3</sup> We present a patient with sequential bilateral schisis detachments, each of which was symptomatic at onset but which settled spontaneously.

### Case report

In March 2000 a 46 year old man was referred with a 2 day history of photopsia and a disturbance in the upper part of the visual field in his right eye. Visual acuity was 6/5 unaided in each eye, and neither eye had a PVD. Funduscopy revealed a schisis detachment inferiorly in the right eye with a curvilinear outer leaf break at the posterior limit of the cyst (fig 1A). The detachment extended midway between the main inferotemporal branch retinal artery and the fovea. The full thickness of retina delineating the superotemporal edge of the outer leaf break had a sawtooth pattern of outer retinal shagreen, while the free inferonasal edge of the break was rolled over. The oedema resolved within a week and no surgical intervention was recommended, merely observation. A bullous inferotemporal retinoschisis was also noted in the left eye, extending almost to the major vascular arcade (fig 1B). During 3 years of follow up, a clinically obvious decrease in the height of the cyst and spontaneous closure of the outer leaf break were observed in the right eye, RPE atrophy indicating the extent of previous retinal detachment (fig 1C and E). Right vision has remained 6/5 albeit with visual field loss superiorly.

In November 2001, photopsia and visual field disturbances were experienced in the left eye. Examination revealed a curvilinear outer leaf break at the posterior limit of the inferotemporal cyst (fig 1D). The associated schisis detachment encroached upon, but did not involve, the left fovea. Given the patient's history, surgery was considered unnecessary. Again the retinoschisis cavity deflated and subretinal fluid slowly absorbed leaving RPE atrophy in its wake (fig 1F). Left vision has remained 6/5 but with an absolute superior nasal scotoma.



**Figure 1** Retinal photographs; (A), (C), and (E) are from the right eye in March 2000, November 2001, and October 2002 respectively; (B), (D), and (F) are from the left eye in March 2000, November 2001, and October 2002 respectively.

### Comment

Most outer leaf breaks develop well within the confines of a retinoschisis, and cyst fluid separates the RPE and outer leaf only in the immediate vicinity of the breaks.<sup>3</sup> However, the giant outer leaf breaks responsible for the schisis detachments in our patient were each located at the posterior limit of a large retinal cyst. It is unsurprising, therefore, that the detachments progressed beyond the retinoschisis and were symptomatic.

This is the first report of symptomatic schisis detachments that settled without surgery. We agree with Byer<sup>2,3</sup> that the appropriate management for non-progressive schisis detachments is "to do nothing," and believe this policy can be extended to symptomatic, inferior schisis detachments that do not involve the fovea. Surgical intervention, including retinopexy around the breaks, might well have induced sight threatening complications in our patient<sup>2,4,5</sup> while offering no real prospect of a better outcome or prognosis.

**J Durnian, W Pollock**

Department of Ophthalmology, Blackpool Victoria Hospital, Blackpool, UK

**D McLeod**

Academic Department of Ophthalmology, Manchester Royal Eye Hospital, Manchester, UK

Correspondence to: Professor D McLeod, Academic Department of Ophthalmology, Manchester Royal Eye Hospital, Oxford Road, Manchester M13 9WH, UK; david.mcleod@man.ac.uk

doi: 10.1136/bjo.2003.029876

Accepted for publication 1 October 2003

### References

- 1 Byer NE. Clinical study of senile retinoschisis. *Arch Ophthalmol* 1968;**79**:36–44.
- 2 Byer NE. Long term natural history study of senile retinoschisis with implications for management. *Ophthalmology* 1986;**93**:1127–37.
- 3 Byer NE. Perspectives on the management of the complications of senile retinoschisis. *Eye* 2002;**16**:359–64.
- 4 Sulonen JM, Wells CG, Barricks ME, et al. Degenerative retinoschisis with giant outer layer breaks and retinal detachment. *Am J Ophthalmol* 1985;**99**:114–21.
- 5 Hoerauf H, Joachimmeyer E, Laqua H. Senile schisis detachment with posterior outer layer breaks. *Retina* 2001;**21**:602–12.

## MAILBOX

### Trypan blue: authors' reply

We would like to thank Dr Rodrigues and colleagues for bringing up this interesting point of what exactly trypan blue stains.<sup>1</sup>

In our study, immunohistochemistry was performed to determine the nature of cells involved in the epiretinal membranes (ERM)—not to determine the presence or absence of the ERM. Presence or absence of ERM was determined by examining routinely stained sections (haematoxylin and eosin, periodic acid Schiff) for cytoplasm/nuclei of epiretinal cell elements. All four of the macular hole internal limiting membrane (ILM) specimens were examined in this way.<sup>2</sup> Furthermore trypan blue (in low concentrations) stains the anterior lens capsule.<sup>3</sup> Since this capsule lacks glia, we do not believe that the evidence supports the contention of the correspondents that the staining of our ILM specimens is due to undetected "glial cell elements of the highly cellular ERM" rather than ILM.

Clinically two features are observed with the use of trypan blue. Firstly, the whole posterior pole that comes into contact with trypan blue is stained a faint blue in all cases. The staining pattern is diffuse and not patchy, suggesting trypan blue staining is indiscriminate of ERM or ILM. Secondly, in cases of macular pucker, the trypan blue stained ERM can be removed separately, leaving intact ILM behind, which can be further stained and removed. In cases of macular hole where a clinical ERM is not present, it appears that only the ILM is stained and peeled. We have harvested these membranes and confirmed that the membranes only consist of ILM and without a secondary ERM.

There is no doubt that trypan blue stains both ERM and ILM. We, however, have no knowledge as to what the structural elements of these membrane that the dye is attached to. We concede that staining of ILM with trypan blue can be variable and sometimes rather faint. Since our publication, Perrier and Sebag have also reported their experience with trypan blue in staining ILM and ERM.<sup>4,5</sup> Although histological findings were not given in these studies, clinically the authors found the dye to be useful in both types of membranes. Given the many concerns regarding the use of indocyanine green,<sup>6</sup> we believe it is a positive development that an alternative clinically useful dye is available.

**K K Li, P Hiscott, D Wong**

The Royal Liverpool University Hospital, Prescot Street, Liverpool L7 8XP, UK

Correspondence to: Dr Kenneth K Li, Prince of Wales Hospital, Shatin, NT, Hong Kong; vitreous@rcsed.ac.uk

Accepted for publication 25 September 2003

### References

- 1 Rodrigues EB, Meyer CH, Schmidt JC, et al. Trypan blue stains the epiretinal membrane but not the internal limiting membrane. *Br J Ophthalmol* 2003;**87**:1431–2.
- 2 Li K, Wong D, Hiscott, et al. Trypan blue staining of internal limiting membrane and epiretinal membrane during vitrectomy: visual results and histopathological findings. *Br J Ophthalmol* 2003;**87**:216–19.
- 3 Melles GR, de Waard PW, Pameyer JH, et al. Trypan blue capsule staining to visualize the capsulorhexis in cataract surgery. *J Cataract Refract Surg* 1999;**25**:7–9.



- 4 Perrier M, Sebag M. Trypan blue-assisted peeling of the internal limiting membrane during macular hole surgery. *Am J Ophthalmol* 2003;135:903-5.
- 5 Perrier M, Sebag M. Epiretinal membrane surgery assisted by trypan blue. *Am J Ophthalmol* 2003;135:909-11.
- 6 Gandorfer A, Haritoglou C, Gass CA, et al. Indocyanine green-assisted peeling of the internal limiting membrane may cause retinal damage. *Am J Ophthalmol* 2001;132:431-3.

## Charles Bonnet syndrome and brimonidine: comments

We read, with interest the article published in the *BJO* by Tomsak *et al.*<sup>1</sup> Interest in the Charles-Bonnet syndrome (CBS) has escalated of late, highlighting the probable 15% incidence of the condition in patients with significant visual impairment coupled with a clear sensorium.<sup>2</sup>

The authors implied that CBS was induced in four patients by brimonidine tartrate on the basis of patient age and the instigation of brimonidine therapy, with discontinuation resulting in eventual resolution of the hallucinations. Firstly, the diagnostic criteria proposed by Gold and Rabins<sup>3</sup> and Podell *et al.*<sup>4</sup> quite rightly made no reference to age being indicative of CBS, although incidence certainly increases with age. Schwartz and Vahgei<sup>5</sup> found that CBS also occurred in children following profound visual loss. This suggests that the high incidence in the elderly population is possibly attributable to the increased incidence of acquired visual loss occurring with age; therefore, age is not a criterion for diagnosis. Further, although the Snellen acuity of all four patients was reasonably good in at least one eye of each patient, it may be surmised that severe visual impairment may have been due to visual field loss secondary to glaucomatous damage. Although this is not clear from the article, the cause of visual impairment and bilaterality are important in the diagnosis of CBS. Indeed, bilateral advanced visual field defects induced by glaucoma and homonymous hemianopia have resulted in CBS.<sup>6,7</sup> A prevailing theory suggests sensory visual deprivation as an integral causative factor in CBS. Interestingly, and supportive of this theory, musical pseudohallucinations have been documented in cases of acquired deafness.<sup>8</sup> Sensory deprivation in the presence of a clear sensorium will be necessary bilaterally to induce CBS, although no lower limit of Snellen visual acuity has been defined as a level for which CBS symptoms are stimulated. In the article case 4 seems to have sufficiently adequate visual function in the right eye to justify a definite misdiagnosis of CBS.

Secondly, as mentioned by the authors,  $\alpha$ -2 agonists have been shown to cause systemic and neuropsychiatric phenomena.<sup>9</sup> As with the discontinuation of any medication, the expectation would be resolution of induced symptoms, and as such we believe the hallucinations may easily be explained as a side effect of the medication. Brimonidine is a known lipophilic compound able to penetrate the blood-brain barrier. Through the accompanying package insert, neurological side effects such as depression and dizziness are well known. There is, therefore, little doubt that in the aged population in whom pharmacokinetics is often unpredictable, the likelihood of greater systemic absorption and distribution may well lead to neuropsychiatric phenomena. Consequently, we believe

that CBS was not the cause of the complex visual hallucinations experienced by these patients but may be attributed to a rarer side effect of brimonidine, which should now be included in the patient information leaflet.

I Rahman, B Fernando, M Harrison

Manchester Royal Eye Hospital, Lister Centre, Nelson Street, Manchester M1, UK

Correspondence to: Mr Imran Rahman, Manchester Royal Eye Hospital, Lister Centre, Nelson Street, Manchester M1, UK; imran1973@tiscali.co.uk

Accepted for publication 3 October 2003

## References

- 1 Tomsak RL, Zaret CR, Weidenthal D. Charles Bonnet syndrome precipitated by brimonidine tartrate eye drops. *Br J Ophthalmol* 2003;87:917.
- 2 Menon GJ, Rahman I, Menon SJ, et al. Complex visual hallucinations in the visually impaired: the Charles Bonnet syndrome. *Surv Ophthalmol* 2003;48:58-72 (major review).
- 3 Gold K, Rabins PV. Isolated visual hallucinations and the Charles-Bonnet syndrome: a review of the literature and presentation of six cases. *Compr Psychiatry* 1989;30:90-8.
- 4 Podoll K, Osterheider M, Noth J. Das Charles Bonnet syndrom. *Fortschr Neurol Psychiat* 1989;57:43-60.
- 5 Schwartz TL, Vahgei L. Charles Bonnet syndrome in children. *J AAPOS* 1998;2:310-3.
- 6 Damas-Mora J, Skelton-Robinson M, Jenner FA. The Charles Bonnet syndrome in perspective. *Psychol Med* 1982;12:251-61.
- 7 Dodd J, Heffernan A, Blake J. Visual hallucinations associated with Charles Bonnet syndrome—an ever increasing diagnosis. *Ir Med J* 1999;92:344-5.
- 8 Griffiths TD. Musical hallucinosis in acquired deafness: phenomenology and brain substrate. *Brain* 2000;123:2065-76.
- 9 Kim DD, Bay G. A case of suspected alphanon-induced psychosis. *Arch Ophthalmol* 2000;118:1132-3.

## Periocular corticosteroid therapy: comments

I read with great interest the article by Okada *et al.*<sup>1</sup> reporting the efficacy and complications of trans-Tenon's retrobulbar infusion of triamcinolone acetonide for posterior uveitic inflammation. The authors have to be commended for the excellent description of this novel technique.

The efficacy of various methods of corticosteroid injection has always been a matter of debate with different studies giving different results. McCartney *et al.*<sup>2</sup> showed that the major route of penetration of steroids after subconjunctival injection was directly through the adjacent sclera, choroid, and retina. In addition, the authors described methods to inject steroids in the sub-Tenon's space and concluded that the injections should be placed immediately adjacent to the site of intraocular inflammation that was under treatment. In contrast, in a study on rabbit eyes, Wilson *et al.*<sup>3</sup> have elegantly demonstrated that injection of corticosteroids by the sub-Tenon's route does not show a significant effect on the blood-retinal barrier owing to inadequate penetration. The authors analysed the severity of blood-retinal barrier breakdown following panretinal photocoagulation, using rapid sequential magnetic resonance image with contrast. Of note, in this study the authors have taken particular care to ensure the accurate placement of the

needle in the sub-Tenon's space. A similar result was obtained in a study Jennings *et al.*<sup>4</sup> on the efficacy of posterior sub-Tenon's injections in patients with cystoid macular oedema caused by uveitis. The authors found that the injection of steroids by the sub-Tenon's route did not consistently affect the blood-retinal barrier permeability in such patients and that there was no diffusion of the steroids into the eye in therapeutically meaningful concentrations. This is of particular concern since it is the breakdown in the blood-retinal barrier that leads to influx of serum/serum components leading to macular oedema, epiretinal membrane, and other sequelae.

Sub-Tenon's injections when compared to intravitreal injections have the disadvantage of probably a decreased and difficult drug penetration through the sclera and choroid and a rapid removal of the drug by the choroidal circulation after penetration with the resultant shortened duration of action. This is probably the reason why the sub-Tenon's route of injection of steroids has not become popular in diabetic macular oedema in contrast with the increased popularity of intravitreal steroid injections.

Interestingly, Freeman *et al.*<sup>5</sup> have postulated that the lack of therapeutic response to sub-Tenon's corticosteroids may be because of placement at a site relatively far from the target zone. They determined the location of repository corticosteroid after sub-Tenon's injection by echography and showed that the steroid was deposited within the sub-Tenon's space over the macula in only 11 of 24 cases. They hence concluded that the therapeutic response manifested by improvement in macular function may be related to the proximity of the corticosteroid to the macular area. The impressive efficacy reported in the study by Okada *et al.*<sup>1</sup> could probably be the result of reliable drug placement thanks to the visual confirmation of cannula entry into the sub-Tenon's space, as the authors speculate. However, it is important to note that most of the patients in this study continued to receive topical steroid drops. Whether these drops had an additive effect is unclear.

It would probably be worthwhile to consider a planned, primary intravitreal injection of corticosteroids under aseptic conditions that has the distinct advantage of getting distributed into a much larger volume for selected conditions. There would be no cases of "therapeutic failures" that are seen after injection of steroids into the sub-Tenon's space and the resultant confusion as to whether the unsatisfactory response is secondary to the disease process or failure to inject the steroid into the sub-Tenon's space or the debated lower efficacy of this route of injection. The procedure is simpler than the described trans-Tenon's retrobulbar infusion (no special cannula is required), but the risk of endophthalmitis is daunting.<sup>6</sup>

V Vedantham

Aravind Eye Hospital and Postgraduate Institute of Ophthalmology, 1 Anna Nagar, Madurai, Tamil Nadu, India; drvasumathy@yahoo.com

Accepted for publication 3 October 2003

## References

- 1 Okada AA, Wakabayashi T, Morimura Y, et al. Trans-Tenon's retrobulbar triamcinolone infusion for the treatment of uveitis. *Br J Ophthalmol* 2003;87:968-71.

- 2 **McCartney HJ**, Drysdale IO, Gornall AG, *et al.* An autoradiographic study of the penetration of subconjunctivally injected hydrocortisone into normal and inflamed rabbit eyes. *Invest Ophthalmol* 1965;4:297.
- 3 **Wilson CA**, Berkowitz BA, Sato Y, *et al.* Treatment with intravitreal steroid reduces blood-retinal barrier breakdown due to retinal photocoagulation. *Arch Ophthalmol* 1992;110:1155-9.
- 4 **Jennings T**, Rusin MM, Tessler HH, *et al.* Posterior sub-Tenon's injections of corticosteroids in uveitis patients with cystoid macular edema. *Jpn J Ophthalmol* 1988;32:385-91.
- 5 **Freeman WR**, Green RL, Smith RE. Echographic localization of corticosteroids after periocular injection. *Am J Ophthalmol* 1987;103(Pt 1):281-8.
- 6 **Benz MS**, Murray TG, Dubovy SR, *et al.* Endophthalmitis caused by *Mycobacterium chelonae* abscessus after intravitreal injection of triamcinolone. *Arch Ophthalmol* 2003;121:271-3.

## Transcaruncular approach for the management of frontoethmoidal mucoceles: a comment

We read the article by Lai *et al*<sup>1</sup> with interest.

The authors report a modification of the non-obliterative external procedure that was first described by Lynch in 1921.<sup>2</sup> The Lynch-Howarth procedure<sup>2-4</sup> involved transnasal stenting to prevent medial-ward collapse of the orbit obstructing drainage from the frontal sinus into the nose. Although the transcaruncular procedure uses a different external approach, it nevertheless often involves removal of part of the lamina papyracea for access to the sinuses. Hence, as with the Lynch approach, prolapse of orbital contents into the defect may occur, increasing the risk of re-stenosis. In addition, the cells in the frontal recess are not formally cleared and thus drainage into the nasal cavity is not assured. Stenting of sinus openings results in a significant fibrotic reaction in a proportion of patients, and closure of such a previously stented opening is likely. Furthermore, the follow up period in this study is too short to confirm the success or failure of this technique as recurrence often takes years to manifest.<sup>4</sup>

Endoscopic management of mucoceles protruding into the other sinuses or nasal cavity has been an accepted treatment for years.<sup>3-9</sup> Frontoethmoidal mucoceles are typical of such mucoceles where the bony wall surrounding the mucocele is thin and therefore easily accessible transnasally. The endoscopic procedure creates a large area clear of cells which allows the greatest possible marsupialisation of the mucocele. No stenting is required. Har-El<sup>9</sup> reported the largest series of 108 mucoceles with a median follow

up of 4.7 years with a recurrence rate of only 0.9%. Therefore, we would recommend an endoscopic approach for frontoethmoidal mucoceles as the integrity of the lamina papyracea is maintained and the largest possible opening is created into the mucocele, which in turn minimises the chances of recurrence.

**J J Khong, P Wormald, D Selva**

Royal Adelaide Hospital, North Terrace, Adelaide, Australia

Correspondence to: Dr Jwu Jin Khong, Royal Adelaide Hospital, North Terrace, Adelaide, Australia; jikhong@yahoo.com

Accepted for publication 3 October 2003

## References

- 1 **Lai PC**, Liao SL, Jou JR, *et al.* Transcaruncular approach for the management of frontoethmoidal mucoceles. *Br J Ophthalmol* 2003;87:699-703.
- 2 **Lynch RC**. The technique of a radical frontal sinus operation which has given me the best results. *Laryngoscope* 1921;31:1-5.
- 3 **Ritter FN**, ed. Surgical procedures on the paranasal sinuses: the frontal sinus. In: *The paranasal sinuses: surgery and technique*, 2nd ed. St Louis: Mosby, 1978:136-45.
- 4 **Neel HB**, McDonald TJ, Facer GW. Modified Lynch procedure for chronic frontal sinus diseases: rationale, technique, and long-term results. *Laryngoscope* 1987;97:1274-9.
- 5 **Kennedy DW**, Josephson JS, Zinreich SJ, *et al.* Endoscopic sinus surgery for mucoceles: a viable alternative. *Laryngoscope* 1989;99:885-95.
- 6 **Schaefer SD**, Close LG. Endoscopic management of frontal sinus disease. *Laryngoscope* 1990;100:155-60.
- 7 **Har-El G**, Balwally AN, Lucente FE. Sinus mucoceles: is marsupialization enough? *Otolaryngol Head Neck Surg* 1997;117:633-40.
- 8 **Lund VJ**. Endoscopic management of paranasal sinus mucoceles. *J Laryngol Otol* 1998;112:36-40.
- 9 **Har-El G**. Endoscopic management of 108 sinus mucoceles. *Laryngoscope* 2001;111:2131-4.

## NOTICES

### Cataract surgery

The latest issue of *Community Eye Health* (No 48) discusses a solution to reduce worldwide cataract blindness, including sutureless non-phaco cataract surgery. For further information please contact: Journal of Community Eye Health, International Resource Centre, International Centre for Eye Health, Department of Infectious and Tropical Diseases, London School of Hygiene and Tropical Medicine, Keppel Street, London WC1E 7HT, UK

(tel: +44 (0)20 7612 7964; email: Anita.Shah@lshtm.ac.uk; website: www.jceh.co.uk). Annual subscription (4 issues) UK£28/US\$45. Free to developing country applicants.

### Elimination of avoidable blindness

The 56th World Health Assembly (WHA) considered the report on the elimination of avoidable blindness (doc A56/26) and urged Member States to: (1) Commit themselves to supporting the Global Initiative for the Elimination of Avoidable Blindness by setting up a national Vision 2020 plan by 2005; (2) Establish a national coordinating committee for Vision 2020, or a national blindness prevention committee to help implement the plan; (3) Implement the plan by 2007; (4) Include effective monitoring and evaluation of the plan with the aim of showing a reduction in the magnitude of avoidable blindness by 2010; (5) To support the mobilisation of resources for eliminating avoidable blindness. The WHA also urged the Director-General to maintain and strengthen WHO's collaboration with Member States and the partners of the Global Initiative for the Elimination of Avoidable Blindness as well as aid in the coordination and support of national capability.

### XVth Meeting of the International Neuro-Ophthalmology Society

The XVth Meeting of the International Neuro-Ophthalmology Society will take place 18-22 July 2004, in Geneva, Switzerland. Further details: Prof. A Safran, University Hospital Geneva, c/o SYMPORG SA, Geneva (fax: +4122 839 8484; email: info@symporg.ch; website: www.symporg.ch).

### 4th International Congress on Autoimmunity

The 4th International Congress on Autoimmunity will take place 3-7 November 2004 in Budapest, Hungary. The deadline for the receipt of abstracts is 20 June 2004. Further details: Kenes International Global Congress Organisers and Association Management Services, 17 Rue du Cendrier, PO Box 1726, CH-1211 Geneva 1, Switzerland (tel: +41 22 908 0488; fax: +41 22 732 2850; email: autoim04@kenes.com; website: www.kenes.com/autoim2004).

### XVI International Congress for Eye Research

The XVI International Congress for Eye Research will be held on 29 August - 3 September 2004 in Sydney, Australia. For further information, please contact: icer2004@tourhosts.com.au (website: www.tourhosts.com.au/icer2004).