

Postscript

LETTERS

If you have a burning desire to respond to a paper published in *BJO*, why not make use of our "rapid response" option?

Log onto our website (www.bjophthalmol.com), find the paper that interests you, and send your response via email by clicking on the "eletters" option in the box at the top right hand corner.

Providing it isn't libellous or obscene, it will be posted within seven days. You can retrieve it by clicking on "read eletters" on our homepage.

The editors will decide as before whether to also publish it in a future paper issue.

Orbital varices and orbital wall defects

Orbital varices are a vascular hamartoma typified by a plexus of low pressure, low flow, thin walled and distensible vessels that intermingle with the normal orbital vessels.¹⁻⁴ If freely communicating with the orbital circulation, engorgement of varices can occur by increasing venous pressure through the Valsalva manoeuvre,⁵ bending posture,⁶ coughing or straining and these, in turn, lead to the clinical characteristics of variable proptosis, intermittent pain, and orbital haemorrhage.^{7,8}

Observation is usually warranted for small lesions, but surgical intervention may be necessary in advanced cases: indications for surgical intervention include non-resolving episodes of thrombosis, severe disfiguring proptosis or displacement of the globe, and optic nerve compression.¹⁻³ Surgery can be extremely difficult, as varices are very friable and intimately intermixed with normal orbital structures; there is also a significant risk of visual loss as a result of haemorrhage or optic nerve damage, the latter being generally caused by vascular compromise.^{9,10} The association of orbital venous anomalies with orbital wall defects provides a further source of surgical difficulty because of the close proximity of intracranial structures and the continuity with extraorbital or intracranial venous anomalies.

Case series

The orbital database, at Moorfields Eye Hospital, was used to identify patients with a clinical diagnosis of low pressure orbital varices and their orbital imaging (computed tomography and/or magnetic resonance image) was reviewed. Images were examined for evidence of orbital expansion, osseous defects of the orbit, nose or sinuses, and anomalies of the frontal lobes. Patients who had either orbital or intracranial surgery before the date of imaging were excluded from the investigation.

The clinical diagnosis of orbital varices was identified in 310 patients, and imaging was available for 223 patients (72%). Six patients with previous orbital or intracranial surgery were excluded and nine cases (4%) had

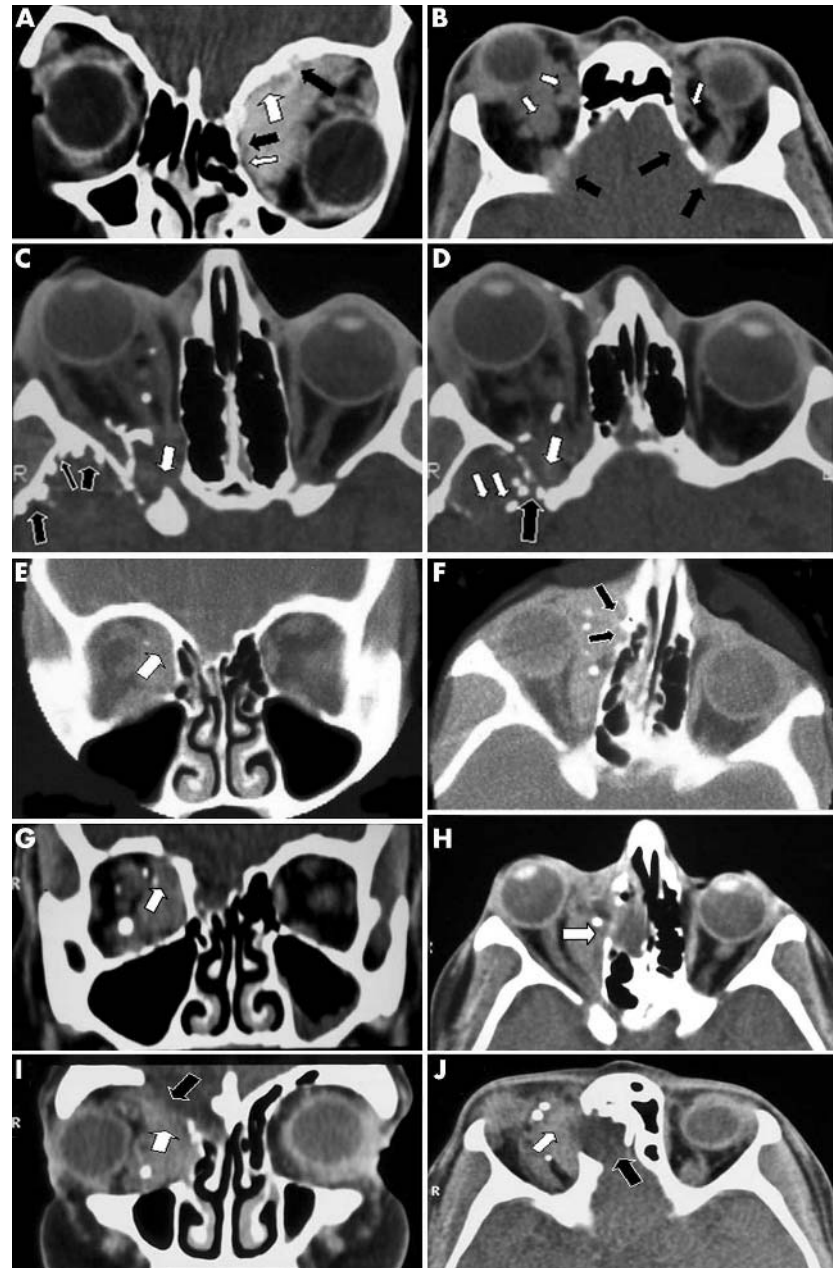


Figure 1 (A) (Patient 1) Extensive left orbital varices (white arrows) causing orbital expansion, globe displacement, and "pitting" of the orbital roof and lamina papyracea (black arrows). (B) (Patient 5) Bilateral orbital varices associated with multiple defects, rather than pitting, of the orbital walls. (C) (Patient 6) Right orbital varices, with phleboliths, extending through the orbital apex into the middle cranial fossa (white arrows) and (D) associated with intracranial bone "pitting" and "defects" (black arrows). (E) Coronal and (F) axial CT scans of patient 2 with superonasal varices (white arrows) of right orbit in 1981. (G-J) Repeat coronal and axial CT scans in 2001 show significant enlargement of the bone defect with complete loss of mineralisation, and expansion of the frontal lobe meninges into the orbital wall defect (black arrow).

associated anomalies of the neighbouring orbital walls (table 1).

Four cases (patients 1-4) were associated with "pitting" of the orbital wall secondary to orbital varices (fig 1A). Another three cases (patients 6-8) were associated with enlarged

superior orbital fissure and two cases (patients 5 and 9) with multiple orbital roof "defects" (fig 1B). Orbital varices were present up to the dural space in two cases (patients 4 and 5), and involved the frontal lobe parenchyma in one case (patient 6; fig 1C, D).

Table 1 Characteristics of nine patients with orbital wall defects in association with orbital varices

No	Side	Age (years) at referral	Sex	Main location of orbital varix	Expansion of orbit	Absent walls	Ethmoid	Cribriform	Frontal
1	Left	6	M	Medial and extensive superomedial	Present	Small roof defect	Pitted bone and smaller ethmoid	L-low R-normal	Dips low at cribriform
2	Right	21	F	Extraconal-medial	Present	Tiny thin area SNQ	Pitted bone and smaller ethmoid	R-low L-mild	Low frontal lobe over cribriform
3	Left	62	M	Superomedial	Present	Pitted roof and small defects of veins	Compressed	Normal	Hint of varix but otherwise normal
4	Right	58	F	Panorbit intraconal and extraconal	Present	Post superior wall and pitted bone	Normal	Normal	Varices up to frontal lobe and intraconal
5	Right	47	M	Panorbit intraconal and extraconal	Absent	Posterior orbital roof	Normal	Normal	Varices up to dural space
6	Right	14	F	Posterior intraconal, superior extraconal	Present	Enlarged SOF	Normal	Normal	Varices into frontal lobe
7	Left	40	F	Posterior intraconal	Present	Enlarged SOF and small lateral wall	Slightly smaller	Unknown	Normal
8	Left	37	F	Posterior intraconal and extraconal	Present	Very enlarged SOF, patchy SNQ defects posteriorly	Normal	Normal	Normal
9	Left	66	M	Extraconal-superior (large)	Present	Posterior orbital roof	Slightly smaller	Normal	Normal

SNQ = superonasal quadrant; SOF = superior orbital fissure.

One patient (case 2) had thinning of the superonasal quadrant of the orbital wall, nasal orbital wall pitting, and a low ipsilateral cribriform plate, when first seen at age 21 in 1981 (fig 1E, F). On repeat imaging 20 years later (2001), this patient was noted to have developed proptosis, a defect in the superonasal wall of the orbit, and a new mid-line nasal encephalocele (fig 1I, J).

Comment

Fine cut (3 mm) orbital CT scans easily delineate varices and diagnostic phleboliths, which occur from thrombus formation,⁷ and provide an excellent natural contrast between brain, bone, and varix. The typical findings for varices include an ill defined multiloculated mass, with some patchy contrast enhancement, in communication with the neighbouring orbital circulation⁴⁻⁷; diffuse expansion of the orbital walls is well recognised in some cases, especially in childhood lesions.

Several factors may have biased the study population: many are symptomatic patients, having been referred from other ophthalmic units in consideration for surgical intervention. The apparent incidence of orbital wall defects (4%) in our series may, therefore, be a slight overestimate. In a minority of patients, orbital varices may be associated with orbital wall defects, and such defects may, eventually, lead to an encephalocele formation. Clinicians should be aware of these, apparently unreported, associations before embarking on surgical intervention for orbital varices.

N Islam, K Mireskandari, G E Rose
Moorfields Eye Hospital, London EC1V 2PD, UK

Correspondence to: Mr G E Rose, Orbital Service, Moorfields Eye Hospital, City Road, London EC1V 2PD, UK;

doi: 10.1136/bjo.2003.024547

Accepted for publication 10 July 2003

References

1 **Rootman J.** *Diseases of the orbit. A multidisciplinary approach*, 2nd ed. Philadelphia: Lippincott Williams and Wilkins, 2002:517-22.

2 **Beyer R, Levine MR, Sternberg I.** Orbital varices: a surgical approach. *Ophthalm Plast Reconstr Surg* 1985;1:205-10.
 3 **Wright JE, Sullivan TJ, Garner A, et al.** Orbital venous anomalies. *Ophthalmology* 1997;104:905-13.
 4 **Rubin PAD, Remulla HD.** Orbital venous anomalies demonstrated by spiral computed tomography. *Ophthalmology* 1997;104:1463-70.
 5 **Shields JA, Dolinskas C, Augsburger JJ, et al.** Demonstration of orbital varix with computed tomography and Valsalva manoeuvre. *Am J Ophthalmol* 1984;97:108-10.
 6 **Cohen JA, Char DH, Norman D.** Bilateral orbital varices associated with habitual bending. *Arch Ophthalmol* 1995;113:1360-2.
 7 **Bullock JD, Goldberg SH, Connelly PJ.** Orbital varix thrombosis. *Ophthalmology* 1990;97:251-6.
 8 **Feroozan R, Shields CL, Shields JA, et al.** Congenital orbital varices causing extreme neonatal proptosis. *Am J Ophthalmol* 2000;129:693-4.
 9 **Harris GJ, Sakol PJ, Bonavolonta G, et al.** An analysis of thirty cases of orbital lymphangioma. Pathophysiologic considerations and management recommendations. *Ophthalmology* 1990;97:1583-92.
 10 **Weill A, Cognard C, Castaigns L, et al.** Embolization of an orbital varix after surgical exposure. *Am J Neuroradiol* 1998;19:921-3.

Exenteration of invasive conjunctival squamous cell carcinoma

Ocular surface squamous neoplasia (OSSN) includes conjunctival intraepithelial neoplasia with dysplasia, carcinoma in situ and conjunctival squamous cell carcinoma (SCC). Beside ultraviolet B irradiation identified as an risk factor, OSSN is associated with human papillomavirus type 16 and 18 (HPV-16, HPV-18).¹⁻⁵ The exact role and possible prognostic value of p53 overexpression is unclear and little is known about its expression during the development of conjunctival SCC.

Case reports

Patient 1

A 75 year old man was referred with a 10 year history of a conjunctival mass of the left eye with visual acuity of hand movement.

Previous biopsies had revealed conjunctival dysplasia. On examination, the tumour of the ocular and tarsal conjunctiva of the lower lid covered the entire corneal surface (fig 1A).

Patient 2

A 90 year old patient presented with a 2 year history of an extensive conjunctival papillomatous tumour of the left eye covering three quarters of the cornea with visual acuity of light perception. A full thickness biopsy was performed.

Both patients underwent orbital exenteration including removal of the eyelids. Histopathologically the focal invasive, completely removed tumour of patient 1 grew in a papillomatous manner. The tumour cells of the conjunctival neoplasm showed strongly enlarged nuclei with prominent nucleoli, and formed cohesive units with intercellular bridges (fig 1B).

The exophytic tumour of patient 2 was predominantly intraepithelial with foci of subepithelial invasion. Focal tumour anaplasia was observed in the otherwise moderately differentiated tumour with squamous cell differentiation.

Immunostaining of both specimens revealed strong p53 (monoclonal mouse-anti-human p53-protein DO-7, Dako) over-expression (>26% of epithelium cells) and low expression of p21 (<6% of epithelium cells) of the invasive region of the tumour indicating an inactivating p53 mutation (fig 1C). While in patient 1 expression for p53 was found in all epithelial layers, in patient 2 it was expressed suprabasally. In contrast, both p53 and p21 showed moderate reactivity in the dysplastic region up to the middle layer of the tumour (fig 1D). In the apical layer epithelium cells were occasionally p21 positive.

Immunostaining for HPV (HPV screening antibody, Virofem Diagnostica, Germany) was positive in patient 1.

Comment

The high recurrence rate of OSSN of 9-64% after resection seems to depend on the histopathological grade and status of surgical margins.⁵ HPV-16 and HPV-18 are considered

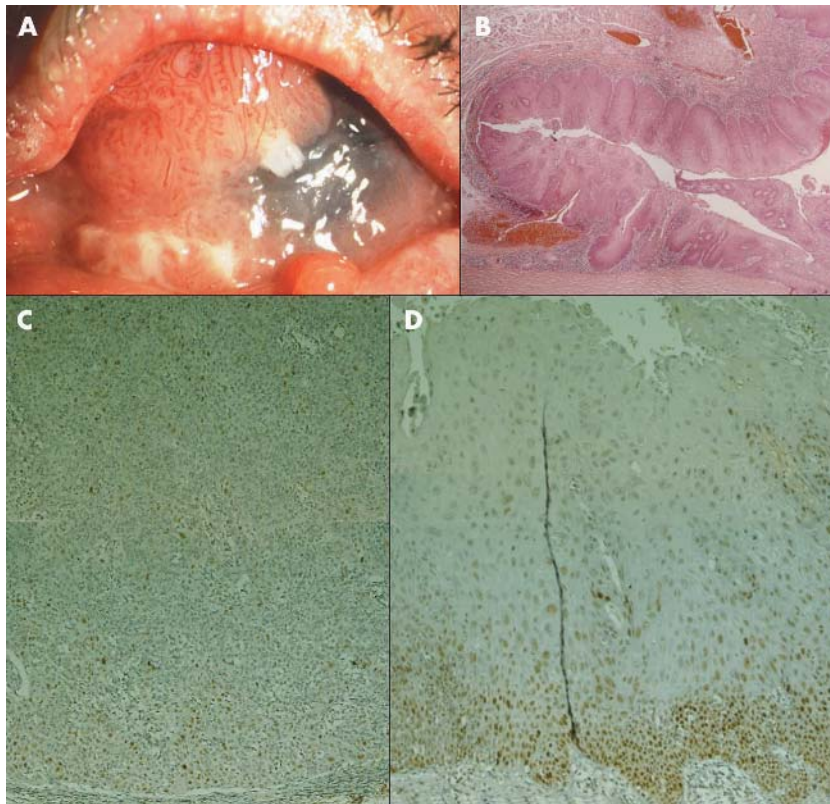


Figure 1 Patient 1. (A) Extensive papillomatous tumour, subtotally covering the corneal surface of the left eye. Nodular thickening of the lower eyelid indicates eyelid involvement. (B) Histological appearance. Papillomatous pattern of the large epithelial lesion with focal invasion above the cornea. Subepithelially, inflammatory cells and some dilated vessels (haematoxylin and eosin, original magnification, $\times 2.5$). (C) p53, showing strong diffuse reactivity in invasive region indicating an inactivating p53 mutation (original magnification, $\times 10$). (D) p53, showing moderate expression predominantly in the suprabasal layers in dysplastic conjunctiva of the same specimen (original magnification, $\times 10$).

to be possible cofactors involved in initiation and early progression of OSSN.^{1-4,7} Though both of the presented tumours were clinically papillomatous, immunostaining for HPV was positive only in patient 1.

The tumour suppressor gene p53 has been found to be inactivated in over 50% of human cancers. In OSSN, overexpression of p53 has been previously reported in some SCC of conjunctiva.^{6,7} In the SCC of our patients, p53 overexpression indicating inactivating p53 mutations were observed only in the invasive part of the tumour, but not in the carcinoma in situ. While Dushku and coworkers assumed that p53 mutations could be an early event in tumour development consistent with ultraviolet radiation, our findings clearly indicate that mutations of p53 are a late event that occur with disease progression, as observed with other solid tumours.^{7,8} Karcioğlu and associates found a correlation between p53 overexpression and unfavourable clinical course.⁹ In contrast, Aoki and colleagues found no expression for p53 in SCC but positive staining in dysplasia.¹⁰

Our results of two exenterated advanced stages of SCC emphasise the necessity to remove dysplastic OSSN completely to prevent progression to invasive carcinomas. Identification of inactivating p53 mutations may indicate an increased risk for invasiveness. Therefore immunohistochemical analysis of biopsy specimen may help in the management of these tumours.

R Guthoff, W E Lieb

Department of Ophthalmology, Julius Maximilians University Würzburg, Germany

P Ströbel, A Zettl

Institute of Pathology, Julius Maximilians University Würzburg, Germany

Correspondence to: Dr R Guthoff, Universitäts-Augenklinik, Josef-Schneider-Strasse 11, 97080 Würzburg, Germany; r_guthoff@yahoo.de

doi: 10.1136/bjo.2003.038588

Accepted for publication 7 December 2003

References

- 1 **McDonnell JM**, Mayr AJ, Martin WJ. DNA of human papillomavirus type 16 in dysplastic and malignant lesions of the conjunctiva and cornea. *N Engl J Med* 1989;**320**:1442-6.
- 2 **McDonnell JM**, McDonnell PJ, Sun YY. Human papillomavirus DNA in tissues and ocular surface swabs of patients with conjunctival epithelial neoplasia. *Invest Ophthalmol Vis Sci* 1992;**33**:184-9.
- 3 **Nakamura Y**, Mashima Y, Kameyama K, *et al*. Detection of human papillomavirus infection in squamous tumours of the conjunctiva and lacrimal sac by immunohistochemistry, in situ hybridisation, and polymerase chain reaction. *Br J Ophthalmol* 1997;**81**:308-13.
- 4 **Karcioğlu ZA**, Issa TM. Human papilloma virus in neoplastic and non-neoplastic conditions of the external eye. *Br J Ophthalmol* 1997;**81**:595-8.
- 5 **Lee GA**, Hirst LW. Ocular surface squamous neoplasia. (Review) *Surv Ophthalmol* 1995;**39**:429-50.
- 6 **Toth J**, Karcioğlu ZA, Moshfeghi AA, *et al*. The relationship between human papillomavirus and p53 gene in conjunctival squamous cell carcinoma. *Cornea* 2000;**19**:159-62.
- 7 **Dushku N**, Hatcher SL, Albert DM, *et al*. p53 expression and relation to human papillomavirus infection in pingueculae, pterygia, and limbal tumors. *Arch Ophthalmol* 1999;**117**:1593-9.
- 8 **Gryfe R**, Swallow C, Bapat B, *et al*. Molecular biology of colorectal cancer. *Curr Probl Cancer* 1997;**21**:233-300.
- 9 **Karcioğlu ZA**, Toth J. Relation between p53 overexpression and clinical behavior of ocular/orbital invasion of conjunctival squamous cell carcinoma. *Ophthalm Plast Reconstr Surg* 2000;**16**:443-9.
- 10 **Aoki S**, Kubo E, Nakamura S, *et al*. Possible prognostic markers in conjunctival dysplasia and squamous cell carcinoma. *Jpn J Ophthalmol* 1998;**42**:256-61.

Familial pseudotumoral sclerochoroidal calcification associated with chondrocalcinosis

Sclerochoroidal calcification is the deposition of calcium at the level of the sclera and choroid. Two entities have been described: metastatic calcifications resulting from deposition of calcium in normal tissues caused by phosphocalcic metabolism abnormality such as primary and secondary hyperparathyroidism,¹ pseudohypoparathyroidism, hypervitaminose D, vitamin D intoxication, hypophosphataemia, sarcoidosis, Bartter syndrome, and Gitelman syndrome²³; and dystrophic calcifications caused by secondary deposition of calcium in abnormal tissues despite normal serum levels of calcium and phosphate.

Sclerochoroidal calcifications can also be idiopathic.⁴ We describe the first case of hereditary form of sclerochoroidal calcifications associated with familial articular chondrocalcinosis.

Case report

A 69 year old man was admitted to the department of ophthalmology in November 1999 with gradual deterioration of vision in both eyes. He had a medical history of articular chondrocalcinosis. His father, brother, and son were treated for the same disease.

On examination, best corrected visual acuity was 20/20 in the right eye and finger counting in the left eye. Slit lamp examination and ocular tension were normal. The funduscopy revealed multiple bilateral pseudotumoral white choroidal masses in both eyes (fig 1). Ultrasound examination of the eyes confirmed the calcific nature of the lesions.

On fluorescein angiography in March 1979 the pseudotumoral lesions were smaller and did not involve the macular area in left eye (fig 1, left).

He had an extensive metabolic evaluation in the Broussais department of physiology that was normal. The systemic diagnosis was familial articular chondrocalcinosis.

We decided to examine the whole family to search for ophthalmic abnormalities linked with familial chondrocalcinosis.

The 74 year old brother and the 40 year old son also suffered from chronic articular chondrocalcinosis. Their best visual acuity was 20/20 in both eyes.

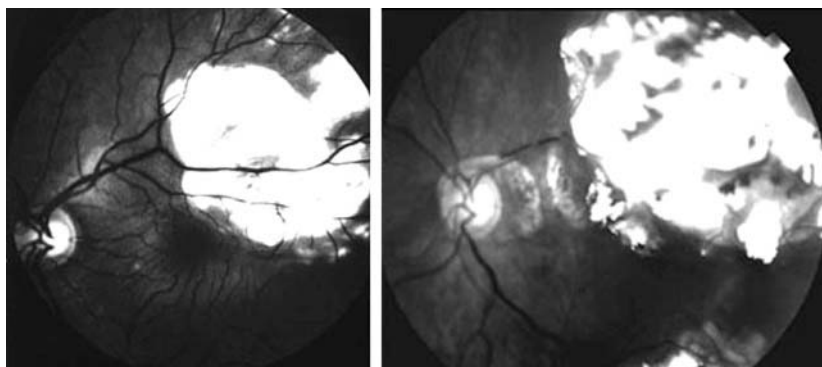


Figure 1 Fluorescein angiography of the 69 year old patient in 1979 (left) and 2000 (right) showing evolution of the sclerochoroidal calcifications with time.

The brother's funduscopy revealed multiple bilateral, extrafoveal pseudotumoral white choroidal masses (fig 2, top). The son's funduscopy revealed plaque-like and only slightly elevated lesions seen in the mid-periphery (fig 2, bottom). Ultrasonograms confirmed the calcific nature of these lesions.

Comment

In 1997, Shields *et al*⁵ described a case of sclerochoroidal calcifications in a normocalcaemic patient who had chondrocalcinosis.

We first describe a familial case of sclerochoroidal calcifications associated with calcium pyrophosphate dihydrate (CPPD). In this family, autosomal dominant inheritance is highly likely because there are affected individuals in each generation, there is male to male transmission, and every affected member has an affected parent.

Inheritance in sclerochoroidal calcifications has never been described; however, hereditary forms of chondrocalcinosis have already been described.

In our report, a patient had a 24 year follow up showing a progressive involvement of the macular area, suggesting a growth of the calcifications. Two types of calcifications have been described previously, the plaque-like and the pseudotumoral type.

To our knowledge, it has never been determined if the plaque-like lesions evolve into tumour-like lesions. In 1992, Schachat and associates⁶ reported 10 cases with follow up ranging from 7 months to 10 years, for whom no change in the lesion was seen. This is the first observation with 24 years of follow up suggesting a possible evolution of plaque-like lesions to pseudotumoral lesions.

We suggest that every patient affected by familial chondrocalcinosis should have an ophthalmic examination to detect sclerochoroidal calcification. These lesions seem to be evolving in time with possible involvement of the macula. Choroidal neovascularisation is also a vision threatening complication of sclerochoroidal calcifications.⁷ Our case suggest the need to perform ophthalmological

examination in patients and family members of patients affected by chondrocalcinosis.

S Boutboul, T Bourcier, J-P Heligon, P Houiller, M Ullern, M Abitbol, V Borderie, L Laroche
CHNO des XV-XX, 28, Rue de Charenton 75571 Paris
Cedex 12 Paris, France

Correspondence to: Dr Sandrine Boutboul, CHNO des XV-XX, 28, Rue de Charenton 75571 Paris Cedex 12 Paris, France; skowronek@free.fr

doi: 10.1136/bjo.2003.039925

Accepted for publication 15 December 2003

References

- 1 Suzuki JI, Takeda M, Sekine N, *et al*. Bilateral metastatic sclerochoroidal calcification in a patient with hyperparathyroidism. *Ophthalmologica* 1992;**205**:10-14.
- 2 Bourcier T, Blain P, Massin P, *et al*. Sclerochoroidal calcification associated with Gitelman syndrome. *Am J Ophthalmol* 1999;**128**:767-8.
- 3 Vezzoli G, Soldati L, Jansen A, *et al*. Choroidal calcifications in patients with Gitelman's syndrome. *Am J Kidney Dis* 2000;**6**:855.
- 4 Lim JI, Goldberg MF. Idiopathic sclerochoroidal calcification. *Arch Ophthalmol* 1989;**107**:1122-3.
- 5 Shields JA. Sclerochoroidal calcification in calcium pyrophosphate dihydrate deposition disease (pseudogout). *Arch Ophthalmol* 1997;**115**:1077-9.
- 6 Schachat AP, Robertson DM, Mieler WF, *et al*. Sclerochoroidal calcification. *Arch Ophthalmol* 1992;**110**:196-9.
- 7 Cohen SY, Guyot-Sionnest M, Puech M. Choroidal neovascularization as a late complication of hyperparathyroidism. *Am J Ophthalmol* 1998;**126**:320-2.

Whole body PET/CT imaging for detection of metastatic choroidal melanoma

Metastatic choroidal melanoma typically presents in the liver. Therefore, liver enzyme assays are the most common haematological evaluation performed after treatment.¹

In 1985, The Collaborative Ocular Melanoma Study required periodic medical evaluations including a physical examination, liver functions studies, a complete blood count, and a chest x ray. If liver enzymes exceeded 1.5 times normal, computed tomography (CT) of the abdomen was required. If low attenuation hepatic nodules suggested metastatic disease, fine needle aspiration biopsy of the liver tumours provided cytopathological confirmation.¹

Positron emission tomography (PET) is a molecular imaging technique that uses radiolabelled molecules to image metabolic activity in vivo.^{2,3} When whole body PET was combined with computed radiographic tomography (CT), PET/CT put anatomy and function on the same page making practical a new era of physiological imaging.²⁻⁶

This study examines the ability of positron emission tomography combined with computed tomography (PET/CT) to allow for detection of previously occult metastatic melanoma.

Case report

A 77 year old woman presented with a 15.4×15 mm width and 13.2 mm high collar button shaped choroidal melanoma with a large secondary retinal detachment in her right eye. Her preoperative medical evaluation

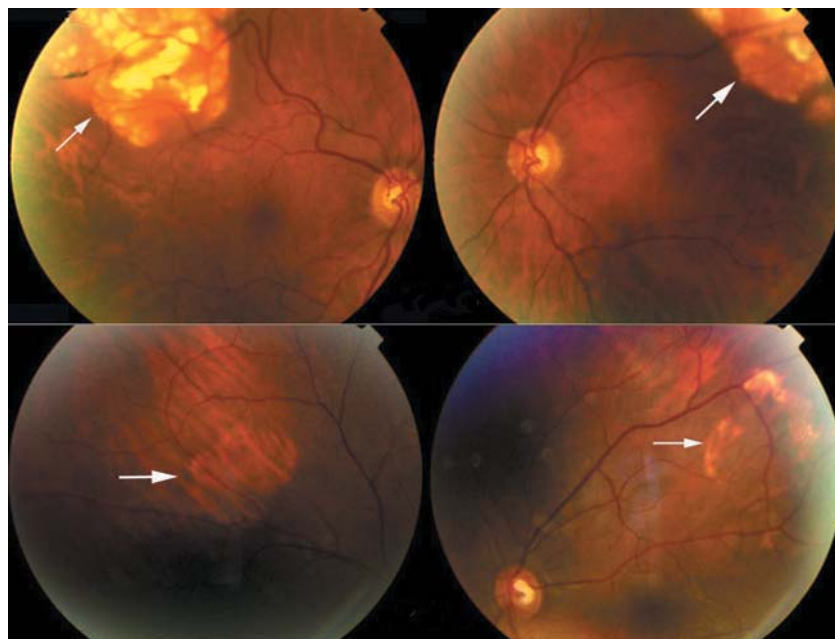


Figure 2 Funduscopy of the patient's brother (top) and son (bottom) revealing tumour-like and plaque-like calcifications.

Table 1 Patient characteristics

Physical	Examination	Blood examination	X ray	CT scan abdomen with contrast	Whole body PET/CT	
					CT	PET
General Subcutaneous tissue	Icterus 2 nodules in the anterior abdominal wall			No lesions noted	1.4 cm subcutaneous nodule in the anterior abdominal wall	Hypermetabolic focus in the subcutaneous tissue of the anterior abdominal wall
Nodes	None			No lesions noted	Enlarged para aortic lymph nodes on the left side	Hypermetabolic focus in the upper abdomen
Lungs	No abnormalities noted		Pleural effusion of right lung base. No nodules	Pleural effusion right lung base and calcified hilar nodes	Two small 3 mm nodules in the right upper lobe. Right pleural effusion	No foci noted
Liver	Enlarged	High bilirubin, AST, ALT, alkaline phosphatase, GGT		Enlarged. 2 areas of low attenuation in the anterior aspect of the right lobe	Low attenuation lesion >20 cm in greatest diameter in the right lobe with calcification seen posteriorly. Numerous low attenuation lesions throughout both lobes of the liver	Enlarged. Large hypermetabolic focus in the right lobe with mass effect. Numerous hypermetabolic foci throughout remainder of liver.
Kidney				8 mm cyst midpole and 2 cm cyst upper pole of left kidney	Large right renal cyst. Additional smaller cysts	Photopenic defect due to large right renal cyst
Bone				No lesions noted	No lesions noted	Hypermetabolic foci in the right skull base, left scapula, left humerus, sternum, multiple bilateral ribs, thoracic and lumbosacral spine, pelvis, and bilateral femurs

(including CT imaging of the abdomen) proved negative. She was treated by enucleation.

Two years later a follow up medical evaluation revealed elevated liver function studies (table 1) and a chest x ray showed a

pleural effusion. CT of the abdomen with contrast revealed multiple low attenuation hepatic foci consistent with metastatic melanoma.

A PET/CT was requested. Fifty minutes after intravenous administration of 15.2 mCi of fluorodeoxyglucose, whole body PET/CT imaging revealed enlarged para-aortic lymph nodes and a subcutaneous nodule in the abdominal wall (fig 1). The CT portion of the PET/CT also revealed two 3 mm nodules in the upper lobe of the right lung (too small to be visualised by PET imaging). PET imaging was able to reveal multiple bony metastasis that were not seen on the CT portion (fig 1). Both CT and PET showed a large liver metastasis, but CT was better at defining tumour size. Since it is a physiological assay, PET also demonstrated the metabolic activity of the metastatic tumours (fig 1).

Comment

In this case, whole body PET/CT was found to be capable of uncovering metastases not seen with abdominal CT alone. This led us away from considering regional perfusion of the liver, hepatic resection, and towards systemic treatment.^{7,8} Therefore, when PET/CT identifies extrahepatic involvement, it can have a significant impact on the management of patients with metastatic choroidal melanoma.

PET/CT could also be used for initial staging. Early detection of occult metastases

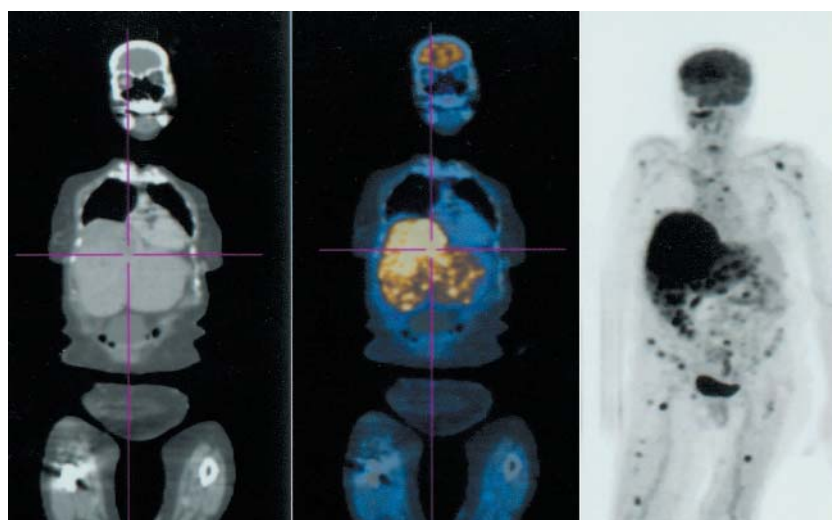


Figure 1 On the left, the CT demonstrates the anatomy; on the right the PET shows areas of hypermetabolism (glucose uptake); in the middle the two images are fused. PET/CT revealed enlarged para-aortic lymph nodes and a subcutaneous nodule in the anterior abdominal wall. The PET imaging portion of the PET/CT was able to reveal multiple bony metastases that were not seen on the CT portion of the examination. Both CT and PET showed a large liver metastasis.

offers the potential to avoid ineffective and expensive enucleations, radioactive plaques, proton irradiation, eye wall resections, or laser treatment.^{9,10} Local therapies would be abandoned in favour of systemic treatments.

Another issue related to PET/CT is cost. Up to five times more than CT of the abdomen, PET/CT is only covered (Medicare) for melanoma staging/restaging when the stage of the cancer remains in doubt after completion of conventional imaging (or if the clinical management would differ depending on the PET findings). Since PET/CT revealed extrahepatic foci in this case, it changed our clinical approach. There is little doubt about the improved ability of PET/CT to detect lesions; the real issue is cost and if the results will change outcomes.

This study goes one step further than CT, MRI, or PET alone. By combining whole body PET and CT, this examination joins anatomy and function in one examination (fig 1). The relative efficacy of PET/CT to locate metastases should be evaluated within the framework of a prospective study.

P T Finger, M Kurli

The New York Eye Cancer Center, New York, USA

P T Finger, M Kurli, P Wesley, L Tena

The New York Eye and Ear Infirmary, New York, USA

P T Finger, L Tena

St Vincent's Comprehensive Cancer Center, New York, USA

P T Finger, K R Kerr

Beth Israel Medical Center

P T Finger, A Pavlick

New York University School of Medicine, New York, USA

Correspondence to: Paul T Finger, MD, The New York Eye Cancer Center, 115 East 61st Street, New York, NY 10021, USA; pfinger@eyecancer.com

doi: 10.1136/bjo.2003.039289

Accepted for publication 1 January 2004

This work was supported by The EyeCare Foundation and Research to Prevent Blindness, New York, USA.

References

- Diener-West M, Hawkins BS, Markowitz JA, *et al*. A review of mortality from choroidal melanoma. II A meta-analysis of 5-year mortality rates following enucleation, 1966 through 1988. *Arch Ophthalmol* 1992;**110**:245–50.
- Townsend DW, Cherry SR. Combined anatomy and function: the path to true image fusion. *Eur Radiol* 2001;**11**:1968–74.
- Mijnhout GS, Hoekstra OS, van Tulder MW, *et al*. Systematic review of the diagnostic accuracy of 18F-fluorodeoxyglucose positron emission tomography in melanoma patients. *Cancer* 2001;**91**:1530–42.
- Stas M, Stroobants S, Dupont P, *et al*. 18-FDG PET scan in the staging of recurrent melanoma: additional value and therapeutic impact. *Melanoma Res* 2002;**12**:479–90.
- Swetter SM, Carroll LA, Johnson DL, *et al*. Positron emission tomography is superior to computed tomography for metastatic detection in melanoma patients. *Ann Surg Oncol* 2002;**9**:646–53.
- Finger PT, Czechonska G, D'Arienzo P, *et al*. Positron emission tomography of choroidal melanoma. *Probl Med Nukl* 1996;**10**:235–9.
- Mavligit GM, Charnsangavej C, Carrasco CH, *et al*. Regression of ocular melanoma metastatic to the liver after hepatic arterial chemoembolization with cisplatin and polyvinyl sponge. *JAMA* 1988;**260**:974–6.
- Albert DM, Niffenegger AS, Willson JK. Treatment of metastatic uveal melanoma: review and recommendations. *Surv Ophthalmol* 1992;**36**:429–38.
- Moshfeghi DM, Moshfeghi AA, Finger PT. Enucleation. *Surv Ophthalmol* 2000;**44**:277–301.
- Finger PT. Radiation therapy for choroidal melanoma. *Surv Ophthalmol* 1997;**42**:215–32.

Trans-Tenon's retrobulbar triamcinolone infusion for small choroidal neovascularisation

Intravitreal and sub-Tenon's corticosteroids are being evaluated for the treatment of choroidal neovascularisation (CNV).^{1–3} We reported on the efficacy of triamcinolone acetonide administered as a trans-Tenon's retrobulbar infusion (triamcinolone infusion) in reducing inflammation in uveitic eyes.⁴ Here we evaluated the same treatment in eyes with small subfoveal CNV.

Case reports

Triamcinolone infusion was performed in 22 eyes of 22 patients with subfoveal CNV of greatest diameter less than or equal to 1 disc diameter (DD). The diagnoses were age related macular degeneration (AMD) in 14 eyes, idiopathic CNV in four eyes, polypoidal choroidal vasculopathy (PCV) in three eyes, and punctate inner choroidopathy (PIC) in one eye. One AMD eye had undergone ablative argon laser photocoagulation for CNV previously, but no other eyes had received previous treatment. The median post-triamcinolone infusion follow up was 7.5 months (range 4–27 months). Pretreatment fluorescein angiography (FA)

revealed predominantly classic CNV in 12 eyes and predominantly occult CNV in 10 eyes. Records were reviewed retrospectively and did not require institutional review board approval. Informed consent was obtained before each procedure.

The patient's eye was prepared with povidone-iodine and sterile drapes applied. After topical anaesthesia, conjunctiva and Tenon's capsule were incised in the infero-temporal quadrant. A 23 gauge curved blunt cannula approximately 2.1 cm in length (#HS-2764, Handaya Co, Ltd, Tokyo, Japan) was inserted to the hub into sub-Tenon's space and 20 mg (0.5 ml) triamcinolone acetonide (Bristol Pharmaceutical, KK, Tokyo, Japan) was infused. The wound was left unsutured and 0.5% levofloxacin was instilled topically three times a day for 1 week.

Onset of CNV fibrosis was observed in 14 eyes (64%) by 3 months post-triamcinolone infusion (fig 1). Rates of fibrosis were 50% (7/14 eyes) for AMD, 100% (4/4 eyes) for idiopathic CNV, 67% (2/3 eyes) for PCV, and 100% (1/1 eye) for PIC. Fibrosis did not correlate with CNV size or lesion composition. FA performed at 3 months showed decreased lesion leakage in 12 eyes (55%), no change in five eyes (23%), and increased leakage in five eyes (23%). Best corrected visual acuity (VA) at 3 months for all eyes improved by ≥ 0.2 logarithm of the minimum angle of resolution (logMAR) in four eyes (18%), remained unchanged in 13 eyes (59%), and worsened by ≥ 0.2 logMAR in five eyes (23%). The median decimal VA for all eyes was 0.30 before treatment (range 0.08–1.0) and 0.24 at 3 months after treatment (range 0.05–1.2). Of the 14 eyes with AMD, the VA at 3 months improved by ≥ 0.2 logMAR in one eye (7%), remained

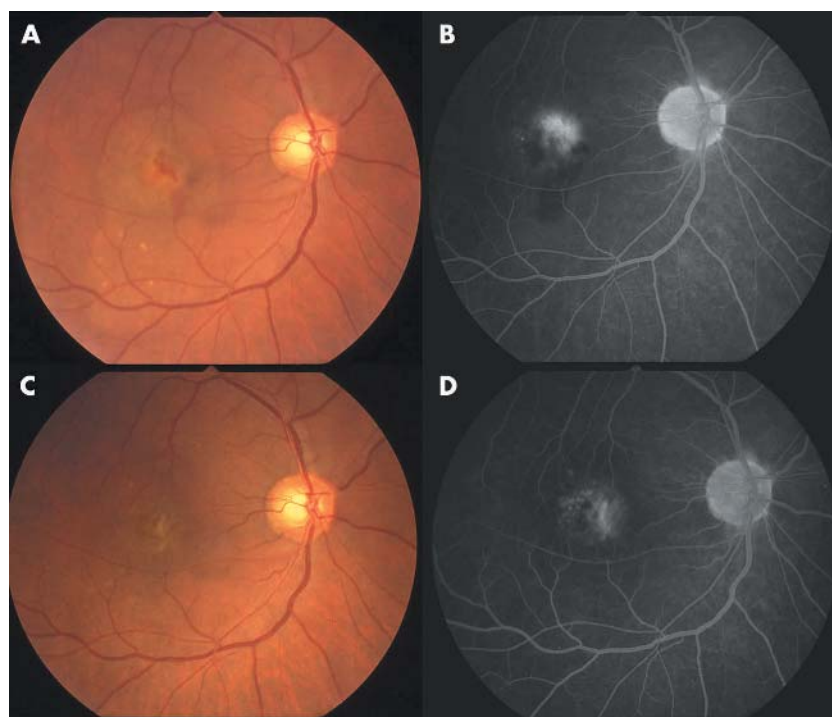


Figure 1 Colour fundus photographs and fluorescein angiography late images of an eye in a 65 year old patient with age related macular degeneration and small subfoveal choroidal neovascularisation before (A, B; best corrected visual acuity 0.3) and 3 months after triamcinolone infusion (C, D; best corrected visual acuity 0.7).

unchanged in 10 eyes (71%), and worsened by ≥ 0.2 logMAR in three eyes (21%). In these AMD eyes, the median decimal VA was 0.30 before treatment (range 0.08–1.0) and 0.20 at 3 months after treatment (range 0.05–0.7). Complications such as intraocular pressure elevation, infection, or cataract progression were not noted in any eyes.

Comment

This interventional case series shows that trans-Tenon's retrobulbar infusion of triamcinolone acetonide resulted in lesion fibrosis in the majority of eyes with small CNV, efficacy being best for idiopathic CNV or CNV related to PIC. The mechanism of action of triamcinolone acetonide in inhibiting CNV growth probably involves several pathways. The effect of corticosteroids in inhibiting inflammatory cells that participate in the neovascular response probably has a prominent role.^{5,6} Triamcinolone acetonide has specifically been shown to inhibit basic fibroblast growth factor induced migration and tube formation of choroidal microvascular endothelial cells.⁷ Furthermore, triamcinolone acetonide inhibits choroidal neovascularisation induced by laser trauma in a rat model.⁸ Finally, triamcinolone acetonide may decrease vascular permeability, thereby decreasing influx of serum proteins that may contribute to an angiogenic micro-environment.⁹ Longer follow up and greater numbers of cases in a randomised clinical trial are needed to confirm these results.

A A Okada, T Wakabayashi, E Kojima, Y Asano, T Hida

Kyorin Eye Center, Kyorin University School of Medicine, 6-20-2 Shinkawa, Mitaka, Tokyo, Japan

Correspondence to: A A Okada, MD, Department of Ophthalmology, Kyorin University School of Medicine, 6-20-2, Shinkawa, Mitaka, Tokyo 181-8611 Japan; aokada@po.ijnet.or.jp

doi: 10.1136/bjo.2003.039719

Accepted for publication 6 January 2004

References

- Challa JK, Gillies MC, Penfold PL, *et al*. Exudative macular degeneration and intravitreal triamcinolone: 18 month follow-up. *Aust NZ J Ophthalmol* 1998;**26**:277–81.
- Danis RP, Ciulla TA, Pratt LM, *et al*. Intravitreal triamcinolone acetonide in exudative age-related macular degeneration. *Retina* 2000;**20**:244–50.
- Gillies MC, Simpson JM, Luo W, *et al*. A randomized clinical trial of a single dose of intravitreal triamcinolone acetonide for neovascular age-related macular degeneration: one year results. *Arch Ophthalmol* 2003;**121**:667–73.
- Okada AA, Wakabayashi T, Morimura Y, *et al*. Trans-Tenon's retrobulbar triamcinolone infusion for the treatment of uveitis. *Br J Ophthalmol* 2003;**87**:968–71.
- Proia A, Hirakata A, McInnes J, *et al*. The effect of angiostatic steroids and B-cyclodextrin tetradecasulfate on corneal neovascularization in the rat. *Exp Eye Res* 1993;**57**:693–8.
- Oh H, Takagi H, Takagi C, *et al*. The potential angiogenic role of macrophages in the formation of choroidal neovascular membranes. *Invest Ophthalmol Vis Sci* 1999;**40**:1891–8.
- Wang Y, Friedrichs U, Eichler W, *et al*. Inhibitory effects of triamcinolone acetonide on bFGF-induced migration and tube formation in choroidal microvascular endothelial cells. *Graefes Arch Clin Exp Ophthalmol* 2002;**240**:42–8.
- Ciulla TA, Criswell MH, Danis RP, *et al*. Intravitreal triamcinolone acetonide inhibits

choroidal neovascularization in a laser-treated rat model. *Arch Ophthalmol* 2001;**119**:399–404.

- Carnuccio R, Di Rosa M, Guerrasio B, *et al*. Vasocortin: a novel glucocorticoid-induced anti-inflammatory protein. *Br J Pharmacol* 1987;**90**:443–5.

Retinoblastoma in a child conceived by in vitro fertilisation

As the number of infants born through in vitro fertilisation (IVF) grows, there is increased interest regarding the long term effects of IVF and other assisted reproduction techniques on such offspring. Recent reports have noted cancer in children born after IVF or fertility drug use (table 1).¹

In 2001, retinoblastoma was reported to occur in a child born through IVF in Israel.² Since then, an additional report documented four cases from the Netherlands.³ Here we add a sixth case and the first from the United States. Of these children four had unilateral retinoblastoma and two bilateral disease (table 2).

During 2002, a 16 month old child was referred to The New York Eye Cancer Center with no known family history of eye disease. She had a blind painful right eye with neovascular glaucoma. Intraocular pressures were 35 mm Hg in the right eye, and 14 in the left. Examination of the anterior chamber of the right eye revealed cells on the corneal endothelium and iris neovascularisation. While ophthalmoscopic examination of the right eye was not possible because of opaque media, ultrasonography revealed a densely calcified mass in the posterior pole (fig 1). Computed radiographic tomography demonstrated tumour calcification with no evidence of extrascleral or optic nerve extension.⁴ Post-nucleation histopathology confirmed the diagnosis of retinoblastoma.⁵ The parents did not approve genetic studies of the child.

Further history revealed that this child was born through IVF with a donor egg and the father's sperm. In order to carry the child, the postmenopausal mother received oestrogen and progesterone before and during gestation.

Comment

Several theories of IVF related carcinogenesis exist. Prenatal exposure to fertility drugs may initiate cancer in the embryo or parental germ cells. However, an evidence based association between IVF treatments and

Table 1 Anomalies and cancers reported in offspring of IVF

Condition	Reference
Neuroectodermal tumours	White <i>et al</i> ¹ Kobayashi <i>et al</i> ¹
Neuroblastoma (Note: associated with the use of fertility drugs only.)	Kramer <i>et al</i> ² Michalek <i>et al</i> ³
Retinoblastoma	Moll <i>et al</i> ⁴ Cruysberg <i>et al</i> ⁴ Anteby <i>et al</i> ⁵
Hepatoblastoma	Melamed <i>et al</i> ⁵ Toren <i>et al</i> ⁶
Clear cell kidney sarcoma	Toren <i>et al</i> ⁶
Lymphoma	Kobayashi <i>et al</i> ¹
Transposition of the great arteries	Lancaster ⁷ Berg <i>et al</i> ⁸
Neural tube defects	Lancaster ⁷

Several types of congenital anomalies and cancers have been reported in the literature, primarily in the form of case reports. The relation between IVF and these conditions is not definitively established.

cancer development (in the women taking the drugs) has not been established.⁶

Another possible mechanism has been associated with the culture medium used in the IVF test tube. Experiments on mice suggest that subtle changes in the ingredients of the culture media may alter the activity of imprinted genes.⁷ Like fertility drugs, it remains to be seen whether altered gene imprinting can lead to cancers such as retinoblastoma.

A third possible mechanism of carcinogenesis includes inheritance of genetic defects from gametes and embryo trauma performed during routine intracytoplasmic sperm injection (ICSI) type IVF.

The most likely explanation for an increased risk of secondary carcinogenesis is that the population of patients seeking IVF is dissimilar to the general population. Patients seeking IVF are older or have medical problems that interfere with fertility. This poses a problem with any study other than a randomised prospective trial that compares babies from untreated infertility patients who become pregnant versus babies from infertile patients who become pregnant using IVF. To date all studies published are observations of clusters of disease with the suggestion that there is a cause and effect relation.⁸

Table 2 Retinoblastoma in children born through IVF

Reference	Sex and age at diagnosis (months)	Eye	Cause of subfertility	DNA 13q14 analysis	Assisted reproductive technique
Anteby <i>et al</i> ⁵	NR, 30	Unilateral	NR	NR	IVF with donor sperm
Moll <i>et al</i> ⁴	F, 38	Both	Unexplained	Exon 8 mutated	IVF with 6 courses of clomid
Moll <i>et al</i> ⁴	M, 15	Left	Maternal cause	Normal	IVF
Moll <i>et al</i> ⁴	F, 34	Right	Unexplained	Normal	IVF
Moll <i>et al</i> ⁴	M, 8.5	Both	Unexplained	Intron 3 mutated	IVF with 8 AI attempts
Moll <i>et al</i> ⁴	F, 32	Left	Paternal cause	Normal	IVF with ICSI
This report	F, 16	Right	Maternal cause	NR	IVF

NR, not reported; AI, artificial insemination; ICSI, intracytoplasmic sperm injection.

Current literature on retinoblastoma in children born through IVF includes three case reports that describe a total of six cases of retinoblastoma in these children. The characteristics of these patients and the patient discussed in this report are listed below.

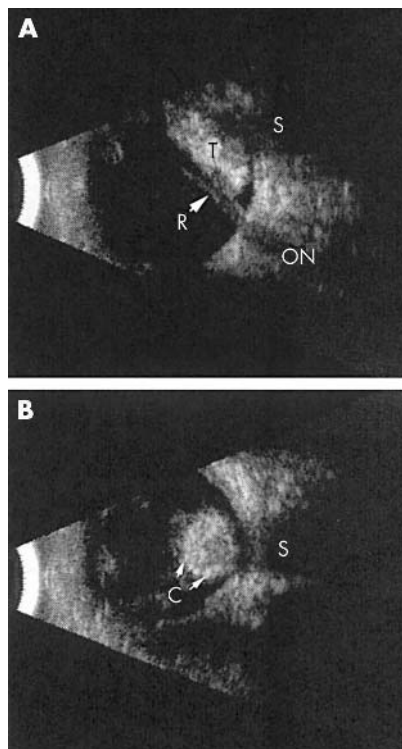


Figure 1 B-scan ultrasonography. (A) A longitudinal view of the right eye demonstrates a tumour posterior to a closed funnel retinal detachment. (B) A transverse view of the eye demonstrates a rounded, densely calcified tumour. R, retina; S, shadow in orbit; C, calcification; T, tumour; ON, optic nerve.

Retinoblastoma is the most common intraocular cancer of childhood and affects approximately 300 children each year in the United States. Retinoblastoma is a manifestation of a de novo deletion or mutation of the q14 band of chromosome 13, occurring as a "second hit" during embryogenesis or the result of two hit deletions in retinal cells. In that it could be the result of chromosomal breakage and deletions in IVF born children, surveillance of retinoblastoma incidence in children born through IVF is warranted.⁷⁻⁹

With the advent of assisted reproductive technology (ART) in 1977, American couples have increasingly turned to such treatments to overcome fertility problems. Nationwide, 99 629 procedures were performed in 2000 by ART. In that year, fertility treatments in which the egg and sperm are handled in the laboratory resulted in 25 228 live births and 35 025 infants. This report expands information on geography and determinants of both ART success and multiple birth risks (beyond that which appears in the 2000 Assisted Reproductive Technology Success Rates¹⁹). Therefore, it seems reasonable to maintain a registry of post-IVF children, to support large epidemiological studies with long term follow up, and prospective randomised studies of infertile couples in order to determine if there is a relation between IVF and cancers such as retinoblastoma.

I Lee, P T Finger

The New York Eye Cancer Center, New York City, NY, USA

I Lee, P T Finger, J A Grifo, A R Rausen,

A Rebarber

New York University School of Medicine, New York City, NY, USA

D H Barad

Albert Einstein College of Medicine, New York City, New York, USA

Correspondence to: P T Finger, The New York Eye Cancer Center, 115 East 61st Street, New York City, NY 10021, USA; pfinger@eyecancer.com

doi: 10.1136/bjo.2003.041160

Accepted for publication 8 January 2004

Supported by The EyeCare Foundation, Inc and Research to Prevent Blindness, New York City, USA.

The authors have no proprietary interest in any material mentioned in this study.

References

- 1 Klip H, Burger CW, deKraker J, *et al*. Risk of cancer in the offspring of women who underwent ovarian stimulation for IVF. *Hum Reprod* 2001;**16**:2451-8.
- 2 Anteby I, Cohen E, Anteby E, *et al*. Ocular manifestations in children born after in vitro fertilization. *Arch Ophthalmol* 2001;**119**:1525-9.
- 3 Moll AC, Imhof SM, Cruysberg JR, *et al*. Incidence of retinoblastoma in children born after in-vitro fertilisation. *Lancet* 2003;**361**:309-10.
- 4 Finger PT, Harbour JW, Karcioglu Z. Risk factors for metastasis in retinoblastoma. *Surv Ophthalmol* 2002;**47**:1-16.
- 5 Moshfeghi DM, Moshfeghi AA, Finger PT. Enucleation. *Surv Ophthalmol* 2000;**44**:277-301.
- 6 Lerner-Geva L, Geva E, Lessing JB, *et al*. The possible association between in vitro fertilization treatments and cancer development. *Int J Gynecol Cancer* 2003;**13**:23-7.
- 7 Doherty AS, Mann MR, Tremblay KD, *et al*. Differential effects of culture on imprinted H19 expression in the preimplantation mouse embryo. *Biol Reprod* 2000;**62**:1526-35.
- 8 Bruinsma F, Venn A, Lancaster P, *et al*. Incidence of cancer in children born after in-vitro fertilization. *Human Reprod* 2000;**15**:604-7.
- 9 Lerner-Geva L, Toren A, Chetrit A, *et al*. The risk for cancer among children of women who underwent in vitro fertilization. *Cancer* 2000;**88**:2845-7.
- 10 White L, Giri N, Vowels MR, *et al*. Neuroectodermal tumours in children born after assisted conception. *Lancet* 1990;**336**:1577.
- 11 Kobayashi N, Matsui I, Tanimura M, *et al*. Childhood neuroectodermal tumours and malignant lymphoma after maternal ovulation induction. *Lancet* 1991;**338**:955.
- 12 Kramer S, Ward E, Meadows AT, *et al*. Medical and drug risk factors associated with neuroblastoma: a case-control study. *J Natl Cancer Inst* 1987;**78**:797-804.
- 13 Michalek AM, Buck GM, Nasca PC, *et al*. Gravid health status, medication use, and risk of neuroblastoma. *Am J Epidemiol* 1996;**143**:996-1001.
- 14 Cruysberg JR, Moll AC, Imhof SM. Bilateral sporadic retinoblastoma in a child born after in vitro fertilization. *Arch Ophthalmol* 2002;**120**:1773, author reply 1773-4.
- 15 Melamed O, Bujanover Y, Hammer J, *et al*. Hepatoblastoma in an infant born to a mother after hormonal treatment for sterility. *N Engl J Med* 1982;**307**:820.
- 16 Toren A, Sharon N, Mandel M, *et al*. Two embryonal cancers after in vitro fertilization. *Cancer* 1995;**76**:2372-4.
- 17 Lancaster PA. Congenital malformations after in vitro fertilization. *Lancet* 1987;**2**:1392-3.
- 18 Berg T, Ericson A, Hillensjo T, *et al*. Deliveries and children born after in-vitro fertilization in Sweden 1982-95: a retrospective cohort study. *Lancet* 1999;**354**:1579-85.

19 National Summary and Fertility Clinic Report. Assisted reproductive technology success rates. *MMWR* 2000;**52**:No SS-9.

Angle closure glaucoma after laser photocoagulation for retinopathy of prematurity

Infantile angle closure glaucoma (ACG) is a rare consequence of retinopathy of prematurity (ROP) and usually occurs a few years after laser treatment for ROP.¹⁻³ A Medline search for ACG following laser photocoagulation extracted only one case. In the case, ACG occurred in 2 weeks after laser photocoagulation and although occurrence of iris bombe in both eyes was described, the mechanism for the ACG was not fully clarified.⁴

We present a case of bilateral ACG that occurred within a several weeks after the laser photocoagulation for ROP. We shall discuss the importance of ultrasound biomicroscopy (UBM) in the diagnosis.

Case report

A baby girl, born at 25 weeks gestation weighing 796 g, was diagnosed with stage 2 plus, zone 2 ROP bilaterally at 33 weeks. Diode laser photocoagulation, 986 applications right eye and 629 left eye, with 200-240 mW, 0.4 second duration, was performed by a paediatric ophthalmologist. On the following day, severe hyphaema was observed bilaterally but there was no evidence of choroidal detachment by B-mode ultrasound sonography. Topical atropine and corticosteroid were started and she was

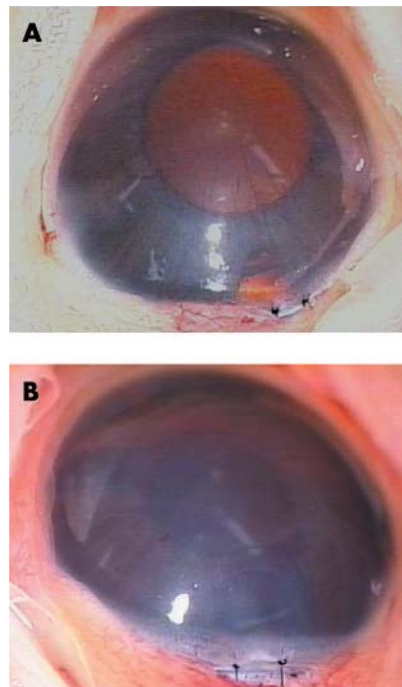


Figure 1 Photographs of the anterior segment of left eye (A) and right eye (B) obtained with an operative microscope after peripheral iridectomy. The photographs show shallow anterior chambers and persistent pupillary membranes and iridohyaloid vessels (A), and corneal opacity (B).

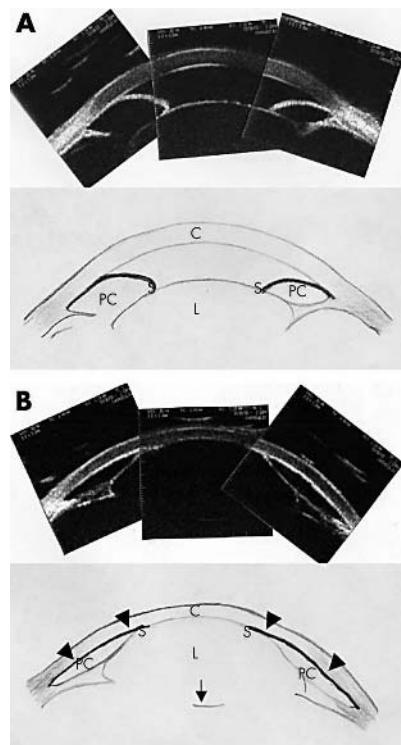


Figure 2 Composite images of the anterior segment scanned with UBM (top) and schematic representations (bottom). (A) Left eye. Posterior synechia and iris bombe can be seen. C, cornea; L, lens; AC, anterior chamber; S, posterior synechia; PC, posterior chamber. (B) Right eye. The high echo lines (arrowheads) along the corneal endothelium represent the iris adherent to the corneal endothelium and the iris bombe. The lens is displaced into the anterior chamber and the anterior chamber is completely obliterated. The arrow represents the posterior capsule of the lens. Note that the cornea is distended and is thin as a result of the high intraocular pressure. The thickness of the cornea at the centre is 394 μm , and 613 μm in the left eye as measured with a caliper installed in the UBM model 840 Humphrey.

followed up conservatively. During the follow up period, total posterior synechia was formed in the both eyes and the anterior chamber became shallow.

At 39 weeks, the corneal diameter had increased, and the anterior chamber was extremely shallow bilaterally. The intraocular pressure (IOP) in the right eye was elevated to 28 mm Hg, and she was referred to our hospital.

Our examination showed that the corneal diameter was increased to 11 mm bilaterally. Slit lamp examination showed corneal oedema and shallow anterior chamber depth bilaterally, especially in the right eye. The corneal oedema made the funduscopy difficult bilaterally. The IOP under the general anaesthesia was 33 mm Hg right eye and 17 mm Hg left eye. Persistent pupillary membranes and iridohyaloid vessels were observed but rubeosis iridis was not observed (fig 1).

UBM images of anterior segments demonstrated iris bombe bilaterally, and the entire right iris surface was adherent to the corneal endothelium. As a result, the anterior capsule

of the lens was also attached to the corneal endothelium (fig 2). Choroidal detachment and a retrolental mass were not observed by B-mode ultrasound sonography (fig 2).

Peripheral iridectomy was performed bilaterally (fig 1). Postoperatively, her peripheral anterior chamber deepened bilaterally although the lens in the right eye was still adherent to the corneal endothelium. Indirect ophthalmoscopy revealed normal cup to disc ratio. The IOP fell to normal levels bilaterally.

Comment

Shallow anterior chambers in ROP patients are known to be caused by various factors—for example, choroidal detachment after excessive photocoagulation, development of retrolental mass, or relative increment in lens thickness,³ but usually the cause of shallow anterior chamber cannot be determined. In our case, the development of hyphaema after photocoagulation induced posterior synechia, and the iris bombe followed. The displacement of the anterior chamber structures was induced by the forward movement of the iris-lens diaphragm in the right eye, and the ocular fragility in premature baby may explain this deformity.

Vitreous haemorrhage is known to occur in 7.9% of ROP cases after photocoagulation.⁶ In our case, there is a possibility that the hyphaema was derived from vitreous haemorrhage. Another possibility is an accidental photocoagulation of persistent pupillary membranes and/or iridocorneal vessels caused the hyphaema. We are not aware of such morphological changes after photocoagulation for ROP.

ACG that occurs immediately after retinal photocoagulation in ROP patients is rare, but is still an important complication. In ROP patients, the lens and its ligament are weak, and therefore not only ACG but also lens displacement occurred. It is important that we be aware of the possible development of ACG following retinal photocoagulation for ROP.

A Uehara, T Kurokawa, N Gotoh, N Yoshimura

Department of Ophthalmology, Shinshu University School of Medicine, Matsumoto, Japan

T Tokushima

Department of Ophthalmology, Nagano Children's Hospital, Nagano, Japan

Correspondence to: N Yoshimura, MD, PhD, Department of Ophthalmology and Visual Sciences Kyoto University Graduate School of Medicine, Kyoto 606-8507, Japan; nagaeye@kuhp.kyoto-u.ac.jp

doi: 10.1136/bjo.2003.037994

Accepted for publication 22 January 2004

References

- 1 **Bloidi FC.** Retrolental fibroplasias (retinopathy of prematurity). *Trans Am Acad Ophthalmol Otolaryngol* 1955;**59**:35–8.
- 2 **McCormic AQ, Pratt-Johnson JA.** Angle closure glaucoma in infancy. *Ophthalmic Surg* 1971;**2**:91–3.
- 3 **Smith J, Shivitz I.** Angle-closure glaucoma in adult with cicatricial retinopathy of prematurity. *Arch Ophthalmol* 1984;**102**:371–2.
- 4 **Lee AL, Lee LR, Gole GA.** Angle-closure glaucoma after laser treatment for retinopathy of prematurity. *J AAPOS* 1998;**2**:383–4.
- 5 **Hibino Y, Takahashi M, Majima A.** Studies on ocular functions of cicatricial retinopathy of

prematurity. *Managements of refractive elements. Jpn J Clin Ophthalmol* 1978;**32**:655–62.

- 6 **Fallaha N, Lynn MJ, Aaberg TM Jr, et al.** Clinical outcome of confluent laser photocoagulation for retinopathy of prematurity. *J AAPOS* 2002;**6**:81–5.

Sequential treatment of central retinal vein occlusion with intravitreal tissue plasminogen activator and intravitreal triamcinolone

Treatment for central retinal vein occlusion (CRVO) remains disappointing despite recently proposed intraocular surgical techniques.^{1–2} We previously introduced the use of intravitreal tissue plasminogen activator (TPA) for acute central retinal vein occlusion in 1999.³ Numerous investigators have confirmed its safety and suggested that it may have a beneficial role in the treatment of acute central retinal vein occlusion.^{4–7} Although some studies in rabbits suggest the rabbit retina is not permeable to TPA,

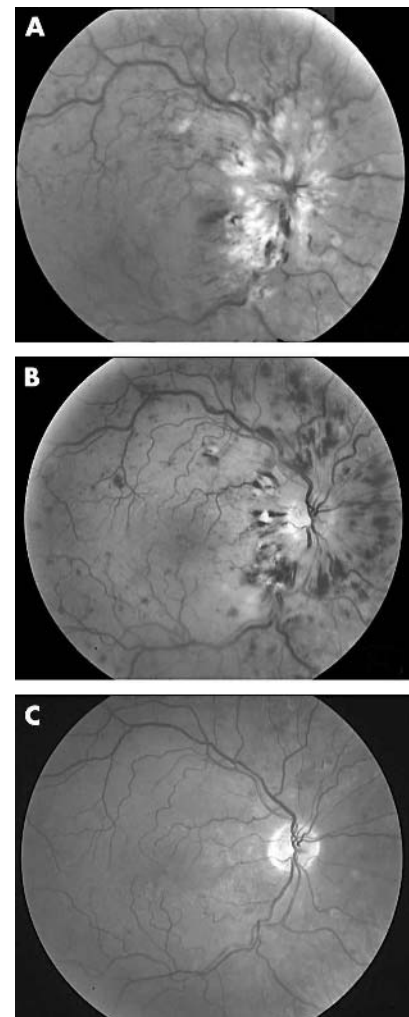


Figure 1 (A) Fundus photograph shows an acute CRVO with dilated retinal veins, retinal haemorrhages, and retinal oedema. (B) Fundus appearance 1 month after intravitreal injection of tissue plasminogen activator. (C) Photograph of the same eye 5 months later.

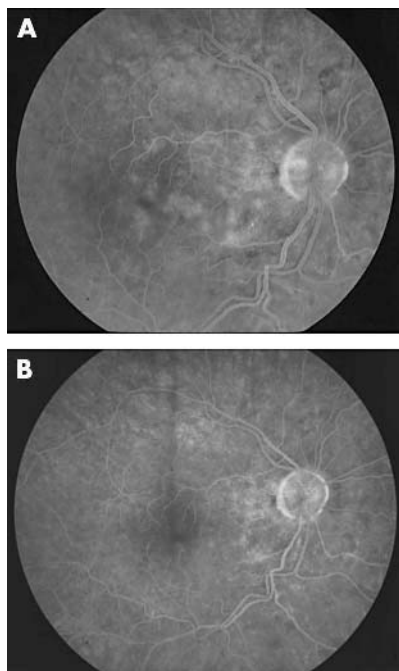


Figure 2 (A) Fluorescein angiogram reveals persistent macular oedema and hyperfluorescence 6 months after intravitreal TPA injection. (B) Late frames show resolution of macular oedema 6 weeks after intravitreal triamcinolone.

investigators found the porcine retina was, in fact, permeable to TPA.^{8,9} Our clinical experience with intravitreal TPA in humans with CRVO and large submacular haemorrhages strongly suggests that intravitreal TPA does cross the human retina. Greenberg *et al* were the first to report the possible beneficial effect of intravitreal steroids on patients with chronic CRVO.¹⁰ This report describes a sequential treatment strategy for patients with CRVO who present early in the course of their disease and can be performed in the office while avoiding the risks of vitrectomy. It utilises intravitreal TPA in the acute phase of the vein occlusion to attempt clot lysis, and then treats any remaining vascular leakage with intravitreal triamcinolone.

Case report

A 59 year old obese, hypertensive flight instructor presented with a sudden decrease in vision for 7 days in the right eye. Vision was 20/400 right eye and 20/20 left eye. The patient was diagnosed with an acute CRVO in the right eye (fig 1A). The left eye was normal. After being advised of the risks and benefits, the patient elected to undergo intravitreal injection of TPA (75 µg). Thirteen days later, the patient noted marked improvement in vision with 20/60 vision. Thirty four days after the injection, the patient's vision was 20/30 (Fig 1B).

Six months after intravitreal TPA injection, the vision remained 20/30, but the patient still complained of metamorphopsia and blurry vision despite resolution of other findings of CRVO (fig 1C). Fluorescein angiogram (FA) revealed persistent macular oedema (fig 2A). Optical coherence tomography (OCT) showed the foveal thickness to be 331 µm with mild intraretinal oedema. After

being advised of the risks and the benefits, the patient then underwent injection of intravitreal triamcinolone (4 mg).

Six weeks after the intravitreal triamcinolone, the FA returned to normal and OCT showed decreased foveal thickness from 331 µm to 291 µm. The patient reported a significant improvement in vision with decreased metamorphopsia. Vision was 20/25 with no late leakage on the fluorescein angiogram (fig 2B).

Comment

To our knowledge, this represents the first published case of CRVO treated sequentially with intravitreal TPA for the acute phase and intravitreal triamcinolone for the chronic phase. TPA is a drug that must be used early in the course of thrombus formation to be effective. We do not recommend its use for patients with chronic symptoms. Intravitreal steroids appear to decrease the blood-retinal barrier breakdown and macular oedema, but recurrent oedema may occur since the steroids do not appear to affect the thrombus itself.

J M L, J J K, M C Cheung

Ophthalmology, University of California at San Francisco, San Francisco, CA, USA

J M Lahey, J J K

Ophthalmology, Kaiser Permanente, Hayward, CA, USA

Correspondence to: J M Lahey, MD, Ophthalmology (Retina), Kaiser Permanente Medical Center, 27400 Hesperian Boulevard, Hayward, CA 94545-4299, USA; Mike.Lahey@kp.org

doi: 10.1136/bjo.2004.043406

Accepted for publication 3 February 2004

References

- 1 **Opremacak EM**, Bruce RA, Lomeo MD, *et al*. Radial optic neurotomy for central retinal vein occlusion: a retrospective pilot study of 11 consecutive cases. *Retina* 2001;**21**:408–15.
- 2 **Weiss JN**, Byone LA. Injection of tissue plasminogen activator into a branch retinal vein in eyes with central retinal vein occlusion. *Ophthalmology* 2001;**108**:2249–57.
- 3 **Lahey JM**, Fong DS, Kearney J. Intravitreal tissue plasminogen activator for acute central retinal vein occlusion. *Ophthalmic Surg Lasers* 1999;**30**:427–34.
- 4 **Weizer JS**, Fekrat S. Intravitreal tissue plasminogen activator for the treatment of central retinal vein occlusion. *Ophthalmic Surg Lasers Imaging* 2003;**34**:350–2.
- 5 **Glacet-Bernard A**, Kuhn D, Vine AK, *et al*. Treatment of recent onset central retinal vein occlusion with intravitreal tissue plasminogen activator: a pilot study. *Br J Ophthalmol* 2000;**84**:609–13.
- 6 **Ghazi NG**, Noureddine B, Haddad RS, *et al*. Intravitreal tissue plasminogen activator in the management of central retinal vein occlusion. *Retina* 2003;**23**:780–4.
- 7 **Elman MJ**, Raden RZ, Carrigan A. Intravitreal injection of tissue plasminogen activator for central retinal vein occlusion. *Trans Am Ophthalmol Soc.* 2001;**99**: 219–21; discussion 222–3.
- 8 **Kamei M**, Misono K, Lewis H. A study of the ability of tissue plasminogen activator to diffuse into the subretinal space after intravitreal injection in rabbits. *Am J Ophthalmol* 1999;**128**:739–46.
- 9 **Mahmoud TH**, Peng Y-W, Proia A, *et al*. Intravitreal tissue plasminogen activator penetrates the retinal veins in a porcine model of vascular occlusion. *Invest Ophthalmol Vis Sci.* 2002;**43**: E-abstract 3533, Presented at ARVO, 2002.

2002;**43**: E-abstract 3533, Presented at ARVO, 2002.

10 **Greenberg PB**, Martidis A, Rogers AH, *et al*. Intravitreal triamcinolone acetate for macular oedema due to central retinal vein occlusion. *Br J Ophthalmol* 2002;**86**:247–8.

Severe post-laser suprachoroidal haemorrhaging in a diabetic patient receiving anticoagulants

Although the aetiology is not well understood, expulsive suprachoroidal haemorrhaging (ESH) is the most severe complication associated with intraocular surgery. Anticoagulants are considered a risk factor for spontaneous suprachoroidal haemorrhaging in cases with high myopia, age related macular degeneration, and diabetic retinopathy.^{1–5} However, ESH post photocoagulation is extremely rare regardless of anticoagulant therapy. We have experienced a severe case of post-laser ESH correlated with anticoagulant therapy, which resulted in irreversible visual disturbance.

Case report

A 70 year old woman was diagnosed with pre-proliferative diabetic retinopathy based on fluorescein angiographic examinations. Two months before diagnosis, she had right eye cataract surgery. During the past 6 years, the patient received warfarin (4 mg/day) and aspirin (81 mg/day) because of atrial fibrillation after myocardial infarction. Laser photocoagulation was performed in her right eye with a Nidek MC-7000, yellow-green laser. Operating conditions were 200–280 burns per session with a spot size 200 µm, exposure 0.2 seconds, power 100–120 mW using a QuadraSpheric contact lens (Volk, Tokyo, Japan). Treatment was separated into three partitions with a minimum 2 week interval between sessions. Three days after final photocoagulation, the patient had a sudden visual loss to hand movements. In slit lamp examinations, the retina seemed to be attached to the posterior surface of the implanted intraocular lens. Severe choroidal detachment was found by fundus examination (fig 1). The B-mode ultrasonography showed massive haemorrhaging in the choroidal space (fig 2). In systemic examinations, multiple purple spots were observed in both her arms. Microhaematuria was also found. Blood examination revealed blood sugar 167 mg/dl; platelet number 179 000 ×10⁹/l; PT% 19% (control 70–120); PTTs 28.7 seconds; PT INR 4.72 (control 1); APTT 80.2 seconds (control 24.0–38.0); and bleeding time 5 minutes. Although surgery was planned to proceed as soon as the anticoagulant was washed out, her right eye lost all light perception before treatment.

Comment

We have described a case of ESH after laser photocoagulation in a patient receiving anticoagulant therapy. Laser photocoagulation is known as an effective treatment for various ocular diseases and is a widely used, non-incision surgical procedure. However, a number of complications have been reported, with some citing an irreversible visual disturbance.⁶ On the other hand, anticoagulant therapy is prevalent after cardiac/brain infarctions, which necessitate long term coagulation system management. In the present case, the PT INR was extremely prolonged (a respected value of 2–3 is

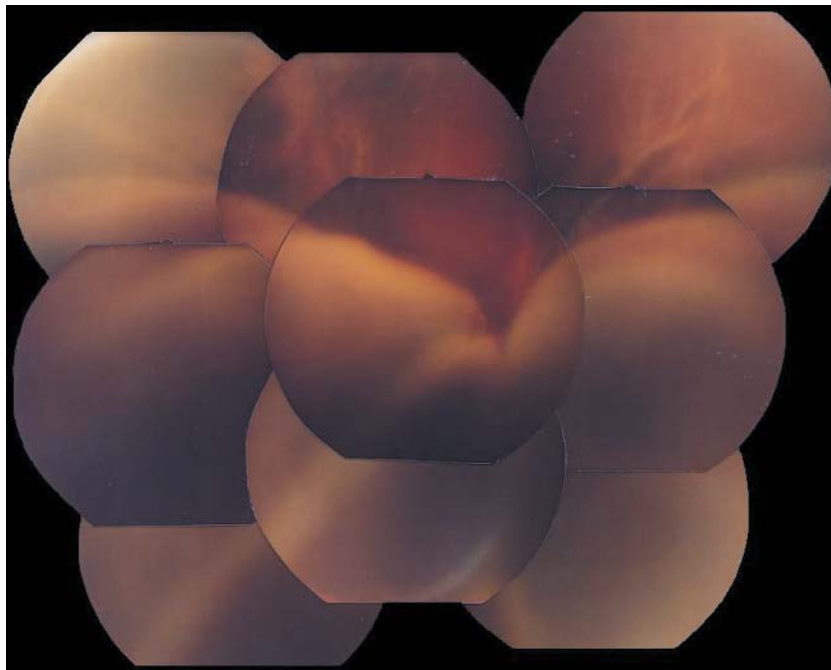


Figure 1 A fundus photograph of the patient after laser photocoagulation. A severe choroidal detachment associated with secondary retinal detachment was found.

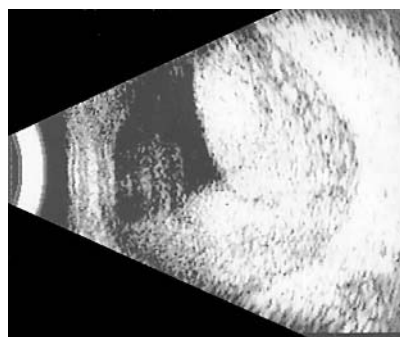


Figure 2 The findings of B-mode ultrasound examination. A massive haemorrhage in the choroids is present.

appropriate for post-cardiac infarction). Presumably, choroidal microbleeding initiated by photocoagulation persisted because of an overly suppressed coagulation system; blood pooled in the choroidal space, which assumed an ESH. To our knowledge there is only one other similar case reported by Khairallah *et al* that showed post-laser choroidal haematoma in a diabetic patient treated with anticoagulant.⁷ Even though ESH incidence is low, extreme caution must be exercised when performing laser therapy in patients using anticoagulants, because of potentially serious outcomes. An age of 65 years or more, history of stroke, history of gastrointestinal bleeding, a serious morbid condition (recent myocardial infarction, renal insufficiency, or severe anaemia), and atrial fibrillation are five high risk factors for major bleeding in outpatients treated with warfarin.⁸ If possible, preoperative coagulation system examinations are recommended for high risk patients receiving anticoagulant treatments.

**A Mikawa, S Honda, I Sugita, N Okamoto,
H Toda**

Department of Ophthalmology, Kitano Hospital,
Tazukekofukai Medical Research Institute, Osaka,
Japan

Correspondence to: A Mikawa, Department of
Ophthalmology, Kitano Hospital, Tazukekofukai
Medical Research Institute, 2-4-20 Ougimachi,
Kita-ku, Osaka 530-8480, Japan;
a-matsuo@kitano-hp.or.jp

doi: 10.1136/bjo.2004.043489

Accepted for publication 14 February 2004

References

- 1 **Chak M**, Williamson TH. Spontaneous suprachoroidal haemorrhage associated with high myopia and aspirin. *Eye* 2003;17:525-7.
- 2 **Fadi EB**, William H, Jarrett H, *et al*. Massive hemorrhage complicating age-related macular degeneration. *Ophthalmology* 1986;93:1581-92.
- 3 **Edwards P**. Massive choroidal hemorrhage in age-related macular degeneration: a complication of anticoagulant therapy. *J Am Optom Assoc* 1996;67:223-6.
- 4 **Yang SS**, Arthur D, McDonald R. Massive spontaneous choroidal hemorrhage. *Retina* 2003;23:139-44.
- 5 **Raj A**, Sekhri R, Salam A, *et al*. Massive subretinal bleed in a patient with background diabetic retinopathy and on treatment with warfarin. *Eye* 2003;17:649-652.
- 6 **Zweng HC**, Little HL, Hammond AH. Complications of argon laser photocoagulation. *Trans Am Acad Ophthalmol Otolaryngol* 1974;78:OP195-204.
- 7 **Khairallah M**, Chachia N. Post-laser choroidal hematoma in a diabetic patient treated with an oral anticoagulant. *J Fr Ophthalmol* 1994;17:138-140.
- 8 **Landefeld CS**, Goldman L. Major bleeding in outpatients treated with warfarin: incidence and prediction by factors known at the start of outpatient therapy. *Am J Med* 1989;87:144-52.

MAILBOX

Authors' reply

We appreciate the interest and many comments we have received regarding our recent article.¹ In reply to the comments by Dr Vedantham, we acknowledge the paucity of experimental data to prove that accurate placement of corticosteroids into the sub-Tenon's space provides good drug penetration into the eye. However, the studies to the contrary cited by Vedantham have all used needles to make such "accurate placement," including the study by Jennings *et al*,² which utilised the technique described by Tessler.³ Use of needles represents not only a potential hazard to the eye in terms of accidental globe penetration, but also makes it much more difficult to place any sub-Tenon's injection under the posterior Tenon's capsule near the macula and/or around the optic nerve. It has been shown that many injections intended for the sub-Tenon's space merely end up somewhere in the orbit outside of Tenon's capsule.⁴ We believe that our method using a 23 gauge blunt, curved, long cannula (the one we used was No HS-2764 by Handaya Co, Ltd, Tokyo, Japan) assures accurate placement into the target space, thereby increasing therapeutic efficacy and obviating the need for globe invasive procedures such as intravitreal injection of corticosteroids, corticosteroid intravitreal implants, and/or therapeutic vitrectomy.

However, we are in agreement with Vedantham, in that ultimately corticosteroid placed outside of the eye may be no match for the efficacy that may be obtained by corticosteroid placed inside the eye. Yet we have found such a high efficacy rate for the trans-Tenon's retrobulbar infusion of triamcinolone in uveitis that we can conceive of no reason why this treatment should not be tried *before* procedures such as intravitreal injections that carry risks of severe complications are considered. For example, as also pointed out by Vedantham, the risks of intravitreal corticosteroid injections even include development of a rare form of mycobacterial endophthalmitis.⁵ Therefore, the risk to the eye of intravitreal procedures, especially when involving corticosteroid administration, cannot be taken lightly. Furthermore, we believe that the reason why sub-Tenon's injections of corticosteroids have not become popular among retina specialists who for example treat diabetic macular oedema, is more likely related to the lower efficacy rate when using needles as opposed to the technique using an infusion cannula that we advocate. Lastly, obtaining the infusion cannula seems like a small inconvenience (and an even smaller cost) to the physician compared to the risk of doing intravitreal injections of corticosteroids as a treatment of first choice as advocated by Vedantham. We strongly encourage all uveitis and retina specialists who have up until now been disappointed with the efficacy of their sub-Tenon's corticosteroid injections, to make the effort to obtain an appropriate cannula and revise their technique before jumping to intravitreal procedures.

In reply to the first comment by Dr Mehta,⁶ we acknowledge the current WHO guidelines, revised for 2003, that include recommendations for extrapulmonary tuberculosis.⁷ However, we would also like to amend Mehta's comment, in that the WHO admits in those guidelines that there are many

regimens with reported efficacy including a 6 month regimen of rifampicin (with streptomycin also given in the initial phase only) for meningeal tuberculosis. Furthermore, the WHO recommendations are for active extrapulmonary tuberculosis that has been diagnosed by specimen examination or strong clinical evidence, and give no recommendations for latent infection. As we have previously reported in a series on intraocular tuberculosis, systemic examination failed to identify a focus of active tuberculosis in the majority of our patients,⁸ and we have come to suspect that the uveitis we observed may be an immune response to latent tuberculosis antigen sequestered elsewhere. Therefore, the patients we described were given a diagnosis of "presumed intraocular tuberculosis," that is with uveitis presumed to be related to the *Mycobacterium tuberculosis* organism. Furthermore, we would like to clarify that in the cases of presumed ocular tuberculosis that received trans-Tenon's retrobulbar triamcinolone infusion,¹ this treatment was judged to be effective in two of three eyes. Regardless, since the focus of active or latent tuberculosis was never identified in our patients, a two drug regimen of isoniazid and rifampicin was used as a therapeutic trial for antituberculosis therapy. A similar therapeutic trial for ocular tuberculosis, albeit with isoniazid alone, has been previously advocated in Japan by Ishihara and Ohno.⁹

With regard to the second comment, among the 16 patients who were receiving some form of systemic immunosuppressive therapy, we did not notice any difference in outcome when compared to patients who were not on immunosuppressive therapy. In other words, the efficacy of trans-Tenon's retrobulbar triamcinolone infusion was the same. However, we suspect that the recurrence rate after triamcinolone infusion may be different, and we are currently investigating this possibility.

A A Okada, T Wakabayashi

Kyrorin Eye Center, Kyrorin University School of Medicine, Tokyo, Japan

Correspondence to: Annabelle A Okada, Kyrorin Eye Center, Kyrorin University School of Medicine, Tokyo, Japan; aokada@po.iijnet.or.jp

doi: 10.1136/bjo.2003.038851

Accepted for publication 20 November 2003

References

- 1 **Okada AA, Wakabayashi T, Morimura Y, et al.** Trans-Tenon's retrobulbar triamcinolone infusion for the treatment of uveitis. *Br J Ophthalmol* 2003;**87**:968-71.
- 2 **Jennings T, Rusin MM, Tessler HH, et al.** Posterior sub-Tenon's injections of corticosteroids in uveitis patients with cystoid macular edema. *Jpn J Ophthalmol* 1988;**32**:385-91.
- 3 **Tessler H.** Uveitis. In: Peyman GA, Sanders DR, Goldberg MF, eds. *Principles and practice of ophthalmology*, Vol 2. 1st ed. Philadelphia: Saunders, 1980:1554-629.

- 4 **Freeman WR, Green RL, Smith RE.** Echographic localization of corticosteroids after periocular injection. *Am J Ophthalmol* 1987;**103**:281-8.
- 5 **Benz MS, Murray TG, Dubovy SR, et al.** Endophthalmitis caused by *Mycobacterium chelonae* abscessus after intravitreal injection of triamcinolone. *Arch Ophthalmol* 2003;**121**:271-3.
- 6 **Mehta SA.** Trans-Tenon's triamcinolone and pretreatment. *Br J Ophthalmol* 2003. www.bjophthalmol.com/cgi/eletters/87/8/968#183, 1 Aug 2003.
- 7 **World Health Organization.** Case definitions (p 24) and standardised treatment regimens (p 35-36). In: *Treatment of tuberculosis: guidelines for national programmes*, 3rd ed. (WHO/CDS/TB/2003.313). Geneva: WHO, 2003 (accessed on 13 October 2003).
- 8 **Morimura Y, Okada AA, Kawahara S, et al.** Tuberculin skin testing in uveitis patients and treatment of presumed intraocular tuberculosis in Japan. *Ophthalmology* 2002;**109**:851-7.
- 9 **Ishihara M, Ohno S.** [Ocular tuberculosis]. *Nippon Rinsho* 1998;**56**:3157-61.

Owls' eyes move

"Double crossed," the cover illustration and article by Schwab on the barn owl refers to the alleged immobility of the owl's eyes.¹ This is a myth which should not be perpetuated in the *BJO*. The owl's eyes do in fact move, and while the amount is not large, it is just enough for two papers on the subject²⁻³ The phrase "nearly immobile" is preferable.

M J Steinbach

Correspondence to: Professor Martin J Steinbach, University of Toronto, Department of Ophthalmology and Vision Sciences, Toronto Western Hospital, 399 Bathurst Street, Toronto M5T 2S8, Canada; mjs@yorku.ca

doi: 10.1136/bjo.2004.042291

Accepted for publication 16 January 2004

References

- 1 **Schwab IR.** Double crossed. *Br J Ophthalmol* 2003;**87**:1442.
- 2 **Steinbach MJ, Money KE.** Eye movements of the owl. *Vis Res* 1973;**13**:889-91.
- 3 **Steinbach MJ, Angus RG, Money KE.** Torsional eye movements of the owl. *Vis Res* 1974;**14**:745-6.

Tropical Medicine, Keppel Street, London WC1E 7HT, UK (tel: +44 (0)20 7612 7964; email: Anita.Shah@lshtm.ac.uk; online edition: www.jceh.co.uk). Annual subscription (4 issues) UK £28/US\$45. Free to developing country applicants.

Elimination of avoidable blindness

The 56th World Health Assembly (WHA) considered the report on the elimination of avoidable blindness (doc A56/26) and urged Member States to: (1) Commit themselves to supporting the Global Initiative for the Elimination of Avoidable Blindness by setting up a national Vision 2020 plan by 2005; (2) Establish a national coordinating committee for Vision 2020, or a national blindness prevention committee to help implement the plan; (3) Implement the plan by 2007; (4) Include effective monitoring and evaluation of the plan with the aim of showing a reduction in the magnitude of avoidable blindness by 2010; (5) To support the mobilisation of resources for eliminating avoidable blindness. The WHA also urged the Director-General to maintain and strengthen WHO's collaboration with Member States and the partners of the Global Initiative for the Elimination of Avoidable Blindness as well as aid in the coordination and support of national capability.

4th International Congress on Autoimmunity

The 4th International Congress on Autoimmunity will take place 3-7 November 2004 in Budapest, Hungary. The deadline for the receipt of abstracts is 20 June 2004. Further details: Kenes International Global Congress Organisers and Association Management Services, 17 Rue du Cendrier, PO Box 1726, CH-1211 Geneva 1, Switzerland (tel: +41 22 908 0488; fax: +41 22 732 2850; email: autoim04@kenes.com; website: www.kenes.com/autoim2004).

XVI International Congress for Eye Research

The XVI International Congress for Eye Research will be held on 29 August - 3 September 2004 in Sydney, Australia. For further information, please contact: icer2004@tourhosts.com.au (website: www.tourhosts.com.au/icer2004).

Glaucoma Society Silver Jubilee Meeting 2004

The Silver Jubilee Meeting and Dinner for the Glaucoma Society will be held on 3 December 2004 at the Royal College of Physicians in Regents Park, London. The meeting will take place between 8.30am and 5pm and the dinner will be held between 6.30pm and 10pm. For further information, please contact: Janet Flowers, Administrator, 29 Quarry Hill, Grays, Essex, RM17 5BT (tel: 01375 383172; e-mail: glausoc@ukeire.freeseve.co.uk).

NOTICES

Low vision care

The latest issue of *Community Eye Health* (No 49) deals with the problems and management of low vision. For further information please contact: Journal of Community Eye Health, International Resource Centre, International Centre for Eye Health, Department of Infectious and Tropical Diseases, London School of Hygiene and