

PostScript

LETTERS

If you have a burning desire to respond to a paper published in *BJO*, why not make use of our "rapid response" option?

Log onto our website (www.bjophthalmol.com), find the paper that interests you, and send your response via email by clicking on the "eletters" option in the box at the top right hand corner.

Providing it isn't libellous or obscene, it will be posted within seven days. You can retrieve it by clicking on "read eletters" on our homepage.

The editors will decide as before whether to also publish it in a future paper issue.

Cystoid macular oedema with trypan blue use

We present a large comparative series of trypan blue use in cataract surgery. This series of trypan blue used in all eyes regardless of cataract severity may be unique. We found an apparent increased rate of cystoid macular oedema (CMO) associated with trypan blue use.

Melles *et al*'s¹ report on the use of trypan blue in cataract extraction in 1999 combined with Apple *et al*'s²⁻⁴ series on dye enhanced cataract surgery facilitated widespread acceptance of this technique. The dye has been shown to stain basement membrane of lens capsule.⁵ Trypan blue is now widely used to assist in cataract extraction when visualisation of the anterior capsule is poor because of loss of red reflex. Trypan blue has also been used to improve contrast during cataract extraction in eyes with corneal opacities⁶ and to stain internal limiting membrane and epiretinal membrane during vitreoretinal surgery.^{7,8} The safety profile of trypan blue appears good with no adverse effects reported in several large series.⁹⁻¹¹

Patients and methods

In this retrospective, comparative study we identified a consecutive series of 75 patients (group A) in whom trypan blue had been used "routinely" regardless of cataract type or density. A consecutive series of 94 patients (group B) who had routine phacoemulsification by the same surgeon were used as a control group.

Apart from the use of trypan blue to facilitate capsulorhexis, standard phacoemulsification techniques were used in both groups.

The data from the two cohorts were compared using mean and standard deviations for continuous variables such as age, and proportions for categorical variables such as sex. For acuity a numeric ordinal score was created from 1 to 10 by placing all the recorded acuities in order. This numeric ordinal score allowed us to plot the data using box plots, and to analyse the data using non-parametric methods to produce p values where necessary.

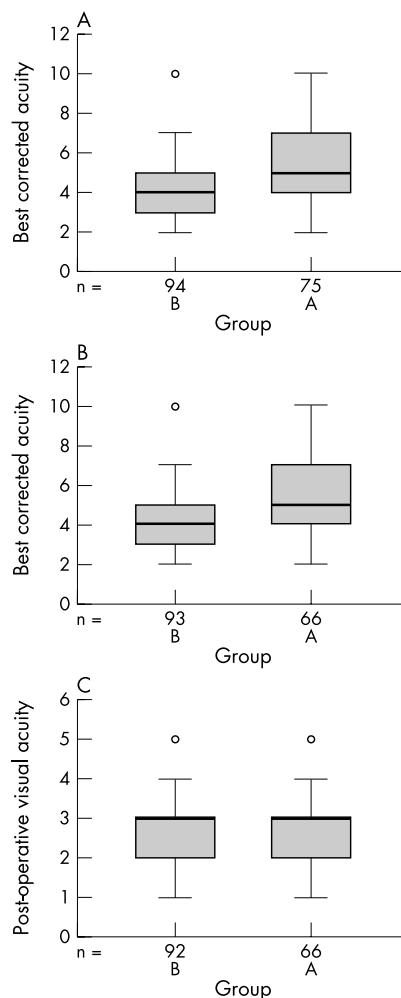


Figure 1 (A) Preoperative best corrected acuity (group A = 75, group B = 94); (B) preoperative acuity without co-morbidity (group A = 66, group B = 93); (C) postoperative acuity without co-morbidity. Acuity key: 6/5 = 1; 6/6 = 2; 6/9 = 3; 6/12 = 4; 6/18 = 5; 6/24 = 6; 6/36 = 7; 6/60 = 8; 2/60 = 9; <2/60 = 10.

Results

The two groups compared favourably with regard to age and sex (table 1) but the preoperative best corrected acuity was worse

in group A (fig 1A). Group A also had a higher proportion of patients with ocular co-morbidity (table 1).

If all the cases with co-morbidity are removed from both groups, the preoperative best corrected acuity remains worse in group A, suggesting that the cataracts in this group were visually of greater significance (fig 1B).

There were four patients with clinically apparent CMO in group A and no cases in group B. The CMO was confirmed in all cases by the vitreoretinal specialist (PRS) using standard biomicroscopy techniques with a fundal contact lens. The incidence of clinically apparent CMO was 5.3% in group A and 0% in group B ($p = 0.037$).

All cases of CMO were treated with a combination of topical steroid and non-steroidal anti-inflammatory drops and resolved completely with good visual outcomes.

The postoperative acuities compared favourably in both groups after patients with co-morbidity were removed from both groups (fig 1C).

Comment

Cystoid macular oedema resulting in visual loss occurs in up to 3.8% of cases following cataract extraction by phacoemulsification without posterior capsule rupture^{12,13} and up to 13% of cases with posterior capsule rupture.^{14,15} Ursell *et al*¹⁶ demonstrated an incidence of *angiographic* CMO of 19% following phacoemulsification (none of the patients in this group had clinically apparent CMO).

CMO has *not* been reported as a result of trypan blue use, but trypan blue has been shown to cause damaged photoreceptors in rabbit eyes after intravitreal injection.¹⁷ Trypan blue has also been shown to be carcinogenic and teratogenic in animal studies.^{18,19} The clinical significance or relevance to a human population of the animal studies is uncertain.

Trypan blue has been shown to inadvertently stain posterior capsule²⁰ and intra-ocular lens implants.^{21,22}

None of the patients in our group who developed CMO had associated posterior capsule rupture or ocular co-morbidity and all of the cases were treated successfully with good visual outcomes.

Dada *et al*²³ and Sharma *et al*²⁴ suggested the use of trypan blue in routine cases to aid in training of junior surgeons. Our study would suggest some caution with this approach in view of the apparent increase in the incidence of CMO with trypan blue use.

Table 1 Age and sex distribution and co-morbidity

Variable	Group A (n=75)	Group B (n=94)
Mean age (SD)	79.4 (9.8)	78.4 (8.5)
Sex:		
Male	25 (33.3%)	31 (33%)
Female	50 (66.7%)	63 (67%)
ARMD	7	1
CVA	1	0
ERM	1	0

ARMD, age related macular degeneration; CVA, cerebrovascular accident; ERM, epiretinal membrane.

The preoperative best corrected acuity was decreased in the group in which trypan blue was used. This suggests that the cataracts in this group were of greater density, possibly requiring more energy to remove using phacoemulsification. The energy used during surgery however was not recorded. The CMO may therefore be a reflection of higher energy used in denser cataract.

A prospective trial with matched cohorts is required to prove the suggested higher incidence of CMO with trypan blue use. OCT scanning of the maculas in both groups would give non-invasive objective evidence of CMO.

We suggest the following steps to limit the apparent complication of CMO with trypan blue use:

- Use the smallest amount and lowest concentration of trypan blue possible (trypan blue in concentrations as low as 0.0125% has been shown to effectively stain the anterior capsule²⁵)
- Increase postoperative steroid or anti-inflammatory drops prophylactically
- Use only in appropriate cases—that is, with poor visualisation of the anterior capsule.

**P Gouws, M Merriman, S Goethals,
P R Simcock, R J Greenwood, G Wright**
Bristol Eye Hospital, Lower Maudlin Street,
Bristol BS1 2LX, UK

Correspondence to: P Gouws, Bristol Eye Hospital,
Bristol, UK; pieter@gouws.freeserve.co.uk

doi: 10.1136/bjo.2004.041756

Accepted for publication 12 February 2004

References

- 1 **Melles GR, de Waard PW, Pameyer JH, et al.** Trypan blue capsule staining to visualize the capsulorhexis in cataract surgery. *J Cataract Refract Surg* 1999;**25**:7–9.
- 2 **Pandey SK, Werner L, Escobar-Gomez M, et al.** Dye-enhanced cataract surgery. Part 1: Anterior capsule staining for capsulorhexis in advanced/white cataract. *J Cataract Refract Surg* 2000;**26**:1052–9.
- 3 **Werner L, Pandey SK, Escobar-Gomez M, et al.** Dye-enhanced cataract surgery. Part 2: Learning critical steps of phacoemulsification. *J Cataract Refract Surg* 2000;**26**:1060–5.
- 4 **Pandey SK, Werner L, Escobar-Gomez M, et al.** Dye-enhanced cataract surgery. Part 3: Posterior capsule staining to learn posterior continuous curvilinear capsulorhexis. *J Cataract Refract Surg* 2000;**26**:1066–71.
- 5 **Singh AJ, Sarodia UA, Brown L, et al.** A histological analysis of lens capsules stained with trypan blue for capsulorhexis in phacoemulsification cataract surgery. *Eye* 2003;**17**:567–70.
- 6 **Bhartiya P, Sharma N, Ray M, et al.** Trypan blue assisted phacoemulsification in corneal opacities. *Br J Ophthalmol* 2002;**86**(8):857–9.
- 7 **Perrier M, Sebag M.** Trypan blue-assisted peeling of the internal limiting membrane during macular hole surgery. *Am J Ophthalmol* 2003;**135**:903–5.
- 8 **Li K, Wong D, Hiscott P, et al.** Trypan blue staining of internal limiting membrane and epiretinal membrane during vitrectomy: visual results and histopathological findings. *Br J Ophthalmol* 2003;**87**:216–9.
- 9 **Jacob S, Agarwal A, Agarwal A, et al.** Trypan blue as an adjunct for safe phacoemulsification in eyes with white cataract. *J Cataract Refract Surg* 2002;**28**:1819–25.
- 10 **Melles GR, de Waard PW, Pameijer JH, et al.** [Staining the lens capsule with trypan blue for

visualizing capsulorhexis in surgery of mature cataracts]. *Klin Monatsbl Augenheilkd* 1999;**215**:342–4 (In German).

- 11 **Van Dooren BT, de Waard PW, Poort-van Nieuhuys H, et al.** Corneal endothelial cell density after trypan blue capsule staining in cataract surgery. *J Cataract Refract Surg* 2002;**28**:574–5.
- 12 **Malik AR, Qazi ZA, Gilbert C.** Visual outcome after high volume cataract surgery in Pakistan. *Br J Ophthalmol* 2003;**87**:937–40.
- 13 **Riley AF, Malik TY, Grupcheva CN, et al.** The Auckland Cataract Study: co-morbidity, surgical techniques, and clinical outcomes in a public hospital service. *Br J Ophthalmol* 2002;**86**:185–90.
- 14 **Chan FA, Mathur R, Ku JJK, et al.** Short-term outcomes in eyes with posterior capsule rupture during cataract surgery. *J Cataract Refract Surg* 2003;**29**(3):537–41.
- 15 **Blomquist PH, Rugwani RM.** Visual outcomes after vitreous loss during cataract surgery performed by residents. *J Cataract Refract Surg* 2002;**28**:847–52.
- 16 **Ursell PG, Spalton DJ, Whitcup SM, et al.** Cystoid macular edema after phacoemulsification: relationship to blood-aqueous barrier damage and visual acuity. *J Cataract Refract Surg* 1999;**25**:1492–7.
- 17 **Veckeneer M, van Overdam K, Manzer J, et al.** Ocular toxicity study of trypan blue injected into the vitreous cavity of rabbit eyes. *Graefes Arch Clin Exp Ophthalmol* 2001;**239**:698–704.
- 18 **Chung KT.** The significance of azo-reduction in the mutagenesis and carcinogenesis of azo dyes. *Mutat Res* 1983;**114**:269–81.
- 19 **Ema M, Kanoh S.** Studies on the pharmacological bases of fetal toxicity of drugs. Effect of trypan blue on pregnant rats and their offspring. *Nippon Yakurigaku Zasshi* 1982;**79**:369–81.
- 20 **Birchall W, Raynor MK, Turner GS.** Inadvertent staining of the posterior lens capsule with trypan blue dye during phacoemulsification. *Arch Ophthalmol* 2001;**119**:1082–3.
- 21 **Werner L, Apple DJ, Crema AS, et al.** Permanent blue discoloration of a hydrogel intraocular lens by intraoperative trypan blue. *J Cataract Refract Surg* 2002;**28**:1279–86.
- 22 **Fritz WL.** Digital image analysis of trypan blue and fluorescein staining of anterior lens capsules and intraocular lenses. *J Cataract Refract Surg* 2002;**28**:1034–8.
- 23 **Dada T, Ray M, Bhartiya P, et al.** Trypan-blue-assisted capsulorhexis for trainee phacoemulsification surgeons. *J Cataract Refract Surg* 2002;**28**:575–6.
- 24 **Sharma N, Bhartiya P, Sinha R, et al.** Trypan blue assisted phacoemulsification by residents in training. *Clin Experiment Ophthalmol* 2002;**30**:386–7.
- 25 **Yetik H, Devranoglu K, Ozkan S.** Determining the lowest trypan blue concentration that satisfactorily stains the anterior capsule. *J Cataract Refract Surg* 2002;**28**:988–91.

Familial intraocular cysts in association with anisometropia

Vitreous cysts are rare. Their origin is postulated to be a congenital remnant of the primary hyaloidal system¹ or ciliary body pigment epithelium.² Although most vitreal cysts are asymptomatic, some may cause intermittent visual field defects. Treatment is seldom indicated, though laser photocoagulation or vitrectomy have been suggested.^{1,3}

Iris cysts include iris pigment epithelial cysts and stromal cysts.⁴ The former may get dislodged into either the anterior chamber or into the vitreous chamber. They become symptomatic when they enlarge and occlude the visual axis. Treatment includes aspiration or surgical excision of the cyst.

Both vitreous and iris cysts have been previously reported as sporadic findings. In this report, we present the clinical and echographic manifestations of intraocular cysts in two siblings.

Case report

Two sisters, 11 and 3 years old, were referred for evaluation because of intraocular cysts and amblyopic fellow eyes. They were the products of a full term normal pregnancy with an uneventful perinatal history. Their parents were not relatives. Past medical history was unremarkable. The children in the family were reportedly healthy with no ocular pathology but were inaccessible for examination.

The older sister was known to have worn glasses since the age of 7 years. She complained of intermittent obscuration of vision in her right eye. Her vision was 6/12, J1 right eye and counting fingers at 1 metre with J14 left eye. By indirect ophthalmoscopy of her right eye, a round pigmented, cystic structure was observed in the vitreous cavity (fig 1). The left fundus showed myopic chorioretinal changes with a tilted optic disc. Retinoscopy showed marked myopic anisometropia of +1.00–1.25×75° right eye and –10.50–2.00×95° left eye. Ultrasonography disclosed a 3.05 mm cystic, round, hypoechogenic vitreal structure (fig 1). It was partially mobile with vitreal after-movements and was tethered to fine vitreal strands. Its walls showed internal reflectivity of 60%, whereas its contents had very low (<5%) reflectivity.

The younger sister was fitted with spectacles at the age of 7 months because of anisometropic myopia. Her visual acuity (picture cube) was 0.03 right eye with unsteady fixation and 0.2 left eye. In her left eye a cystic, pigmented lesion was attached to the posterior iris surface and extended into the anterior vitreous (fig 2). It was located in the superotemporal quadrant causing adjacent lenticular cortical opacities. Indirect ophthalmoscopy revealed bilateral mild retinal myopic changes. High frequency echography of the iris lesion disclosed a cyst with hypoechogenic content measuring 3.68 mm in diameter (fig 2). Cycloplegic refraction showed anisometropic myopia of –7.5–1.00×90° right eye and –0.5–3.50×80° left eye.

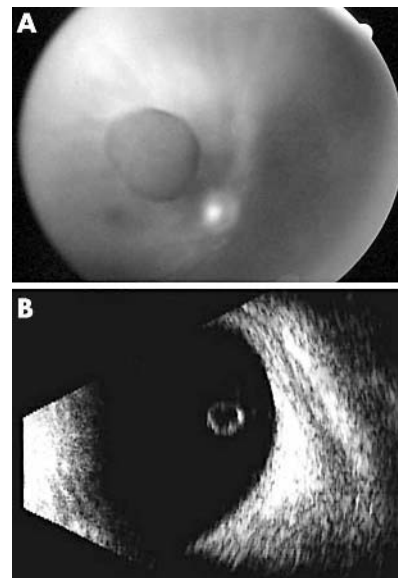


Figure 1 (A) Homogeneously pigmented vitreous cyst. (B) B-scan echography that demonstrates a round, echolucent vitreous cyst bound by fine vitreal strands.

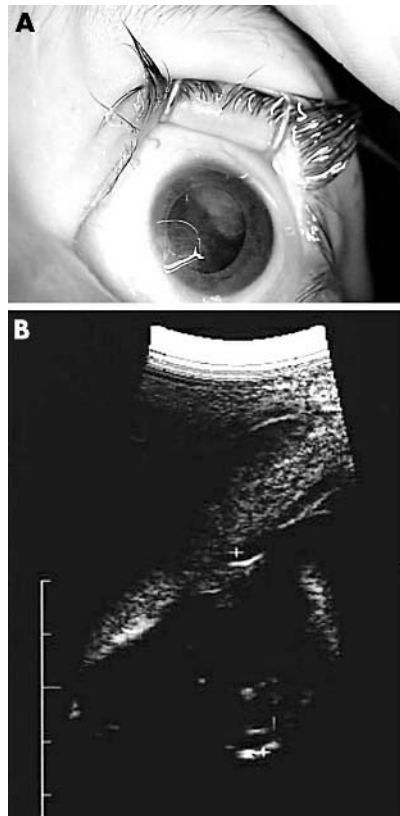


Figure 2 (A) Cystic structure extending from the posterior layer of the iris in the superotemporal quadrant. (B) High frequency echography that shows a cystic structure attached to the posterior iris.

The poor vision in the fellow eye (without cyst) was attributed to the high anisometropia present in both sisters. They were prescribed glasses with anti-amblyopic therapy by patching. No invasive therapy of the cysts in the eye with better vision was recommended.

Comment

This reports the unusual association between vitreous and iris cysts found in two siblings. The familial clustering of pigmented intraocular cysts suggests a hereditary aetiology in these sisters. Sallo *et al*⁷ reported on the occurrence of primary marginal pigment epithelial iris cysts in four members of one family, thus postulating an autosomal dominant heredity pattern. Nork and Millecchia¹ reported an association between vitreous cyst in a patient and corneal dermoid in her son. A familial association between vitreous cyst and iris cyst was not previously reported. Our study, in accordance with previous reports, emphasises the need for examination of family members once an intraocular cyst has been diagnosed in a young child.

The second unusual association described in these siblings is the deeply amblyopic fellow eye with high anisometropic myopic astigmatism. It is not clear whether axial myopia developed because of the amblyopia or whether the amblyopia is secondary to anisometropia. Amblyopia in anisometropia results from the suppression of cortical vision centres that receive inputs from the chronically defocused eye. Also, the eyes of a child

with anisometropic amblyopia look normal to the family, leading to delay in detection and treatment.

The physical characteristics of the vitreous cyst we described, including its confinement to the region of Cloquet's canal, are similar to those reported by others.¹ This suggests that the cysts may be remnants of the persistent fetal vasculature, though this manifestation was not included in Goldberg's description of this disease.⁶ However, since no surgical excision was performed, we may postulate regarding their cellular origin. Nork and Millecchia¹ suggested after histological studies, that the cyst origin was pigment epithelial-type cells. In our study, indirect evidence that the cysts originated from pigment epithelium include their homogeneous brown pigmentation, medium reflectivity, and continuation of iris cyst with the posterior iris surface. The cellular origin of the vitreal cyst is less obvious. It can either be a primary congenital hyaloidal remnant or a cyst that detached from the iris during childhood. Only few have reported on vitreous cysts jarring loose from the ciliary body pigment epithelium.²

R Amer, I Anteby

Department of Ophthalmology, Hadassah University Hospital, Jerusalem, Israel

Correspondence to: Radgonda Amer, MD, Department of Ophthalmology, Hadassah University Hospital, POB 12000, Jerusalem 91120, Israel; rodgonda@hotmail.com

doi: 10.1136/bjo.2003.041277

Accepted for publication 29 February 2004

Proprietary interest: none.

References

- 1 Nork TM, Millecchia LL. Treatment and histopathology of a congenital vitreous cyst. *Ophthalmology* 1998;**105**:825-30.
- 2 Lisch W, Rochels R. Pathogenesis of congenital vitreous cysts. *Klin Monatsbl Augenheilkd* 1989;**195**:375-8.
- 3 Awan KJ. Biomicroscopy and argon laser photostyloscopy of free-floating vitreous cysts. *Ophthalmology* 1985;**92**:1710-11.
- 4 Shields JA, Kline MW, Augsburger JJ. Primary iris cysts: a review of the literature and report of 62 cases. *Br J Ophthalmol* 1984;**68**:152.
- 5 Sallo FB, Haivani I. Recurring transitory blindness caused by primary marginal pigment epithelial iris cysts. *Am J Ophthalmol* 2002;**133**:407-9.
- 6 Goldberg MF. Persistent fetal vasculature (PFV): an integrated interpretation of signs and symptoms associated with persistent hyperplastic primary vitreous (PHPV). LIV Edward Jackson Memorial Lecture. *Am J Ophthalmol* 1997;**124**:587-626.

Central retinal artery occlusion and ophthalmoplegia following spinal surgery

Visual loss and ophthalmoplegia are very infrequent complications after spinal surgery.¹⁻³ Visual loss may be caused by ischaemic optic neuropathy, central retinal artery or vein occlusion, or occipital stroke.²⁻³ Previous reports have attributed this complication to patient positioning, intraoperative blood loss, and controlled hypotension or shock.²⁻³ Associated risk factors include anaemia, prolonged surgical time, bradyarrhythmia, hypertension, diabetes, smoking, vascular disease, and increased blood viscosity.²⁻⁶ Ophthalmoplegia after spinal surgery is even more unusual than visual loss, and only few

reports exist in the literature.⁶⁻⁸ Moreover, magnetic resonance image (MRI) studies to differentiate between cavernous sinus thrombosis and direct compression of orbital contents have not been previously described. We therefore report two patients who developed this unusual combination of ophthalmoplegia and central retinal artery occlusion (CRAO) after spinal surgery.

Case 1

A 62 year old male ex-smoker underwent a L2-L3 posterior spinal decompression and segmental instrumentation for lumbar stenosis and scoliosis, in prone position with ocular protection (gauze swab and tape). The surgery lasted 2 hours and 45 minutes. Before the procedure blood pressure was 140/60 mm Hg and during operation it was maintained at 90/60 mm Hg. Just after surgery he complained of visual loss and left ocular and nasal pain. Examination revealed left palpebral oedema, local erythema, blindness, and total ophthalmoplegia of the left eye. Left pupil was dilated and fixed. The funduscopic examination showed retinal oedema, a central cherry-red spot at the macula, and attenuated arteries. The rest of his neurological examination was normal.

The haematocrit dropped from 43% to 34%. The brain MRI was normal and the orbit MRI revealed enlargement and hyperintensity of left ocular muscles in T2 weighted images sparing their tendons (fig 1). Ocular motility recovered in 4 weeks but visual loss persisted until the last follow up at 7 months.

Case 2

A 23 year old man with a history of tobacco abuse and asthma underwent a prolonged cervical arthrodesis in prone position caused by C7 vertebral collapse with spinal contusion. Immediately after surgery he complained of left visual loss and he was referred to our hospital. Details of duration of surgery, ocular protection, intraoperative blood pressure, and haematocrit were unavailable. Upon examination he showed blindness of the left eye with palpebral oedema, orbital pain, and total external ophthalmoplegia. The funduscopic examination revealed a pale retina with a macular cherry-red spot. The pupil was dilated and fixed. The MRI studies showed a normal brain, but swelling of the left extraocular muscles; MRI angiography and ophthalmic echo Doppler were normal. After 3 months

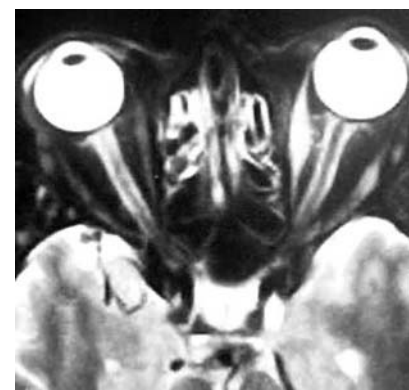


Figure 1 MRI of the orbit. T2 weighed image shows proptosis and oedema of extraocular muscles in the left eye, sparing their tendons.

Table 1 Reported patients with postoperative CRAO, ophthalmoplegia, or both

Author	Sex/age	Surgery	Position	Instrumentation	Operating time (minutes)	Blood pressure (mm Hg)	CRAO	Ophthalmoplegia
Slocum 1948 ⁹	F/55	Neurosurgical	Prone	No	180	80/60	Right	No
Givner 1950 ⁴	M/late 50s	Abdominal	Supine	No	265	Shock	Right	No
	F/33	Abdominal	Supine	No	85	Mild shock	Right	No
	F/37	Abdominal	Supine	No	90	Shock	Left	No
	F/40	Abdominal	Supine	No	Unknown	Unknown	Right	No
Gillan 1953 ⁵	M/26	Abdominal	Supine	No	At least 100	Systolic 70	Left	No
	F/48	Abdominal	Supine	No	At least 140	Systolic 55	Left	No
Hollenhorst 1954 ⁸	M/48	Spine	Prone	No	120	Normal	Left	No
	M/29	Neurosurgical	Sitting	No	120	Normal	Left	No
	M/65	Spine	Prone	No	120	Normal	Left	No
	M/50	Spine	Prone	No	180	90/60	Left	Yes
	M/39	Spine	Prone	No	180	Normal	Left	Yes
	F/36	Neurosurgical	Prone	No	240	Normal	Left	Yes
	M/50	Spine	Upright	No	240	Normal	Right	Yes
	M/29	Neurosurgical	Prone	No	360	92/55	Left	Yes
Bradish 1987 ¹⁰	F/12	Spine	Prone	Yes	180	Systolic 50	Left	No
West 1990 ⁷	F/50	Spine	Prone	Yes	270	Systolic 70–90	Left	Yes
Wolfe 1992 ⁶	F/28	Spine	Prone	Yes	135	90/60	Right	Yes
Grossman 1993 ¹³	F/12	Spine	Prone	Yes	360	Mean 70–80	Right	No
Halfon 2004	M/62	Spine	Prone	Yes	165	140/60–90/60	Left	Yes
	M/23	Spine	Prone	Yes	Unknown	Unknown	Left	Yes

CRAO, central retinal artery occlusion.

vision did not recover but ocular motility partially improved.

Comment

Our two patients developed complete ophthalmoplegia and CRAO after spinal surgery. Intraoperative ocular protection was used at least in the first patient. Common features included prone position and postoperative signs of orbital swelling. Imaging studies revealed signs of oedema in extraocular muscles sparing their tendons. To our knowledge, extraocular muscles abnormalities in MRI have not been previously reported. Ophthalmoplegia partially improved in one patient and fully recovered in the other within a few weeks, but visual loss persisted in both cases.

Stevens *et al.*² in a retrospective review of 3450 spinal surgeries, identified seven patients (incidence 0.2%) with visual loss caused by ischaemic optic neuropathy, occipital infarction, or central retinal vein occlusion, but neither presented with CRAO or extraocular muscle abnormalities.

Only few patients with CRAO following surgery have been previously described in the English literature (table 1). Moreover, Little¹ analysed 27 930 cases of controlled hypotension anaesthesia and found only three cases of CRAO. No details of surgical positioning or procedure were given. Since the original report of Slocum *et al.*,⁹ it has been emphasised that CRAO may be the result of extrinsic ocular pressure caused by head rest or anaesthetic mask malposition in the presence of hypotension, shock, and prolonged anaesthesia.^{4 5 8–10}

Ophthalmoplegia related to spinal surgery is also an exceptional complication. West *et al.*⁷ described a patient who developed unilateral total external ophthalmoplegia and unilateral visual loss following scoliosis surgery. An orbit computed tomography scan performed 1 week later showed left proptosis and swelling of the left medial rectus and ruled out cavernous sinus thrombosis. The authors suggested that perioperative ocular compression might be the cause. Wolfe *et al.*⁶ reported a young woman who suffered a

right CRAO after an instrumented spinal surgery. Postoperatively, the patient had blindness, moderate ptosis, restriction of the extraocular movements, and paraesthesias in the supraorbital region of the same eye. A CT scan of the brain and orbits showed only mild oedema of the right optic nerve. Ocular motility improved but the visual loss did not. Although prognosis is usually very poor, a recent patient described in Japan was treated successfully with urokinase and PGE1, stellate ganglion block, and hyperbaric oxygen therapy.¹¹

Hollenhorst *et al.*⁸ reported eight cases of unilateral visual loss after inadvertent orbital pressure during general anaesthesia for neurosurgical procedures. The most severe cases had proptosis, ptosis, and paralysis of extraocular musculature with no recovery. Moreover, they provoked visual loss and ophthalmoplegia by orbital compression for 60 minutes in seven rhesus monkeys, in the setting of hypovolaemia and hypotension. They proposed that partial or complete collapse of the arterial and venous channels of the orbit, occurred as a result of a tamponade action of the ocular contents. When the external pressure is released, the ischaemic vascular channels dilate and there is a transudation of fluid through the permeable walls into the tissue spaces. This results in orbital oedema, proptosis, paresis of ocular movement, and massive oedema of the retina. Based on findings from this animal model, it is likely that external pressure during the surgical procedure induces occlusion of the arterial and venous orbital vessels. The increased MRI signal in extraocular muscles is probably the expression of post-ischaemic oedema facilitated by the richer vascular supply and the more prominent extravascular space characteristic of these muscles.¹² Reversibility of ophthalmoplegia will probably depend on the degree of ischaemia suffered by both the extraocular muscles and the III, IV, and VI cranial nerves.

CRAO and ophthalmoplegia are unusual, but severe, complications after spinal surgery. Postoperative signs of orbital swelling, only in the affected eyes, were clear evidence of intraoperative compression in our patients.

The increase in intraorbital pressure associated with hypotension, shock, anaemia, prolonged operative time, and bradyarrhythmia are considered to be the main risk factors for developing CRAO and ophthalmoplegia. Adequate eye protection during surgery, and meticulous attention to keep the eyes free from pressure, can reduce the risk of these potentially avoidable serious complications.

Acknowledgement

We thank Dr John Stewart for his critical reading of the manuscript.

M J Halfon, P Bonardo, S Valensi,
M C Zaffaroni, M M Fernandez Pardal,
D Ribero Ayerza, R Ebner, P Anderson,
R C Reinis

Hospital Britanico, Perdriel 74, Buenos Aires
C1280AEB, Argentina

Correspondence to: Dr Mario J Halfon, Hospital Britanico, Perdriel 74, Buenos Aires C1280AEB, Argentina; mjhalfon@yahoo.com

doi: 10.1136/bjo.2003.039651

Accepted for publication 14 February 2004

References

- Little DM. Induced hypotension during anaesthesia and surgery. *Anesthesiology* 1955;16:320–32.
- Stevens WR, Glazer PA, Kelley SD, *et al.* Ophthalmic complications after spinal surgery. *Spine* 1997;12:1319–24.
- Myers MA, Hamilton SR, Bogosian AJ, *et al.* Visual loss as a complication of spine surgery: a review of 37 cases. *Spine* 1997;12:1325–9.
- Givner I, Jaffe N. Occlusion of the central retinal artery following anaesthesia. *Arch Ophthalmol* 1950;43:197–201.
- Gillan JG. Two cases of unilateral blindness following anaesthesia with vascular hypotension. *Can Med Assoc J* 1953;69:294–6.
- Wolfe SW, Lospinoso MF, Burke SW. Unilateral blindness as a complication of patient positioning for spinal surgery. A case report. *Spine* 1992;17:600–5.
- West J, Askin G, Clarke M, *et al.* Loss of vision in one eye following scoliosis surgery. *Br J Ophthalmol* 1990;74:243–4.
- Hollenhorst RW, Svien HJ, Benoit CF. Unilateral blindness occurring during anaesthesia for

- neurosurgical operations. *Arch Ophthalmol* 1954;**52**:819–30.
- 9 **Slocum HC**, O'Neal KC, Allen CR. Neurovascular complications from malposition on the operating table. *Surg Gynecol Obstet* 1948;**86**:729–34.
 - 10 **Bradish CF**, Flowers M. Central retinal artery occlusion in association with osteogenesis imperfecta. *Spine* 1987;**12**:193–4.
 - 11 **Takeuchi M**, Morita K, Nakatsuka H, *et al.* A case of central retinal artery occlusion after anterior posterior fusion of the lumbar spine. *Masui* 2001;**50**:899–901.
 - 12 **Kaissar BA**, Kim JH, Bravo S, *et al.* Histologic basis for increased extraocular muscle enhancement in gadolinium-enhanced MR imaging. *Radiology* 1991;**179**:541–2.
 - 13 **Grossman W**, Ward WT. Central retinal artery occlusion after scoliosis surgery with a horseshoe headrest. Case report and literature review. *Spine* 1993;**18**:1226–8.

MAILBOX

Prophylaxis of ophthalmia neonatorum

I read with great interest the article by Isenberg *et al.*¹ The authors deserve to be commended for their pioneering interest in childhood blindness. There are certain points that I would like to clarify and supplement with regard to their study.

(1) The authors have mentioned that only babies born by a vaginal delivery were studied, since the eyes of babies delivered by caesarean section were previously proved to be nearly always sterile. This would result in a gross underestimation of the incidence of ophthalmia neonatorum in this study, for the following reason.

By convention, ophthalmia neonatorum is defined as conjunctivitis arising within 1 month after birth. Hence, some of these conjunctival infections could originate from sources other than the maternal vaginal and cervical flora. In fact, some cases of ophthalmia neonatorum, especially those caused by *Staphylococcus aureus*, could have originated at home, as previously reported by the authors themselves. In the same study, no significant difference in the frequency or type of infection was seen among the infants delivered vaginally or by caesarean section.²

Other authors, too have made similar observations. Krohn *et al.*³ have found some cases of ophthalmia neonatorum to have been acquired from the infants' nasopharyngeal passages or from their care givers after birth. Verma *et al.*⁴ in a prospective study from India, found no correlation between the microbiology of the conjunctival swabs of the infected eyes (*Staph aureus* was the commonest isolate) and the vaginal and cervical swabs of the mothers (*Escherichia coli* was the commonest isolate). They concluded that most of the cases of ophthalmia neonatorum were acquired postnatally. In the light of these previously reported studies, I feel that exclusion of cases that were delivered by caesarean section was not warranted and weakens the power of this study. The efficacy of the second drop of povidone-iodine was not tested on a significant proportion of the cases of ophthalmia neonatorum (those cases affecting the babies delivered by caesarean section).

(2) It would be relevant to note the percentage of ophthalmia neonatorum cases with neonatal dacryocystitis due to congenital nasolacrimal duct obstruction in this series. Such cases obviously would not have

benefited from a second drop of povidone-iodine.

(3) The Indian study by Verma *et al.*⁴ found a seasonal incidence of ophthalmia neonatorum with two peaks: in February and May–June, in most probability as a result of the monsoon and the hot tropical climate with the attendant eye seeking flies. It would be interesting to know whether any such seasonal variation was noted in this study, which was carried out in Kenya, a country with a hot tropical climate, like India. If so, the efficacy of the second drop could be investigated again during such peaks.

V Vedantham

Correspondence to: Vasumathy Vedantham, Retina-Vitreous Service, Aravind Eye Hospital and Postgraduate Institute of Ophthalmology, 1 Anna Nagar, Madurai - 625 020, Tamilnadu, India; drvasumathy@yahoo.com

doi: 10.1136/bjo.2004.042846

Accepted for publication 22 January 2004

References

- 1 **Isenberg SJ**, Apt L, Signore MD, *et al.* A double application approach to ophthalmia neonatorum prophylaxis. *Br J Ophthalmol* 2003;**87**:1449–52.
- 2 **Isenberg SJ**, Apt L, Wood M. A controlled trial of povidone-iodine as prophylaxis against ophthalmia neonatorum. *N Engl J Med* 1995;**332**:562–6.
- 3 **Krohn MA**, Hillier SL, Bell TA, *et al.* The bacterial etiology of conjunctivitis in early infancy. *Am J Epidemiol* 1993;**138**:326–32.
- 4 **Verma M**, Chhatwal J, Varghese PV. Neonatal conjunctivitis: a profile. *Indian Pediatr* 1994;**31**:1357–61.

Authors' reply

We greatly appreciate the inquiry of Dr Vedantham and are happy to reply to his questions.

While he is correct regarding the definition of ophthalmia neonatorum including all infections acquired by an infant during the first 30 days of life, for the purposes of our study,¹ we were primarily interested in those cases resulting from neonatal exposure in the birth canal. This source of ophthalmia neonatorum is the one that would be influenced mainly by a second drop of povidone-iodine placed later on the day of birth. Infections postnatally that Dr Vedantham listed as arising, while technically still within the definition of "ophthalmia neonatorum," would not be impacted by this second drop and therefore would not be directly affected by this study. Indeed, Dr Vedantham's interest in neonatal dacryocystitis would also fall within the same question since the reflux from the tear duct causing this infection generally does not arise until well after the first day of life.

The proportion of ophthalmia neonatorum cases acquired postnatally compared with those acquired during the birth process probably differs by country. The difference in predominant causative organisms (*Staphylococcus aureus* and *Enterococcus* in the former situation as in India² v chlamydia and gonococcus in the latter) probably reflects the origin of the infection. Historically, in Kenya a high proportion of the infections probably arose from the birth process as reflected in the type of infecting organism. Thus, our Kenyan study, was primarily directed towards those infections acquired during birth.

The fact that ophthalmia neonatorum in some countries seems to peak in certain seasons and not in others should cause increased vigilance for this disorder in those countries. Our study, however, encompassed more than one full year of births in Kikuyu, Kenya. Therefore, the study included both the peaks and troughs of the incidence of ophthalmia neonatorum.

We thank Dr Vedantham for his interest and hope that in many countries, including India, ophthalmia neonatorum prophylaxis will either continue unabated or be initiated preferentially with the use of povidone-iodine.

S J Isenberg, L Apt

UCLA School of Medicine, Harbor-UCLA Medical Center, 1000 W Carson Street, Box 6, Torrance, CA 90509, USA

Correspondence to: S J Isenberg, UCLA School of Medicine, Harbor-UCLA Medical Center, 1000 W Carson Street, Box 6, Torrance, CA 90509, USA; isenberg@ucla.edu

doi: 10.1136/bjo.2004.045096

Accepted for publication 19 February 2004

References

- 1 **Isenberg SJ**, Apt L, Del Signore M, *et al.* A double application approach to ophthalmia neonatorum prophylaxis. *Br J Ophthalmol* 2003;**87**:1449–52.
- 2 **Verma M**, Chhatwal J, Varghese PV. Neonatal conjunctivitis: a profile. *Indian Pediatr* 1994;**31**:1357–61.

Retinectomy for intractable glaucoma

We read with interest the article by Joussem *et al* on the long term results of retinectomy for the treatment of intractable glaucoma.¹ We congratulate the authors for studying this innovative method for the management of refractory glaucoma with a long follow up of 5 years.

The high incidence of complications in the study, however, has aroused our concern as only 15.9% of patients completed the study uneventfully. Further vitreoretinal surgeries were required in 47.7% because of retinal complications. Moreover, the incidence of hypotony, phthisis, and enucleation was 25%, 20%, and 16% respectively and these figures are higher compared with other treatments such as glaucoma implants and cyclodiode. We have previously studied the use of the Ahmed valve implant for complicated glaucoma and hypotony, phthisis, and enucleation occurred in 10.8%, 3.1%, and 1.5%, respectively.² A recent study on the management of refractory glaucoma by cyclodiode similarly found a lower rate of hypotony and phthisis of 9.5% and 5.3% respectively.³ The high complication rates in the study by Joussem *et al* may be because of the negative case selection with a high incidence of aphakic (30%) and infantile and juvenile glaucoma (7%). A further controlled study comparing retinectomy with other treatments may therefore be warranted.

In this evidence based era, emphasis should be placed on outcomes which are "patient oriented evidence that matters" (POEMs).⁴ It was stated by the authors that the main intentions of the surgery were to relieve pain and to preserve the eye without discomfort. Unfortunately, these POEMs were not included in the final outcome measures. Instead, success was determined

by "disease oriented evidence" (DOE) like intraocular pressure and retinal attachment, which are surrogate outcomes.⁵ These DOEs may not correlate well with the patients' symptoms and it would be valuable if the authors can include the level of pain and discomfort as other outcome measures for the study.

V W Y Wong, T Y Y Lai, D S C Lam
Hong Kong Eye Hospital, 147K Argyle Street,
Kowloon, Hong Kong

Correspondence to: Dr Timothy Y Y Lai, Hong Kong Eye Hospital, 147K Argyle Street, Kowloon, Hong Kong; tyylai@netvigator.com

doi: 10.1136/bjo.2004.042820

Accepted for publication 22 January 2004

References

- 1 **Jousen AM**, Walter P, Jonescu-Cuyper CP, *et al*. Retinectomy for treatment of intractable glaucoma: long term results. *Br J Ophthalmol* 2003;**87**:1094–103.
- 2 **Lai JS**, Poon AS, Chua JK, *et al*. Efficacy and safety of the Ahmed glaucoma valve implant in Chinese eyes with complicated glaucoma. *Br J Ophthalmol* 2000;**84**:718–21.
- 3 **Murphy CC**, Burnett CA, Spry PG, *et al*. A two centre study of the dose-response relation for transscleral diode laser cyclophotocoagulation in refractory glaucoma. *Br J Ophthalmol* 2003;**87**:1252–7.
- 4 **Shaughnessy AF**, Slawson DC, Bennett JH. Becoming an information master: a guidebook to the medical information jungle. *J Fam Pract* 1994;**39**:489–99.
- 5 **Temple R**. Are surrogate markers adequate to assess cardiovascular disease drugs? *JAMA* 1999;**282**:790–5.

Blue light and the circadian clock

Drs Mainster and Sparrow have provided an excellent perspective on the relative merits and difficulties of extending intraocular lens (IOL) absorption into the blue portion of the spectrum.¹

However, they have not considered an unintentional consequence of blockage of the blue portion of the spectrum—reducing the activity of intrinsically photosensitive retinal ganglion cells.^{2–3} These cells subserve several non-visual ocular photoreceptive tasks, most prominently the entrainment of the circadian clock to external light-dark cycles.⁴ Pupillary light responses in mice are also at least partially controlled by this system, which appears to use a novel opsin (melanopsin)^{5–6} and possibly also a flavoprotein (cryptochrome)^{7–8} as photopigments.

Experiments in mice have suggested that the action spectrum for these photopigments peak in the blue, at approximately 480 nm, but with substantial sensitivity to blue light to 430 nm.⁹ This system appears to be functional in humans as documented by the action spectrum for light suppression of the pineal hormone, melatonin.^{10–11}

The clinical importance of these photoreceptors is presently unknown, although it appears that loss of retinal ganglion cells predisposes children and young adults to disorders of sleep timing that outer retinal disease does not.¹² While, as the authors note, there may be substantial benefit in blocking blue light phototoxicity, particularly for patients with pre-existing outer retinal degeneration, these lenses may have unintended consequences with respect to the

timing of sleep and wakefulness or levels of certain neurohormones.

R N Van Gelder

Washington University Medical School, Campus Box 8096, 660 S Euclid Avenue, St Louis, MO 63110, USA; vangelder@vision.wustl.edu

doi: 10.1136/bjo.2004.042861

Accepted for publication 22 January 2004

References

- 1 **Mainster MA**, Sparrow JR. How much blue light should an IOL transmit? *Br J Ophthalmol* 2003;**87**:1523–9.
- 2 **Berson DM**. Strange vision: ganglion cells as circadian photoreceptors. *Trends Neurosci* 2003;**26**:314–20.
- 3 **Berson DM**, Dunn FA, Takao M. Phototransduction by retinal ganglion cells that set the circadian clock. *Science* 2002;**295**:1070–3.
- 4 **Freedman MS**, Lucas RJ, Soni B, *et al*. Regulation of mammalian circadian behavior by non-rod, non-cone, ocular photoreceptors. *Science* 1999;**284**:502–4.
- 5 **Panda S**, Provencio I, Tu DC, *et al*. Melanopsin is required for non-image-forming photic responses in blind mice. *Science* 2003;**301**:525–7.
- 6 **Hattar S**, Lucas RJ, Mrosovsky N, *et al*. Melanopsin and rod-cone photoreceptive systems account for all major accessory visual functions in mice. *Nature* 2003;**424**:75–81.
- 7 **Van Gelder RN**, Wee R, Lee JA, *et al*. Reduced pupillary light responses in mice lacking cryptochromes. *Science* 2003;**299**:222.
- 8 **Selby CP**, Thompson C, Schmitz TM, *et al*. Functional redundancy of cryptochromes and classical photoreceptors for nonvisual ocular photoreception in mice. *Proc Natl Acad Sci USA* 2000;**97**:14697–702.
- 9 **Lucas RJ**, Douglas RH, Foster RG. Characterization of an ocular photopigment capable of driving pupillary constriction in mice. *Nat Neurosci* 2001;**4**:621–6.
- 10 **Brainard GC**, Hanifin JP, Greeson JM, *et al*. Action spectrum for melatonin regulation in humans: evidence for a novel circadian photoreceptor. *J Neurosci* 2001;**21**:6405–12.
- 11 **Thapan K**, Arendt J, Skene DJ. An action spectrum for melatonin suppression: evidence for a novel non-rod, non-cone photoreceptor system in humans. *J Physiol (Lond)* 2001;**535**:261–7.
- 12 **Wee R**, Van Gelder RN. Sleep disturbances in young subjects with visual dysfunction. *Ophthalmology* (in press).

Author's reply

I appreciate Van Gelder's thoughtful comments regarding the potential consequences of a ultraviolet + blue light absorbing intraocular lens (IOL) on circadian rhythmicity. I agree that the clinical importance of retinal ganglion photoreceptors is currently unknown and that decreasing the amount of blue light reaching them might affect their function. Conversely, if photosensitive ganglia respond to circadian changes in their blue light exposure rather than just the magnitude of that exposure, a ultraviolet + blue light absorbing IOL may not impair ganglion function.

Van Gelder re-emphasises our finding that IOL chromophore selection balances the potential loss of useful visual function against a reduction in the risk of acute ultraviolet-blue phototoxicity. Our paper did not state, however, that ultraviolet + blue absorbing IOLs were desirable for people with outer retinal degeneration. Indeed, blue light is more important in scotopic than photopic vision. Individuals with age related macular degeneration have greater night-time visual problems than their peers without it, and these scotopic problems may be exacerbated

if a significant amount of blue light is blocked by an IOL.

M A Mainster

University of Kansas Medical School, 3901 Rainbow Boulevard, MS3009, Kansas City, KS 66160-7379, USA; mmainste@kumc.edu

doi: 10.1136/bjo.2004.045120

Accepted for publication 19 February 2004

Modification of classification of ocular chemical injuries

A recent paper by Kobayashi and co-workers¹ on temporary amniotic membrane patching for acute chemical burns highlights the difficulty in the consistent classification of this type of injury.

Roper-Hall's classification of acute chemical injuries to the eye is based on the original classification of Ballen^{2–3} and there is little difference between them. However, in neither classification is the grade based on the most severe sign. This immediately leads to the problem of trying to classify an eye having, for example, corneal signs of one grade and conjunctival signs of another. There is also difficulty in grading the conjunctival and limbal injuries.

Dua *et al*¹ recognised the problem of assessing limbal stem cell damage and proposed a quasi-analogue scale in order to incorporate intergrade variations. They suggested using limbal fluorescein staining as a marker of limbal stem cell damage. However, their grading scheme is complex and departs significantly from that of Roper-Hall. Although fluorescein staining is a useful sign, it does not necessarily imply limbal stem cell damage or failure and has not been shown to be a better index of limbal damage than perilimbal ischaemia. Importantly, it is also becoming apparent, that both the fornices and mucocutaneous junction of the conjunctiva are important for conjunctival regeneration.^{5–7} In fact, Roper Hall stressed the importance of involvement of contiguous areas of the conjunctiva, which may lead to symblepharon formation.⁴

Although there are limitations with Roper-Hall's classification, it is simple and remains popular. Rather than replace Roper-Hall's and Ballen's classification,^{2–3} we suggest a modification, which addresses some of the issues raised and makes the classification more robust.

One of the questions that needs to be answered is whether to base the grade of injury upon the most severe sign or on a combination of ocular surface signs. A combination of signs using three parameters (cornea, limbus, and conjunctiva), each with three levels requires 27 possible combinations to avoid crossover. To avoid this complexity and without evidence to indicate a difference in prognosis, it would seem reasonable therefore to base the grade of injury on the most severe sign.

Although limbal ischaemia does not necessarily imply limbal stem cell failure, it remains to be shown that it is less indicative than fluorescein limbal staining of limbal damage. We propose therefore to continue to use limbal ischaemia in the grading of injury.

With regard to conjunctival involvement, in order to be able to include the total area of involvement, we suggest dividing the conjunctival surface into bulbar and tarsal areas, as is natural. The bulbar and tarsal conjunctiva comprise approximately two thirds and

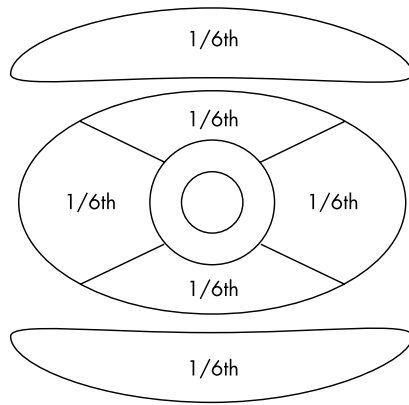


Figure 1 Estimation of conjunctival injury. For example, $1/6\text{th} + 1/6\text{th} = 1/3\text{rd}$.

one third of the total conjunctival surface respectively. Using conjunctival fluorescein staining as an indicator of the extent of conjunctival damage, the area of involvement can be based on the fraction of the third involved, limiting any division into not less than sixths—that is, the tarsal surfaces together comprise a third of conjunctiva (see fig 1). This includes the issue that a vertical distribution of conjunctival injury is as important as a horizontal distribution.

Corneal involvement in terms of prognosis remains an area of difficulty. Although it may be assumed that limbal and conjunctival damage implies a worse prognosis than isolated corneal damage, this has yet to be shown. In addition, a severe chemical injury involving the cornea but not the limbus, or vice versa, would be expected to be an uncommon event. We therefore propose to retain the degree of corneal damage (as proposed by Roper-Hall² and Ballen³) in grading of the injury (see table 1).

Thus, grade I is identified by any isolated corneal epithelial injury. Grade II includes limbal or conjunctival involvement, but involves less than one third of the area involved. Grade III includes either a hazy cornea, defined as obscurity of the iris or pupil details (as per Roper-Hall's and Ballen's original descriptions), and/or greater than one third of limbal or conjunctival damage. With the advent of recent surgical techniques such as amniotic membrane transplants and limbal allografts, the prognosis of more severe ocular chemical injuries previously classified as Roper-Hall grade IV have improved and no longer carry a uniformly poor prognosis.² Therefore, we reason that these cases can be included in grade III of our proposed classification.

In conclusion, in the absence of good evidence for re-classifying ocular surface injuries, it would seem reasonable to keep

to the Roper-Hall/Ballen classification and to move it forward by addressing the weaknesses of that system. We hope that the proposed grading system improves the consistency with which chemical injuries are reported in the literature, serves as a basis for controlled comparative evaluation of modern treatment, and stimulates further work in this area.

S Harun, S Srinivasan, K Hollingworth, M Batterbury, S Kaye

8z Link, Royal Liverpool University Hospital, Prescott Street, Liverpool L7 8XP, UK

Correspondence to: Mr Shabbir Harun, 8z Link, Royal Liverpool University Hospital, Prescott Street, Liverpool L7 8XP, UK; harun@doctors.org.uk

doi: 10.1136/bjo.2004.046797

Accepted 15 March 2004

References

- 1 Kobayashi A, Shirao Y, Yoshita T, *et al*. Temporary amniotic membrane patching for acute chemical burns. *Eye* 2003;**17**:149–58.
- 2 Roper-Hall MJ. Thermal and chemical burns. *Trans Ophthalmol Soc UK* 1965;**85**:631–53.
- 3 Ballen PH. Hemstead NY. Treatment of chemical burns of the eye. *Eye, Ear, Nose and Throat Monthly* 1964;**43**:57–61.
- 4 Dua HS, King AJ, Joseph A. A new classification of ocular surface burns. *Br J Ophthalmol* 2001;**85**:1379–83.
- 5 Wirtschafter JD, Ketcham JM, Weinstock RJ, *et al*. Mucocutaneous junction as the major source of replacement palpebral conjunctival epithelial cells. *Invest Ophthalmol Vis Sci* 1999;**40**:3138–46.
- 6 Wei ZG, Wu RL, Lavkar RM, *et al*. In vitro growth and differentiation of rabbit bulbar, fornix and palpebral conjunctival epithelia. Implications on conjunctival epithelial transdifferentiation and stem cells. *Invest Ophthalmol Vis Sci* 1993;**34**:1814–28.
- 7 Brodovsky SC, McCarty CA, Snibson G, *et al*. Management of alkali burns: an 11 year retrospective review. *Ophthalmology* 2000;**107**:1829–35.

Author's response

The response by Harun *et al* is to be commended in so far as it highlights the problems with the current Roper-Hall classification system and the difficulties it poses in evaluating outcome and efficacy of treatments in ocular surface burns. As a proposed modification, however, it is a retrograde step.

The three major issues with the Roper-Hall¹ classification were that it lumped all injuries with 50% or more of limbal involvement into one category, did not take into account conjunctival involvement in the actual classification, and placed undue emphasis on the degree of corneal haze.

The proposed modification by Harun *et al* goes a step backwards by grouping all injuries with more than 33% limbal involvement into

one category. The grading of a patient with all 12 clock hours of limbus involvement would then be the same as one with just over 3 clock hours of limbus involvement! The prognosis given to these two patients cannot be the same, given that the Roper-Hall and the Dua, King, and Joseph² classifications are prognostic classifications. Furthermore, a patient presenting with less than one third limbus involvement does not necessarily come with less than one third conjunctival involvement, which could be much more. The proposed modification does not allow for such variances, which are frequent. The Dua, King, and Joseph classification has the flexibility to allow for such variables and also to progressively document change both improvement and deterioration, over the acute phase of the injury. The authors rightly point out that the degree of ischaemia does not always correspond to degree of limbal involvement. Yet limbal involvement without ischaemia, in the form of loss of stem cells, can have an equally important impact on prognosis. That is precisely why the Dua, King, and Joseph classification considers limbal involvement (to encompass ischaemia as well) rather than limbal ischaemia alone.

The point about conjunctival involvement is well made in the proposed modification. This does not differ significantly from the Dua, King, and Joseph classification. The latter was the first to take this aspect of burns into account in determining severity and prognosis. The authors mention the importance of tarsal conjunctival involvement. This is a valid though often an impractical consideration. Associated swelling, induration, thickening, shrinkage and the like, of the lids make tarsal conjunctival evaluation impractical if not impossible in some cases, in the immediate post-injury period. It was for this practical consideration that the Dua, King, and Joseph classification included only the extent of bulbar conjunctival involvement in determining the grade. It is interesting to note that the authors disregard limbal fluorescein staining as an indicator of limbal damage (as proposed in the Dua, King, and Joseph classification) but propose fluorescein staining as an indicator of conjunctival damage in evaluating extent of conjunctival damage. This implies that fluorescein staining is appropriate to evaluate both conjunctival epithelial damage and conjunctival ischaemia but not limbal epithelial damage and limbal ischaemia. There is no rationale for this.

Corneal haze can be an indicator of the offending chemical rather than the severity of the insult. It is not uncommon to find a clear and transparent cornea, which is totally denuded of its epithelium, immediately after a chemical injury. This can stay so for a few days before becoming rapidly hazy or opaque, or remain clear and become re-epithelialised. Corneal endothelial damage leading to stromal oedema and haze can occur later in the course of an acute chemical injury. Conversely, a hazy cornea with a resultant scar could do well following a corneal graft procedure if the limbal involvement is minimal. The proposed modification retains corneal haze as a grading parameter and includes a hazy cornea in grade 3 only. There are many chemical injuries, which involve 3–6 clock hours of the limbus (30–50%) with a clear cornea. These do not fall well in any grade in the proposed new classification and highlight the inherent

Table 1 Modified classification of ocular chemical injuries

Grade	Cornea	Limbal ischaemia	Conjunctival involvement	Prognosis
I	Clear: epithelial damage only	None	None	Good
II	Clear: epithelial damage only	<1/3	<1/3	Good
III	Hazy cornea	OR >1/3	OR >1/3	Guarded

problem in the Roper-Hall classification and its proposed modification.

Most important of all, the proposed classification is purely theoretical and has not been validated. The Dua, King, and Joseph classification is based on several years of clinical experience of managing burns including more than 67 patients. It is simple and easy to use (clock hours of limbus involvement and percentage of conjunctival involvement), flexible, and allows for all combinations of different extents of involvement of the two structures. It is validated as a prognostic indicator and allows for accurate comparison of cases. The proposed new classification/modification fails on all these counts.

H S Dua

Division of Ophthalmology and Visual Sciences, B Floor, Eye ENT Centre, University Hospital, Queens Medical Centre, Derby Road, Nottingham NG7 2UH, UK; harminder.dua@nottingham.ac.uk

doi: 10.1136/bjo.2004.046797

Accepted 23 March 2004



Further communications regarding this subject can be found at eLetters on the BJO website (www.bjophthalmol.com)

References

- 1 Roper-Hall MJ. Thermal and chemical burns. *Trans Ophthalmol Soc UK* 1965;**85**:631-53.
- 2 Dua HS, King AJ, Joseph A. New classification of ocular surface burns. *Br J Ophthalmol* 2001;**85**:1379-83.

BOOK REVIEW

Complications in Ophthalmic Plastic Surgery

Ed by B G Brazzo. Pp 264; £130.50 (€169.95). New York: Springer Verlag, 2003. ISBN 0-387-00283-9.

There is no doubt that complications in surgery are an inevitable fact.

Nevertheless, the unforeseen surgical outcomes always play a fundamental part in the self improving process. Certainly, the experience provides the safest way, for both the patient and the surgeon, to prevent harm and smooth the final result.

This book represents one of the most serious, and not very common, works focusing on the complications in ophthalmic plastic surgery. It is a considerably well organised book, which apparently requires some basic knowledge of oculoplastics and facial aesthetic surgery. The format is based on three distinguished parts: cosmetic surgery, ptosis, and lower eyelid malposition. A

very competent number of contributors cover the topics of their specific interest. In the first part the authors are dealing with the blepharoplasties, the laser resurfacing, and the forehead lift. The ptosis chapter is referred to the most common ptosis techniques but brow suspension is remarkably absent. The third part, although it is entitled "Lower eyelid malposition," includes and some unrelated, though welcomed topics, like DCR, enucleation, and orbital fractures.

The necessity of the communication between the surgeon and the patient is vigorously emphasised and didactically analysed in every single chapter. Deep understanding of the patient's expectations as well as detailed information about the pragmatic results is recommended throughout the chapters of the book. There is quite a sufficient reference to preoperative evaluation of the patient regarding measurements, anaesthesia, and surgical preparation.

Although the covered operations are extensively described, a countable number of other surgical techniques, and their possible complications, are not mentioned. The latter is probably related to the editor's orientation to aesthetic oculoplastic surgery.

The anatomical and pathophysiological mechanisms of the most common complications are thoroughly explained. At the same time, the authors give many enlightening tips, based on their broad experience, for preventing the problems, and meticulously describe the management of the intraoperative and postoperative complications. The number of the illustrations do not adequately correspond to the addressed complications and the quality of the pictures varies, depending on the author's collection. Additionally, the shortage of references in some of the most interesting chapters (ptosis, enucleation) should certainly not be overlooked, for the magnitude of such a book.

Every attempt to give precious advice about the frustrating and unavoidable surgical complications is always warmly welcomed. Brian Brazzo's book is predominately a useful guide to the understanding, prevention, and management of the commonest problems in oculoplastic surgery. Despite the expected problems of every first edition this generally represents a meticulous work on specific issues and thus is recommended for the ophthalmic surgeon and especially for surgeons who are chiefly interested in oculoplastics and cosmetic surgery.

N Chalvatzis

Bristol Eye Hospital, Lower Maudlin Street, Bristol BS1 2LX, UK; nikocha@hotmail.com

CORRECTION

In the letter titled Sequential treatment of central retinal vein occlusion with intravitreal

tissue plasminogen activator and intravitreal triamcinolone (*Br J Ophthalmol* 2004;**88**:1100-1101) the authors were listed incorrectly. The correct listing is as follows: J M Lahey, J J Kearney, M C Cheung. The journal apologises for this error.

It has come to our attention that, owing to a production error, the letter by N Islam, K Mireskandari, and G E Rose has been published twice, in the June issue (*Br J Ophthalmol* 2004;**88**:833-834) and the August issue (*Br J Ophthalmol* 2004;**88**:1092-1093). The initial publication in the June issue should be taken as the article of record. We apologise to the authors and readers for any confusion this accidental duplicate publication may have caused.

NOTICES

Childhood cataract

The latest issue of Community Eye Health (No 50) deals with the manitude, management, economics and impact of childhood cataract. For further information please contact: Journal of Community Eye Health, International Resource Centre, International Centre for Eye Health, Department of Infectious and Tropical Diseases, London School of Hygiene and Tropical Medicine, Keppel Street, London WC1E 7HT, UK (tel: +44 (0)20 7612 7964; email: Anita.Shah@lshtm.ac.uk; online edition: www.jceh.co.uk). Annual subscription (4 issues) UK £28/US\$45. Free to developing country applicants.

Ophthalmic Anesthesia Society

The 18th annual meeting of the Ophthalmic Anesthesia Society will be held on 1-3 October 2004 in Chicago, USA. For further details: Ophthalmic Anesthesia Society (OAS), 793-A Foothill Blvd, PMB #119, San Luis Obispo, CA 93405, USA (tel: 001 805 534 0300; fax: 001 805 534 9030; email: info@eyeanesthesia.org; website: www.eyeanesthesia.org).

4th International Congress on Autoimmunity

The 4th International Congress on Autoimmunity will take place 3-7 November 2004 in Budapest, Hungary. Further details: Kenes International Global Congress Organisers and Association Management Services, 17 Rue du Cendrier, PO Box 1726, CH-1211 Geneva 1, Switzerland (tel: +41 22 908 0488; fax: +41 22 732 2850; email: autoim04@kenes.com; website: www.kenes.com/autoim2004).