

# PostScript

## LETTERS

If you have a burning desire to respond to a paper published in the *BJO*, why not make use of our "rapid response" option?

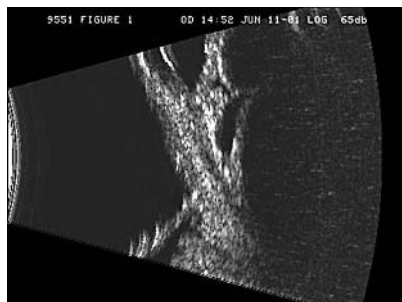
Log on to our website ([www.bjophthalmol.com](http://www.bjophthalmol.com)), find the paper that interests you, and send your response via email by clicking on the "eletters" option in the box at the top right hand corner.

Providing it isn't libellous or obscene, it will be posted within seven days. You can retrieve it by clicking on "read eletters" on our homepage.

The editors will decide as before whether to also publish it in a future paper issue.

### Echographic features of a case of malignant intraocular medulloepithelioma

Intraocular medulloepithelioma is a rare embryonal neoplasm, usually presenting in the first decade of life as a unilateral, cystic ciliary body mass arising from the non-pigmented ciliary epithelium. Histologically, medulloepithelioma is classified as non-teratoid (a pure proliferation of medullary



**Figure 1** High resolution scan showing moderately reflective opacity at the pars plana, extending along a thickened looking anterior hyaloid face to the posterior lens. No ciliary body mass present.

epithelial cells) or teratoid (containing heteroplastic elements such as hyaline cartilage, skeletal muscle or neuroglial tissue).<sup>1-3</sup> Either group can be subclassified as benign or malignant, the latter showing evidence of poor differentiation, increased mitotic activity, and local invasion with or without extraocular extension.<sup>2</sup>

We report the progressive echographic findings in a case of malignant intraocular medulloepithelioma. Echographic examination, by B-scan (10 MHz probe) and high resolution anterior segment scan (20 MHz probe), was performed during two examinations under anaesthesia (EUA), using the I3 system.

#### Case report

An 18 month old girl presented with a distorted pupil apparently following a fall downstairs some 4 weeks previously. Her right pupil was displaced inferotemporally, with a localised area of ectropion uveae and underlying segmental lens opacity.

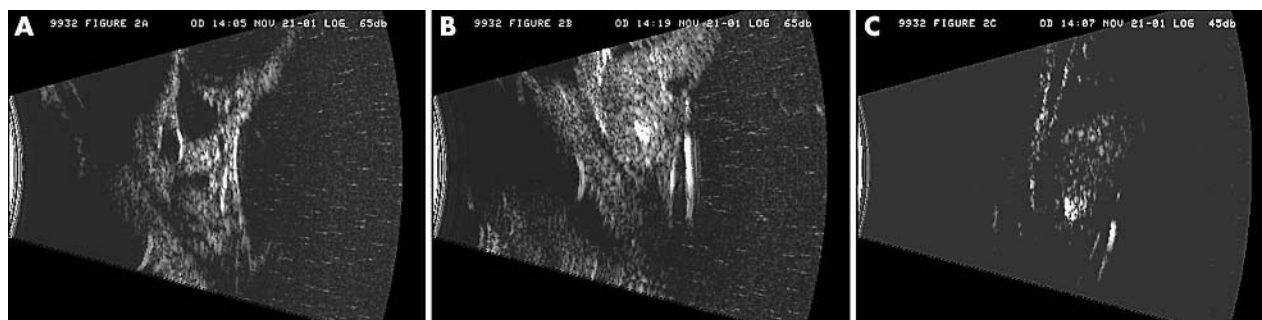
An urgent EUA confirmed the clinical findings. The retina and ora serrata were normal on funduscopy but there was the vague suggestion of a subtle whitish pars plana abnormality inferotemporally. Visualisation of this area was however hampered by the lens opacity. B-scan was normal but high resolution scan showed an inferotemporal peripupillary iris cyst with irregular thickening of the peripheral iris. The ciliary body appeared normal but a triangular opacity of moderate reflectivity arose from the inferotemporal pars plana and extended along a thickened anterior hyaloid face (fig 1). In the absence of a definite mass the tissue changes were thought possibly to be secondary to trauma, perhaps of a penetrating nature. It was decided to manage her conservatively with an initial period of observation and occlusion therapy.

Unfortunately, she was lost to follow up and re-presented 4 months later with a right mature cataract. A repeat EUA was performed and B-scan now showed a partial posterior vitreous detachment with cellular vitreous. High resolution scan showed extensive increased irregular echoes of variable reflectivity extending from the pars plana to the ciliary body and along the anterior hyaloid face to the posterior lens. Small

echolucent areas were present as well as one area of hyper-reflectivity inferotemporally. Although there was no absolute shadowing posterior to this hyper-reflective area, it remained highly reflective at low gain suggesting possible cartilage (fig 2A-C). Lens aspiration was performed revealing a dense, vascularised cyclitic membrane and underlying white fibrous tissue circumferentially around the pars plana and ciliary body though no distinct mass. Inferotemporally this structure was cystic with an area of hard chalky tissue, corresponding to the bright echo on scan, which was again thought probably to represent cartilage. A diagnosis of possible medulloepithelioma was made and confirmed on subsequent histological examination of tissue biopsies and vitreous cytology. Unfortunately, during surgery she developed an inferotemporal retinal dialysis requiring vitrectomy and inevitably some retrolenticular tissue was lost to further histological analysis during this procedure. Subsequent enucleation and extensive histological examination of the globe confirmed the diagnosis of malignant medulloepithelioma, although no heterologous elements could be identified in the available tissue.

#### Comment

Limited information exists regarding the echographic features of medulloepithelioma.<sup>1-5</sup> We had the rare opportunity of examining a case of malignant medulloepithelioma by B-scan and high resolution scan at both early and later stages of development, showing significant progression of the condition. Our case presented with a pupil abnormality, localised segmental cataract and probable early cyclitic membrane arising from the pars plana but not with a typical ciliary body mass. Development of a cyclitic membrane is a recognised feature associated with medulloepithelioma.<sup>1-6</sup> We have demonstrated the value of high resolution echography in such cases particularly demonstrating early changes when little was clinically evident. Our case demonstrates that, even in the absence of a ciliary body mass, the suggestion of early or unusual retrolenticular membrane should alert one to the possible diagnosis of intraocular medulloepithelioma.



**Figure 2** High resolution scan now showing increased echoes of variable reflectivity from pars plana to ciliary body and posterior lens. Cystic structure with echolucent areas temporally (A). Very highly reflective echo inferotemporal pars plana (B). Although only very slight posterior shadowing, hyper-reflective echo persists at low gain (C), suggesting possible cartilage.

R I Owen, P A C Tiffin, D H W Steel

Sunderland Eye Infirmary, Queen Alexandra Road,  
Sunderland SR2 9HP, UK

Correspondence to: Rona I Owen, Sunderland Eye  
Infirmary, Queen Alexandra Road, Sunderland SR2  
9HP, UK; ronaowen@msn.com

doi: 10.1136/bjo.2004.045203

Accepted for publication 19 May 2004

## References

- 1 Shields JA, Eagle RC Jr, Shields CL, et al. Congenital neoplasms of the non-pigmented ciliary epithelium (medulloepithelioma). *Ophthalmology* 1996;103:1998-2006.
- 2 Broughton WL, Zimmerman LE. A clinicopathologic study of 56 cases of medulloepithelioma. *Am J Ophthalmol* 1978;85:407-18.
- 3 Orellana J, Moura RA, Font RL, et al. Medulloepithelioma diagnosed by ultrasound and vitreous aspirate. *Ophthalmology* 1983;90:1531-8.
- 4 Shields JA, Eagle RC, Shields CL, et al. Fluorescein angiography and ultrasonography of malignant intraocular medulloepithelioma. *J Paediatr Ophthalmol Strabismus* 1996;33:193-6.
- 5 Foster RE, Murray TG, Byrne SF, et al. echographic features of medulloepithelioma. *Am J Ophthalmol* 2000;103:364-6.
- 6 Shields JA, Eagle RC, Shields CL, et al. Pigmented medulloepithelioma of the ciliary body. *Arch Ophthalmol*, 2002;120:207-9.

## Drug induced autoenucleation with resultant chiasmal damage

Self enucleation or "oedipism"<sup>1</sup> is a rare form of self mutilation, occurring with paranoid delusions, either as a result of a drug related toxic psychosis or in functional psychoses, such as schizophrenia. It is most often described in acutely psychotic patients, who have religious or sexual delusions.<sup>2</sup>

We report a case of self enucleation of a right eye in a 19 year old male—induced by drug psychosis. The force of autoenucleation traumatised the chiasm resulting in a left temporal field defect. Only two cases of contralateral field defect secondary to chiasmal damage have been reported in the literature.<sup>3,4</sup> Many drugs are known to cause hallucination leading to self mutilation.

Deliberate self harm (DSH)<sup>5</sup> is a well known entity which varies from mild (skin picking and hair pulling) to severe forms of self mutilation like self amputation and self enucleation.<sup>5</sup> DSH is known to result from delusions and command hallucinations occurring in psychotic and mood disorders, dementia, personality disorder, drug misuse, and mental retardation. In adults, attempts at ocular damage are associated with acute psychosis, self enucleation being the extreme form of ocular mutilation.

## Case report

A 19 year old man was admitted following attempted enucleation of his right eye during an acute psychotic episode after taking ecstasy, LSD, and excess alcohol. He described, "seeing an army of police officers attacking him." He attempted to remove a "bomb" which had gone into his eye using a nail clipper and pliers. He was still in a state of psychosis running around aimlessly and

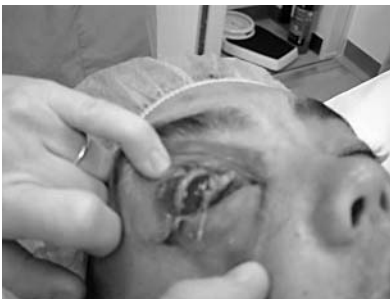

Figure 1 Total absence of globe.

had to be held to the ground by six people to prevent further self mutilation.

He was admitted to a general medical hospital in a state of psychosis and was treated with haloperidol. He had no known past psychiatric disorders. He is healthy, fit with no known past medical illness. Full blood count, urea and electrolytes, and blood gases were normal.

Toxicology of urine and blood were positive for amphetamine; no test for LSD was performed.

He was transferred to the Royal Victoria Eye and Ear Hospital on the same day in a stable condition. Ocular examination revealed no perception of light in his right eye with severely chemosed eyelids and the globe could not be visualised. Visual acuity in the left eye was 6/6 with normal anterior segment and fundus examination.

Exploration of the right socket under anaesthesia revealed no identifiable structures except for orbital fat, inferior rectus muscle, conjunctiva, and Tenon's capsule (fig 1). The optic nerve stump was not visible. A porous polyethylene orbital implant was inserted, the Tenon's and conjunctiva sutured over it in separate layers. Considering the instruments and force used to extract the eye, surprisingly there was no apparent loss of conjunctival tissue, leaving adequate fornices for a prosthesis, which was fitted 6 weeks later.

Goldmann visual field showed left upper temporal quadrantanopia to the I4e and I3e targets, and a left hemianopia to the I2e target (fig 2), indicating trauma to the chiasm. The patient has been advised not to drive at present. A magnetic resonance image showed no visible abnormality of the chiasm or left visual pathway. The patient is being closely monitored by the psychological team and is attending a drug rehabilitation clinic.

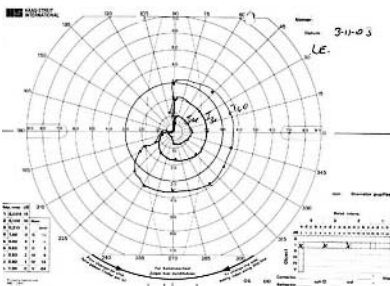


Figure 2 Goldmann field of the left eye.

## Comment

This report presents a rare case of a self enucleation of the right eye in a young man. This severe trauma resulted in loss of vision in the right eye and partial visual field loss in the other eye. Avulsion of the optic nerve was found in the right eye. The left eye showed no evidence of ischaemia or sympathetic ophthalmia. The visual field defect of the left eye resulted from traumatic severance of the right optic nerve causing secondary chiasmal damage. There were no intracranial complications.

Life threatening complications may result from self enucleation, including intracranial or subarachnoid haemorrhage, cerebrospinal fluid leakage, and bacterial meningitis.<sup>3</sup> Radiographic imaging is required to exclude intracranial bleeding, optic chiasmal injury, and bone fractures.

Self enucleation or "oedipism" is a rare entity which requires operative reconstruction of the orbit, and also neurological monitoring to identify and treat any possible intracranial complications. The other eye should be observed for possible sympathetic ophthalmia which may occur because of residual uveal tissue in the socket. Visual field of the remaining eye must be performed in the acute phase, as field loss secondary to chiasmal trauma or severance traumatic optic neuropathy may occur and may respond to intravenous steroids,<sup>4</sup> though this is controversial. Field loss will have implications with regard to driving and some occupations and may even require the patient to be registered as partially sighted.

Long term psychiatric therapy should be implemented to prevent further self injurious behaviour, as according to literature severe forms of self mutilation after self enucleation can occur.<sup>6</sup> This includes attempted suicide.

Though cases of severance optic neuropathy and chiasmal damage are rarely reported, this may be due to lack of symptomatology and failure to perform field testing. The importance of visual field analysis cannot be overemphasised, because of the potential implications for affected patients.

I Tuwir, E Chako, D Brosnahan, L Cassidy

Royal Victoria Eye and Ear Hospital, Dublin, Republic of Ireland

Correspondence to: Dr Ismail Tuwir, Royal Victoria  
Eye and Ear Hospital, Dublin, Republic of Ireland;  
tuwir@hotmail.com

doi: 10.1136/bjo.2004.049676

Accepted for publication 19 May 2004

## References

- 1 Bergua A, Sperling W, Kuchle M. Self-enucleation in drug-related psychosis. *Ophthalmologica* 2002;216:269-71.
- 2 Aung T, Yap EY, Fam HB, et al. Oedipism. *Aust N Z J Ophthalmol*, 1996;24:153-7.
- 3 Khan JA, Buescher L, Ide CH, et al. Medical management of self-enucleation. *Arch Ophthalmol* 1985;103:386-9.
- 4 Parmar B, Edmunds B, Plant G. Traumatic enucleation with chiasmal damage: magnetic resonance image findings and response to steroids. *Br J Ophthalmol* 2002;86:1317-18.
- 5 Koh KGWW, Yeo BKL. Self-enucleation in a young schizophrenic patient—a case report. *Singapore Med J* 2002;43:159-60.
- 6 Krauss R, Robert D. Review. Autoenucleation. *Surv Ophthalmol* 1984;29:179-87.

## Repeated intravitreal injection of triamcinolone acetonide for diffuse diabetic macular oedema

Recent studies have suggested that intravitreal triamcinolone acetonide may be a treatment option for diffuse diabetic macular oedema.<sup>1</sup> Since the duration of the effect of an intravitreal application of triamcinolone acetonide lasts between 4 weeks and up to 9 months,<sup>2,3</sup> the purpose of this study was to evaluate the effect of a repeated intravitreal injection of triamcinolone acetonide.

### Case reports

The clinical interventional case series study included four patients with diffuse diabetic macular oedema who consecutively received a second intravitreal injection of about 20 mg triamcinolone acetonide 7.6 (SD 3.9) months (median, 6.7 months; range, 4.1–13.1 months) after the first injection, and for whom follow up was longer than 3 months. The second injection was carried out, since visual acuity had decreased again after an initial increase following the first intravitreal injection. Mean follow up after the second injection was 5.6 (SD 4.2) months (median 5.6 months; range 1–10.5 months). Mean age of the patients was 62.0 (5.0) years (range 56.8–67.8 years; median 61.7 years), refractive error ranged between a mean of -0.75 (SD 1.19) dioptres and +2.50 (1.38) dioptres. All patients were fully informed about the experimental character of the therapy and had signed an informed consent. The ethics committee of the university had approved the study. All patients received an intravitreal injection of about 20 mg triamcinolone acetonide in 0.2 ml Ringer's solution as previously described in detail.<sup>4</sup>

After the first injection, visual acuity increased from 0.12 (SD 0.05) (range 0.08–0.20) to a maximum of 0.23 (SD 0.14) (range 0.10–0.40). Converting visual acuity measurements into the logarithm of the minimum angle of resolution (logMAR) showed a change in the minimum angle of resolution from 0.95 (SD 0.17) logMAR units to 0.71 (SD 0.29) logMAR units. After the second injection, visual acuity increased from 0.12 (SD 0.06) (range 0.08–0.20) to a mean maximal visual acuity of 0.18 (SD 0.06) (range 0.10–0.25). The minimum angle of resolution changed from 0.97 (SD 0.19) logMAR units to 0.77 (SD 0.17) logMAR units. All eyes increased in visual acuity. After the first injection, and after the second injection, respectively, intraocular pressure increased to values higher than 21 mm Hg in three eyes. For all of these eyes, intraocular pressure could be normalised by topical antiglaucomatous treatment.

### Comment

The data of this study may suggest that the repeated intravitreal injection of about 20 mg of triamcinolone acetonide as treatment of diffuse diabetic macular oedema can be associated with an increase in visual acuity again in those patients who as "triamcinolone responders" showed an improvement in visual acuity after a preceding intravitreal injection of triamcinolone acetonide. It is in agreement with a previous study on repeated intravitreal injections of triamcinolone acetonide for exudative age related macular degeneration.<sup>5</sup>

J B Jonas, I Kreissig, R F Degenring, B A Kamppeper

Department of Ophthalmology, Faculty of Clinical Medicine Mannheim of the University Heidelberg, Germany

Correspondence to: Dr J Jonas, Universitäts-Augenklinik, Theodor-Kutzer-Ufer 1-3, 68167 Mannheim, Germany; Jost.Jonas@ma.augen.uni-heidelberg.de

doi: 10.1136/bjo.2004.050575

Accepted for publication 19 May 2004

Proprietary interest: none.

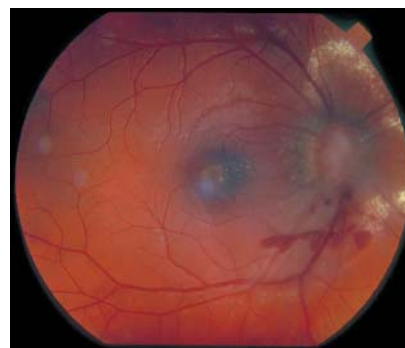### References

- 1 **Martidis A**, Duker JS, Greenberg PB, *et al*. Intravitreal triamcinolone for refractory diabetic macular edema. *Ophthalmology* 2002;**109**:920–7.
- 2 **Beer PM**, Bakri SJ, Singh RJ, *et al*. Intraocular concentration and pharmacokinetics of triamcinolone acetonide after a single intravitreal injection. *Ophthalmology* 2003;**110**:681–6.
- 3 **Jonas JB**, Degenring R, Kamppeper B, *et al*. Duration of the effect of intravitreal triamcinolone acetonide as treatment of diffuse diabetic macular edema. *Am J Ophthalmol* 2004;(in press).
- 4 **Early Treatment Diabetic Retinopathy Study Research Group**. Classification of diabetic retinopathy from fluorescein angiograms. ETDRS report number 11. *Ophthalmology* 1991;**98**:807–2.
- 5 **Jonas JB**, Akkoyun I, Budde WM, *et al*. Intravitreal re-injection of triamcinolone for exudative age-related macular degeneration. *Arch Ophthalmol* 2004;**122**:218–22.

### Papillary vasoproliferative changes in cat scratch disease

A 23 year old man presented with a 10 day history of general malaise and a 1 week history of floaters in both eyes, predominantly in the right. He denied a febrile illness and exposure to animals. General medical history was unremarkable. He was not taking any medications.

On examination his visual acuity was 6/4-1 in the right eye and 6/4 in the left eye. Anterior chambers were quiet in both eyes. Dilated retinal examination showed 2+ vitreous cellular activity in the right eye and 1+ in the left eye, as well as evidence of bilateral neuroretinitis. The right optic disc was swollen with large dilated tortuous vessels associated with marked gliosis. The lesion was surrounded by lipid exudate and an inferior preretinal haemorrhage (fig 1). In the



**Figure 1** Colour fundus photograph of right eye showing papillary aneurysmal lesion with overlying gliosis, peripapillary hard exudate, and inferior preretinal haemorrhage.

left eye, there was also a prominent sheathed arteriole superior to the fovea.

Fluorescein angiography in the early phase demonstrated the arterial aneurysmal vascular changes on the optic disc (fig 2). Significant leakage occurred in the mid-phase (fig 3). There was no evidence of retina arteriolar or venular occlusion.

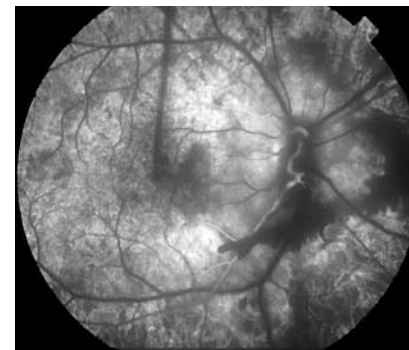
Full blood count with differential, serum electrolyte, C reactive protein, and erythrocyte sedimentation rate results were normal. The serum IgG was slightly elevated (IgG 14.26 g/l, normal laboratory range 6.12–12.93 g/l) and the serum IgA and IgM levels were normal, with a normal serum electrophoretic pattern. HIV serology was negative. Mantoux test, treponemal serology, antinuclear antibody, rheumatoid factor, and sarcoid results were also negative. An orbital computed tomography (CT) scan did not show significant abnormalities.

The diagnosis of cat scratch disease was confirmed by an elevated titre for *Bartonella (Rochalimaea) henselae* of 1:128 using the indirect fluorescent antibody test.

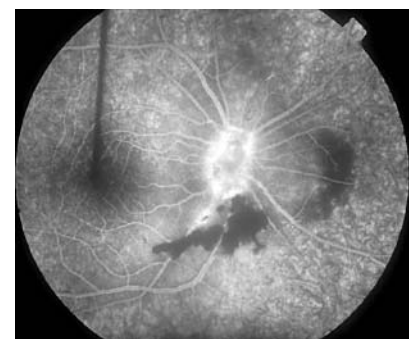
The patient was treated with 150 mg oral doxycycline twice daily and 100 mg oral rifampicin twice daily. The vitritis settled with prednisone. However the aneurysmal disc changes remained unchanged. At 1 year follow up his visual acuity was 6/6 in both eyes. The left eye subsequently developed marked papillary vasoproliferative changes at 12 months (fig 4).

### Comment

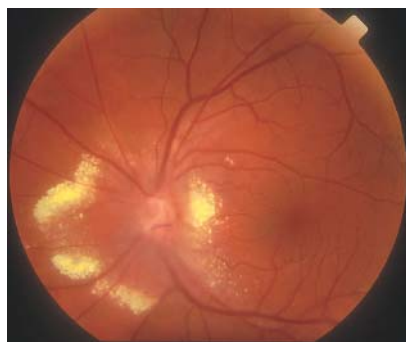Cat scratch disease (CSD) is typically a benign and self limiting illness, caused by *Bartonella henselae* bacteria (previously known



**Figure 2** Fluorescein angiography of right eye showing early filling of the arteriolar aneurysmal lesion on the optic disc.



**Figure 3** Fluorescein angiography of right eye showing mid-phase peripapillary leakage.



**Figure 4** Colour fundus photograph of the left eye showing severe papillary vasoproliferative changes at 12 months.

as *Rochalimaea henselae*) lasting 6–12 weeks in the absence of antibiotic treatment. Ocular lesions occur in about 6% of cases.<sup>1</sup> This case illustrates the papillary vasoproliferative changes that can occur with CSD. Retinal vascular proliferative changes may be of diagnostic significance and should be sought in patients with ocular CSD.

Ocular manifestations of cat scratch disease include Parinaud's oculoglandular syndrome, neuroretinitis, optic neuritis, focal chorioretinitis, retinitis, exudative maculopathy, serous retinal detachment, vitreous inflammation,<sup>2</sup> and in this report, retinal vasoproliferative lesions. An angiomatous lesion has previously been described in cat scratch disease.<sup>3</sup> It has also been known to be associated with central retinal artery and vein occlusion, as well as neovascular glaucoma.<sup>4</sup>

Doxycycline and rifampicin have been used to treat neuroretinitis in CSD, as they have superior penetration into the central nervous system and eye.<sup>4–6</sup> Long term prognosis is usually good, although some patients may acquire a mild post infectious optic neuropathy.<sup>6</sup> The prevalence of CSD requires further study but it may be more common than expected in the general population or in patients with idiopathic uveitis.<sup>7</sup> Therefore, it is important to look for papillary vasoproliferative changes that may suggest the diagnosis of CSD.

**A A Chang, A Zeldovich, N H Sachdev, C Ly, P Beaumont**  
Sydney Retina Clinic, NSW, Australia

Correspondence to: Dr Andrew Chang, Sydney Retinal Clinic and Day Surgery, Level 13, 187 Macquarie Street, Sydney NSW 2000 Australia; achang@sydneyretina.com.au

doi: 10.1136/bjo.2004.048132

Accepted for publication 13 June 2004

## References

- 1 **Regnery R**, Tappero J. Unraveling mysteries associated with catscratch disease, bacillary angiomatosis, and related syndromes. *Emerg Infect Dis* 1995;1:16–21.
- 2 **Solley WA**, Martin DF, Newman NJ, et al. Cat scratch disease: posterior segment manifestations. *Ophthalmology* 1999;106:1546–53.
- 3 **Fish RH**, Hogan RN, Nightingale SD, et al. Peripapillary angiomatosis associated with cat-scratch neuroretinitis. *Arch Ophthalmol* 1992;110:323.
- 4 **Gray AV**, Michels KS, Lauer AK, et al. Bartonella henselae infection associated with neuroretinitis, central retinal artery and vein occlusion, neovascular glaucoma, and severe vision loss. *Am J Ophthalmol* 2004;137:187–9.
- 5 **Cunningham ET**, Koehler JE. Ocular bartonellosis. *Am J Ophthalmol* 2000;130:340–9.
- 6 **Reed JB**, Scales DK, Wong MT, et al. Bartonella henselae neuroretinitis in cat scratch disease. Diagnosis, management, and sequelae. *Ophthalmology* 1998;105:459–66.
- 7 **Suhler EB**, Lauer AK, Rosenbaum JT. Prevalence of serologic evidence of cat scratch disease in patients with neuroretinitis. *Ophthalmology* 2000;107:871–6.

## Treatment of recurrent orbital haemangiopericytoma with surgery and proton beam therapy

Orbital haemangiopericytoma is a rare, potentially malignant vascular tumour, which can affect any part of the orbit. The treatment of choice is complete surgical excision but because of its vascular nature and tissue friability during surgery this is frequently not achieved.<sup>1,2</sup> Difficulties in correctly diagnosing this tumour preoperatively compound this problem. Incomplete excision is associated with increased risk of local recurrence and metastatic disease, which are reported to occur in up to 43% and 15% of cases respectively, and can take many years to become manifest.<sup>2,3</sup> Treatment options for orbital recurrence include orbital exenteration, further attempts at complete excision, or local excision and adjuvant therapy with radiotherapy,<sup>4</sup> brachytherapy,<sup>5</sup> or chemotherapy.<sup>3</sup> To our knowledge the use of proton beam therapy in controlling recurrent orbital haemangiopericytoma has never been described. We therefore report such a case.

## Case report

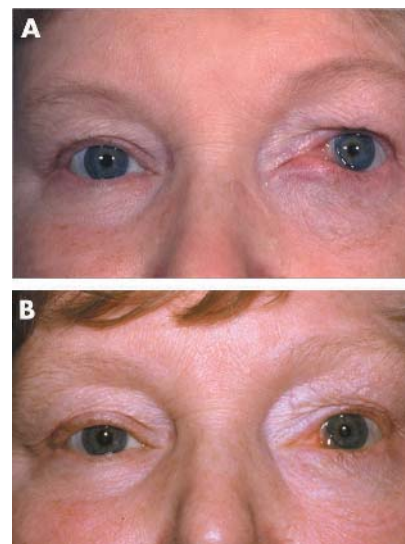
A 61 year old woman presented with a second recurrence of a left medial orbital haemangiopericytoma 2 years following radical excision of the tumour via a transfrontal approach, and 14 years after initial excision. She was found to have non-axial proptosis of the globe associated with a soft tissue swelling at the medial canthus (fig 1). Her visual acuities were unchanged from initial presentation at 6/6 in the right eye and 6/9 in the left eye. She also had restriction of the left globe on dextroversion resulting in diplopia, which, although longstanding, had deteriorated considerably as shown by the field of binocular single vision. Neurosurgical review was arranged and it was thought that further attempts at complete excision would be unsuccessful. This, together with the patient's desire not to undergo further major surgery, led us to explore other treatment options. She therefore underwent further local excision via a medial orbital approach to debulk the tumour mass followed by proton beam therapy with a total irradiation dose of 50 Gy equivalent in 20 fractions over 28 days. The protocol for this management plan employed standard parameters, with treatment margins of 2.5 mm on either side of the tumour, and 2.0 mm at its posterior limit. She responded well to this treatment with a reduction in tumour size radiologically, and a subjective improvement in ocular motility. In the 7 years following her proton beam treatment serial magnetic resonance imaging (MRI) has revealed no further growth of the residual tumour mass (fig 2). She maintained a visual acuity of 6/9 in the left eye for 3 years following treatment but subsequently developed ischaemic optic neuropathy reducing her acuity to 5/60.

## Comment

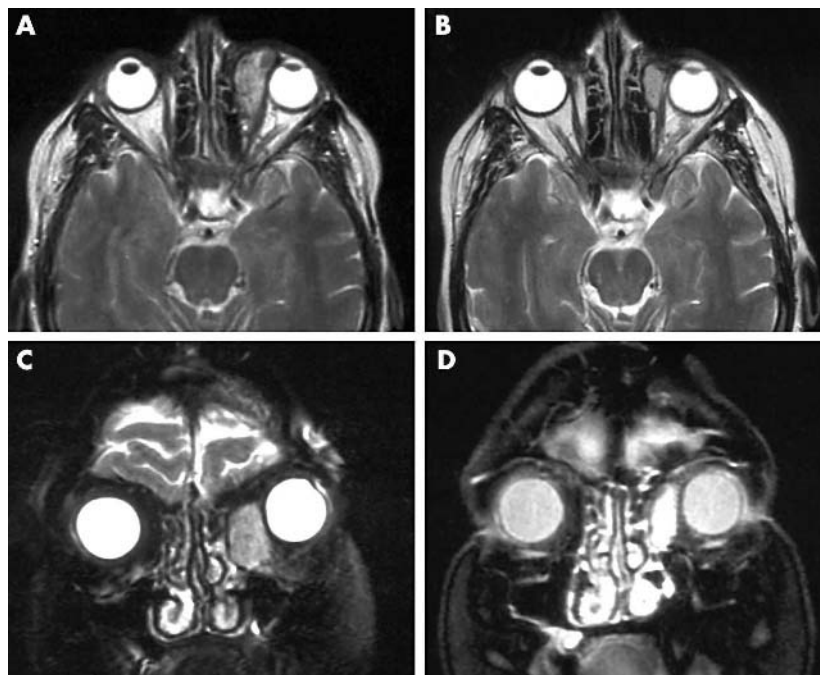
This patient, having already undergone extensive orbital surgery on two occasions, was reluctant to consider a further procedure. Although there is evidence to support the use of adjuvant external beam radiotherapy after conservative surgery,<sup>4</sup> it was felt that because of the size and location of our patient's tumour, the dose required was likely to cause significant damage to surrounding structures. A decision was therefore taken to explore proton beam therapy as a potential adjuvant treatment for our patient, particularly as our department has gained experience with its use in the management of uveal melanomas. Following discussion with our colleagues at the Douglas Cyclotron, Clatterbridge Centre for Oncology, it was decided that owing to the relatively superficial location of the tumour, proton beam therapy would be a feasible option.

High energy heavy charged particle irradiation with proton beams offers several advantages over external radiotherapy. The particles have minimal scatter and can be collimated into small beams delivering maximal ionisation as they stop. This results in the phenomenon of the Bragg peak which is "modulated" with depth to produce a precise uniform dose volume.<sup>6</sup> As the depth of penetration can be controlled, the radiation can be targeted almost exclusively at the tumour mass with minimal irradiation of surrounding tissues.<sup>7</sup> The radiation dose of 50 Gy equivalent was chosen empirically and based on the normal dose used for the treatment of choroidal melanomas as there is no precedent in using this treatment for orbital haemangiopericytoma.

Unfortunately, this patient developed ischaemic optic neuropathy which is a recognised complication of proton beam therapy, particularly when more than 2 mm of optic nerve is irradiated at 30 Gy equivalent.<sup>8</sup> Because of the size and location of our patient's tumour, there was a high risk of this complication occurring, as there would have been had external beam radiotherapy been used instead. Nevertheless, this report demonstrates that proton beam therapy can be effective in controlling recurrent



**Figure 1** (A) Before further local excision and proton beam therapy the left medial canthal swelling and lateral globe displacement is obvious. (B) 7 years after treatment the reduction in tumour mass is still clearly visible.



**Figure 2** Axial (A) and coronal (C) MRI images before proton beam therapy. The haemangiopericytoma is evident in the left medial orbit. (B) and (D) show the same views 7 years after conservative surgery and proton beam therapy.

orbital haemangiopericytoma and perhaps its use should therefore be considered as an adjuvant in the treatment of recurrent disease, particularly when the tumour is in a superficial location.

**H C Gear, E G Kemp**

Tennent Institute of Ophthalmology, Gartnavel General Hospital, Glasgow, UK

**A Kacperek, R D Errington**

Douglas Cyclotron, Clatterbridge Centre for Oncology, Wirral, UK

Correspondence to: Ewan G Kemp, Tennent Institute of Ophthalmology, Gartnavel General Hospital, Glasgow, UK; Ewan.Kemp@northglasgow.scot.nhs.uk

doi: 10.1136/bjo.2004.048439

Accepted for publication 2 June 2004

## References

- Sullivan TJ, Wright JE, Wulc AW, *et al.* Haemangiopericytoma of the orbit. *Aust N Z J Ophthalmol* 1992;**20**:325–32.
- Jakobiec FA, Howard GM, Jones IS, *et al.* Hemangiopericytoma of the orbit. *Am J Ophthalmol* 1974;**78**:816–34.
- Croxatto JO, Font RL. Hemangiopericytoma of the orbit: a clinicopathologic study of 30 cases. *Hum Path* 1982;**13**:210–18.
- Setzkorn RK, Lee DJ, Iliff NT, *et al.* Hemangiopericytoma of the orbit treated with conservative surgery and radiotherapy. *Arch Ophthalmol* 1987;**105**:1103–5.
- Tijl JW, Koornneef L, Blank LE. Recurrent hemangiopericytoma and brachytherapy. *Doc Ophthalmol* 1992;**82**:103–7.
- Wilson RR. Radiological use of fast protons. *Radiology* 1946;**47**:487–91.
- Gragoudas ES, Goitein M, Verhey L, *et al.* Proton beam irradiation. *Ophthalmology* 1980;**87**:571–81.
- Meyer A, Levy C, Blondel J, *et al.* Optic neuropathy after proton-beam therapy for malignant choroidal melanoma. *J Fr Ophthalmol* 2000;**23**:543–53.

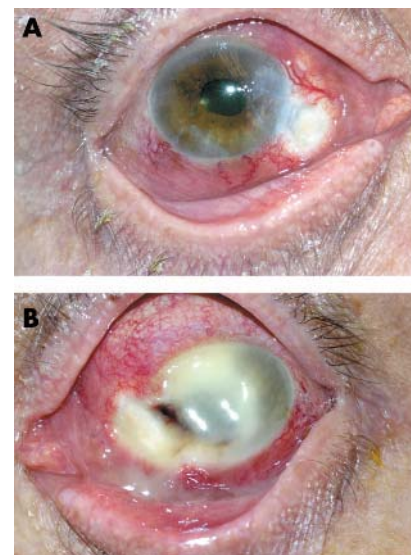
## Bilateral surgically induced necrotising scleritis with secondary superinfection

Surgically induced necrotising scleritis (SINS) is a rare complication of ocular surgery that has been described after pterygium excision, cataract extraction, trabeculectomy, penetrating keratoplasty, strabismus surgery, and retinal detachment repair.<sup>1–3</sup> We describe a rare case of bilateral necrotising scleritis complicated by a secondary polymicrobial infection following uncomplicated phacoemulsification and pterygia excision.

## Case report

A 66 year old Samoan male, with type II diabetes, end stage renal disease, coronary artery disease, and gout underwent uncomplicated combined phacoemulsification and bare sclera pterygium excision (without antimetabolites) in the right eye, followed 1 month later by the same combined procedure in the left eye. Three weeks later, the patient developed severe right sided eye pain. An erythrocyte sedimentation rate was 98 mm in the first hour, and oral prednisone (80 mg/day) was initiated. A temporal artery biopsy was negative and prednisone was discontinued after 4 days of treatment. One week later, the patient developed left sided eye pain as well as a productive cough. Corneoscleral necrosis developed in the left eye and rapidly progressed to perforation.

On examination, the visual acuity was 20/40 right eye and light perception left eye. In the left eye (fig 1), there was ischaemic scleral necrosis with thinning, perforation, and iris prolapse at the nasal limbus. On the right, there was a hypopyon and a 4 mm × 3.5 mm area of necrotic, ischaemic sclera with thinning at the limbus. Fundus examination of the right eye demonstrated moderate non-proliferative diabetic retinopathy.



**Figure 1** (A) Right eye demonstrating a local area of scleral necrosis at the nasal limbus and a hypopyon. (B) Left eye demonstrating scleral necrosis with thinning, perforation, and iris prolapse at the nasal limbus.

B-scan ultrasound revealed choroidal thickening right eye and haemorrhagic choroidals left eye.

Scleral cultures were taken, and the patient's corneoscleral perforation was emergently closed with cyanoacrylate glue. An extensive laboratory evaluation for systemic aetiologies of scleral necrosis was unrevealing except for a mildly elevated rheumatoid factor of 62 IU/ml (normal <40 IU/ml.) Culture results demonstrated a bilateral polymicrobial infection, with *Streptococcus pneumoniae* and *Streptococcus viridans* in the right eye, and *Streptococcus pneumoniae*, *Streptococcus viridans*, and *Haemophilus influenzae* in the left eye.

The patient was treated with topical (gatifloxacin and vancomycin), intravenous (ciprofloxacin), and subconjunctival (vancomycin) antibiotics. In addition, oral anti-collagenase therapy (tetracycline and vitamin C) was employed. Repeat cultures taken on day 3 were negative. By day 4, however, the vision in the right eye had decreased to 20/200, the area of necrosis had enlarged and the pupil began to peak nasally. Systemic immune suppression was initiated with an intravenous pulse of 1 g of both cyclophosphamide and methylprednisolone. Within 48 hours of initiating immune suppression, granulation tissue began to fill the areas of necrosis and ocular pain subsided. Two months following presentation, while on a prednisone taper, the patient's best corrected visual acuity was 20/40 right eye. He remained at light perception in the left eye.

## Comment

We believe this complicated case of bilateral, rapidly progressing, necrotising scleritis in a post-surgical patient represents a case of bilateral surgically induced necrotising scleritis (SINS) complicated by secondary polymicrobial infection. SINS has been reported following bare sclera pterygia excision, though it is more commonly associated with adjunctive  $\beta$  irradiation, thiotepa, and mitomycin C.<sup>4–6</sup> The time course of events, as well as the response to

immune suppression supports a primary auto-immune aetiology complicated, secondly, by a polymicrobial infection. Immune suppression, however, was initiated only after aggressive antimicrobial therapy.

The necrotising nature of the scleritis in our patient is consistent with the series by O'Donoghue *et al* in which a fourfold greater rate of necrosis occurred in post-surgical patients compared to a non-surgically induced scleritis population.<sup>2</sup> In their series, the majority of patients (75%) had two or more surgical procedures before the onset of scleritis, and systemic immune suppression was necessary in 93% of patients. Our case similarly illustrates the need to consider immunosuppressive therapy in patients with postoperative necrosis.

**M R Vagefi, D A Hollander**

Department of Ophthalmology, University of California, San Francisco, CA, USA

**G D Seitzman, T P Margolis**

Department of Ophthalmology and The Francis I Proctor Foundation, University of California, San Francisco, CA, USA

Correspondence to: Todd P Margolis, MD, The Francis I Proctor Foundation, 95 Kirkham Street, Room 305, University of California at San Francisco, San Francisco, CA 94143-0944, USA; [tpms@itsa.ucsf.edu](mailto:tpms@itsa.ucsf.edu)

doi: 10.1136/bjo.2004.051359

Accepted for publication 4 June 2004

## References

- 1 **Lyne AJ**, Lloyd-Jones D. Necrotising scleritis after ocular surgery. *Trans Ophthalmol Soc UK* 1979;**99**:146-9.
- 2 **O'Donoghue E**, Lightman S, Tuft S, *et al*. Surgically induced necrotising sclerokeratitis (SINS)—precipitating factors and response to treatment. *Br J Ophthalmol* 1992;**76**:17-21.
- 3 **Galanopoulos A**, Snibson G, O'Day J. Necrotising anterior scleritis after pterygium surgery. *Aust N Z J Ophthalmol* 1994;**22**:167-73.
- 4 **Alsagoff Z**, Tan DTH, Chee SP. Necrotising scleritis after bare sclera excision of pterygium. *Br J Ophthalmol* 2000;**84**:1050-2.
- 5 **Tarr KH**, Constable IJ. Late complications of pterygium treatment. *Br J Ophthalmol* 1980;**64**:496-505.
- 6 **Rubinfeld RS**, Pfister RR, Stein RM, *et al*. Serious complications of topical mitomycin-C after pterygium surgery. *Ophthalmology* 1992;**99**:1647-54.

## NOTICES

### Worldwide clinical trials for new technique for early detection of eye disease

A unique new non-invasive technique for high resolution optical imaging of the eye is

receiving global acclaim. By combining two high-resolution imaging technologies, the new technique provides doctors with 3-D images of the retina, macula and the optic nerve.

For more information, contact the Media Office on 01227 823581/823100 or email [MediaOffice@kent.ac.uk](mailto:MediaOffice@kent.ac.uk) News releases can also be found at: <http://www.kent.ac.uk/news>

### Vision 2020 Priority Diseases

The latest (redesigned) issue of *Community Eye Health* (No 51) deals with the gaps between aims of Vision 2020 and how far we are still from them, especially in Africa. For further information please contact: Journal of Community Eye Health, International Resource Centre, International Centre for Eye Health, Department of Infectious and Tropical Diseases, London School of Hygiene and Tropical Medicine, Keppel Street, London WC1E 7HT, UK (tel: +44 (0)20 7612 7964; email: [Anita.Shah@lshtm.ac.uk](mailto:Anita.Shah@lshtm.ac.uk); online edition: [www.jceh.co.uk](http://www.jceh.co.uk)). Annual subscription (4 issues) UKE28/US\$45. Free to developing country applicants.

### British Oculoplastic Surgery Society

Call for papers for the 5<sup>th</sup> annual meeting of the BOPSS to be held on 15 and 16 May 2005 at The Belfry, Birmingham. The abstract submission deadline is 4 February 2005, and abstracts can be submitted online at [www.bopss.org](http://www.bopss.org).