

Personal practice

Management of gastro-oesophageal reflux

I J CARRÉ

Nuffield Department of Child Health, Queen's University of Belfast and Royal Belfast Hospital for Sick Children

SUMMARY Parental reassurance and thickened feeds are the only requirements in the management of infants with reflux when this is the sole detectable gastro-oesophageal abnormality. In view of the strong propensity for spontaneous clinical resolution and the excellent results achieved by conservative management, infants with reflux due to a partial thoracic stomach (hiatal hernia) uncomplicated by a stricture should be treated in the first instance by postural therapy, with or without thickened feeds and supplements of antacids, domperidone, and cimetidine. Those showing no response after an adequate period of conservative treatment should have an antireflux operation. The Belsey MK IV type of fundoplication is preferred. Only an exceptional patient will require to be treated surgically before 12 months of age. The same surgical antireflux procedure, combined with oesophageal dilatations as necessary, is the treatment of choice for patients with a partial thoracic stomach complicated by a reflux oesophageal stricture. A similar treatment regimen should be followed for patients with reflux after repair of an oesophageal atresia. Surgical correction is mandatory for all infants with reflux due to a large combined hiatal hernia.

Gastro-oesophageal reflux is common in infants. In the great majority this constitutes a 'physiological' event and is of little clinical consequence. In a minority of instances reflux is 'pathological' and potentially harmful and almost always due to an underlying partial thoracic stomach (sliding hiatal hernia) (Fig. 1).¹ From the point of view of management there are therefore two major categories of

patients to be considered: (1) infants with reflux as the only detectable gastro-oesophageal abnormality and (2) patients with gastro-oesophageal reflux attributable to a partial thoracic stomach. A very small additional group of infants warrants separate comment. In these patients reflux occurs after surgical repair of an oesophageal atresia or as a complication of a combined hiatal hernia (Fig. 1).

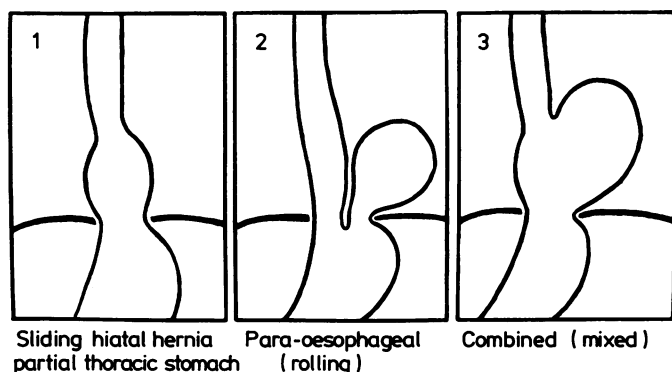


Fig. 1 Types of hiatal hernia.

Infants with reflux only

In these infants reflux is a self limiting condition that resolves spontaneously as an effective antireflux barrier is gradually established.² It is an important aspect of management that parents should be reassured of this fact. The clinical problem presented by these infants is predominantly one of frequent regurgitation and very occasional vomiting. These patients, when bottle fed, should be treated in the first instance with thickened feeds. This can be achieved by adding a thickening agent such as a carob seed preparation (for example Nestargel) to bottle feeds. For treatment to be effective adequate thickening is essential. Nestargel should be added to feeds in the proportion of 1 g to 115 ml (4 oz). This type of preparation has the great advantage over additives such as cereals of having no food value and so avoids undesirable calorie supplementation. Parents should be warned that Nestargel can cause frequent loose gelatinous stools which may occasionally necessitate its temporary withdrawal. The introduction of spoon feeding will further hasten clinical resolution. In the author's experience of over 1000 infants with this type of isolated reflux not one has required surgical intervention.

Should there be little or no clinical response to thickened feeds within two or three weeks, postural therapy should be added and the infant re-examined radiologically for a partial thoracic stomach particularly if the clinical features are strongly suggestive of this disorder.³ The possibility that the infant's symptoms may in fact be due to some totally unrelated disorder such as a urinary tract infection should also be carefully reconsidered. This applies

especially to those infants who seem reluctant to feed and are failing to thrive.

Infants with reflux and partial thoracic stomach

About 65% of all infants attending hospital with symptoms due to a partial thoracic stomach will become symptom free by 2 years of age if given no treatment⁴ (Fig. 2). Because of this tendency to undergo spontaneous clinical improvement therapeutic results need to be critically evaluated. In making any assessment it is of the utmost importance that particular attention be paid to the age and category of patient being treated, the details of treatment, the frequency and duration of review, and the method of evaluating results. Unfortunately such essential data are frequently omitted in published reports making it difficult, if not impossible, to effect a useful comparison between different studies. This has inevitably led to much confusion over the indications and relative merits of different treatments, particularly with regard to conservative *v* surgical management.

The following observations and conclusions relating to management are based on personally documented information and experience of 710 infants with a partial thoracic stomach who have been studied prospectively by the author during the past 35 years. One hundred and twenty eight have been kept under review for over 20 years; 80 of these for more than 30 years.

Conservative management. The objective of conservative management is to exploit and accelerate the natural tendency for clinical recovery. The

Symptoms before 3 months of age	Symptoms on weaning to solid food	Prognosis	Approximate % of patients
Present (98%)	None or improved	Benign course. Symptom free by 2 years.	60 - 65
	No improvement or worse	Prolonged clinical course. Troublesome symptoms >4 years No oesophageal stricture	30
Absent (2%)		Oesophageal stricture	5
Deaths (in absence of an oesophageal stricture)			<5

Fig. 2 Natural history of partial thoracic stomach.⁴

regimen of management currently employed by the author is, with only minor modifications, the same as that originally formulated in the early 1950s.⁵

Postural therapy

Postural therapy is the essential basis of treatment. This is aimed at reducing reflux and assisting clearance of regurgitated gastric juice from the terminal oesophagus thereby decreasing the risk of oesophagitis and of aspiration pneumonia. Infants should be nursed sitting up at an angle of 60° or more both by day and night. This degree of 'propping' can only be maintained by using some form of harness or hard backed chair. Lesser degrees of propping using pillows or raising the head of the cot on blocks are of no detectable value. Maintaining an infant upright for only short periods after feeds is equally unhelpful. It is imperative that this upright posture be maintained during the night when gastric secretions are neither diluted nor buffered by milk feeds. During sleep salivation all but ceases and the frequency of swallowing is correspondingly greatly reduced. As a result the neutralising effect of swallowed saliva is lost and because peristaltic waves are not initiated, clearing of the lower oesophagus of refluxed gastric juice is impaired. Postural treatment should also be maintained by day, though it is essential that infants should be taken out of their chairs not only for feeding and napkin changing but also very importantly for cuddling and play. Except possibly for an initial period in hospital, and provided social circumstances permit, patients who are otherwise well are treated at home and kept under regular hospital outpatient review. Parents must be given an unhurried simple explanation of the nature of the disorder and its prognosis and of the reason for employing the form of management advocated, since successful treatment will very largely depend on their cooperation and understanding.

Supplementary measures

Various supplementary measures may be helpful. Frequent small feeds will often result in a reduction in vomiting in small infants. A similar effect can be achieved by adding a thickening agent (Nestargel) to the bottle feeds of those responding slowly to posture alone.

Antacids are symptomatically helpful in adults and their use in children would therefore seem clinically justified, both for their neutralising effect and for their capacity to increase gastro-oesophageal sphincteric tone. In young children this can usefully be prescribed as an alginate-antacid compound (Gaviscon); 10 ml are given after meals and at bedtime. In the stomach this preparation forms a

viscous antacid demulcent gel that floats like a raft on the surface of the stomach contents. The frequency of reflux is reduced,⁶ and should reflux occur this bland material will tend to be regurgitated into the oesophagus ahead of other gastric contents. An infant preparation of Gaviscon is available for mixing into bottle feeds. This particular form of presentation, however, has two serious disadvantages: (1) the very occasional formation of large bezoar-like masses of agglutinated intragastric material,^{7,8} and (2) its sodium content (4 mmol per sachet) which can increase the sodium content of feeds to an undesirable degree. In infants, therefore, it is preferable to use sodium free preparations such as Asilone.

Metoclopramide and cimetidine are two drugs that have been advocated as likely to be of benefit, but their usefulness is limited and they should only be prescribed in selected cases. Metoclopramide should theoretically be helpful because of its effect of increasing both gastro-oesophageal sphincteric pressure and the rate of gastric emptying. Distressing extrapyramidal side effects, however, have very occasionally been reported in infants, even when the dose schedule used has been less than that normally recommended.^{9,10} If prescribed, prolonged use should be avoided, the dose used should be less than recommended (less than 0.5 mg/kg/24 hrs), and a careful watch must be kept for dystonic reactions. A preferable drug to metoclopramide would seem to be the dopamine receptor antagonist domperidone. This drug, which seems to be equally effective therapeutically, has the important added advantage of being very much less likely to cause dystonic reactions in babies.¹¹ Domperidone can be given orally in a dose of 0.6 to 1.2 mg/kg/24 hrs in three divided doses.

Cimetidine is an H₂ receptor antagonist and a potent inhibitor of gastric hydrochloric acid and pepsin secretion; it has no effect on the gastro-oesophageal sphincter. Clinical trials in adults with reflux oesophagitis have yielded conflicting results in that though symptoms are usually improved, there is often no conclusive objective evidence of concomitant oesophageal healing. Treatment with 20 to 40 mg/kg/24 hrs in three divided doses is recommended for children. Anticholinergic drugs should be avoided as they reduce the tone of the gastro-oesophageal sphincter.

Results

The clinical assessment of a patient's progress and response to treatment is derived from a composite analysis of many factors such as vomiting frequency, the occurrence of haematemesis, dysphagia, weight

gain, anaemia and pulmonary infections possibly augmented in a very few instances by radiological and endoscopic examination. Endoscopy is not a required routine procedure. It is only necessary and helpful in selected cases when clinical progress is proving unsatisfactory and when radiological studies suggest the possibility of stricture formation. In practice the frequency of vomiting provides the most useful single clinical guide to progress during early infancy. Parents should, therefore, always be asked to keep an accurate record of vomiting episodes. Brief relapses, often caused by an upper respiratory tract infection, are not of themselves an indication for stopping conservative treatment.

When started in early infancy, conservative management may be expected to benefit most patients.^{5 12} Over 90% of patients started on treatment before 3 months of age will be free of symptoms by 1 year, compared with an estimated 35% in the absence of treatment.^{12 13} (Table 1). It is, however, important to appreciate that the response to treatment is often gradual. Though greatly improved, about 30% of patients will still not be totally free of symptoms after three months' treatment; postural treatment of these infants should be maintained for up to six months if necessary. Otherwise treatment may be stopped once six weeks of freedom from symptoms have been recorded.

Patients treated successfully by conservative means who have been followed up for over 30 years have remained in good health despite the fact that a partial thoracic stomach was still shown on fluoroscopy in about 40% when reviewed after 20 years.^{14 15} If radiological resolution of a partial thoracic stomach is going to occur this will have taken place by 4 to 6 years of age.

In older patients the therapeutic response is less satisfactory. This is to be expected since oesophageal damage is more likely to be present and because adequate sustained posturing is more difficult to achieve. Nevertheless, provided there is no evidence of a stricture, a three month trial of postural therapy should be tried since about 80% of patients aged between 6 and 18 months will respond. Not all untreated patients first diagnosed after 18

Table 1 Long term clinical progress of untreated and conservatively treated infants with partial thoracic stomach

Treatment	Patients (%) clinically well at:			
	1 Year	2 Years	4 Years	30 + Years
None	35	55	70	85
Postural (<3 months of age)	90	95	95	95

Table 2 Management of patients with partial thoracic stomach

Age on starting treatment (months)	Duration of conservative treatment (months)	Proceeding to surgery (%)	Surgery
<6	6	5	Fundoplication
6-18	3	20	
>18	3	60	
All ages with stricture	Nil	100	Fundoplication (+ dilatations)

months of age are necessarily badly affected clinically. Even though it is often impossible to implement effective postural therapy, a three month trial of conservative management of these patients without a stricture will result in 40% becoming symptom free.

Surgery. The efficacy of conservative management is such that very few children under 12 months of age with a partial thoracic stomach require to be treated surgically. Patients with no stricture whose symptoms persist despite an adequate course of conservative treatment and those with an endoscopically confirmed stricture will require to be treated surgically (Table 2). An antireflux operation such as a Nissen or Belsey MK IV type of fundoplication should be performed. The two third wrap-around Belsey procedure is preferred to the 360° Nissen fundoplication for it allows postoperative patients to vomit when necessary, and to belch—a facility of particular importance to children because of their fondness for aerated drinks. Patients with a stricture will require, in addition to a fundoplication, to have the stricture dilated as necessary: radical surgery with oesophageal resection and colon replacement should be avoided.

The same management guidelines are applicable to mentally handicapped children with a partial thoracic stomach. Symptoms of gastro-oesophageal incompetence in these children are, however, often misinterpreted or overshadowed by those of developmental retardation. As a consequence the diagnosis of a partial thoracic stomach is frequently delayed, and this delay together with the difficulty of carrying out adequate postural therapy means that a greater proportion of these patients will require to be treated surgically.

Infants with reflux as a complication of other gastro-oesophageal disorders

The surgical correction of oesophageal atresia is often followed by swallowing difficulties and recurrent attacks of aspiration pneumonitis. These com-

plaints are mainly due to grossly disturbed oesophageal motility.¹⁶ Gastro-oesophageal reflux with or without a partial thoracic stomach can also be shown in many of these infants. The clinical importance of this latter observation is, however, difficult to evaluate. Because of impaired oesophageal clearing, reflux in these patients is more likely to be of clinical significance than in infants with a normally functioning oesophagus. The possibility that reflux may be an aggravating factor must, therefore, be carefully considered in patients with protracted troublesome symptoms or a tight persistent anastomotic stricture.¹⁷ In those in whom there is good evidence of the harmful effect of reflux an antireflux operation should be undertaken whether or not a partial thoracic stomach is present. In the author's experience antireflux surgery is, however, only occasionally required, for with very few exceptions these patients can be successfully managed conservatively as outlined in the section on partial thoracic stomach.

Symptomatic gastro-oesophageal reflux is often a feature of the very uncommon combined type of hiatal hernia (Fig. 1). In this abnormality a relatively large portion of stomach protrudes into the thorax; in some only the pyloric region may remain within the abdomen. Because of the risk of pyloric obstruction and torsion of the stomach these herniae should be repaired surgically regardless of the severity of symptoms.

References

- ¹ Carré IJ. The clinical significance of gastro-oesophageal reflux. *Arch Dis Child* 1984;**59**:911–2.
- ² Boix-Ochoa J, Canals J. Maturation of the lower esophagus. *J Pediatr Surg* 1976;**11**:749–56.
- ³ Carré IJ. Disorders of the oro-pharynx and oesophagus. In: Anderson CM, Burke V, eds. *Pediatric gastroenterology*. Oxford: Blackwell Scientific, 1975:33–79.
- ⁴ Carré IJ. The natural history of the partial thoracic stomach ('hiatus hernia') in children. *Arch Dis Child* 1959;**34**:344–53.
- ⁵ Carré IJ. Postural treatment of children with a partial thoracic stomach ('hiatus hernia'). *Arch Dis Child* 1960;**35**:569–80.
- ⁶ Stanciu C, Bennett JR. Alginate/antacid in the reduction of gastro-oesophageal reflux. *Lancet* 1974;**i**:109–11.
- ⁷ Hewitt GJ, Benham ES. A complication of Gaviscon in a neonate—'The Gavisconoma'. *Aust Paediatr J* 1976;**12**:47–8.
- ⁸ Keipert JA. The mode of action and complications of infant Gaviscon. *Aust Paediatr J* 1979;**15**:263–5.
- ⁹ Reid M. Dystonic reactions to metoclopramide (Maxolon). *Ulster Med J* 1977;**46**:38–40.
- ¹⁰ Low LCK, Goel KM. Metoclopramide poisoning in children. *Arch Dis Child* 1980;**55**:310–2.
- ¹¹ De Loore I, Van Ravensteyn H, Ameryckx L. Domperidone drops in the symptomatic treatment of chronic paediatric vomiting and regurgitation: a comparison with metoclopramide. *Postgrad Med J* 1979;**55**:40–2.
- ¹² Carré IJ. Postural treatment of infants and young children with a hiatal hernia (partial thoracic stomach). In: Gellis SS, ed. *Gastroesophageal reflux*. Report of the seventy-sixth Ross Conference on paediatric research. Columbus, Ohio: Ross Laboratories, 1979:86–94.
- ¹³ Carré IJ. Clinical features and natural history of gastro-oesophageal incompetence/partial thoracic stomach ('hiatal hernia') in children. In: Van Heukelem HA, Gooszen HG, Terpstra JL, Belsey RHR, eds. *Pathological gastro-oesophageal reflux*. Proceedings of the Workshop on Diagnosis and Treatment of Pathological Gastro-oesophageal Reflux. Noordwijk/Leiden 22–24 November 1982. Amsterdam: Zuid-Nederlandse Uitgevers-Mij Bv, 1983.
- ¹⁴ Carré IJ, Astley R, Langmead-Smith R. A 20-year follow-up of children with a partial thoracic stomach (hiatal hernia). *Aust Paediatr J* 1976;**12**:92–4.
- ¹⁵ Astley R, Carré IJ, Langmead-Smith R. A 20 year prospective follow-up of childhood hiatal hernia. *Br J Radiol* 1977;**50**:400–3.
- ¹⁶ Shepard RL, Fenn S, Sieber WK. Evaluation of esophageal function in postoperative esophageal atresia and tracheo-oesophageal fistula. *Surgery* 1966;**59**:608–17.
- ¹⁷ Pieretti R, Shandling G, Stephens CA. Resistant esophageal stenosis associated with reflux after repair of esophageal atresia: a therapeutic approach. *J Pediatr Surg* 1974;**9**:355–7.

Correspondence to Professor I J Carré, Le Val, Les Blicqs, St Andrew's, Guernsey, Channel Islands.