

## Developmental sequence of periventricular leukomalacia

Correlation of ultrasound, clinical, and nuclear magnetic resonance functions

L M S DUBOWITZ, G M BYDDER, AND J MUSHIN

*Departments of Paediatrics and Neonatal Medicine and Diagnostic Radiology, Royal Postgraduate Medical School, Hammersmith Hospital, London*

**SUMMARY** The evolution of severe periventricular leukomalacia was followed by ultrasonography in three newborn infants, and the subsequent myelination of the brain was assessed by nuclear magnetic resonance imaging. Four stages of periventricular leukomalacia could be identified by ultrasonography; (1) initial congestion, followed by (2) relative normalisation, (3) development of cysts, and (4) resolution of cysts but development of ventricular enlargement. All infants exhibited abnormal neurological signs from 36 weeks conceptual age and had unequivocal signs of cerebral palsy by 6 to 9 months of age. One infant became cortically blind but the other two seemed to have normal vision. Nuclear magnetic resonance imaging showed some abnormality of the ventricular system and delayed myelination in all three infants. The delay was most noticeable in the opticothalamic region, which was also the site of the most extensive lesions observed on ultrasonography. Progress in myelination was observed in the infants where a repeat scan was performed.

Periventricular leukomalacia in the brain of the newborn infant has been recognised by pathologists since the last century.<sup>1-3</sup> Its ischaemic nature and evolution, however, were first documented only comparatively recently by Banker and Larroche.<sup>4</sup> It is an infarction of the white matter which leads to demyelination.<sup>5</sup> It has been suggested that lesions in the area of the centrum semiovale form the anatomical basis of cerebral diplegia, while the lesions in the optic and auditory radiation will lead to sensory impairment.<sup>5, 6</sup>

Recent advances in imaging techniques have provided the opportunity to test this hypothesis. Periventricular leukomalacia has been detected in the neonatal period by cranial ultrasonography.<sup>7, 8</sup> Recently Bowerman *et al*<sup>9</sup> reported the evolution of the ultrasound findings in some of the survivors. Further confirmation was obtained by correlative necropsy studies by Nwaesei *et al*<sup>10</sup> who showed that echodensities of this nature seen in the parenchyma on ultrasonography represent haemorrhagic or non-haemorrhagic periventricular infarction.

Nuclear magnetic resonance imaging can show the process of myelination in infancy<sup>11</sup> and it should thus be possible to study the effect of periventricular

leukomalacia on myelination during life and correlate this with clinical outcome.

We have been able to study prospectively, over an 18 month period, three infants in whom the diagnosis of periventricular leukomalacia was made in the neonatal period by ultrasonography. The evolution of the ultrasound appearances, the clinical course, and associated findings on nuclear magnetic resonance imaging form the basis of this report.

### Patients and methods

The three infants were born at 31, 30, and 31 weeks' gestation, and weighed 1420, 1340, and 1760 g respectively (cases 1, 2 and 3). The pregnancy was complicated by antepartum haemorrhage in case 1. All three were delivered by emergency caesarean section because of fetal distress in case 1, breech presentation in a triplet pregnancy in case 2, and transverse lie in case 3. All had Apgar scores of 5 or less at one minute, were briefly intubated, and had Apgar scores above 7 by 10 minutes. They were all reintubated for hyaline membrane disease within the first few hours of life. All three also developed pneumothoraces, had acidosis (with at least one pH

value below 7.2), and had a period of low pulse pressure, though the lowest systolic blood pressure recorded in any of them was 42 mmHg. None had any evidence of sepsis.

All three infants had daily ultrasound examinations and neurological assessments during the first week of life, then twice weekly until hospital discharge and again at 42, 41, and 42 weeks conceptual age respectively.

Ultrasound scanning was performed through the anterior fontanelle using an ATL Mark III sector scanner with 5 and 7 MHz transducers. Images were obtained in coronal, semiaxial, and parasagittal planes. Increased echogenicity was considered present when it was similar in density to that of the choroid plexus and was visible in the coronal or axial as well as the parasagittal planes. Cysts were identified as areas of low echogenicity of at least 2 mm in diameter.

Neurological assessment in the neonatal period included a detailed neurological examination,<sup>12</sup> measurement of visual acuity by preferential looking

technique,<sup>13 14</sup> visually evoked responses, and auditory brainstem responses. The infants were re-evaluated at 6, 9, 12, 15, and 18 months of age using a standardized neurological proforma adapted from the Ounsted (personal communication, 1978) and Touwen<sup>15</sup> examinations and by the Griffiths mental development scale.

Nuclear magnetic resonance imaging was performed in case 1 at 9 months, in case 2 at 11½ months and 15 months, and in case 3 at 15 months chronological age. The technique of nuclear magnetic resonance scanning and the normal appearances in infants have previously been described.<sup>9</sup> Inversion recovery (T<sub>1</sub> dependent) images were obtained at low ventricular level. Ventricular size and the degree of apparent myelination were compared with age matched controls.

## Results

**Ultrasound findings.** Periventricular densities were not noted until day 3 in cases 1 and 2 but were

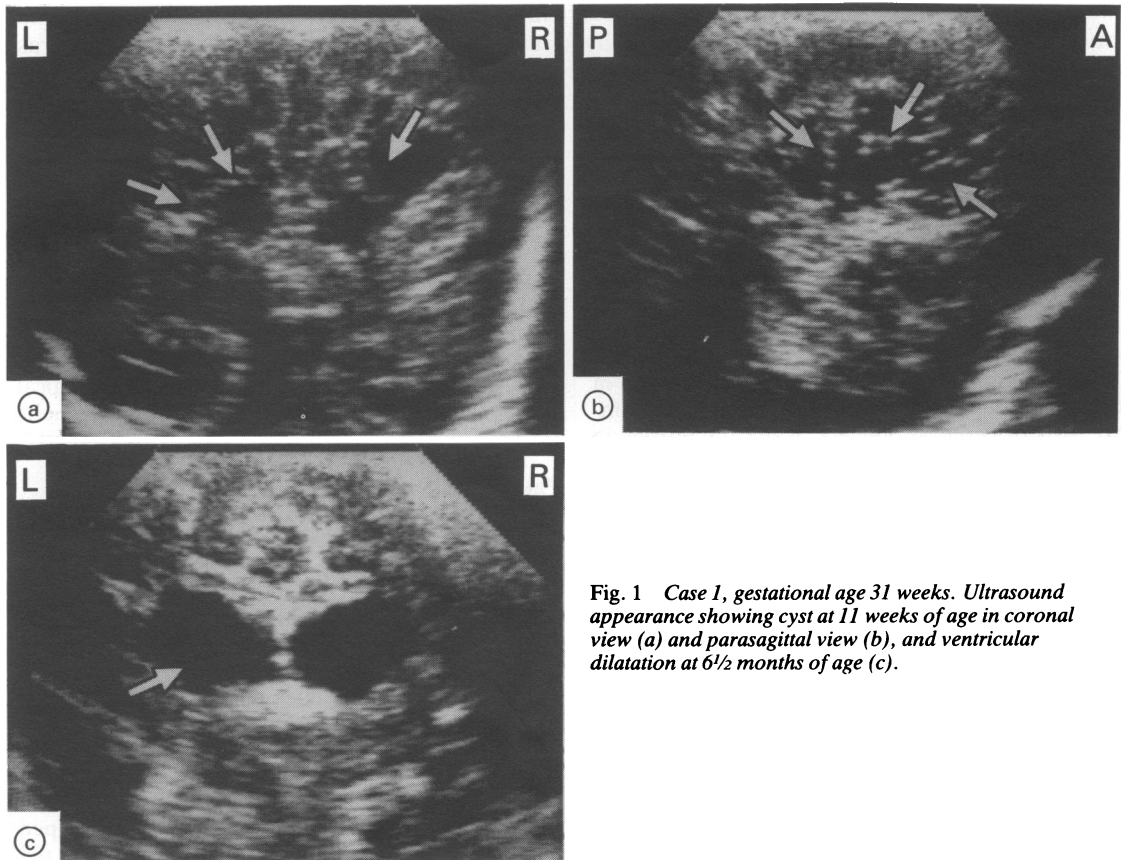


Fig. 1 Case 1, gestational age 31 weeks. Ultrasound appearance showing cyst at 11 weeks of age in coronal view (a) and parasagittal view (b), and ventricular dilatation at 6½ months of age (c).

already present on the first scan at 12 hours of age in case 3. In coronal section the echodensities seemed maximal lateral to and above the lateral ventricle, while in the parasagittal plane they were most noticeable above and posterior to the lateral ventricle.

In case 1 they were still present two days later, but after this the scan seemed normal and remained so until the infant's discharge to the referring hospital at 34 weeks conceptual age. The infant was re-admitted two weeks later because of 'collapse' and convulsions. Periventricular densities were noted the following day, but were only seen for 24 hours. The infant was referred back again to the referring hospital at 38 weeks conceptual age and was seen again four weeks later. At that time (42 weeks conceptual age) multiple cystic lesions were detected by ultrasonography throughout the cerebral parenchyma (Fig. 1a). The appearances remained unchanged for the next four weeks, but when the infant was scanned at 6 months chronological age (57 weeks conceptual age) they were no

longer visible. At this stage ventricular enlargement was noted. These appearances persisted throughout all the subsequent scans until 9 months of age after which the fontanelle closed and further scans were not possible (Fig. 1).

In case 2 the echodensities persisted for four days, after which the scan seemed normal until 33 days of age. At that time multiple cystic areas were noted adjacent to the occipital horns. These abnormalities were more prominent on the left side. There was no evidence that the cysts were communicating with the ventricles. The infant was discharged to the referring hospital the following day. When seen again at 42 weeks conceptual age the cysts were no longer visible, but asymmetrical ventricular dilatation was seen, which was more noticeable on the left. This persisted through all the subsequent scans (Fig. 2).

In case 3 the periventricular densities persisted for over two weeks, after which they became less noticeable. The wall of the posterior horn became irregular and some areas of low echogenicity could be seen around it, but in spite of repeated scanning

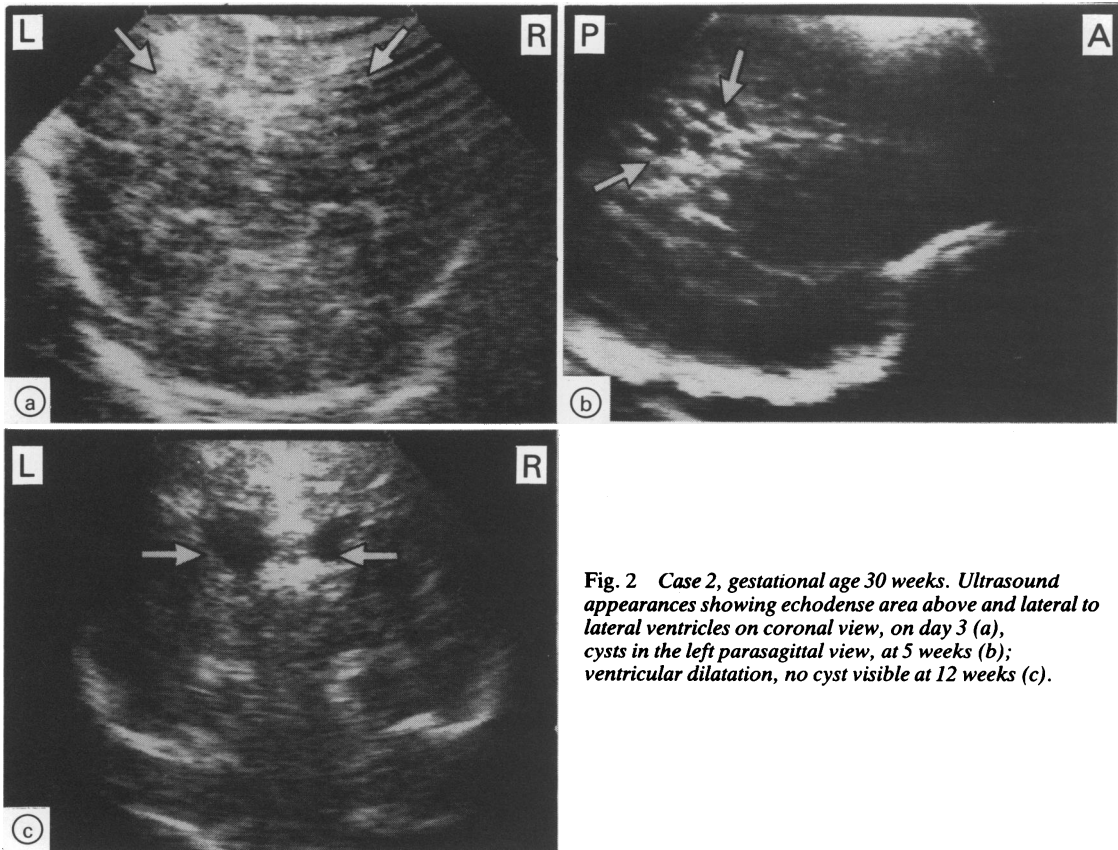


Fig. 2 Case 2, gestational age 30 weeks. Ultrasound appearances showing echodense area above and lateral to lateral ventricles on coronal view, on day 3 (a), cysts in the left parasagittal view, at 5 weeks (b); ventricular dilatation, no cyst visible at 12 weeks (c).

with a 7 MHz transducer, no definite cysts could be identified at any time. The infant was discharged from hospital at 38 weeks, and was seen again at 42 weeks conceptual age. No cysts were visible and the ventricles were considered to be within normal limits. At 6 months chronological age a moderate degree of irregular ventricular enlargement was noted, but by 9 months of age the ventricles had decreased in size (Fig. 3). None of the infants had any evidence of periventricular haemorrhage at any time.

**Neurological assessment.** All three infants showed very noticeable hypotonia and poor visual alertness when assessed at 34, 35, and 36 weeks conceptual age respectively. At 41 to 42 weeks conceptual age an abnormal tone pattern was still present in all three infants, consisting of increase in arm flexor tone, adducted thumbs, and increased extensor tone in the legs. Trunk and head control were generally poor, though some relative increase in neck extensor tone was noted. At this stage all three showed an

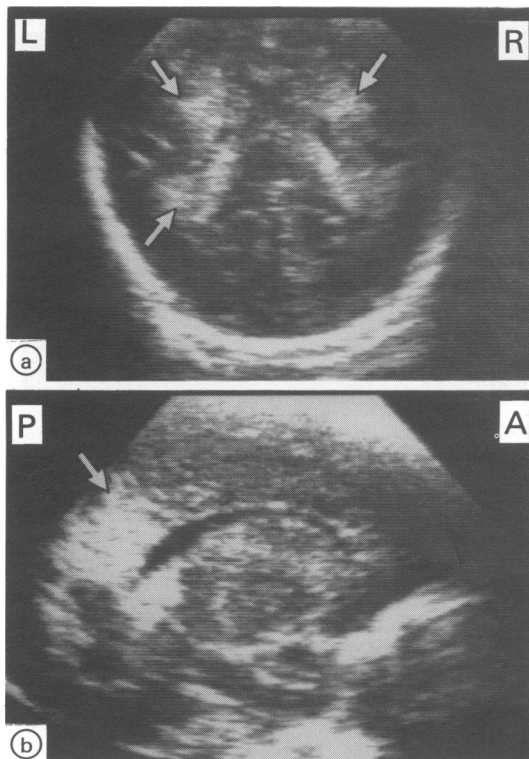


Fig. 3 Case 3, gestational age 31 weeks. Ultrasound scan showing periventricular densities on day 1. Semiaxial scan (a); parasagittal scan (b).

ability to track a bright red woollen ball, but visual attention was still poor. In cases 1 and 2 visual acuity was abnormal (160' arc) but was normal (80' arc) in case 3. Visual evoked responses were obtained in the neonatal period in cases 2 and 3. In case 2 they were absent at 35 weeks, and present but immature at 42 weeks conceptual age. In case 3 they were normal at 38 weeks conceptual age. Auditory brainstem responses were normal in all three infants.

At age 6 months all three infants showed unequivocal signs of cerebral palsy. Case 1 was quadriplegic, the other two diplegic, but with more noticeable signs on the right side in case 2 and on the left side in case 3. From 9 months onwards all three infants were considered quadriplegic. Case 1 had equally severe involvement in the arms and legs, cases 2 and 3 showed more leg than arm involvement and both still had asymmetry. The Griffiths quotients uncorrected/corrected (for prematurity) in the three infants done at various ages were as follows:

Case 1—less than 40 both uncorrected and corrected at 9, 12, and 18 months.

Case 2—47/72 at 9 months, 54/65 at 12 months, 50/56 at 15 months, 48/54 at 18 months.

Case 3—59/83 at 9 months, 61/73 at 12 months, 47/56 at 15 months, 50/56 at 18 months.

Case 1 was considered blind at one year and had absent visually evoked responses. The other two infants had an intermittent squint, but visual function seemed normal on clinical assessment and no abnormality was found on ophthalmological examination at 1 year of age.

**Nuclear magnetic resonance imaging.** Case 1, at 8 months of age, showed symmetrical enlargement of both ventricles mainly involving the posterior horn. Compared with infants of the same postmenstrual age, the scan had a grossly abnormal appearance. No myelin was recognisable (Fig. 4).

Case 2, at 11½ months of age and compared with the normal triplet, also showed considerable enlargement of the ventricular system, mainly involving the posterior horn which was more marked on the left side. The scan at 15 months showed the ventricular system unchanged. Myelination had progressed, but was still considerably delayed compared with the normal triplet. The relative delay posteriorly was now even more striking (Fig. 5).

In case 3 the scan performed at 15 months showed only mild dilatation of the posterior horn. Compared with the age matched control myelination was delayed. Again this was much more noticeable posteriorly. No asymmetry could be detected (Fig. 6).

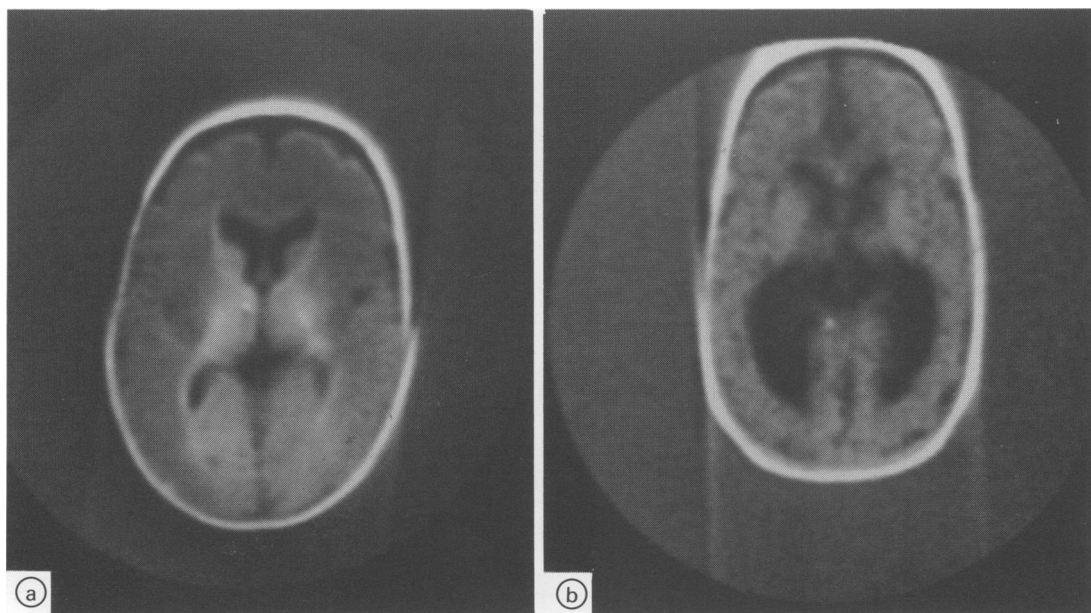


Fig. 4 Nuclear magnetic resonance inversion recovery scan of a 6 month normal control (a) and case 1 (b) at 8 months chronological age (6 months corrected for prematurity).

Note presence of myelination in thalamus, internal capsule and thalamic radiation in normal control and dilated posterior horns but no visible myelination in case 1.

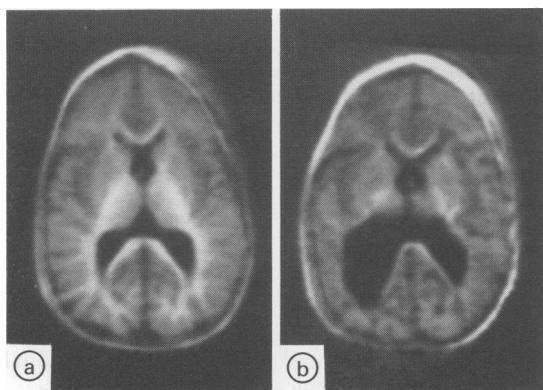


Fig. 5 Nuclear magnetic resonance inversion recovery scan of normal triplet (a) and affected triplet, case 2 (b) at 11½ months.

Normal triplet has well developed myelin in forceps minor and major and opticohalamic radiation. Abnormal triplet has asymmetrical ventricular dilatation. Some myelin is present in the forceps minor but myelination is poor in internal capsule L>R and very poor in opticohalamic radiation.

## Discussion

From our sequential ultrasound studies in these infants we were able to define four stages in the evolution of their leukomalacia: (1) congestion

(increased echogenicity), often followed by (2) relative return to normal, (3) the development of cysts, and (4) resolution of cysts but presence of ventricular enlargement. This evolution is similar to that described by Bowerman *et al.*<sup>9</sup> In our experience, however, as illustrated by case 3, it seems that cysts may not always be recognisable even by regular scanning. This could be explained by the inability of the ultrasound equipment to visualise cysts less than 2 mm in diameter. It is also possible that not all cases progress to cyst formation. The absence of cysts, however, does not imply the absence of permanent tissue destruction or future handicap as is shown in both the clinical outcome and nuclear magnetic resonance findings in this case. It is of interest that the clinical outcome in cases 2 and 3 was similar, though cyst formation and persistent ventricular dilatation were only present in case 2. Some degree of ventricular enlargement was noted in all three patients, though it was less pronounced and transient in the infant who did not seem to have any cysts. It is thus interesting to speculate whether most cases of late ventricular enlargement, particularly of the posterior horn, represent the end stages of leukomalacia. The various stages noted on the ultrasound scan also correspond fairly closely with the various stages of this condition described by

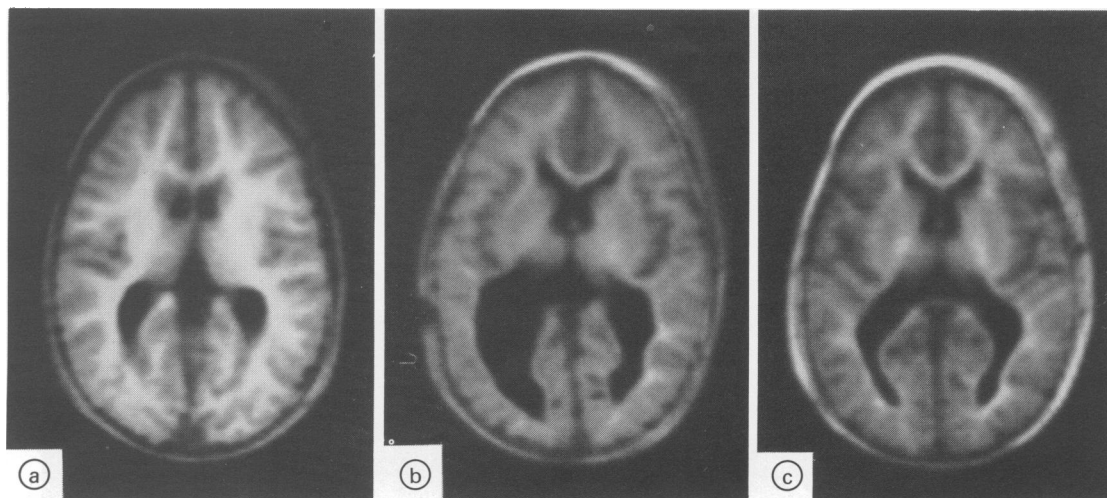


Fig. 6 Nuclear magnetic resonance inversion recovery scan showing normal triplet (a) and cases 1 (b) and 2 (c) at 15 months of age.

Note progression of myelination in both triplets compared to previous scan (Fig. 5), but case 2 still shows very poor myelination compared to its normal sibling. Delay more noticeable posteriorly. The appearances are similar but the ventricles are more normal in appearance in case 3 (c).

DeReuck *et al*<sup>16</sup> in necropsy specimens of infants who survived the neonatal period.

Although hypotension and infection have been described as causative factors in animals,<sup>17</sup> we could find no definite common predisposing cause in our patients. It is of interest that all the three patients described here and also six of seven reported by Bowerman<sup>9</sup> were infants above 30 weeks' gestation while the condition was most prevalent in Shuman's necropsy cases in infants of youngest gestational age and lowest birthweight.<sup>6</sup> The reason for this discrepancy is not quite clear but it is possible that most of the younger infants do not survive long enough for the condition to be recognised in its full form on ultrasonography.

Although it has been implied that no distinct neurological pattern can be distinguished in these infants, no previous detailed neurological assessment has been recorded, partly because in many infants the diagnosis was retrospective.<sup>9</sup> We have found that all our infants showed a similar, though not necessarily pathognomonic pattern in the neonatal period (that is initial hypotonia at 36 weeks conceptual age which was replaced by hypertonia by 40 weeks with abnormal distribution of tone, associated with irritability, tremors, and poor alertness). This pattern is different from that observed after periventricular haemorrhage. It is also of interest that although one of the infants turned out to be cortically blind later, visual function was shown clinically during the first three months of life.

The nuclear magnetic resonance findings were of special interest. In two cases the delay in myelination was mainly in the opticothalamic radiation, yet at 18 months these infants manifested mainly a motor and not a visual disability. The abnormalities were also more noticeable in the infants with cysts. Further studies will be needed to establish whether the apparent delay in myelination relates more to disturbances of tissue structure or to abnormal function.

These three patients illustrate for the first time during life the probable natural history of severe leukomalacia in infants without periventricular haemorrhage who survive the neonatal period. Further correlative studies will be needed to establish what proportion of infants with similar lesions show later handicap and to what extent the initial appearances may predict later outcome.

#### Addendum

Since the submission of this article we have had two further cases with similar clinical outcome and nuclear magnetic resonance findings at 10 months and 18 months chronological age.

We thank Dr M I Levene for the initial ultrasound scans in case 1, Miss J M Pennock for help with NMR imaging, Mr A Mushin for ophthalmological opinion, Dr S Lary for the ABRs, Professor V Dubowitz, and Dr J Wigglesworth for criticism and advice, and Mrs C Wrage for secretarial help. The work was supported by the Medical Research Council.

References

- <sup>1</sup> Parrot JM. Étude sur le ramollissement de l'encephale chez le nouveau-ne. *Arch Physiol Norm Path* 1873;**5**:59-73.
- <sup>2</sup> Parrot JM. Étude sur le ramollissement de l'encephale chez le nouveau-ne. *Arch Physiol Norm Path* 1873;**5**:176-95.
- <sup>3</sup> Parrot JM. Étude sur le ramollissement de l'encephale chez le nouveau-ne. *Arch Physiol Norm Path* 1873;**5**:283-303.
- <sup>4</sup> Banker B, Larroche JC. Periventricular leukomalacia of infancy. A form of neonatal anoxic encephalopathy. *Arch Neurol* 1962;**7**:386-410.
- <sup>5</sup> Larroche JC. *Pathology of the neonate*. New York: Excerpta Medica, 1977.
- <sup>6</sup> Shuman RH, Selednik LY. Periventricular leukomalacia. A one year autopsy study. *Arch Neurol* 1980;**37**:231.
- <sup>7</sup> Hill A, Melson GL, Clark HB. Haemorrhagic periventricular leukomalacia: diagnosis by real-time ultrasound and correlation with autopsy findings. *Pediatrics* 1982;**69**:282-4.
- <sup>8</sup> Levene MI, Wigglesworth JS, Dubowitz V. Hemorrhagic periventricular leukomalacia in the neonate. A real time ultrasound study. *Pediatrics* 1983;**71**:794-7.
- <sup>9</sup> Bowerman RA, Donn SM, DiPietro MA, D'Amato CJ, Hicks SP. Periventricular leukomalacia in the pre-term newborn infant: sonographic and clinical features. *Radiology* 1984; **151**:383-8.
- <sup>10</sup> Nwaesei CG, Pape KE, Martin DJ, Becker LE, Fitz CR. Periventricular infarction diagnosed by ultrasound. a post-mortem correlation. *J Pediatr* 1984;**105**:106-10.
- <sup>11</sup> Johnson MA, Pennock JM, Bydder GM, *et al*. Clinical NMR imaging of the brain of children. Normal and neurological disease. *A J N R* 1983;**4**:1013-26.
- <sup>12</sup> Dubowitz LMS, Dubowitz V. *The neurological assessment of the preterm and full-term newborn infant*. Clinics in Developmental Medicine 79. London: SIMP with Heinemann Medical, 1981.
- <sup>13</sup> Morante A, Dubowitz LMS, Levene MI, *et al*. The development of visual function in normal and neurologically abnormal preterm and full-term infants. *Dev Med Child Neurol* 1982; **24**:771-84.
- <sup>14</sup> Fantz RL, Fagan JF. Visual attention to size and number of pattern details by term and preterm infants during the first six months. *Child Dev* 1975;**46**:3-18.
- <sup>15</sup> Touwen BCL. *Examination of the child with minor neurological dysfunction*. Clinics in Developmental Medicine 71, 2nd ed. London: SIMP with Heinemann Medical, 1979.
- <sup>16</sup> De Reuck J, Chattha AS, Richardson EP. Pathogenesis and evolution of leukomalacia in infancy. *Arch Neurol* 1972;**27**:229.
- <sup>17</sup> Young RSK, Hernandez MJ, Yagel SK. Selective reduction of blood flow to white matter during hypotension in newborn dogs: a possible mechanism of periventricular leukomalacia. *Ann Neurol* 1982;**12**:445-8.

Correspondence to Dr L M S Dubowitz, Department of Paediatrics and Neonatal Medicine, Hammersmith Hospital, London W12 0HS.

Received 26 November 1985