

## Aetiology of idiopathic spinal deformities

There are two types of idiopathic spinal deformity—idiopathic scoliosis, and idiopathic kyphosis (Scheuermann's disease). Both conditions affect otherwise entirely normal, healthy children and while idiopathic scoliosis has two peaks of incidence during infancy and early adolescence, idiopathic kyphosis is mainly prevalent in late adolescence. Idiopathic scoliosis and kyphosis share many features, being modal at the same site with a common apex at the eighth and ninth thoracic vertebral bodies and having a similar familial trend and community prevalence rate. As will be seen, they also share a common 'pathological process'.

### Idiopathic scoliosis

Because many disorders of nerve or muscle are associated with a scoliosis most workers attempting to discover the cause of idiopathic scoliosis have focussed on neuromuscular factors. No such factors, or any other structural or functional abnormalities, have been found which are not secondary to the presence of a spinal deformity.<sup>1</sup> Moreover, with two per cent of teenagers showing an idiopathic scoliosis of 10° or more, a hitherto unknown neuromuscular disorder of epidemic proportions has to be incriminated. What has not received sufficient attention is the nature of the idiopathic scoliotic deformity.

**Three dimensional deformity.** A postero-anterior radiograph of the spine of a patient with idiopathic thoracic scoliosis (Fig. 1) shows the three components of the deformity, one of which is aetiologically crucial. The lateral curvature of the spine with rotation of the vertebrae within the curve are the two most obvious, most described, but least important features. Wherever the idiopathic scoliotic deformity occurs in the spine, for example thoracic, thoraco-lumbar, or lumbar, the direction of rotation is the same, such that the posterior elements rotate into the curve concavity while the vertebral bodies rotate anteriorly into the curve convexity. If a line, imaginary or true, is now drawn down the tips of the spinous processes throughout the curve and a similar line is drawn through the centre of the vertebral bodies, it will be seen that the line joining the spinous processes is the shorter. Therefore, the back of the spine is shorter than the front and the entire deformity must be lordotic.<sup>2</sup>

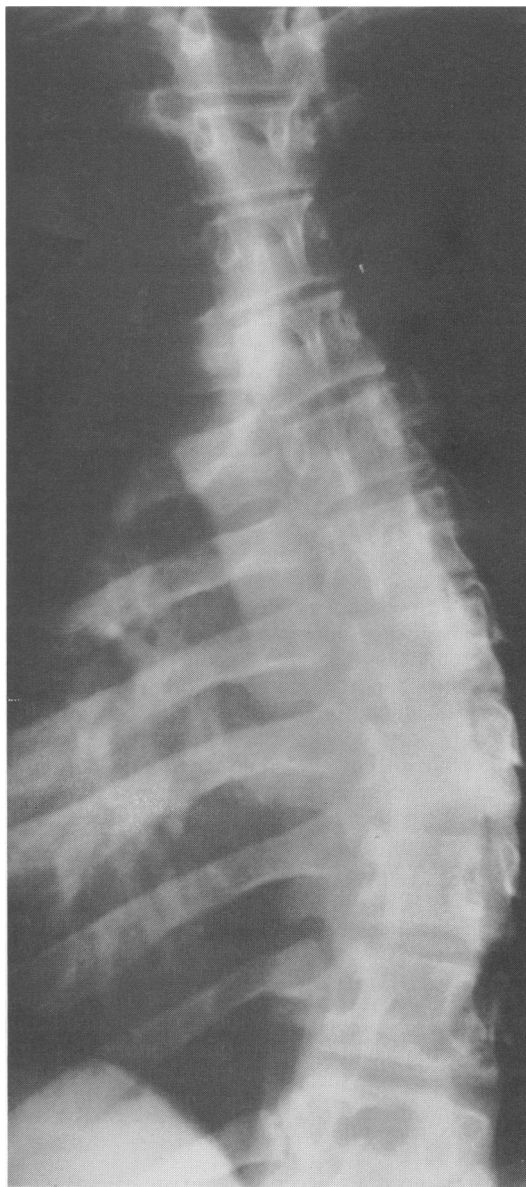
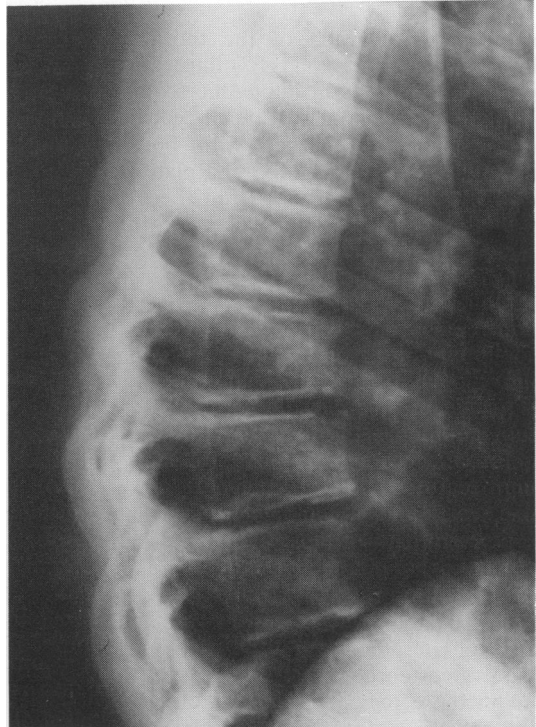
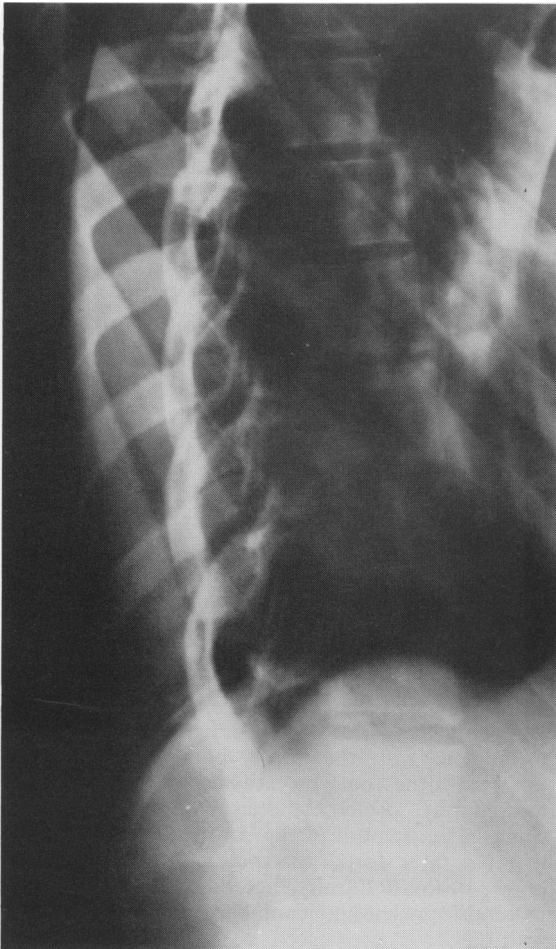


Fig. 1 *Postero-anterior radiograph of a patient with idiopathic thoracic scoliosis. There is a lateral curvature of the spine with rotation such that the spinous processes are directed towards the curve concavity.*

This elementary but important geometrical point seems to have received little emphasis, and, additionally, spurious impressions of the three dimensional nature of the idiopathic scoliotic deformity have been perpetuated by the taking of inappropriate radiographic views. Because of the rotational component a posterior-anterior radiograph of the patient must, by definition, be an oblique view of the deformity and so, of course, is a lateral view of the patient. In order to take true planar views either beam or patient must be rotated according to the amount of rotation of that particular vertebra, and when a true lateral projection of the curve apex is obtained (Fig. 2) the lordosis is clearly visualised.<sup>3</sup> It is attributable solely to sagittal spine shape, the anterior height of the vertebral bodies being greater than the posterior and any Schmorl node

formation or end plate irregularity more posteriorly. Disc height remains symmetrical and does not contribute to the lordosis.

**Normal sagittal spine shape.** The presence of a lordosis in the thoracic region implies a radical alteration in sagittal spine shape. There is normally a kyphosis here, although the spine above and below is naturally lordotic. The axis of spinal rotation runs through these sagittal spine curves so that the normal thoracic kyphosis, lying behind the axis of rotation and therefore being under tension and not compression, is protected from rotation. In the presence of a thoracic lordosis the axis of spinal rotation will run behind the front of the vertebral bodies, which, particularly on forward flexion, undergo compression and must rotate to the side to



**Fig. 2** (left) True lateral radiograph of the apical region of an idiopathic thoracic scoliosis. There is a lordosis at bony level.

(above) Lateral radiograph of the thoracic spine of a patient with Scheuermann's disease. There is a kyphosis at bony level.

be accommodated (the rotational prominence in idiopathic scoliosis is much more noticeable on forward flexion).

In the cervical and lumbar regions lordoses are normal but they are protected from rotational instability by having a large amount of segmental movement available, by the presence of powerful muscles and fascial systems behind them, and by squat vertebrae with a broad front which tend to resist rotation. Moreover, these are at the extreme ends of the spine which naturally tend to remain facing the front. Idiopathic scoliosis may occur, however, if the lumbar lordosis is increased or if stiffness is superimposed. Thus, while the term 'kypho-scoliosis' is what most practitioners recall of spinal deformities, it is a combination which cannot and does not exist.<sup>2</sup>

#### **Idiopathic kyphosis (Scheuermann's disease)**

The lateral radiograph of the thoracic spine in Scheuermann's disease (Fig. 2) illustrates the same vertebral changes as in idiopathic scoliosis, but in the opposite direction with much reduced anterior vertebral height compared with posterior, and Schmorl node formation and end plate irregularity being situated anteriorly.<sup>4</sup> Again these are otherwise entirely healthy normal children. If the process of vertebral wedging is asymmetric (for example the right side of the vertebra being more affected than the left) then a mild scoliosis can exist at the same site as the kyphosis but with the spinous processes rotated towards the curve convexity, the opposite direction to that occurring in idiopathic scoliosis, as would be entirely expected with an asymmetric kyphosis. The anteriorly situated axis of spinal rotation ensures, however, that the kyphotic region itself does not rotate. Where a severe scoliosis can occur in the spine of a patient with Scheuermann's disease, is below the area of kyphosis, where there is a compensatory lordosis, which as in idiopathic scoliosis is vulnerable to rotation. Therefore in more than 50% of patients with Scheuermann's disease there is a true idiopathic scoliotic deformity apical some five vertebrae below the apex of the kyphosis. Thus in these patients the same otherwise normal child has the deformities of both Scheuermann's disease and idiopathic scoliosis but not at the same site. This lends strong support to a common pathological process.

#### **Normal lateral spinal profile**

The normal thoracic kyphosis extends from the third to the tenth thoracic vertebrae, those above belong-

ing to the cervical lordosis and those below belonging to the lumbar lordosis. During late childhood and early adolescence, between the ages of 8 and 12 years, the normal thoracic kyphosis reduces in size and this occurs at the same time in both boys and girls.<sup>5</sup> Thus, during this period, those with an excessive amount of flattening become truly lordotic with obvious rotational consequences, and in girls this process is occurring during the phase of increased growth velocity of early adolescence. This explains why girls are particularly vulnerable to the deformity of idiopathic scoliosis. By the time boys go through their peak adolescent growth velocity the thoracic kyphosis has become fully re-established: they are relatively protected from idiopathic scoliosis, therefore, but are particularly prone to the opposite deformity of Scheuermann's disease, which is not prevalent until later adolescence. Lateral profile is governed, like other aspects of body shape, genetically, and this explains the familial trend observed in both idiopathic scoliosis and Scheuermann's disease.<sup>6</sup> The scoliotic patient, however, with a flattened lateral profile seems marginally taller than a peer, without there being any other growth abnormality, because of the uncoiling effect.

#### **Treatment considerations**

The kyphotic spine clearly requires extension so that the anterior aspects of the growth plates can be unloaded, and if a brace or cast which maintains spinal extension is applied then there is true physiological correction of sagittal spinal shape. Scheuermann's disease, therefore, is eminently treatable conservatively. The thoracic lordosis of idiopathic scoliosis would, however, require flexion and this is precisely when the deformity is rotationally unstable. Accordingly, the deformity of idiopathic scoliosis is not treatable conservatively<sup>2</sup> and, while it can be envisaged that the wearing of a brace 23 hours a day will at least prevent the patient from the unfavourable consequences of leaning forward, there is no clear evidence that it alters the natural history of the condition.<sup>7</sup> The deformity of idiopathic scoliosis can, therefore, only be corrected surgically. Harrington instrumentation, which is attached above and below the area of rotational deformity, cannot be expected to alter the rotational prominence with which every teenager presents and this is borne out by studies using computed tomography.<sup>8</sup> Only by altering the shape of the spine in the sagittal plane can the normal thoracic kyphosis be restored, the spine derotated, all three planes of the deformity thereby corrected, and the patient's presenting complaint effectively dealt with.<sup>4</sup>

**References**

- <sup>1</sup> Zetterberg C, Aniansson A, Grimby G. Morphology of the paravertebral muscles in adolescent idiopathic scoliosis. *Spine* 1983;**8**:457–62.
- <sup>2</sup> Dickson RA, Lawton JO, Archer IA, Butt WP. The pathogenesis of idiopathic scoliosis. *J Bone Joint Surg* 1984;**66B**:8–15.
- <sup>3</sup> Deacon P, Flood BM, Dickson RA. Idiopathic scoliosis in three dimensions. A radiographic and morphometric analysis. *J Bone Joint Surg* 1984;**66B**:509–12.
- <sup>4</sup> Dickson RA, Lawton JO, Butt WP. The pathogenesis of idiopathic scoliosis. In: Dickson RA, Bradford DS, eds. *Management of spinal deformities*. London: Butterworths, 1984:1–37.
- <sup>5</sup> Willner S. Spinal pantograph—a non-invasive technique for describing kyphosis and lordosis in the thoraco-lumbar spine. *Acta Orthop Scand* 1981;**52**:525–9.
- <sup>6</sup> Wynne-Davies R. Familial (idiopathic) scoliosis. A family survey. *J Bone Joint Surg* 1968;**50B**:24–30.
- <sup>7</sup> Kaiser RP, Shufflebarger HL. The Milwaukee brace in idiopathic scoliosis. Evaluation of 123 completed cases. *Clin Orthop* 1976;**118**:19–24.
- <sup>8</sup> Aaro S, Dahlborn M. The effect of Harrington instrumentation on the longitudinal axis rotation of the apical vertebra and on the spinal and rib-cage deformity in idiopathic scoliosis studied by computer tomography. *Spine* 1982;**7**:457–62.

R A DICKSON  
*Department of Orthopaedic Surgery,  
St James's University Hospital,  
Leeds LS9 7TF*

---

**Associate Editor**

In recent years neonatology has been the scene of some of the most vigorous change and active research within paediatrics. We receive a very large number of good, original articles relating to the newborn and in order to deal with these more effectively and to strengthen their presentation we are appointing an Associate Editor for fetal and neonatal medicine. Dr Malcolm Chiswick, a member of the Editorial Committee, is taking on this task and will correspond directly with authors and

referees in connection with neonatal articles and will represent those interests to the Editors. Dr Chiswick is a consultant paediatrician at the North West Regional Perinatal Centre, St Mary's Hospital, Manchester and has been a member of the National Maternity Services Advisory Committee producing the recent report on neonatal care. He has written many papers and books relating to perinatal medicine; we welcome the expertise and help that he will provide.