

weak. At 9 months the spastic hemiparesis on the left side became more evident. Head circumference continued to grow along the 25th percentile, and echoencephalography confirmed that the width of the left ventricle and the porencephalic cyst had not increased in size. At 1 year the child was alert, was able to call 'daddy', and attempted to stand. He could walk freely at 16 months with a slight limp in the left leg.

Discussion

Large intracerebral and intraventricular haemorrhage has been reported to be fatal in 76–100% of cases.^{1,2} Virtually all surviving patients have moderate to severe neurological deficits,¹ and up to 58% of them develop hydrocephalus.¹ It is unclear how much of the neurological deficit after such a haemorrhage is due to immediate parenchymal damage and how much is due to hydrocephalus.^{1,6} Shunt complications can make matters worse.

Directly evacuating the parenchymal haemorrhage and intraventricular blood clots theoretically reduced two pathogenetic mechanisms. Firstly, pressure reduction alleviated ischaemic damage to the perifocal parenchyma; the rapid neurological improvement of our patient six hours postoperatively might support this. Secondly, evacuation of the blood clots possibly helped to arrest developing hydrocephalus which might have been produced by

temporary occlusion of the interventricular foramina. As the dilatation of the ventricles was arrested at a moderate stage, definitive shunting or lumbar punctures were not necessary.

It is impossible to determine whether evacuation of the haemorrhage influenced the outcome at 16 months. Potential benefit of the procedure may be confined to the rapid relief of abnormal neurological signs in the acute stage of intracerebral and intraventricular haemorrhage, or it may also reduce the incidence of progressive post-haemorrhagic obstructive hydrocephalus.

References

- 1 Allan WC, Volpe JJ. Periventricular—intraventricular hemorrhage. *Pediatr Clin North Am* 1986;**36**:47–63.
- 2 Allan WC, Dransfield DA, Tito AM. Ventricular dilation following periventricular—intraventricular hemorrhage: outcome at age 1 year. *Pediatrics*, 1984;**73**:158–62.
- 3 Volpe JJ. Intraventricular hemorrhage in premature infants. *Pediatr Reviews* 1980;**2**:145.
- 4 Auer LM. Endoscopic evacuation of intracranial hematomas. *Neurosurgons* 1987;**6**:381–8.
- 5 Auer LM. Endoscopic evacuation of intracerebral haemorrhage. *Acta Neurochir (Wien)* 1985;**74**:124–8.
- 6 Cooke RWI. Early prognosis of low birth weight infants treated for progressive posthaemorrhagic hydrocephalus. *Arch Dis Child* 1983;**58**:410–4.

Correspondence and requests for reprints to Dr E Ritschl, Department of Paediatrics, University of Graz, Auenbruggerplatz, A-8036 Graz, Austria.

Received 12 May 1987

Atrial natriuretic peptide and patent ductus arteriosus in preterm infants

W RASCHER AND H W SEYBERTH

Department of Pediatrics, Children's Hospital of the University of Heidelberg, Heidelberg, West Germany

SUMMARY Preterm infants with symptomatic patent ductus arteriosus had considerably raised plasma concentrations of atrial natriuretic peptide. Surgical ligation of the patent ductus arteriosus was associated with an immediate fall in plasma atrial natriuretic peptide concentration. Thus left to right shunting and left atrial distension may cause atrial natriuretic peptide release in preterm infants with patent ductus arteriosus.

The existence of a natriuretic hormone released by atrial distension and volume expansion was post-

ulated more than 30 years ago. Recently such a hormone, atrial natriuretic peptide, was discovered.¹ It is produced by mammalian atria, stored in granules of atrial myocytes and released into the circulation when volume expands and the atrium distends.^{1,2}

Preterm infants with symptomatic patent ductus arteriosus are a good group in which to study atrial natriuretic peptide release. In these infants arterial blood is shunted from the aortic root into the pulmonary circulation leading to an increase in pulmonary and left atrial blood volume and to a considerable rise in left atrial pressure.³ Thus if atrial distension is a major stimulus for atrial

natriuretic peptide release, patent ductus arteriosus ought to be associated with raised concentrations of atrial natriuretic peptide and closure of the ductus should result in a drop in plasma atrial natriuretic peptide concentration.

Methods

Six preterm infants with symptomatic patent ductus arteriosus who required assisted ventilation underwent surgical ligation. The diagnosis of symptomatic patent ductus arteriosus with definite left to right shunting was based on the usual clinical criteria of typical left subclavicular murmur, increased peripheral pulses, radiological evidence of cardiomegaly, and increased pulmonary vascular markings. All infants were also evaluated by two dimensional echocardiography to show the enlarged left atrium and to exclude structural congenital heart disease. Gestational age at birth ranged between 26 and 34 weeks (median 30), birth weight between 850 and 1520 g (median 1175), and age at the time of operation between 7 and 13 days (median 10). Patent ductus arteriosus was confirmed and ligated through a left lateral thoracotomy. At operation, ductal diameter was at least the same as that of the aorta.

A 1.5 ml sample of blood was taken into tubes coated with edetic acid for determination of plasma atrial natriuretic peptide concentration. Routine blood sampling was also done about six hours before operation, and between 16 and 24 hours afterwards. Blood was centrifuged immediately and plasma stored at -20°C until assayed.

For comparison, plasma atrial natriuretic peptide concentrations were measured in 14 preterm infants (gestational age at birth from 29 to 34 weeks, median 32; age at blood collection from 7 to 14 days, median 10). Apart from prematurity they were healthy and did not require assisted ventilation whereas all the infants with patent ductus arteriosus required it throughout the study. Plasma atrial natriuretic peptide concentrations were measured by radioimmunoassay after extraction and corrected for incomplete recovery as recently described.⁴ Results were expressed as mean (SD) and statistical comparisons were made by analysis of variance.

Results

Mean (SD) plasma atrial natriuretic peptide concentration in premature infants with symptomatic patent ductus arteriosus was considerably raised compared with that of age matched 'healthy' preterm neonates, being 379.5 (76.5) and 40.9 (21.7) fmol/ml, respectively ($p < 0.01$).

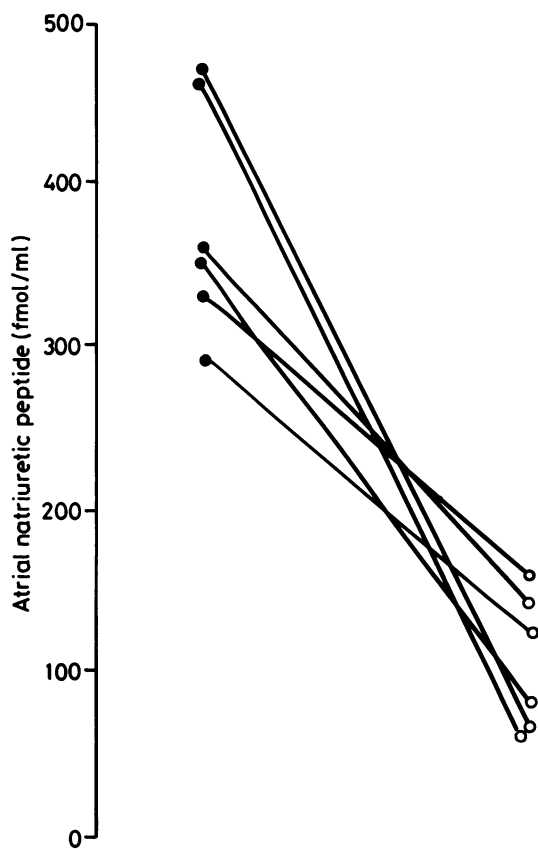


Figure Plasma concentration of atrial natriuretic peptide in six preterm infants before ● and after ○ surgical ligation of patent ductus arteriosus.

Surgical ligation of patent ductus arteriosus was associated with a fall of plasma atrial natriuretic peptide concentrations in all six infants (figure). The mean (SD) plasma atrial natriuretic peptide concentration postoperatively was 107.8 (41.2) fmol/ml ($p < 0.01$). Ligation did not influence serum concentrations of sodium (135.0 (5.6) and 135.3 (5.6) mmol/l), protein (47.7 (9.1) and 47.0 (4.7) g/l), or creatinine (1.5 (0.6) and 1.4 (0.5) mg/dl).

Discussion

Mechanisms by which atrial natriuretic peptide is released into the circulation have not yet been well defined in infants and children. We have recently shown that atrial natriuretic peptide is raised in children with fluid overload due to end stage renal disease when compared with children with chronic renal failure without volume expansion, and with

normal healthy children.⁴ The association between the fall in atrial natriuretic peptide concentration and decrease in body weight after volume reduction by haemodialysis suggests that in children volume expansion releases atrial natriuretic peptide. In preterm infants plasma atrial natriuretic peptide concentrations are considerably raised on the second day of life and decrease to normal within 2 or 3 weeks of age.⁵ Concentrations are raised in premature infants with increased sodium intake and are related to sodium excretion.⁶

The localisation of the sensor of atrial natriuretic peptide release has not yet been clearly defined in clinical studies. Interruption of left to right shunting and decreased left atrial distension by surgical closure of the patent ductus arteriosus seems to be a good clinical model in which to study mechanisms of atrial natriuretic peptide release in preterm infants. The immediate drop in plasma atrial natriuretic peptide concentration by 72% when the ductus is closed in preterm infants may indicate that atrial distension due to left to right shunting is responsible for increased atrial natriuretic peptide release in preterm infants with patent ductus arteriosus.

Raised plasma atrial natriuretic peptide concentrations in preterm infants with patent ductus arteriosus may help to preserve renal function and to antagonise the renal vasoconstrictor hormones that are raised in preterm infants with symptomatic patent ductus arteriosus. Although we did not measure renal function in the present study, indirect evidence (unchanged body weight and stable plasma concentrations of sodium, protein, and creatinine)

suggest that an appreciable reduction in urine flow did not occur in our preterm infants after closure of the ductus. This may be due to the fact that renal vasoconstrictor hormone concentrations fall at the same time and renal perfusion improves after abolishing the ductal steal phenomenon.

This study was supported by a grant from the Deutsche Forschungsgemeinschaft (Ra 326/1-2) and HW Seyberth is in receipt of a Heisenberg Stipend from the Deutsche Forschungsgemeinschaft. We thank Dr RE Lang, German Institute for High Blood Pressure Research for developing the atrial natriuretic peptide radioimmunoassay and Mrs R Pöhler for technical assistance.

References

- 1 Needleman P, Greenwald JE. Atriopeptin: a cardiac hormone intimately involved in fluid, electrolyte, and blood pressure homeostasis. *N Engl J Med* 1986;**314**:828-34.
- 2 Lang RE, Thölken H, Ganten D, Luft FC, Ruskoaho H, Unger T. Atrial natriuretic factor - a circulating hormone stimulated by volume loading. *Nature* 1985;**314**:264-6.
- 3 Rudolph AM. The ductus arteriosus and persistent patency of the ductus arteriosus. In: Rudolph AM, ed. *Congenital diseases of the heart*. Chicago: Year Book Medical Publishers, 1976:169-201.
- 4 Rascher W, Tulassay T, Lang RE. Atrial natriuretic peptide in plasma of volume-overloaded children with chronic renal failure. *Lancet* 1985;**ii**:303-5.
- 5 Tulassay T, Rascher W, Hajdu J, Lang RE, Tóth M, Seri I. Influence of dopamine on atrial natriuretic peptide in premature neonates. *Acta Paediatr Scand* 1987;**76**:42-6.
- 6 Tulassay T, Rascher W, Seyberth HW, Lang RE, Tóth M, Sulyok E. The role of atrial natriuretic peptide in the sodium homeostasis of premature infants. *J Pediatr* 1986;**109**:1023-7.

Correspondence to Dr W Rascher, Universitäts-Kinderklinik, Im Neuenheimer Feld 150, D-6900 Heidelberg, FRG.

Received 9 June 1987

Intestinal obstruction due to ingested Vaseline

D W GOH AND R G BUICK

The Children's Hospital, Birmingham

SUMMARY A case of intestinal obstruction due to ingested Vaseline (white soft paraffin) is described. While intestinal obstruction due to bezoars and impacted foodstuffs is uncommon, though well recognised, we know of no previous reports of obstruction caused by semisolid mineral matter.

Case report

A 13 month old girl was admitted having swallowed about 50 g of Vaseline. After confirmation from the

Regional Poisons Unit that this substance was non-toxic she was observed overnight and discharged home the next day, well and asymptomatic.

The following day she became irritable and unwell, began vomiting, and developed abdominal distension. She was readmitted to hospital four days later, having had no bowel action for two days. Her condition deteriorated and she was then transferred to this unit.

She was obviously unwell, with a temperature of 39°C; she was dehydrated and tachypnoeic with grunting, shallow respiration, and pronounced subcostal and intercostal recession. The abdomen was grossly distended and tympanitic with general