

Annotations

Inherited peroxisomal disorders involving the nervous system

For genetic reasons peroxisomes may be absent or lack one or more of their enzymes. The result may be subtle and long delayed, but is often catastrophic and immediately recognisable as a serious disorder at birth. The trouble for the clinician is that it is often not possible to make a diagnosis unless the right tests are thought of: these tests are not part of routine 'metabolic screens.' It is first necessary to frame the question 'could this be a peroxisomopathy?' The object of this annotation is to help with when and how to answer this question.

Peroxisomes

Peroxisomes are subcellular organelles with a single membrane which occur in every cell apart from the mature erythrocyte. They are seen best by appropriate preparation of a biopsied liver specimen where they are about 0.5 μ in diameter and round on section. A high concentration is inferred in other tissues including proximal renal tubules, adrenal cortex, brown fat (particularly in cold adaptation), and myelin forming glia. Peroxisomes, in addition to the peroxidation from which the name derives, are involved in numerous metabolic processes. For clinical diagnostic purposes the most important enzymatic actions to be aware of are the β oxidation of very long chain fatty acids (VLCFA), the synthesis of bile acids, and the synthesis of ether glycerolipids (plasmalogens), the latter involving the enzyme acyl CoA: dihydroxyacetone phosphate acyl transferase which is commonly known as DHAP-AT. Although not conclusively proved at the time of writing, the location of the phytanic acid oxidase which is deficient in Refsum disease must also be in the peroxisome.

Classification of inherited peroxisomal disorders

Inherited peroxisomal disorders are classified into three groups. In group 1 are conditions in which peroxisomes are absent or greatly diminished, with a generalised impairment of peroxisomal functions. In group 2 peroxisomes are present but there is an impairment of some but not all peroxisomal functions. In group 3 only a single peroxisomal function is

defective. Because of the great importance of the peroxisomal enzymes involved in the β oxidation of VLCFA and the use of measurements of VLCFA in diagnosis, this group is itself subdivided. Group 3A includes those conditions in which VLCFA oxidation is impaired and thus VLCFA accumulates, and group 3B those in which the single enzyme defect is of another sort.

GENERALISED PEROXISOMAL DISORDERS (GROUP 1)

The now classical example is the cerebro-hepato-renal syndrome of Zellweger.^{1 2} The typical neonate is more dysmorphic than a baby with Down's syndrome with high forehead and huge fontanelle with metopic extension. Inactivity is even greater than in the Prader-Willi syndrome and hypotonia especially of the muscles of the neck is profound. Epileptic seizures commonly begin in the neonatal period. Because of general unresponsiveness it is difficult to tell that the infant is blind and deaf, but the electroretinogram (ERG) and brainstem auditory evoked responses (BAER) are both flat. The liver is firm and the renal cortex is echogenic. Calcification of the patellae and other cartilages may overshadow the considerable retardation of the bone age. Malformations of the heart or gut may be present and dominate the clinical picture. After early death, general pathology shows hepatic fibrosis, renal cysts, and small adrenals with striated inclusions (the striations representing VLCFA). The brain shows both malformation and degeneration. All the features of Zellweger syndrome appear to stem from a virtual lack of peroxisomes and their functions.

More difficult to recognise in group 1 are the milder variants of Zellweger syndrome. Complementation studies suggest that mild Zellweger syndrome, infantile Refsum disease, and hyperpilocacidaemia may be the same disorder.³ Four recent publications include photographs of the faces of these children up to age 13 and the similarities are considerable.⁴⁻⁷ Characteristically the lobule of the ear is unformed and the palate high arched. Presentation may not be with neurological problems but rather with failure to thrive and steatorrhoea, and low plasma cholesterol and vitamin E concentrations. Clues to the peroxisomal aetiology come from the

palpable liver, the retarded bone development, and the defects of vision (retinal) and hearing (sensori-neural) which become apparent. Dots of pigment on the retina are characteristic. With time, development ceases and although these children may be mobile they show considerable mental handicap perhaps with autistic features. Originally some of these children were regarded as having a variant of Refsum disease (see below) but it is now clear that when there is a generalised peroxisomal deficiency phytanic acid from the diet accumulates with age.⁸

The last of the current members of group 1 goes by the title of neonatal adrenoleukodystrophy (NALD). It got this name because of its pathological resemblance to X linked adrenoleukodystrophy the first member of group 3A. Completion studies indicate that it is genetically distinct from the others.³ Affected infants may be hypotonic and have neonatal seizures but early disorder of development may be mild. Dysmorphic features are also slight—facial photographs are included in three recent reports.⁹⁻¹¹ Retinal blindness may be the over-riding early feature so that the infant is regarded as having Leber's amaurosis.¹² Later, neuropathy is common.^{9, 13} The most characteristic part of the history, however, is that after even a few years of progress there is regression, often abruptly after a febrile illness, with loss of skills and neurological functions and fatal outcome.

IMPAIRMENT OF SOME PEROXISOMAL FUNCTIONS (GROUP 2)

Rhizomelic chondrodysplasia punctata (RCDP) is the only certain disorder having a defect in a selected number of peroxisomal functions,¹⁴ but it may be that the Conradi-Hünemann form¹⁵ will also become included. Infants with RCDP should be easily recognisable by the proximal shortening of their limbs and epiphyseal calcifications, cataracts, and (if survival is sufficiently long) evidence of mental handicap.

DEFECTS OF A SINGLE PEROXISOMAL ENZYME (GROUP 3)
Our knowledge of disorders of a single peroxisomal function (group 3) is expanding at a great rate. This is primarily so in group 3A which now contains four conditions having a primary defect in VLCFA metabolism. The identity of the respective enzyme deficiencies has been established in little over a year.

Disorders with accumulation of VLCFA (group 3A)
Adrenoleukodystrophy (ALD) presents in boys as either school failure due to central demyelination (visible on a computed tomogram) or as adrenal insufficiency, hence the old name Addison-Schilder

disease. A remarkable feature of this X linked disorder is extreme variability within pedigrees,¹⁶ so that later onset adrenomyeloneuropathy (presenting with spastic paraparesis) or adult onset ALD may coexist. People with the gene defect may even be asymptomatic beyond middle age. The similarity of the neuropathology to aggressive multiple sclerosis and the presence of oligoclonal bands in the cerebrospinal fluid has supported the idea that for childhood ALD to occur an autoimmune mechanism is necessary in addition to the genetic defect in VLCFA metabolism. That defect has now been identified as of a specific peroxisomal acyl-CoA synthetase.¹⁷ The site of the gene on Xq28 is adjacent to the genes for red and green colour blindness which may be simultaneously deleted.¹⁸

Defects of β oxidation: 'pseudo-Zellweger syndrome', 'pseudo-NALD', etc

In normal VLCFA metabolism the acyl-CoA synthesised by the enzyme deficient in ALD is oxidised by three peroxisomal enzymes in sequence: acyl-CoA oxidase ('oxidase'), bifunctional protein, and 3-oxoacyl-CoA thiolase ('thiolase').

The first disorder now known to lack one of these enzymes was originally labelled pseudo-Zellweger syndrome¹⁹: it was later discovered that the child in question lacked only the protein of the thiolase enzyme.²⁰ The clinical and pathological features resembled Zellweger syndrome except that dysmorphic features were not so appreciable and there was no calcific stippling. A further family has been described²¹ in which although the thiolase protein was present as shown by immunoblot, the duodenal bile acid pattern indicated thiolase deficiency and was identical to that of the infant with pseudo-Zellweger syndrome (PT Clayton, personal communication). Except for the huge fontanelle (in keeping with a severely delayed bone age), dysmorphic signs were slight in this family (figure). In a further child with evidence of thiolase inactivity, calcific stippling of the patellae was present (MD King, personal communication). All of these infants had neonatal onset seizures and profound hypotonia (figure).

Isolated deficiency of the oxidase protein leads to a clinical course like NALD, entitled pseudo-NALD.²² Pseudo-NALD was also the name given to the condition of a similar patient in whom the pathology also resembled NALD.²³ Later, the oxidase protein was found to be present,²⁴ but presumably it is present in an inactive form.

The last of the three selective β oxidation disorders, bifunctional protein deficiency, has now been discovered (HW Moser, personal communication) in a patient with 'clinical clues' (see below).

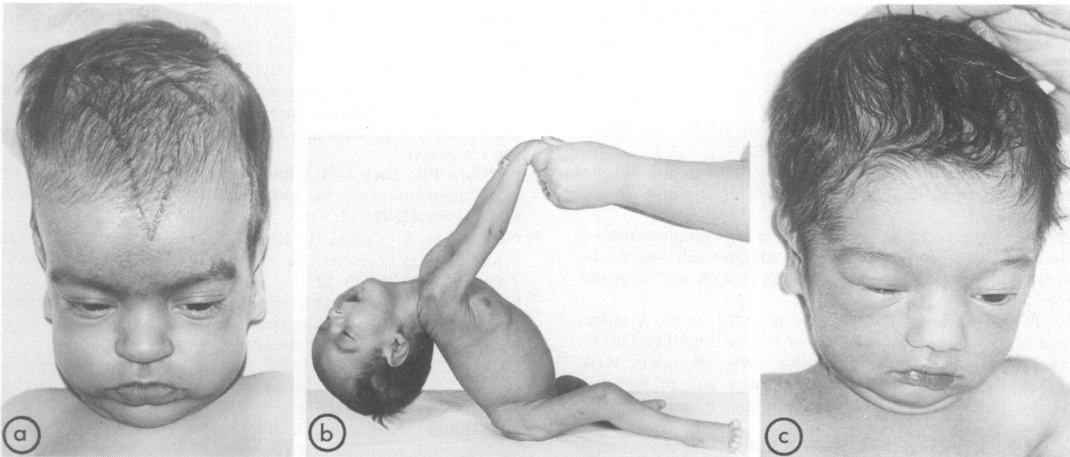


Figure Siblings with defective thiolase: (a) fontanelle and high forehead aged 3 months; (b) extreme neck hypotonia (same day as (a)); and (c) brother aged 1 week; dysmorphism minimal. Note need for handsupport in supine position in (a) and (c).

Refsum disease (group 3B)

The only reasonably established group 3B disorder affecting the nervous system is Refsum disease which with retinitis pigmentosa, neuropathy, and deafness may present in mid childhood. Here the isolated defect is of (presumed) peroxisomal phytanic oxidase.

Clinical clues to a possible peroxisomopathy

Pointers to one or other peroxisomal disorder include: large fontanelle, absent ear lobules, neck hypotonia, early seizures, developmental standstill delay or arrest, pigmentary retinopathy (with a low ERG), sensorineural deafness (with low BAER), hepatomegaly (with or without fibrosis), unexplained hypocholesterolaemia or hypovitaminosis E, and calcific stippling of epiphyses.

Tests in suspect patients

Measurement of the enzyme DHAP-AT in fibroblasts or thrombocytes should detect all the generalised peroxisomal disorders (group 1),²⁵ and those in group 2. The concentration of VLCFA is raised in plasma and fibroblasts in all the generalised peroxisomopathies (group 1) and in all those in group 3A. Abnormal bile acids in urine,²⁶ plasma,²⁷ and bile should be detected (at any rate in the young patient) in all of group 1; in those with absent or defective thiolase the pattern is different and may be specific. Bile acids are normal in ALD and in oxidase deficiency; the situation in bifunctional protein deficiency is not yet known. A properly prepared

liver biopsy specimen in group 1 will show absent or grossly deficient peroxisomes, whereas in group 3A many of the peroxisomes are large (up to $1\ \mu$)^{19 21 22 24} and they may be odd shaped. Phytanic acid is of course raised in the plasma in Refsum disease, but after infancy it will be raised in all the ('mild') group 1 disorders and in RCDP.

Treatment

Specific therapeutic possibilities are at present limited except in Refsum disease where low phytanic acid diet with or without plasmapheresis and low fat diet has proved effective. Low phytanic acid diet has also been used in two children with mild group 1 disorder ('infantile Refsum').²⁸ The neurological improvement reported, including possible arrest of progressive neuropathy, needs confirmation by further studies. However, as in all chronic disorders affecting the nervous system, non-specific treatment (for example, phenytoin for seizures) may help. More specifically, vitamin E supplementation is reasonable in those older children with a secondary deficiency. Attempts to abort ALD by the rigorous low VLCFA diet, oleate and erucate supplements, and plasmapheresis have not yet shown convincing benefit. When there is an affected family member, prevention is possible in all the group 1, 2, and 3A disorders, in that early prenatal diagnosis can be made by DHAP-AT analysis in groups 1 and 2 and by VLCFA measurements in groups 1 and 3A.

I would like to thank Peter Barth, Guy Besley, Peter Clayton, David Doyle, Brian Harding, Brian Lake, Mary King, Ann Moser,

Hugo Moser, Bwee-Tien Poll-The, Frank Roels, Ruud Schutgens, John Tolmie and Ronald Wanders for helpful discussions and insights.

References

- ¹ Opitz JM. The Zellweger syndrome: book review and bibliography. *Am J Med Genet* 1985;**22**:419–26.*
- ² Zellweger H. The cerebro-hepato-renal (Zellweger) syndrome and other peroxisomal disorders. *Dev Med Child Neurol* 1987;**29**:821–9.
- ³ Tager JM, Westerveld A, Strijland A, et al. Complementation analysis of peroxisomal diseases by somatic cell fusion. In: Fahimi HD, Sies H, eds. *Peroxisomes in biology and medicine*. Berlin: Springer-Verlag, 1987:353–7.
- ⁴ Barth PG, Schutgens RBH, Bakkeren JAJM, et al. A milder variant of Zellweger syndrome. *Eur J Pediatr* 1985;**144**:338–42.
- ⁵ Blecker-Wagemakers EM, Oorthuys JWE, Wanders RJA, Schutgens RBH. Long-term survival of a patient with the cerebro-hepato-renal (Zellweger) syndrome. *Clin Genet* 1986;**29**: 160–4.
- ⁶ Budden SS, Kennaway NG, Buist NRM, Poulis A, Weleber RG. Dysmorphic syndrome with phytanic oxidase deficiency, abnormal very long chain fatty acids, and pipercolicacidemia: studies in four children. *J Pediatr* 1986;**108**:33–9.
- ⁷ Poll-The BT, Saudubray JM, Ogier HAM, et al. Infantile Refsum disease: an inherited peroxisomal disorder. *Eur J Pediatr* 1987;**146**:477–83.
- ⁸ Wanders RJA, Smit W, Heymans HSA, et al. Age-related accumulation of phytanic acid in plasma from patients with the cerebro-hepato-renal (Zellweger) syndrome. *Clin Chim Acta* 1987;**166**:45–56.
- ⁹ Kelley RI, Datta NS, Dobyns WB, et al. Neonatal adrenoleukodystrophy: new cases, biochemical studies, and differentiation from Zellweger and related peroxisomal polydystrophy syndromes. *Am J Med Genet* 1986;**23**:869–901.
- ¹⁰ Vamecq J, Draye J-P, van Hoof F, et al. Multiple peroxisomal enzymatic deficiency disorders. *Am J Pathol* 1986;**125**:524–35.
- ¹¹ Wolff J, Nyhan WL, Powell H, et al. Myopathy in an infant with a fatal peroxisomal disorder. *Pediatr Neurol* 1986;**2**:141–6.
- ¹² Ek J, Kase BF, Reith A, Björkhem I, Pedersen JI. Peroxisomal dysfunction in a boy with neurological symptoms and amaurosis (Leber disease): clinical and biochemical findings similar to those observed in Zellweger syndrome. *J Pediatr* 1986;**108**: 19–24.
- ¹³ Aubourg P, Scotto J, Rocchiccioli F, Feldmann-Pautrat D, Robain O. Neonatal adrenoleukodystrophy. *J Neurol Neurosurg Psychiatry* 1986;**49**:77–86.
- ¹⁴ Hoefler G, Hoefler S, Watkins PA, et al. Biochemical abnormalities in rhizomelic chondrodysplasia punctata. *J Pediatr* (in press).
- ¹⁵ Holmes RD, Wilson GN, Hajra AK. Peroxisomal enzyme deficiency in the Conradi-Hunerman form of chondrodysplasia punctata. *N Engl J Med* 1987;**316**:1608.
- ¹⁶ Moser HW, Naidu S, Kumar AJ, Rosenbaum AE. The adrenoleukodystrophies: critical review of neurobiology. *CRC critical reviews in neurobiology* 1987;**3**:29–88. (CRC Press.)
- ¹⁷ Wanders RJA, van Roermund CWT, van Wijland MJA, et al. X-linked adrenoleukodystrophy: identification of the molecular defect at the level of a deficient peroxisomal very-long-chain fatty acyl-CoA synthetase using a newly developed method for the isolation of peroxisomes from fibroblasts. *J Inherited Metab Dis* (in press).
- ¹⁸ Aubourg PR, Sack GH, Moser HW. Frequent alterations of visual pigment genes in adrenoleukodystrophy. *Am J Hum Genet* 1988;**42**:408–13.
- ¹⁹ Goldfischer S, Collins J, Rapin I, et al. Pseudo-Zellweger syndrome: deficiencies in several peroxisomal enzymes. *J Pediatr* 1986;**108**:25–32.
- ²⁰ Schram AW, Goldfischer S, van Roermund CWT, et al. Human peroxisomal 3-oxoacyl-coenzyme A thiolase deficiency. *Proc Natl Acad Sci USA* 1987;**84**:2494–6.
- ²¹ Clayton PT, Lake BD, Hjelm M, et al. Bile acid analyses in “pseudo-Zellweger” syndrome: clues to the defect in peroxisomal β -oxidation. *J Inherited Metab Dis* (in press).
- ²² Poll-The BT, Roels F, Ogier H, et al. A new peroxisomal disorder with enlarged peroxisomes and a specific deficiency of acyl-CoA oxidase (pseudo-neonatal adrenoleukodystrophy). *Am J Hum Genet* 1988;**42**:422–34.
- ²³ Moser AB, Moser HW, Naidu S. Observations about the phenotype of peroxisomal disorders. In: Fahimi HD, Sies H, eds. *Peroxisomes in biology and medicine*. Berlin: Springer-Verlag, 1987:335–40.
- ²⁴ Naidu S, Hoefler G, Watkins G, et al. Neonatal seizures and retardation in a female with biochemical features of X-linked adrenoleukodystrophy: a possible new peroxisomal disease entity. *Neurology* (in press).
- ²⁵ Besley GTN, Broadhead DM. Dihydroxyacetone phosphate acyltransferase deficiency in peroxisomal disorders. *J Inherited Metab Dis* 1987;**10**(suppl 2):236–8.
- ²⁶ Lawson AM, Madigan MJ, Shortland D, Clayton P. Rapid diagnosis of Zellweger syndrome and infantile Refsum’s disease by fast atom bombardment-mass spectrometry of urine bile salts. *Clin Chim Acta* 1986;**161**:221–31.
- ²⁷ Clayton PT, Lake BD, Hall NA, Shortland DB, Carruthers DB, Lawson AM. Plasma bile acids in patients with peroxisomal dysfunction syndromes: analysis by capillary gas chromatography-mass spectrometry. *Eur J Pediatr* 1987;**146**:166–73.
- ²⁸ Robertson EF, Poulos A, Sharp P, et al. Treatment of infantile phytanic acid storage disease: clinical, biochemical and ultrastructural findings in two children treated for 2 years. *Eur J Pediatr* 1988;**147**:133–42.

*Contains 129 references up to 1985.

J B P STEPHENSON
Fraser of Allander Unit,
Royal Hospital for Sick Children,
Glasgow G3 8SJ