

Vulvar myiasis during pregnancy

Mauro R. L. Passos, Renata Q. Varella, Rogério R. Tavares, Nero A. Barreto, Cláudio C. C. Santos, Vandira M. S. Pinheiro, Renato S. Bravo and Maurício H. L. Morelhi

Sexually Transmitted Diseases Sector, Universidade Federal Fluminense, Niterói City, Rio de Janeiro, Brazil

Myiasis is a parasitic infestation caused by the larvae of several fly species. Diagnosis and treatment are simple. The location of this infestation at the vulvar area is, however, an extremely rare occurrence. The authors present two cases of vulvar myiasis affecting pregnant women. The first case is a 19-year-old pregnant girl with vulvar myiasis and concomitant syphilis, vaginal trichomoniasis and genital candidiasis. The patient was also HIV-positive. The second case is a 17-year-old pregnant girl with vulvar myiasis associated with extensive vulvar condyloma acuminatum lesions.

Key words: VULVAR MYIASIS; HYGIENE; PARASITISM

CASE REPORT I

The first case is that of a 19-year-old female who resided in the city of São Gonçalo, Rio de Janeiro. She had multiple sexual partners. The patient underwent a clinical examination at the Sexually Transmitted Diseases (STD) sector of the Fluminense Federal University after presenting at two other public medical centers where she was not examined. She did not allow a physical examination in those clinics, probably because she was in pain and very nervous. At our STD sector she was refractory at first but, in view of the staff's firm stance, the patient eventually agreed to be examined: a large cavitory lesion with many larvae was observed. The patient was taken to the University's hospital where, under peridural anesthesia, more than a hundred maggots were removed. Follow-up was done at our STD clinic where, two weeks after surgery, material for fresh

and stained cytopathology was collected. Serologic testing for syphilis and HIV were done as part of the routine procedures. The patient returned several times and attained complete cicatrization of the wound.

In this case, the larvae were sent to the laboratory where they were identified as belonging to the genus *Sarcophaga* after maturation. Fresh and stained cytopathology revealed candidiasis and trichomoniasis. Conventional treatment for these diseases was prescribed. The serologic tests for syphilis and HIV were positive. After 30 days, the genital lesions were in an advanced stage of cicatrization. At this point the patient's menstrual period was late. Her pregnancy test was positive and she was directed to a prenatal service where she received anti-retroviral medication according to international protocol for pregnancy. She had a normal delivery; the baby was alive and healthy without treponemic or HIV infection.

Correspondence to: Mauro Romero Leal Passos, MD, PhD, Chefe do Setor de DST (MIP/CMB/CCM), Universidade Federal Fluminense, Campus do Valonguinho, Outeiro de São João Batista, Niterói, Rio de Janeiro, Brazil, 24210-150. Email: mipmaur@vm.uff.br

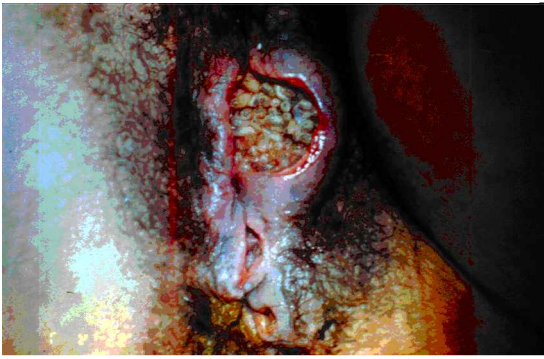

Figure 1 Case 1; large cavitory lesion containing more than 100 maggots

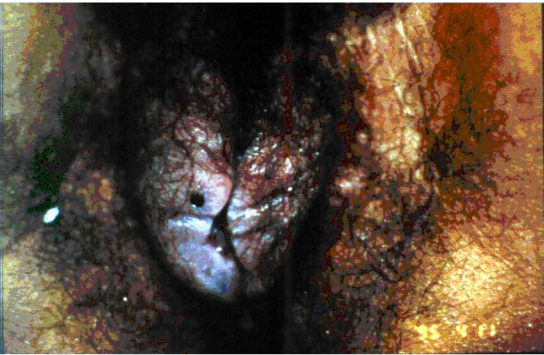


Figure 2 Case 1; appearance of the vulvar area two weeks after surgical cleaning

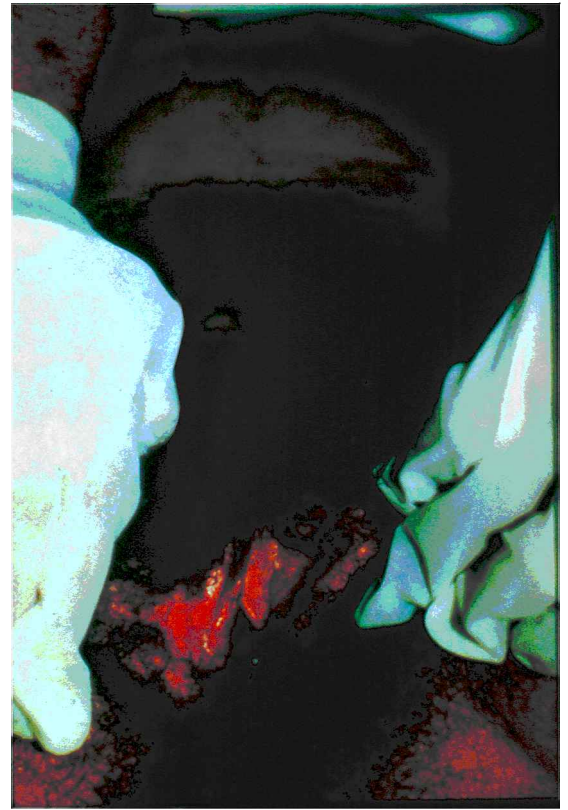


Figure 3 Case 1; the area shows complete wound cicatrization. Pregnancy was already evident

CASE REPORT 2

The second case is that of a female adolescent, 17 years old, also living in the city of S o Gonalo. She was in the tenth gestational week and had a single sexual partner. This patient had been to four public medical centers on the same day, three in S o Gonalo and one in the neighboring city of Niter oi, before arriving at our STD clinic. She had not received appropriate medical attention in any of the clinics. At the first medical center, the doctor could not see the patient because he was attending to another patient's delivery. At the second center she was seen by the doctor but was not examined. Instead, she was told to seek another medical facility. At the third facility, a public hospital's emergency room, she demanded to be examined while lying on an examination bed, but this was not allowed. She was examined standing up and a vulvar condylomatous lesion was detected. The doctor made a prescription for a non-steroidal anti-inflammatory drug. At 11 pm the patient

sought help at another public hospital's emergency room. A parasitologic exam was solicited and she was told to come to the Internal Medicine sector of the hospital on the following day. The next day, following a relative's advice, she came to the STD Sector of the Fluminense Federal University complaining of intense pain at the genital region, which made walking difficult. The gynecologic examination revealed condylomatous lesions of the vulva, vaginal introitus and perineum accompanied by infestation of multiple larvae. Some of the larvae penetrated the vagina, anus, and urethra. The lesions also showed signs of secondary infection; taking this into account the staff opted for the prompt removal of the larvae by means of anatomic tweezers. At this first intervention approximately fifty larvae were removed. After the surgical procedure the region was covered by a layer of solid Vaseline in an attempt to obstruct the ostia through which the larvae could surface because the extensive condylomatous lesions made surgical cleaning very difficult. The patient was

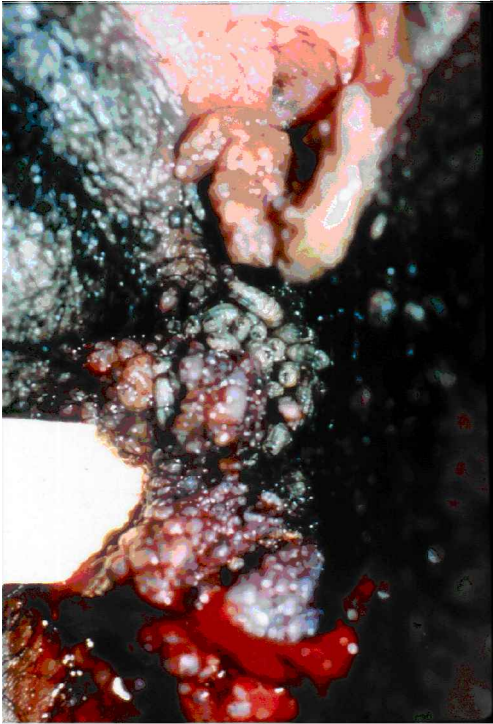

Figure 4 Case 2; extensive genital warts (human Papilloma virus lesions) and many larvae

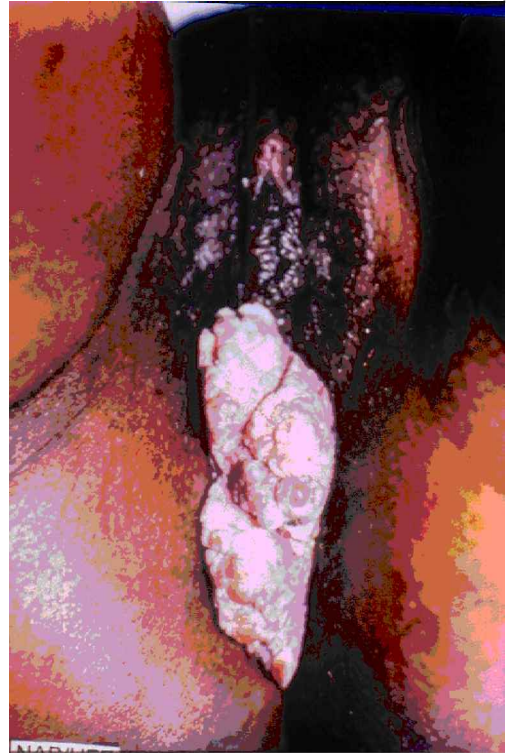


Figure 6 Case 2; as the lesions did not completely regress, the option was taken for surgical excision under local anesthesia

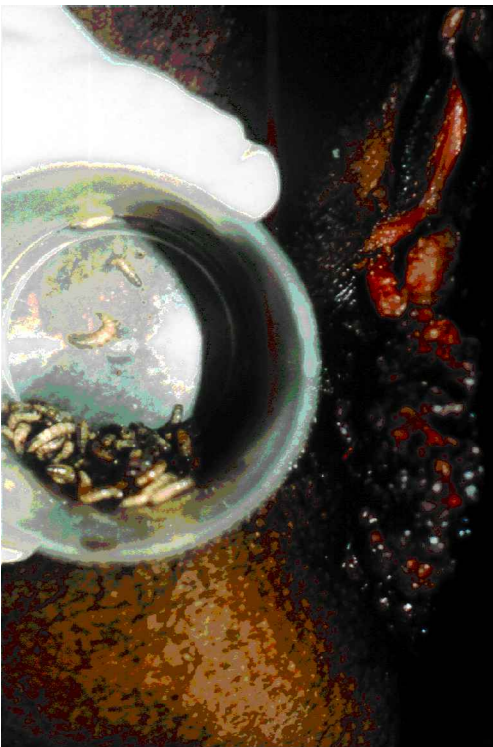

Figure 5 Case 2; larvae typical of *Cochliomyia hominivorax*

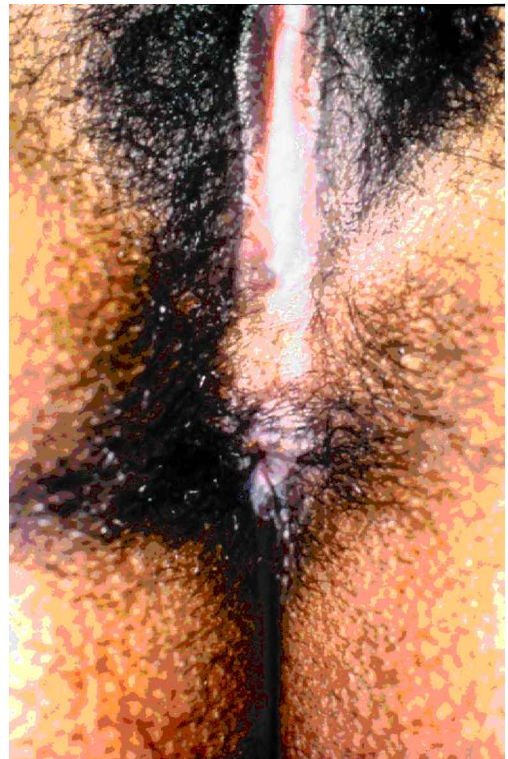


Figure 7 Case 2; patient completely cured

then medicated with an oral analgesic and 1 g oral azithromycin. On the following day, she showed improvement in the level of pain and approximately fifteen larvae were removed.

On the third day, two additional larvae were removed. Treatment of the vulvar condylomatosis was initiated using a trichloroacetic acid 60% solution. Serology for syphilis and HIV, oncotic colpocytology, and Gram's stain of vaginal secretion were additionally performed. The patient returned several times to our clinic; the human papilloma virus (HPV) lesions did not involute completely. There were no concomitant secondary infections. Our staff opted for a surgical removal of the remaining HPV lesions under local anesthesia. It was carried out at our STD clinic and the tissue fragments were sent for histopathologic examination.

In this second case, the larvae were identified as *Cochliomyia hominivorax*. The colpocytology showed cervical intraepithelial neoplasia grade I (CIN I), the Gram stain and the fresh cytology revealed many pyocytes and an exuberant mixed microbiota. Syphilis and HIV serologies were negative. As the patient was being followed for the treatment of the vulvar condylomata and vaginitis, she had a spontaneous abortion while being treated at a different public health service.

DISCUSSION

Myiasis is defined as a disease caused by the infestation of body tissues by larvae of several fly species of veterinary and medical interest. This disease occurs predominantly in rural areas, and is associated with poor hygienic practices, low educational level, and children.

Human myiasis is caused by fly larvae capable of penetrating body orifices as well as healthy or necrotic tissue. The fly species that infest healthy tissue are called *Biontophage* and are responsible for the cutaneous form of this condition (furunculoid myiasis). Among these species are *Dermatobia hominis* (the most frequent), *Cochliomyia hominivorax* and *Oestrus ovis*. The species that infest necrotic tissue (cavitary myiasis) include the genus *Sarcophaga*, *Lucilia*, *Callitroga* and *Musca*, as well as the *Musca fannia* species^{1,2}.

In the primary and furunculoid forms of the disease the larvae penetrate the skin, leading to the formation of painful, inflammatory nodules that can form fistulae to internal organs or to the surface of the skin. Sero-hemorrhagic exudation may be eliminated and the larvae are sometimes seen moving. Some complications have already been documented, such as secondary infection and tetanus. These complications can aggravate the underlying pathologic process. The prognosis is generally good; the treatment consists of the removal of the parasitic larvae and of thorough cleansing of the affected area. Furunculoid myiasis may be treated by the occlusion of the fistula with Vaseline ointment or nail polish, making respiration impossible for the larvae. After this they can be removed with the aid of surgical tweezers and the nodule may be gently expressed. When needed, a small surgical procedure may be performed, with local anesthetics. After all larvae are removed the local area may be cleansed and covered with antibiotic ointment³. Brewer⁴ reports the use of pig fat in an attempt to force the larvae out of the tissue by lack of oxygen.

Although myiasis is infrequent, many reports can be found in the medical literature, as it often affects children and occurs in regions other than the genitalia. While Baird⁵ reports many cases of human myiasis, the published cases of genital myiasis are nevertheless very few⁶⁻⁹. These reports refer to patients of various ages, the youngest being seven months old¹⁰⁻³.

The two cases described above refer to women residing in São Gonçalo, a city with over a million inhabitants, which is double the number of the adjacent Niterói. Both cities belong to the metropolitan area of the city of Rio de Janeiro, a megapolis. Although these two cities preserve some areas with rural characteristics, both patients resided within the urban perimeter and lived in brick houses with electricity, water and sewage facilities. Nonetheless, they shared a low socioeconomic and cultural background, and had not completed their basic education.

Today Niterói (the former capital of the Rio de Janeiro state) is considered the fourth city in Brazil in terms of quality of life, and the first among cities belonging to the Rio de Janeiro state. Niterói does not include a rural area, but its health services cater

for a large part of the neighboring cities' populations, which suffer in terms of quality and quantity of health services. This is also the case for S o Gonçalves.

Gomes and colleagues⁷ described a case of vulvar myiasis affecting an 18-year-old woman. Cilla and colleagues¹ reported an 86-year-old diabetic woman suffering from the same condition. Saleh and Sibae¹⁴ described three cases of genital myiasis caused by *Philophia casei*, a different fly species. Delir⁹ published the case of a young and otherwise healthy Iranian woman. And Ramalingam described a 76-year-old woman suffering from rectal carcinoma and uro-genital myiasis¹⁵.

We emphasize the importance of performing a careful gynecological examination as a way of detecting some less common diseases. Reminding patients of simple hygienic measures, such as washing the genital region with soap and water, may prevent the occurrence of diseases like the one we described. The patients referred to in this article had very poor hygienic habits, although they were not homeless. In our opinion, the fly that deposited ovae on their genital regions was attracted by the odor caused by a lack of proper hygiene and by coexisting genital infections. Because they were not being removed by local cleansing, the larvae grew and led to the inflammatory process. One may speculate that the patients did not wear underwear while sleeping or after sexual intercourse, or perhaps the genital lesions already present made using underwear uncomfortable. We emphasize the importance of offering syphilis and HIV serology tests to all patients presenting genital infections.

As to concurrent pregnancy, half of our small sample (one patient) attained a normal delivery, although she had multiple infections: vulvar myiasis, candidiasis, trichomoniasis, syphilis and HIV infection. The other half (one patient) presented with concomitant vulvar myiasis and

extensive genital wart lesions, and the pregnancy ended by spontaneous abortion.

The first patient, with a larger genital lesion, would not submit to a full clinical examination and had to undergo general anesthesia for the surgical cleaning of her lesions. The second patient, who had HPV infection, was very cooperative and her lesions harbored fewer larvae. She was treated as an outpatient.

The patient in case one had a low educational background and showed difficulty expressing herself and communicating with the medical staff. The patient also seemed unaware of the responsibilities associated with pregnancy. The patient in case two did not reconcile herself with the fact that she was pregnant, but otherwise showed no communication or comprehension problems.

The authors believe that although human myiasis occurs rarely, it probably occurs at a higher rate than is currently thought, a consequence of the fact that most of these patients receive medical care at the periphery of big cities or in countries' hinterlands. The medical professionals who treat these patients do not always have the resources to photographically document these cases and/or may not be used to publishing their work.

We are certain that Brazil and Brazilian medicine, in particular, are in a process of development. As shocking as the cases presented, is the lack of attention displayed by some professionals to the performing of basic actions that constitute medical practice, such as the physical examination and humane care for the patient. Similar situations occur in many countries, being no privilege of the developing nations. Even highly developed countries have shortcomings in the public health arena, especially in the care of low-income patients.

One may suppose these facts to be under-reported in the medical publications of developed countries, but we believe that reporting them does represent a measure of ethical development.

REFERENCES

1. Cilla G, Pico F, Peris A, et al. Human genital myiasis due to *Sarcophaga* [Spanish]. *Rev Clin Esp* 1992;190:189-90
2. Perez-Eid C, Mouffok N. Human urinary myiasis caused by *Fannia canicularis* (Diptera, Muscidae) larvae in Algeria [French]. *Presse Med* 1999;28:580-1

3. Nunzi E, Rongioletti F, Rebora A. Removal of *Dermatobia hominis* larvae [letter]. *Arch Dermatol* 1986;122:140
4. Brewer TF, Wilson ME, Gonzalez E, et al. Bacon therapy and furuncular myiasis. *J Am Med Assoc* 1993;270:2087–8
5. Baird JK, Baird CR, Sabrosky CW. North American cuterebrid myiasis. Report of seventeen new infections of human beings and review of the disease. *J Am Acad Dermatol* 1989;21:763–72
6. J Deus MCBR, Santos JA, Quevedo JMA. Vulvar myiasis [Portuguese]. *Femina* 1989;17:560–3
7. Gomes PA, Fukugava MFN, Cuce LC. Vulvar myiasis [Portuguese]. *J Bras Med* 1996;70:106–8
8. Passos MR, Carvalho AV, Dutra AL, et al. Vulvar myiasis. *Infect Dis Obstet Gynecol* 1998;6:69–71
9. Delir S, Handjani F, Emad M, et al. Vulvar myiasis due to *Wohlfahrtia magnifica*. *Clin Exp Dermatol* 1999;24:279–80
10. Keth AC. Three incidents of human myiasis by rodent *Cuterebra* (Diptera: Cuterebridae) larvae in a localized region of western Pennsylvania. *J Med Entomol* 1999;36:831–2
11. Rao R, Nosanchuk JS, Mackenzie R. Cutaneous myiasis acquired in New York State. *Pediatrics* 1997;99:601–2
12. Schmidt HW. Diptera larvae of the species *Scatopsidae* as genitalia parasites in women [German]. *Z Allgemeinmed* 1970;46:788–9
13. Sherman RA. Wound myiasis in urban and suburban United States. *Arch Intern Med* 2000;160:2004–14
14. Saleh MS, el Sibae MM. Urino-genital myiasis due to *Piophilha casei*. *J Egypt Soc Parasitol* 1993;23:737–9
15. Ramalingam S, Nurulhuda A, Bee LH. Urogenital myiasis caused by *Chrysomya bezziana* (Diptera: Calliphoridae) in peninsular Malaysia. *Southeast Asian J Trop Med Pub Health* 1980;11:405–7

RECEIVED 06/01/01; ACCEPTED 05/03/02