

red marrow. The spleen was slightly enlarged (300 g) but the lymph nodes in various regions showed nothing abnormal. The liver had a brown cut surface that was slightly enlarged, firm, and finely lobulate. The heart was enlarged (490 g) owing to moderate hypertrophy of the right and left ventricles. There was severe oedema and congestion of both lungs. Scanty atherosclerosis was seen in the patent coronary arteries.

Histological Findings.—The bone marrow contained a moderate excess of megakaryocytes and haemosiderin and a slight excess of myeloid precursors (Fig. 1). A section of synovium from the right knee had villous projections covered with swollen synovial cells. Haemosiderin was abundant both in synovial cells and in macrophages in the underlying stroma (Fig. 2). Massive depositions of

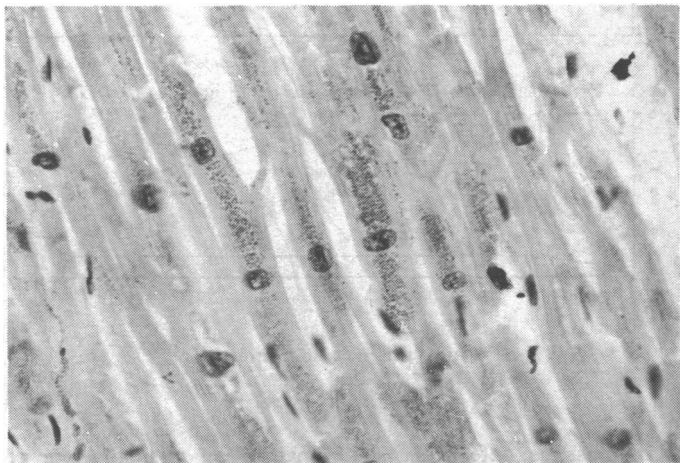


FIG. 3—Heart showing abundant haemosiderin. ($\times 233$.)

haemosiderin were found in the heart (Fig. 3), thyroid, lymph nodes, and suprarenals. There was a considerable amount of haemosiderin in the liver, which was fibrotic, and also in the pancreas, although there was no fibrosis in this organ. Haemosiderin was not seen in skin or skin appendages.

Discussion

Arthropathy is a well-recognized complication of idiopathic haemochromatosis though iron is not always found in the synovial membrane. The diagnosis depends largely on clinical and radiological features. The changes are found more often in the finger joints, large joints being less often involved. We have been unable to find any reference to arthropathy as a result of transfusional siderosis. In the present case the clinical features were mainly involvement of large joints such as knees, ankles, shoulder, and hips. Unfortunately no specific radiographic studies were made of the joints at the time that she complained of arthritis, but at necropsy siderosis was a conspicuous feature.

Absence of both pancreatic fibrosis and cutaneous siderosis was against a diagnosis of idiopathic haemochromatosis, and it seems likely that the arthropathy in this case was directly due to the repeated transfusions and the resultant high levels of serum iron.

We are grateful to Dr. A. P. Dick for permission to report this case.

References

- Dymock, I. W., Hamilton, E. B. D., Laws, J. W., and Williams, R. (1970). *Annals of the Rheumatic Diseases*, 24, 469.
 Hamilton, E., Williams, R., Barlow, K. A., and Smith, P. M. (1968). *Quarterly Journal of Medicine*, 37, 171.
 Schumacher, H. R. (1964). *Arthritis and Rheumatism*, 7, 41.
 Wardle, E. N., and Patten, J. T. (1969). *Annals of the Rheumatic Diseases*, 28, 15.

Q Fever Endocarditis Treated with Trimethoprim and Sulphamethoxazole

R. FREEMAN, MARGARET E. HODSON

British Medical Journal, 1972, 1, 419-420

We here present a case of endocarditis due to *Coxiella burnetii* which appears to have responded to trimethoprim and sulphamethoxazole.

Case History

The patient, a woman aged 45, developed night cramps in both legs in August 1969. By January 1970 she had classical intermittent claudication and presented to this hospital complaining of pain in her right foot, even at rest, loss of weight, poor appetite, exhaustion, and recent breathlessness. There was no history of a rash or of a recent upper or lower respiratory tract infection.

Her only previous history was of a subarachnoid haemorrhage in 1965. The peripheral pulses were noted to be normal at that time. Examination on the present admission showed a temperature of 103°F (39.4°C), pulse 90/min, regular, and blood pressure 160/100 mm Hg. The heart was of normal size and there were no murmurs. The peripheral pulses are shown in Table I. All other systems were

TABLE I—State of Peripheral Pulses as assessed clinically in January 1970 (on Admission) and June 1970 (after two Months of Treatment)

	Right		Left	
	January	June	January	June
Femoral	—	+	+	+
Popliteal .. .	—	*	—	+
Posterior tibial ..	—	*	—	—
Dorsalis pedis ..	—	*	—	—
Subclavicular ..	+	+	+	+
Axillary	+	+	+	+
Brachial	—	+	+	+
Radial	—	+	+	+

+ = Palpable.
 — = Impalpable.
 * = Right leg amputated before second assessment.

clinically normal except that she was thought to have a minimal degree of hepatosplenomegaly.

The right foot was gangrenous and an above-knee amputation was performed. The stump healed well but she remained pyrexial—temperatures over 100°F (37.8°C) being frequently recorded. Extensive investigations failed to find the cause of her illness but by the middle of March a pansystolic murmur was noted at the apex for the first time. Numerous blood cultures were sterile but anti-

University of Leeds, Leeds 2

R. FREEMAN, M.B., CH.B., Lecturer in Bacteriology

Leeds General Infirmary, Leeds 1

MARGARET E. HODSON, M.R.C.P., D.A., Registrar in General Medicine

bodies were shown to both phases of *Cox. burnetii*, and a rising titre of these antibodies confirmed the diagnosis of Q fever endocarditis.

Treatment was started with tetracycline 500 mg four times daily, but shortly afterwards this dose was reduced to 250 mg four times a day, and on 11 April Septrin was added at a dose of 2 tablets twice daily. This was continued until 6 August, when all specific therapy was stopped.

Soon after starting treatment with Septrin and tetracycline she made a steady improvement. The E.S.R. fell to normal limits, she became subjectively well, and a small ulcer which had been present on the left foot healed. She became afebrile, her hepatosplenomegaly resolved, and the peripheral pulses improved (Table I).

After her discharge from hospital she was regularly reviewed in the outpatient clinic and remained well apart from an episode of urinary tract infection which responded to treatment with nalidixic acid.

She was seen on 27 August 1971 having been off all treatment for over a year and was found to be well, the E.S.R. being 3 mm in one hour.

The source of her infection was unproved but she was known to drink raw milk and did, in fact, have serological evidence of past contact with *Brucella*.

Comment

The antibody titres to *Cox. burnetii* in this patient's serum are given in Table II, and the initial response to treatment is shown in the Chart.

TABLE II—Antibodies to *Cox. burnetii* detected in Serum* expressed as Reciprocal of Serum Dilution

	24/3/70	2/4/70	22/4/70	4/6/70	23/7/70	23/9/70	5/1/71	27/8/71
Phase 1	512	1,024	1,024	1,024	512	256	512	256
Phase 2	2,048	8,192	8,192	4,096	2,048	4,096	2,048	2,048

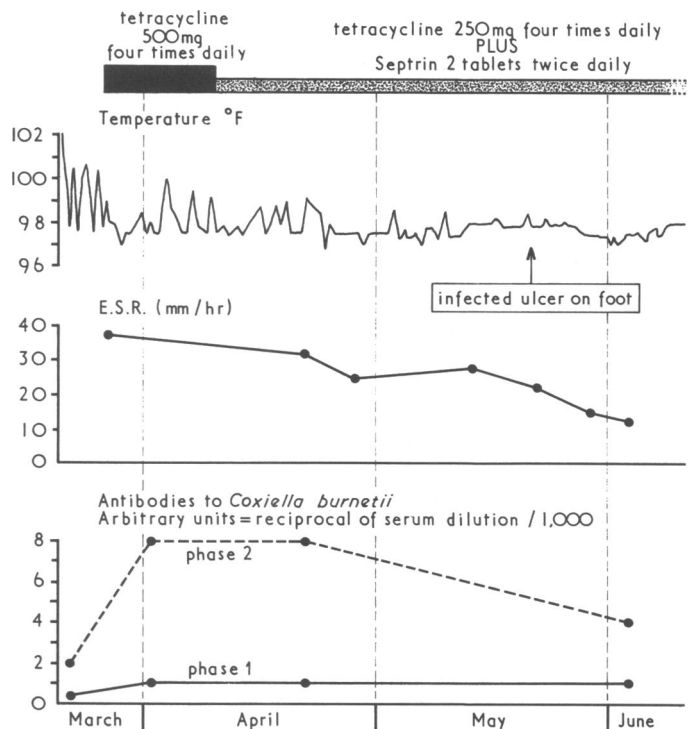
*Complement fixation technique was used.

The presence of a high titre of antibody to phase 1 antigen of *Cox. burnetii* has been taken to indicate chronic infection with this organism since the work of Andrews and Marmion (1959).

The patient had evidence of endocarditis and arteritis. Several authors have reported cases of arterial disease associated with this organism (Horsfall and Tamm, 1965). Since this patient was a relatively young woman her arteritis may have been due to the coxiella infection.

The treatment of Q fever endocarditis is still unsatisfactory. Review of the literature shows that antibiotic therapy is restricted to chloramphenicol and the tetracyclines. Being only bacteriostatic these drugs do not eradicate the organism or cure the condition. Darrell (1968) was of the opinion that antibiotics alone had probably never achieved a cure. For this reason recent therapy has been heart valve replacement under cover of tetracyclines (Kristinsson and Bentall, 1967).

Mattheis *et al.* (1963) found that *Cox. burnetii* was involved in folate metabolism in a similar way to plasmodia. Knowing of the activity of trimethoprim in malaria (Martin and Arnold, 1967) and of the bactericidal nature of its combination with the sulphonamides we thought that the commercial products Septrin and Bactrim might prove effective in this patient.



Patient's response to treatment.

It must be noted that she remained on a small dose of tetracycline throughout and so any benefit cannot be ascribed purely to the new therapy in this case.

The work of Mattheis *et al.* referred to above provides some theoretical justification for the use of trimethoprim and sulphamethoxazole in Q fever endocarditis. If subsequent work confirms the effectiveness of this treatment it will hold out the possibility of a bactericidal therapy in an otherwise intractable condition. We feel that the clinical and haematological response in this case justifies further investigation. Since this condition is rare we cannot expect to encounter many more such patients, and it is with the hope that others might consider using this therapy that we report this case.

Our profound thanks are extended to Dr. M. H. Hambling and his staff, especially Mr. G. Chance, at the Public Health Laboratory, Leeds, for their interest and invaluable help. We are equally indebted to Dr. R. N. Tattersall for his help and for his permission to report this case, which was under his care.

References

- Andrews, P. S., and Marmion, B. P. (1959). *British Medical Journal*, 2, 983.
 Darrell, J. H. (1968). *British Medical Journal*, 4, 40.
 Horsfall, F. L., and Tamm, I. (editors). (1965). In *Viral and Rickettsial Infections of Man*, 4th edn., p. 1068. London, Pitman Medical.
 Kristinsson, A., and Bentall, H. H. (1967). *Lancet*, 2, 693.
 Martin, D. C., and Arnold, J. D. (1967). *Journal of Clinical Pharmacology*, 7, 336.
 Mattheis, M. S., Silverman, M., and Paretsky, D. (1963). *Journal of Bacteriology*, 85, 37.