

37. SPROUSE, R.F. and J.D. RHOADES. Laboratory aspects of canine histoplasmosis. *Am J. publ. Hlth* 62: 1514-1519. 1972.
38. STRAUB, M. and J. SCHWARZ. General pathology of human and canine histoplasmosis. *Am. Rev. resp. Dis.* 82: 528-541. 1960.
39. STRAUB, M., J. SCHWARZ and A.R. FATTAL. Spontaneous canine histoplasmosis. *Archs Path.* 71: 685-692. 1951.
40. SUTLIFF, W.D., C.E. ANDREWS, E. JONES and R.T. TERRY. Histoplasmosis cooperative study from veterans administration-armed forces cooperative study on histoplasmosis. *Am. Rev. resp. Dis.* 89: 641-650. 1964.
41. TURNER, C., C.D. SMITH and M.L. FURCOLOW. Frequency of isolation of *Histoplasma capsulatum* and *Blastomyces dermatidis* from dogs in Kentucky. *Am. J. vet. Res.* 33: 137-141. 1972.
42. WEISSMAN, S. and E.E.A. ACAMPADO. Primary pulmonary histoplasmosis in a cat. *Feline Practice* 5: 28. 1975.

## LETTER TO THE EDITOR

### Coronavirus-like Particles Associated with Diarrhea in Baby Pigs in Quebec

DEAR SIR:

Recently, a coronavirus-like agent has been visualized and associated with diarrhea in pigs of all ages in England (2) and in Belgium (5, 6). This agent appeared to be distinct from the transmissible gastroenteritis (TGE) and hemagglutinating encephalomyelitis viruses (6). We would like to report the finding of similar coronavirus-like particles in Quebec and to report some of the clinical and histopathological observations we have made on these pigs. Incidence of this agent will be compared to that of other enteropathogens implicated in cases of baby pig diarrhea we studied.

During the last three years, we have observed sudden outbreaks and enzootic forms of diarrhea in baby pigs in several Quebec breeding farms with variable morbidity and mortality rates in which we could not demonstrate the presence of the TGE virus or the rotavirus in the baby pigs we examined, despite the presence of villous atrophy in their jejunums. The direct immunofluorescence technique (3) was used to detect these viruses and

was applied on cryostat sections from the small intestines of these baby pigs. Diarrheic feces and intestinal contents from these pigs which were processed for electron microscopic examinations by negative staining revealed the presence of coronavirus-like particles which were pleomorphic, 80-160 nm in diameter, centrally depressed and circled by a fringe of pyriform projections (Figure 1). These particles were morphologically indistinguishable from the coronavirus of TGE (7). Intestinal lesions in these cases were characterized by a multifocal or diffuse villous atrophy in the jejunums and ileums which was moderate to severe in intensity (Figures 3 and 4). There was a direct relationship between the severity of the clinical signs and the severity of the intestinal lesions.

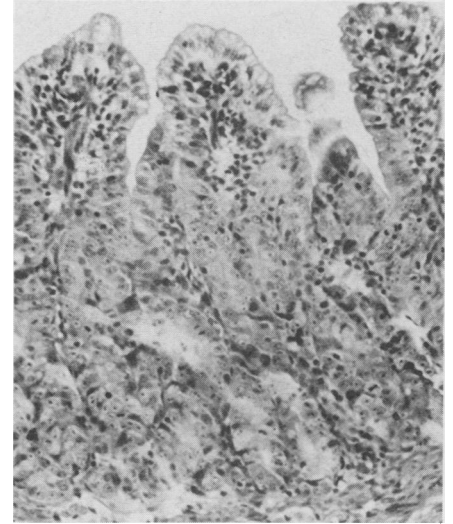


FIGURE 3. Section from the lower jejunum of a six day old diarrheic pig in which coronavirus-like particles only were demonstrated. Notice the villous atrophy and blunting and the elongation of the crypts. HPS. X125.

After routine postmortem examinations of 240 baby pigs (two to 15 days of age) from 63 breeding farms with acute outbreaks of diarrhea, this

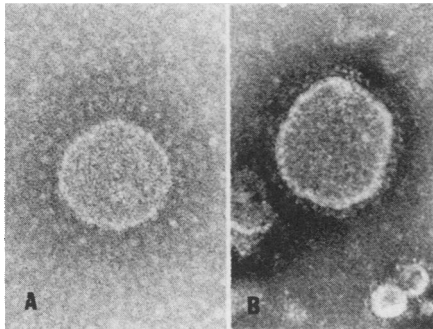


FIGURE 1. Negatively stained coronavirus-like particles from the intestinal content of a five day old diarrheic pig. A: X115,000. B: X160,000.

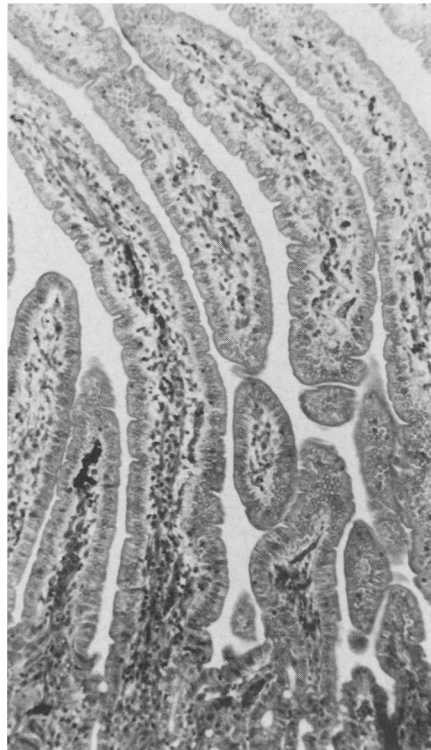


FIGURE 2. Section from the lower jejunum of a normal six day old pig. HPS. X75.

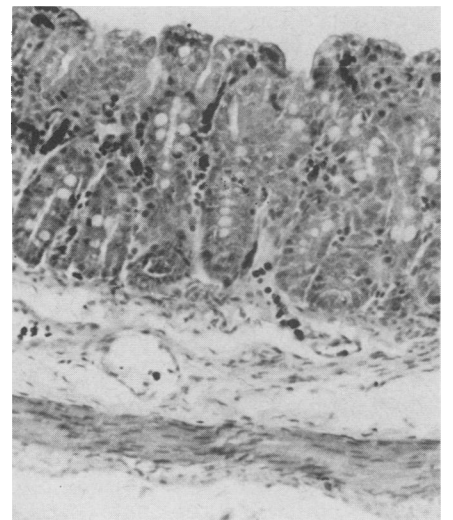


FIGURE 4. Section from the lower jejunum of a five day old diarrheic pig with coronavirus-like particles only. Notice the severe villous atrophy. HPS. X125.

coronavirus-like agent was implicated in 20% of the cases, the TGE virus only in 40%, the enterotoxigenic *Escherichia coli* only in 7%, the rotavirus only in 5.4 and the coccidia only in 10% of the cases. Morbidity and mortality rates were very variable from one farm to another for the same infectious agents.

Another major problem present in Quebec swine breeding farms on continual farrowing programs is a form of enzootic diarrhea which lasts months and years. In these herds diarrhea usually begins between five and ten days of age, most of the litters are affected with 30% to 40% of the piglets involved and mortality rates are variable but usually under 20%. Vomiting is rare and the sows are rarely affected. Thirty-two diarrheic baby pigs from seven of these farms were submitted to necropsy to study the etiology of these cases, by using a combination of bacteriological, virological (direct fluorescent antibody technique for TGE virus and rotavirus and direct electron microscopic examinations of intestinal contents and feces by negative staining) and histological methods. Coronavirus-like agent only was implicated in 40%, coronavirus-like with enterotoxigenic *E. coli* in 9% or coccidia in 12%, TGE virus only in 9% and enterotoxigenic *E. coli* only in 12% of these pigs.

In order to establish a relationship between the coronavirus-like particles and the occurrence of diarrhea, two baby pigs were inoculated orally with two 20% bacteria free suspensions of intestinal contents originating from two diarrheic baby pigs in which coronavirus-like particles only had been found. One of the inoculated pigs had a profuse diarrhea at 24 hours post-exposure and at necropsy a multifocal

villous atrophy was observed in its jejunum. The other pig was not sick at 24 hours post-exposure but focal lesions of villous atrophy were also present. Coronavirus-like particles only were demonstrated in both infected pigs but not in the controls which remained normal. The infected pigs were negative for TGE virus and rotavirus by the immunofluorescence technique.

The data reported above suggest that there is a coronavirus-like agent very prevalent in cases of baby pig diarrhea in the Province of Quebec and this virus appears to be distinct from the TGE virus. We have not checked at this time sera from pigs that have recovered from the disease for the presence of neutralizing antibodies against the hemagglutinating encephalomyelitis virus (HEV). The acute outbreaks of diarrhea in baby pigs associated with this virus seem to be similar to those described in Belgium (5, 6) and England (8). We were very surprised by the high incidence of this infection in the enzootic cases of diarrhea which are common in our breeding farms on continual farrowing programs. This clinical picture of the disease which seems to be the most common in our area has not been described in the previous reports and could represent a persistence of the infection in immune herds because of a continual source of susceptible pigs to maintain the infection. The TGE infection can behave with the same fashion in these breeding farms (1, 4) and both diseases are very similar clinically. Our clinicians call them viral scours.

More work will have to be done in order to characterize better this virus which appears to be a common cause of baby pig scour, at least in the Province of Quebec.

Sincerely yours,  
D.C. TURGEON

*Laboratoire de pathologie  
vétérinaire de Sherbrooke  
Agriculture Québec, 4260  
Boul. Bourque, Rock Forest  
(Québec) J0B 2J0*

M. MORIN  
J. JOLETTE  
R. HIGGINS

*Département de pathologie et  
microbiologie, Faculté de  
Médecine vétérinaire, Université de  
Montréal, Saint-Hyacinthe  
(Québec) J2S 7C6*

G. MARSOLAIS  
E. DiFRANCO  
*Institut Almand-Frappier  
Laval-des-Rapides  
(Québec) H7Z 4Z3*

#### References

1. BOHL, E.H. Transmissible gastroenteritis. In Diseases of Swine. Third Edition. H.W. Dunne, Editor. pp. 158-176. Ames, Iowa: State University Press. 1970.
2. CHASEY, D. and S.F. CARTWRIGHT. Virus-like particles associated with porcine epidemic diarrhea. Res. vet. Sci. 25: 255-256. 1978.
3. MORIN, M., L.G. MOREHOUSE, R.F. SOLORZANO and L.D. OLSON. Transmissible gastroenteritis in feeder swine: clinical, immunofluorescence and histopathological observations. Can. J. comp. Med. 37: 239-248. 1973.
4. MORIN, M. Enzootic form of transmissible gastro-enteritis (TGE) in swine herds. Section K. p. 4. In Proc. 4th Cong. Int. Pig Vet. Soc., Ames, Iowa. 1976.
5. PENSART, M.B., P. DeBOUCK and P. De ROOSE. A virus isolated from an apparently new enzootic diarrhea in swine. Proc. 5th World Int. Pig Vet. Congress, Zagreb, Yugoslavia. Abstract K.A. 9. 1978.
6. PENSART, M.B. and P. DeBOUCK. A new coronavirus-like particle associated with diarrhea in swine. Arch. Virol. 58: 243-247. 1978.
7. PHILIP, J.I.H., S.F. CARTWRIGHT and A.C. SCOTT. The size and morphology of transmissible gastro-enteritis and vomiting and wasting disease viruses of pigs. Vet. Rec. 88: 311-312. 1971.
8. WOOD, E.N. An apparently new syndrome of porcine epidemic diarrhoea. Vet. Rec. 100: 243-244. 1977.