

A Retrospective Study of Heart Disease in Doberman Pinscher Dogs

M. J. HAZLETT, M. G. MAXIE, D. G. ALLEN AND B. P. WILCOCK

Department of Pathology (Hazlett and Wilcock) and Department of Clinical Studies (Allen), Ontario Veterinary College, University of Guelph, Guelph, Ontario N1G 2W1 and Veterinary Laboratory Services Branch (Maxie), Ontario Ministry of Agriculture and Food, Guelph, Ontario N1H 6R8

SUMMARY

The prevalence of gross and/or histological cardiac lesions was found to be much greater in Doberman pinscher dogs (16/26 or 62%) than in non-Doberman dogs (124/417 or 30%). At least some of the affected Dobermans were unrelated. Middle aged (mean age 4.7 yr) Dobermans of both sexes (11M:5F) were affected. Four of the Dobermans with heart lesions had congestive cardiomyopathy; three of these four had congestive heart failure and the other one died suddenly. Prominent gross lesions were ventricular dilation and atrioventricular valvular endocardiosis. Histological lesions noted were prominent myocardial fibrosis, myofiber degeneration with fatty replacement, myofiber vacuolation and arterial intimal cushion formation. A spectrum of myocardial disease exists in Dobermans and clinically overt congestive cardiomyopathy represents one end of this spectrum.

RÉSUMÉ

Une étude rétrospective des maladies cardiaques, chez des chiens Doberman pinscher

Cette étude portait sur 26 Doberman pinscher et 417 chiens d'autres races. Elle révéla une prédominance beaucoup plus accentuée des lésions cardiaques macroscopiques et microscopiques, chez les premiers que chez les derniers. En effet 16, ou 62% des Doberman présentaient de telles lésions, comparativement à seulement

124, ou 30% des chiens d'autres races. Au moins, certains des Doberman n'avaient aucun lien de parenté; des sujets des deux sexes, à savoir 11 mâles et cinq femelles, dont l'âge moyen se situait à 4,7 ans, étaient affectés. Quatre des Doberman qui présentaient des lésions cardiaques souffraient de cardiomyopathie congestive; trois d'entre eux manifestèrent une défaillance cardiaque congestive et le quatrième mourut subitement. Les lésions macroscopiques proéminentes se traduisaient par de la dilatation ventriculaire et de la dégénérescence des valvules atrio-ventriculaires; quant aux lésions microscopiques, elles incluaient une fibrose proéminente du myocarde, de la dégénérescence grasseuse et de la vacuolisation des fibres du myocarde, ainsi qu'une prolifération de l'endartère. Il existe, chez les Doberman, une variété de maladies cardiaques; la cardiomyopathie congestive clinique en représente une manifestation.

INTRODUCTION

Congestive cardiomyopathy (idiopathic myocardial disease) is usually seen in large breeds of dogs (1). In some reports (2,3), the Doberman pinscher has been the breed most commonly affected. Other acquired heart diseases reported in Dobermans include hypertrophic cardiomyopathy (4,5) and atrioventricular bundle degeneration causing sudden death (6,7). Personal observations and communications with veterinarians, dog breeders and

owners has led to concern regarding the apparent high prevalence of both congestive heart failure and sudden unexpected death in Doberman pinschers in Ontario. To document the nature and prevalence of the condition, pathology accessions were reviewed to determine whether Dobermans presented at the Ontario Veterinary College were disproportionately affected by heart diseases.

MATERIALS AND METHODS

Necropsy records of the Department of Pathology, Ontario Veterinary College, from January 1980 to April 1981, were reviewed. Dogs with recorded gross and/or histological heart lesions were categorized as to the nature of the lesion(s). The clinical records of all Dobermans submitted for necropsy during the above period were also reviewed and pertinent historical, clinical, radiographic and electrocardiographic findings noted. Owners of Dobermans with heart disease were contacted in order to obtain pedigree information.

Myocardium had been sectioned in 14 of 16 Dobermans with heart disease, and in two of ten without heart disease. Paraffin blocks were recut and stained with hematoxylin and eosin (H&E) and Masson's trichrome. Myocardial sections were examined microscopically and lesions recorded. In Dobermans 3, 5, 6, 7, 8, 12, 14 and 15 both ventricles were sectioned, and all but dog 6 had interventricular sep-

TABLE I
DIAGNOSES OF CARDIAC DISEASES IN DOBERMANS AND NON-DOBERMANS AS RECORDED IN
NECROPSY RECORDS OF THE ONTARIO VETERINARY COLLEGE, JANUARY 1980 TO APRIL 1981

Gross or microscopic pathology	Dobermans (26) (%)	Non-Dobermans (417) (%)
Dilation LV	7 (27)	23 (6)
RV	10 (38)	30 (7)
Hypertrophy LV	0 (0)	27 (6)
RV	1 (4)	7 (2)
Myocardial disease	11 (42)	15 (4)
Valvular endocardiosis LAV	9 (35)	58 (14)
RAV	10 (38)	38 (9)
Total affected	16 (62)	124 (30)

LV = left ventricular.
RV = right ventricular.
LAV = left atrioventricular.
RAV = right atrioventricular.

tum and atrium sectioned as well. Ventricular myocardium had been sectioned in dogs 1, 4, 9, 11 and 13, but the exact site could not be determined.

RESULTS

An increased prevalence of cardiac disease was observed in Dobermans (16 of 26, or 62%) compared to non-Dobermans (124 of 417, or 30%) (Table I). Dobermans more commonly had ventricular dilation and atrioventricular valvular endocardiosis than did non-Dobermans (Figures 1, 2 and 3). The endocardiosis was of

mild to moderate severity and was more severe than would be expected in young dogs. Irregular pale fibrotic areas were occasionally evident in the hearts of Dobermans with severe heart disease (Figures 2 and 4). Left atrial dilation was commonly associated

with left ventricular dilation (Figure 5). "Left ventricular hypertrophy" was more commonly diagnosed in non-Dobermans than in Dobermans, but in most cases this diagnosis was based solely on macroscopic impressions and was not substantiated by heart weights.

Of the 16 Dobermans with gross and/or microscopic evidence of cardiac disease, four dogs had been presented because of congestive heart failure (dogs, 3, 5, 8 and 12) and one dog had a history of syncope prior to its sudden unexpected death (dog 7) (Table II). Dogs 3, 5, 7 and 8 had congestive cardiomyopathy (3); they were all males and their average age was 3.8 yr. The time elapsed from onset of clinical signs to death was less than one month. These four Dobermans with fully developed congestive cardiomyopathy comprise the "cardiomyopathy" subgroup in Tables III to V. Dog 12 had an underlying congenital cardiac anomaly and does not qualify as congestive cardiomyopathy, but was included with the 11 other dogs which had underlying heart lesions without clinically apparent heart disease. These 12 dogs comprise the "noncardiomyopathy" subgroup in Tables III to V. The mean age at death in the group of 16 Dobermans with cardiac lesions was 4.7 yr (range 6 wk to 9 yr). Males were affected twice as frequently as females (11 males: 5 females). Extra-cardiac gross and microscopic lesions which were consistent with heart disease were: pulmonary congestion and edema, hepatic congestion, hydrothorax, ascites, subcutaneous edema, atrial thrombosis and alveolar heart failure cells (Table III). Atrial thrombosis was unique to the dogs with cardiomyopathy.

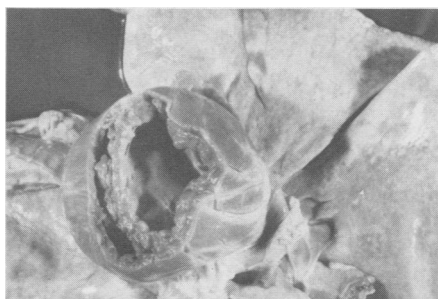

FIGURE 1. Biventricular dilation in a five year old Doberman pinscher female with clinically evident congestive heart failure. View from below with cardiac apex amputated.

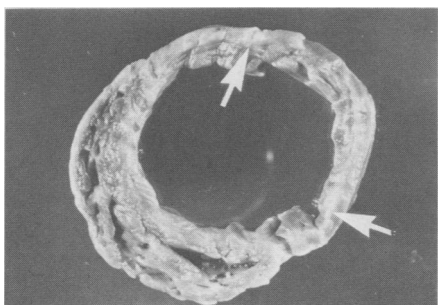


FIGURE 2. Section of the apex of the heart of the Doberman in Figure 1 showing marked left ventricular dilation, thinning of the left ventricular free wall and interventricular septum and irregular pale areas of fibrosis (arrows).

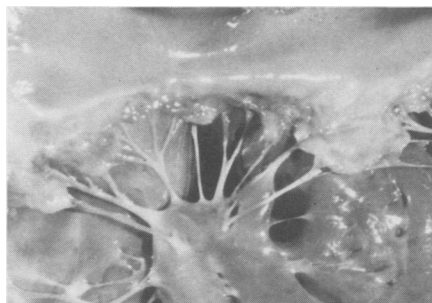

FIGURE 3. Mild endocardiosis of the left atrioventricular valve of the Doberman in Figure 1.

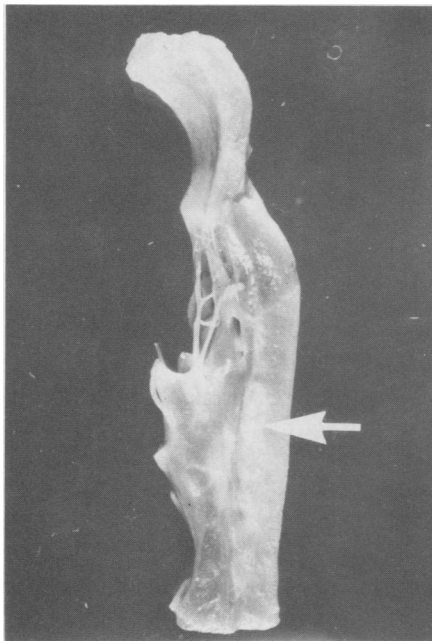


FIGURE 4. Irregular areas of fibrosis (arrow) in the left ventricular free wall of the Doberman in Figure 1.

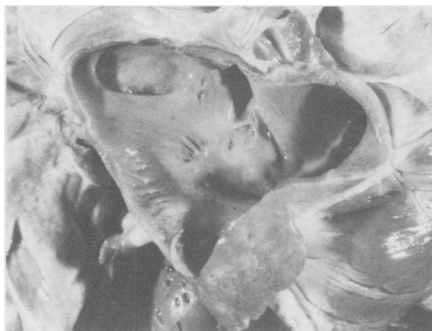

FIGURE 5. Moderate left atrial dilation in the Doberman in Figure 1.

The histological indicators of myocardial disease in affected Dobermans were: myocardial fibrosis of both interstitial and replacement types, infiltration of fat, myofiber degeneration and/or vacuolation and arterial intimal cushion formation (Table II) (Figures 6, 7 and 8). Myocardial fibrosis was often very prominent, especially in the middle third of the ventricular septum and the left ventricular free wall. Fibrosis appeared to involve more of the myocardium of the Dobermans with cardiomyopathy than of those without cardiomyopathy. Arterial degenera-

tive changes had advanced only to the intimal cushion stage.

Historical findings of exercise intolerance, cough, collapse and episodic weakness were strongly associated with heart disease in Dobermans (Table IV), but did not specifically indicate cardiomyopathy as the heart disease involved. Additional historical findings were even less specific in indicating the presence of heart disease or cardiomyopathy.

Findings upon physical examination which indicated the presence of heart disease were: irregular heart rhythm, gallop rhythm, weak pulse,

systolic murmur, pulse deficit, jugular pulse, cough, cyanotic mucous membranes and increased capillary refill time (Table V). Arrhythmias were more common in dogs with cardiomyopathy than in those with less severe cardiac disease.

Relevant findings in two of the four dogs with cardiomyopathy which were radiographed were: cardiomegaly, pulmonary edema, tracheal elevation and pleural effusion.

Electrocardiograms (ECG) were available from three of four Dobermans with postmortem evidence of cardiomyopathy, six of 12 with non-

TABLE II
SIGNALMENT, CLINICAL PROBLEMS AND HEART LESIONS IN DOBERMANS WITH HEART DISEASE

Dog	Age	Sex ^a	Clinical Problems	Gross Heart Lesions ^b	Microscopic Lesions in Ventricular Myocardium			
					Fibrosis	Fat Infiltration	Myofiber Degeneration	Arteriosclerosis
1	1.5 yr	M	Gastric torsion	Dilated RV Mild RAV endocardiosis	+ ^c	+	+	+
2	2.5 yr	F	Myelocytic leukemia	Mineralized foci in myocardium	NA ^d	NA	NA	NA
3	3 yr	M	Congestive heart failure	LA dilation Biventricular dilation Marked bilateral AV endocardiosis	+	+	+	—
4	7 yr	M	Prostatitis, peritonitis	None	+	+	+	+
5	4 yr	CM	Left heart failure	Biventricular dilation Mild LAV endocardiosis	+	+	+	+
6	5 yr	F	Liver disease	Moderate bilateral AV endocardiosis	+	—	+	+
7	4 yr	M	Syncope Sudden death	Mild LV dilation Moderate bilateral AV endocardiosis	+	+	+	+
8	4 yr	M	Right heart failure	Marked LV dilation Mild RV dilation Bilateral AV endocardiosis	+	+	+	+
9	3 yr	SF	Pleuritis	Biventricular dilation	—	—	—	+
10	8 yr	M	C5-6 intervertebral disc protrusion	RV dilation RAV endocardiosis	NA	NA	NA	NA
11	6 wk	F	Convulsions	None ^e	—	—	—	—
12	7 mo	M	Mild exercise intolerance Cardiomegaly Grade 4/5 systolic murmur	Biventricular dilation Marked bilateral AV endocardiosis with rupture of chordae tendineae Interatrial septal defect	+	—	—	+
13	9 yr	M	Splenic hemangiosarcoma	RV dilation Bilateral AV endocardiosis IV septal hamartoma	+	+	—	+
14	6.5 yr	M	Osteosarcoma	Mild biventricular dilation Mild bilateral AV endocardiosis	+	+	+	+
15	8 yr	F	C5-6, 6-7 intervertebral disc protrusion Cardiac arrhythmias Gastrointestinal hemorrhage	RV dilation	+	+	+	+
16	1 yr	M	Unprovoked aggression	Mild bilateral AV endocardiosis	—	+	—	—

^aM = male, CM = castrated male, F = female, SF = spayed female.

^bRV = right ventricle, LV = left ventricle, RAV = right atrioventricular valvular, LAV = left atrioventricular valvular, IV = interventricular, LA = left atrial.

^c+ = lesions present, — = lesions absent.

^dNA = not available.

^eCongestive heart failure diagnosed on the basis of alveolar "heart failure cells" and alveolar fibrin aggregates.

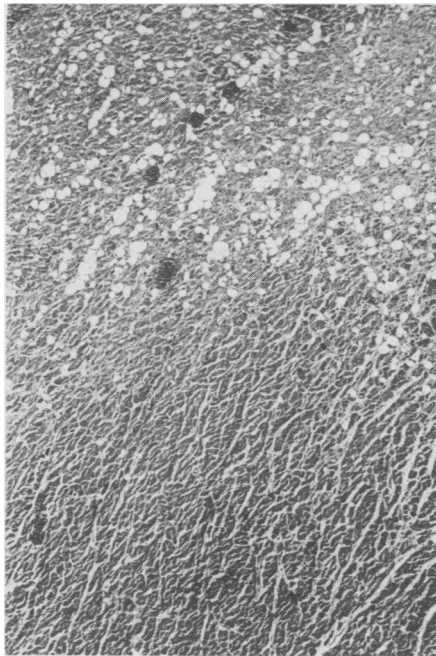


FIGURE 6. Low power photomicrograph showing fibrosis and fatty infiltration in the myocardium of the left ventricular free wall of a Doberman with congestive cardiomyopathy. Masson's trichrome. X 50.

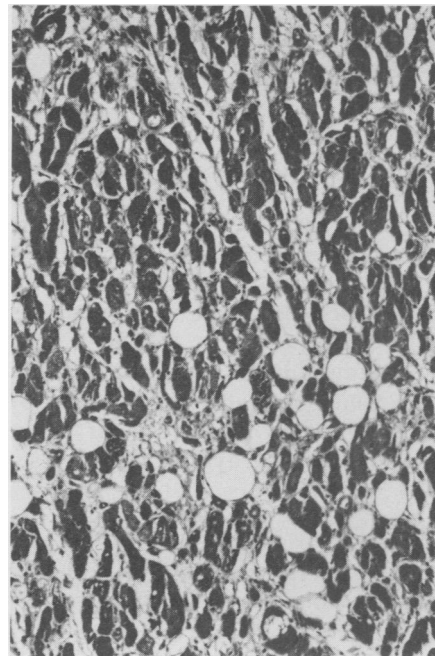


FIGURE 7. Interstitial fibrosis, fatty infiltration, myofiber size variation and myofiber degeneration in the left ventricular free wall of a Doberman with congestive cardiomyopathy. Masson's trichrome. X 150.

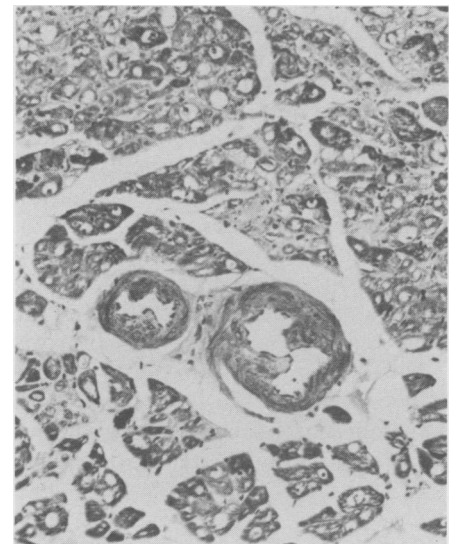


FIGURE 8. Marked interstitial and replacement fibrosis, marked myofiber vacuolation and moderate intimal cushion formation in the ventricular septum of a Doberman with congestive cardiomyopathy. Masson's trichrome. X 150.

TABLE III
EXTRA-CARDIAC LESIONS IN 16 DOBERMANS WITH EVIDENCE OF HEART DISEASE AND IN TEN DOBERMANS WITHOUT EVIDENCE OF HEART DISEASE

Lesion	Heart Disease (16) CMP (4) ^a non-CMP (12)	No Heart Disease (10)
Gross		
Ascites	2	0
Atrial thrombi	1	0
Cervicospinal arthropathy	0	1
Hepatic congestion	4	0
Hydrocephalus	0	1
Hydrothorax	1	1
Intervertebral disc protrusion	0	0
Pleuritis	0	0
Porencephaly	0	1
Portosystemic venous anastomoses	0	3
Prostatitis	0	0
Pulmonary arterial sclerosis	0	0
Pulmonary congestion and edema	4	0
Renal aplasia	1	1
Subcutaneous edema	1	0
Microscopic		
Alveolar heart failure cells	2	0
Chronic hepatopathy	0	1
Glomerulonephritis	1	1
Hemangiosarcoma	0	0
Hepatic encephalopathy	0	2
Lymphocytic thyroiditis	0	1
Myelocytic leukemia	0	0
Osteosarcoma	1	1
Pancreatic adenocarcinoma	0	1
Poliomyelomalacia	0	1
Reticulosis	0	1
Toxoplasmosis	0	1

^aCMP = cardiomyopathy.

cardiomyopathic heart disease and from one of ten Dobermans without evidence of heart disease. Records of physical examination showed that most Dobermans with or without heart disease had normal cardiac rates and rhythms. In cardiomyopathic dogs left ventricular enlargement, i.e. QRS > 0.06 s, R > 3.0 mV, and left atrial enlargement, i.e. P > 0.04 s, with or without a left axis shift, i.e. < 40°, was present in dogs 5, 7 and 8. Premature ventricular contractions (PVC) were present in dogs 7 and 8. The PVC were left ventricular and unifocal in dog 7 and junctional in origin in dog 8. In noncardiomyopathic dogs with heart disease, left ventricular and right ventricular enlargement (deep S waves leads I, II and III and a right axis shift > 100°) was present in dogs 10 and 12 respectively. Atrial fibrillation was evident only in dog 1. Premature ventricular contractions were diagnosed in dogs 10 and 15. The PVC were junctional in origin in dog 10. A low voltage QRS complex (R = 0.35 mV) was present in dog 9 with concurrent pleural effusion.

Examination of pedigrees of the Dobermans with heart disease indicated that several of the dogs were related, for example dogs 5 and 7 were sons of dog 14, but that at least two were from foreign bloodlines entirely unrelated to the other dogs.

TABLE IV
HISTORICAL FINDINGS IN 16 DOBERMANS WITH GROSS OR MICROSCOPIC EVIDENCE OF HEART DISEASE AND TEN DOBERMANS WITHOUT EVIDENCE OF HEART DISEASE

Clinical Signs	Heart Disease (16)		No Heart Disease (10)
	CMP (4) ^a	non-CMP (12)	
Aggressiveness	0	1	2
Anorexia, inappetence	2	3	3
Ascites	1	1	1
Ataxia	1	1	2
Collapse	1	1	0
Cough	2	1	0
Dyspnea	1	1	1
Episodic weakness	1	0	0
Exercise intolerance	1	4	0
Weakness, lethargy	1	4	5
Weight loss	2	5	4

^aCMP = cardiomyopathy.

TABLE V
PHYSICAL FINDINGS IN 16 DOBERMANS WITH EVIDENCE OF HEART DISEASE AND TEN DOBERMANS WITH NO EVIDENCE OF HEART DISEASE

Physical Finding	Heart Disease (16)		No Heart Disease (10)
	CMP (4) ^a	non-CMP (12)	
Ascites	1	1	1
Cough	1	1	0
Dyspnea	3	0	2
Edema	1	0	0
Gallop rhythm	1	0	0
Increased bronchovesicular sounds	1	0	2
Irregular heart rhythm	3	1	0
Jugular pulse	0	1	0
Mucous membranes — 1 CRT ^b	1	1	0
— cyanotic	2	1	0
— jaundiced	0	1	3
— pale	2	3	3
Pulse deficit	3	1	0
Rales	1	0	1
Systolic murmur	2	1	1
Thin or emaciated	2	3	3
Weak	1	2	1
Weak pulse	3	2	0
Natural death; euthanasia	3;1	2;10	0;10

^aCMP = cardiomyopathy.

^b†CRT = increased capillary refill time.

DISCUSSION

Our survey of canine necropsy submissions indicates that Dobermans have an increased prevalence of cardiac disease when compared to non-Dobermans. While only four of the Dobermans examined fit neatly into the category of congestive cardiomyopathy as recently described (3), 11 additional Dobermans had gross and/or microscopic cardiac lesions very similar to these four, albeit milder. We believe that the Dobermans which were presented due to congestive heart failure or sudden death represented one end of a spectrum of cardiomyopathy in Dobermans, wherein progressive myocardial

degeneration and fibrosis may, given time, lead to heart failure. Even at a prevalence of 60%, we may have underestimated the occurrence of heart disease in Dobermans since we were unable to examine myocardium microscopically in two Dobermans with, and eight without, heart disease which were included in this retrospective study.

In the 16 Dobermans in our series which were classified as having heart disease, the prominent gross lesions noted in various degrees were ventricular dilation and atrioventricular valvular endocardiosis. Ventricular dilation is a characteristic of failing myocardium and is one of the features of con-

gestive cardiomyopathy (1,3). The ventricular dilation was most pronounced in the dogs in our series which were in congestive heart failure. Atrioventricular valvular endocardiosis increases with age in dogs (8,9,10), but appeared to be unusually advanced in the Dobermans we observed with cardiac disease. Endocardiosis has been reported to occur occasionally in dogs with cardiomyopathy (1,3). We could not determine whether endocardiosis was a primary degenerative change which was contributing to myocardial failure, or whether myocardial failure and dilation were leading to secondary valvular changes. Systolic murmurs have been reported in four of 20 Dobermans with congestive cardiomyopathy (3) and were noted in two of our four Dobermans with cardiomyopathy.

Microscopic myocardial lesions in our series of Dobermans are consistent with those previously reported (3). We also observed similar changes, although of decreased severity, in the hearts of Dobermans without heart failure. Myocardial fibrosis was the most prominent myocardial lesion in our series of Dobermans and usually had a diffuse interstitial distribution. The cause of this fibrosis is unknown. Foci of replacement fibrosis were present in a random distribution and were presumably sequelae to myodegeneration. The pathogenesis of the myofiber vacuolation is unknown. Although arterial intimal cushions were commonly present, they did not appear to be of sufficient prominence to result in ischemia and the widespread myocardial fibrosis observed. Due to inconsistent sampling, the cardiac conduction system was not thoroughly examined in our series of Dobermans, but was generally within normal limits in those examined. Sudden death in ten of 11 Dobermans has been reported (6) to be due to focal degeneration of the bundle of His as a consequence of coronary arterial narrowing; unaffected Dobermans were not examined in their study. Atrioventricular bundle degeneration has been found in five Dobermans in a group of 12 dogs (7) and was thought to be the cause of sudden death (three dogs) or unprovoked aggression (two dogs). Hypoxic-type neuronal degeneration was demonstrated in the hippocampus

and cerebral cortex of the dogs with unprovoked aggression (7). In our series the sinoatrial node and atrioventricular node were normal in dog 7 which had a history of cardiac syncope and died suddenly and unexpectedly. Dog 16 had displayed unprovoked aggression and had moderate fatty infiltration of the bundle of His, but we did not detect brain lesions. We did not demonstrate heart or brain lesions in dog 6 which was euthanized because of seizures, although the dog did have evidence of congestive heart failure. The significance of conduction system lesions has been cast into doubt by a study of the atrioventricular conduction system of 40 large breed dogs without evidence of cardiac disease, including ten Dobermans (11). It was found that increased fibrous connective tissue, fat infiltration, focal fibrosis extending from the central fibrous body and the summit of the interventricular septum and loss of conduction fibers were normal aging changes which were consistently observed in dogs five years of age or older. Also noted in this study was that "fibrosis, chondroid metaplasia, mineralization and ossification were consistently seen in the summit of the interventricular septum, central fibrous body and root of the aorta". An identifying feature of Dobermans was prominent fibrosis over the crest of the interventricular septum. An alternative explanation of these findings is that they were examining a sample of Dobermans similar to ours, in which underlying heart disease is a very common finding, so common as to appear to be "normal".

Although the total number of ECG available was small, some tendencies are noteworthy. In Dobermans with cardiomyopathy, left heart enlargement predominated. Atrial fibrillation was not diagnosed in this group. Premature ventricular contractions appeared in two of three dogs. In Dobermans with noncardiomyopathic heart disease there was an equal distribution of left and right heart enlargement. Atrial fibrillation was seen in one of six dogs and premature ventricular contractions occurred in two of six. These tendencies concur with the findings of other investigators (3). In other breeds of dogs with congestive cardiomyopathy, atrial fibrillation is the most common rhythm disturbance (2,12).

The cause of congestive cardiomyopathy in dogs is not known, but a hereditary component has been suggested to exist in Dobermans (3,6). Most of the reports or discussions of congestive cardiomyopathy in dogs deal only with dogs exhibiting heart failure or sudden death (2,3,6,7,13) and have not reported the underlying spectrum of myocardial lesions which we are reporting. Cardiomyopathy in Dobermans may be a hereditary disease with variable expression, as is seen in familial glomerulonephritis of Dobermans (14). In our series of 26 Dobermans, seven dogs had histological evidence of glomerulonephritis and three had unilateral renal aplasia, but none of these dogs were azotemic. Other conditions in Dobermans which have been suggested to have a genetic influence include narcolepsy (15), IgM deficiency (16), polyostotic fibrous dysplasia (17), caudal cervical spondylomyelopathy (18), eye defects (19), chronic active hepatitis (20) and von Willebrand's disease (21). Dogs 10 and 15 in our series had caudal cervical intervertebral disc protrusions and dog 20 had cervicospinal arthropathy. Two Dobermans in our series had chronic active hepatitis (dogs 6 and 23) and three dogs had noninflammatory liver disease (dogs 17, 18 and 25). Dog 15 in our series was suspected of having von Willebrand's disease. Thus, several dogs in our series of Dobermans had at least two diseases which are suspected of being genetically determined.

In conclusion, we believe that a spectrum of cardiomyopathic change exists in Doberman pinscher dogs and that these changes are only occasionally expressed as clinically overt congestive cardiomyopathy. The interrelationships of myocardial disease, conduction system degeneration and endocardiosis, with congestive heart failure, sudden unexpected death, unprovoked aggression and seizures remain to be definitively explored.

ACKNOWLEDGMENTS

We thank Dr. C.M.A. Kreplin for assistance in obtaining pedigree information.

REFERENCES

1. ETTINGER SJ. Diseases of the myocardium, In Ettinger SJ, ed. Textbook of veterinary

- internal medicine — diseases of the dog and cat. Vol. 2. Philadelphia: W.B. Saunders Co, 1975: 953-976.
2. HILL BL. Canine idiopathic congestive cardiomyopathy. *Compend Cont Educ Pract Vet* 1981; 3: 615-621.
3. CALVERT CA, CHAPMAN WL Jr, TOAL RL. Congestive cardiomyopathy in Doberman pinscher dogs. *J Am Vet Med Assoc* 1982; 181: 598-602.
4. LIU SK, MARON BJ, TILLEY LP. Canine hypertrophic cardiomyopathy. *J Am Vet Med Assoc* 1979; 174: 708-713.
5. LIU SK, MARON BJ, TILLEY LP. Hypertrophic cardiomyopathy in the dog. *Am J Path* 1979; 94: 497-508.
6. JAMES TN, DRAKE EH. Sudden death in Doberman pinschers. *Ann Intern Med* 1968; 68: 821-829.
7. MEIERHENRY EF, LIU SK. Atrioventricular bundle degeneration associated with sudden death in the dog. *J Am Vet Med Assoc* 1978; 172: 1418-1422.
8. JÖNSSON L. Coronary arterial lesions and myocardial infarcts in the dog. A pathologic and microangiographic study. *Acta Vet Scand (Suppl)* 38. 1972.
9. WHITNEY JC. Cardiovascular pathology. *J Small Anim Pract* 1967; 8: 459-465.
10. WHITNEY JC. Observations on the effect of age on the severity of heart valve lesions in the dog. *J Small Anim Pract* 1974; 15: 511-522.
11. SANDUSKY GE Jr, KERR KM, CAPEN CC. Morphological variations and aging in the atrioventricular conduction system of large breed dogs. *Anat Rec* 1979; 193: 883-902.
12. CHURCH DB, FARROW BRH, WATSON ADJ. Idiopathic congestive cardiomyopathy in a dog. *Aust Vet Pract* 1976; 6: 250-253.
13. VAN VLEET JF, FERRANS VJ, WEIRICH WE. Pathological alterations in congestive cardiomyopathy of dogs. *Am J Vet Res* 1981; 42: 416-424.
14. WILCOCK BP, PATTERSON JM. Familial glomerulonephritis in Doberman pinscher dogs. *Can Vet J* 1979; 20: 244-249.
15. MITLER MM, SOAVE O, DEMENT WC. Narcolepsy in seven dogs. *J Am Vet Med Assoc* 1976; 168: 1036-1038.
16. PLECHNER AJ. IgM deficiency in 2 Doberman pinschers. *Mod Vet Pract* 1982; 63: 150.
17. CARRIG CB, SEAWRIGHT AA. A familial canine polyostotic fibrous dysplasia with subperiosteal cortical defects. *J Small Anim Pract* 1969; 10: 397-405.
18. SEIM HB III, WITHROW SJ. Pathophysiology and diagnosis of caudal cervical spondylomyelopathy with emphasis on the Doberman pinscher. *J Am Anim Hosp Assoc* 1982; 18: 241-251.
19. STADES FC. Persistent hyperplastic tunica vasculosa lentis and persistent hyperplastic primary vitreous (PH TVL/PHPV) in 90 closely related Doberman pinschers; clinical aspects. *J Am Anim Hosp Assoc* 1980; 16: 739-751.
20. JOHNSON GF, ZAWIE DA, GILBERTSON SR, STERNLIEB I. Chronic active hepatitis in Doberman pinschers. *J Am Vet Med Assoc* 1982; 180: 1438-1442.
21. JOHNSTONE IB, CRANE S. Von Willebrand's disease in two families of Doberman pinschers. *Can Vet J* 1981; 22: 239-243.