

ISOLATION OF TRICHOPHYTON RUBRUM (CASTELLANI) SABOURAUD, 1911, FROM ANIMALS

by A. N. CHAKRABORTY,¹ S. GHOSH¹ and F. BLANK²

Trichophyton rubrum (Castellani) Sabouraud, 1911, was first isolated by Bang (1) in 1910 at the Hôpital St. Louis in Paris from two persons who probably became infected in America, and during the same year by Castellani (2) in Ceylon. This dermatophyte which apparently originated in the Far East (3) has now spread to all five continents. At the present time, it is a species that is very often isolated from ringworm of the smooth skin and the nails. Bang (1), working with the first isolated strains, encountered difficulty in producing experimental infection of the hairs of guinea pigs. Similar observations were reported by several authors (4, 5, 6, 7, 8); however, other reports (9, 10, 11, 12, 13) mentioned the successful experimental infection of laboratory animals. The type of infection in the successful experiments varied, and in some instances an endothrix type (12, 13), in others an endo-ectothrix type (6, 9, 11) was observed. This particular behaviour of *Trichophyton rubrum* might explain the small number of reports of cases of ringworm of the scalp and the beard caused by this dermatophyte (4, 12, 13, 14, 15, 16, 17, 18) and the entire lack of any report of an isolation of this fungus from animals. Therefore, we were greatly surprised when we were able to isolate *Trichophyton rubrum* from three animals (one dog and two cows) treated at the Bengal Veterinary College and Hospital, Belgachia, Calcutta. The dog (Fig. 1) showed lesions on the buttocks and the trunk dorsal to the front legs. Loss of hairs was noticed in a few places. These places were scaly, moist and apparently itchy. The first cow had small raised plaques covered with scabs, on the head, around the muzzle and on the side of the nostril. On removal of the scab, there was an exudation of blood. There were also signs of a mild secondary infection. The second cow was covered with ringworm-like lesions all over the body.

In all three cases no infected hairs were found; the scarcity of infected hairs has already been noted in cases of dermatomycosis caused by *Trichophyton granulosum* (19, 20).

The cultures of *Trichophyton rubrum* showed slight radial folds near the margin around the hemispherical center. Later, the cultures became completely overgrown by a long, fluffy, white, aerial mycelium. On Sabouraud glucose agar a purple pigment was formed which also appeared in the marginal hyphae. Pigment formation did not occur on Sabouraud maltose agar. Microscopically, pyriform microconidia, mostly borne singly on the hyphae, and sausage-like, thin-walled macroconidia were seen. In older cultures many chlamydospores were present.

¹Department of Dermatology, Calcutta School of Tropical Medicine, Calcutta, India.

²Department of Bacteriology and Immunology, McGill University, Montreal, Canada.

REFERENCES

- (1) BANG, H. Sur une trichophytie cutanée à grands cercles, causée par un dermatophyte nouveau (*Trichophyton purpureum* Bang.). Ann. dermat. syph., 5e sér., 1: 225-238, 1910.
- (2) CASTELLANI, A. Observations on a new species of *Epidermophyton* found in tinea cruris. Brit. J. Derm., 22: 146-150, 1910.
- (3) LANGERON, M. Précis de Mycologie. Paris 1945.
- (4) BLANK, F. and SCHUPPLI, R. Sycosis barbae, hervorgerufen durch *Trichophyton rubrum* (Castellani) Sabouraud. Dermatologica, 102: 102-105, 1951.
- (5) GÖTZ, H. Klinische und experimentelle Untersuchungen über die Hautpilzkrankungen im Gebiet von Hamburg 1948-1950. Arch. f. Derm. Syph., 195: 1-76, 1952.
- (6) OTA, M. and KAWATSURE, S. Sur le *Sabouraudites ruber* et ses variétés. Ann. de Parasitologie humaine et comparée, 11: 476-501, 1933.
- (7) PAYENNEVILLE, J. and RIVALIER, E. Un cas d'épidermophytie exotique. Ann. dermat. syph., 7e sér., 8: 378-392, 1937.
- (8) PRIESTLEY, H. Ringworm and allied parasitic skin diseases in Australia. Med. J. Australia 1917 II: 471-475.
- (9) CATANEI, A. Sur la place de *Trichophyton rubrum* dans la classification. Etude parasitologique et expérimentale d'une nouvelle souche de ce champignon. Arch. Inst. Pasteur d'Algérie, 16: 227-231, 1938.
- (10) CATANEI, A. Sur un premier cas algérien de teigne cutanée à *Trichophyton rubrum*. Arch. Inst. Pasteur d'Algérie, 25: 89, 1947.
- (11) CATANEI, A. and LEFRANC, M. Observations cliniques et parasitologiques sur un deuxième cas algérien de teigne cutanée à *Trichophyton rubrum*. Arch. Inst. Pasteur d'Algérie, 28: 93-94, 1950.
- (12) MILOCHEVITCH, S. Contribution à l'étude du *Trichophyton rubrum*. Ann. de Parasitologie humaine et comparée, 13: 253-258, 1935.

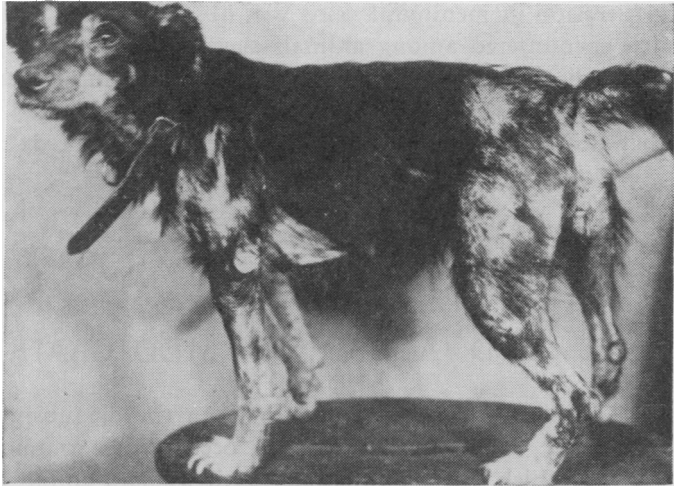


Fig. 1.—Dog Infected
Trichophyton rubrum

- (13) VANBREUSEGHEM, R. A propos de *Trichophyton rubrum*. Sa présence en Belgique et au Congo belge. Arch. Belges, Derm. Syph., 5, fasc. 4, 1-13, 1949.
- (14) KATO, Y. On the ringworm of the scalp caused by *Sabouraudites ruber*, especially on its character of endothrix. Jap. J. Derm. Urol., 25: 895-903, 1925 in Ota, M. and Kawatsuré, S. (6).
- (15) MANCY, E. S. Superficial fungous infection in Victoria. Med. J. Australia, 1952, I: 883-884.
- (16) RAY, L. F. Ringworm of scalp in Pacific Northwest. Northwest Med., 46: 214-216, 1947.

- (17) VANBREUSEGHEM, R. Diagnose et systématique des Dermatophytes. Contribution à la connaissance des Teignes du Congo Belge. Ann. Soc. Belge Méd. Trop., 30: 867-986, 1950.
- (18) WALKER, J. The dermatophytes of Great Britain. Report of a three years' survey. Brit. J. Derm. Syph., 62: 239-251, 1950.
- (19) SABOURAUD, R. Maladies du cuir chevelu. III. Les maladies cryptogamiques. Les teignes. Paris 1910.
- (20) BLANK, F., BYRNE, J. L., PLUMMER, P. J. G. and AVERY, R. J. Isolation of *Trichophyton granulosum* Sabouraud, 1909, from chinchillas showing "fur-slipping". Can. J. Comp. Med. Vet. Sci., 17: 396-402, 1953.

SPORADIC BOVINE ENCEPHALOMYELITIS

In 1953, Wenner and his associates (Amer. J. Hyg., 57: 1-14; 15-29) reported on the isolation of a member of the psittacosis-lymphogranuloma family of viruses from nine cases of sporadic bovine encephalomyelitis. They have recently described the results of their infectivity tests in calves (J. Infect. Dis., 94: 284-295, 1954). In calves ranging in age from 2 weeks to 8 months that were infected by intracerebral, intraperitoneal or subcutaneous routes, a mild illness occurred without frank clinical signs of encephalomyelitis. Focal perivascular infiltration in meningeal veins was observed but not the diffuse encephalomyelitis encountered among animals succumbing during epizootics. Group-specific antibodies for the psittacosis-lymphogranuloma venereum family of viruses, demonstrable by complement-fixation tests, appeared during convalescence as they do in cases occurring in naturally affected herds.

USE AND ABUSE OF MEDICAMENTS IN FEED

Medication is effective only when the diagnosis is accurate. As practiced at present, subacute intoxications occur more commonly than is recognized. Agents which are incompatible, such as para-amino-benzoic acid for chronic respiratory disease and sulfonamides for coccidiosis control, are sometimes fed simultaneously. Flowers of sulfur, sometimes used as a coccidiostatic agent, may interfere with normal bone formation in chickens and some sulfonamides may affect the calcium deposit in egg-shell formation. Furthermore, such drugs may be objectionably found in poultry meats and eggs, just as antibiotic drugs, when promiscuously fed to cows, may be found in their milk.