

pathway (with an apparently normal electrocardiogram when the patient is in sinus rhythm, differentiating this accessory pathway from the manifest anomalous pathway of the Wolff-Parkinson-White syndrome or the A-V node bypass of the Lown-Ganong-Levine syndrome).

In the absence of electrophysiological studies, the data available support the diagnosis of an ectopic atrial tachycardia in this young man.

The regression of a dilated cardiomyopathy picture is well reported after surgical treatment,² and more recently, following catheter ablation techniques.³ Flecainide is increasingly being used for the management of supraventricular tachycardias and this case provides further evidence of its efficacy.^{4 5}

This case is noteworthy, firstly because of the relatively low ventricular rate, and secondly because it provides clear evidence that the presence of left ventricular dysfunction is not always due to primary myocardial disease, but may be secondary to chronic tachycardia—in this case, incessant ectopic atrial tachycardia. As such, it is potentially reversible with

specific antiarrhythmic drugs such as flecainide—hence the term 'pseudocardiomyopathy'.

References

- ¹ Gallagher JJ. Tachycardia and cardiomyopathy: chicken-egg dilemma revisited. *J Am Coll Cardiol* 1985;6:1172-3.
- ² Bertil Olsson S, Blomström P, Sabel KG, William Olsson G. Incessant ectopic atrial tachycardia: successful surgical treatment with regression of dilated cardiomyopathy picture. *Am J Cardiol* 1984;53:1465-6.
- ³ Gillette PC. Treatment of atrial automatic tachycardia by ablation procedures. *J Am Coll Cardiol* 1985;6:405-9.
- ⁴ Creamer JE, Nathan AW, Camm AJ. Successful treatment of atrial tachycardia with flecainide acetate. *Br Heart J* 1985;53:164-6.
- ⁵ Till JA, Rowland E, Shinebourne EA, Ward DE. Treatment of refractory supraventricular arrhythmias with flecainide acetate. *Arch Dis Child* 1987;62:247-52.

Correspondence to Dr G Gladman, Neonatal Medical Unit, St Mary's Hospital, Whitworth Park, Manchester M13 0JH.

Accepted 21 September 1988

Chronic neonatal Coxsackie myocarditis

A GOREN,* M KAPLAN,* J GLASER,† AND M ISACSOHN‡

*Departments of *Neonatology, †Pediatric Cardiology, and ‡Infectious Disease Unit, Shaare Zedek Medical Center, The Hebrew University-Hadassah Medical School, Jerusalem, Israel*

SUMMARY A baby girl, with a birth weight of 2540 g, developed myocarditis with gross, permanent myocardial calcification. The clinical course was progressively downhill, and she died at 14 months of age. Neutralisation antibody to Coxsackie virus group B1 rose from 1:80 after delivery to 1:1280 at age 5 months. The protracted course of this infant's disease represents a new clinical form of fatal neonatal Coxsackie virus group B infection.

The clinical spectrum of neonatal infection with Coxsackie virus group B ranges from a mild, non-specific febrile illness to its severe, and often fatal, manifestation as myocarditis.^{1 2}

We report a newborn girl with proved Coxsackie virus group B1 disease who had an unusually protracted course with chronic cardiac dysfunction, permanent myocardial calcification, and severe failure to thrive.

Case report

A girl, weighing 2540 g, was delivered at 36 weeks' gestation by caesarean section because of maternal fever, accompanied by dry cough and diarrhoea, and hypertension. The mother did not have a rash. Transient respiratory distress in the child was followed by the appearance of fever on the 4th day of life. A systolic heart murmur and a third heart sound became audible; subsequently there were numerous runs of supraventricular tachycardia and development of congestive cardiac failure. The cerebrospinal fluid contained leucocytes at a concentration of $200 \times 10^6/l$, the protein concentration was 1.4 g/l, and glucose 3.1 mmol/l. Serum glucose concentration was 4.1 mmol/l. Cultures of blood, urine, and cerebrospinal fluid were negative for bacterial growth. Despite ventilatory support and treatment with digoxin, diuretics, corticosteroids, and verapamil, the clinical condition did not improve and the arrhythmia persisted for many weeks.

Virological investigation showed neutralisation antibody to Coxsackie virus group B1 at 1:80 in the immediate neonatal period; this increased to 1:1280 at age 5 months. The virus could not be isolated from the stool or throat of either the mother or child.

From the 14th day of life echocardiographically

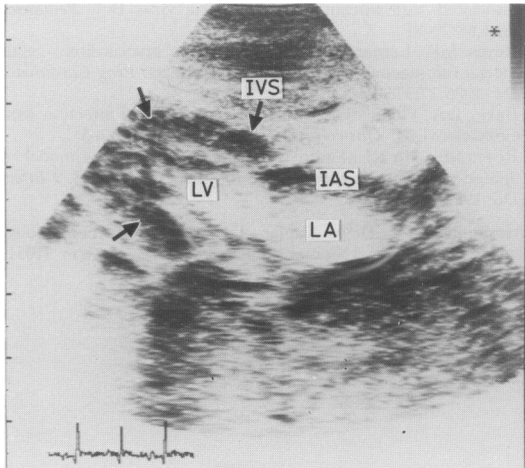


Fig 1 Echocardiogram (subxiphoid four chamber view) at age 4 months. Note areas of extreme echogenicity in the left ventricular myocardium (arrows) probably due to calcification. IVS: interventricular septum; IAS: interatrial septum; LV: left ventricle; and LA: left atrium.

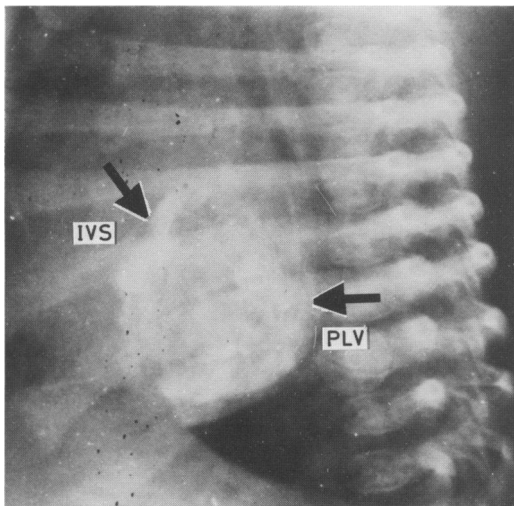


Fig 2 Lateral radiograph of chest taken at age 6 weeks showing widespread calcification of the left ventricle (arrows). IVS, interventricular septum; PLV: posterior left ventricular wall.

distinguishable, extremely echogenic areas became visible in the left ventricular myocardium and gradually increased in intensity (fig 1). These areas subsequently appeared radiologically (fig 2) and on computed tomography as dense calcifications, and had not been present in early echocardiograms and radiographs. Ejection fraction, determined by multigated angiography, was severely impaired: on day 52 the ejection fraction was <40%. Although this improved substantially, myocardial function was still abnormal, with ejection fraction 63%, on day 115. Cardiac catheterisation showed pulmonary hypertension but no structural abnormality. Although the infant could gradually be weaned off the ventilator, her general condition remained poor. The congestive cardiac failure could be only incompletely controlled. Bouts of fever for which no apparent cause could be determined recurred frequently. Despite adequate nutritional intake there was severe failure to thrive. The infant died at age 14 months. Permission for necropsy could not be obtained.

Discussion

Infants can become infected with Coxsackie virus group B by transplacental transmission, contact infection during birth, and by human contact after delivery.¹ Kaplan *et al* suggested that infection early in life is a significant factor leading to severe disease, and that in fatal cases the virus is transferred to the infant while in utero.² Thus the maternal febrile illness, early onset of the clinical signs, and the very severe course of the disease suggest that the infant we have described was infected transplacentally.

An unusual finding in our infant was the rapid development of severe myocardial calcification. We are aware of only one case in the literature, described by Barson *et al*,³ of radiologically similar myocardial calcification associated with Coxsackie virus B4 infection. In contrast with our infant who had permanent calcification and subsequently died, their infant, however, recovered clinically, with complete resolution of the calcification by 7 months of age. Our experience shows that the calcification can be detected in its early stages by standard echocardiographic techniques, and should be actively sought out in infants with Coxsackie virus B myocarditis.

Despite an increasing titre of viral type specific antibodies in our infant, as the virus was not isolated from or localised to the cardiac tissue itself, a virus induced myocarditis could not be definitely determined.⁴ Coxsackie virus group B, however, has been shown to cause histological myocardial calcification in both neonatal human⁵ and murine

tissue.⁶ Thus it would appear that the myocardial calcification in our infant followed myocarditis caused by the Coxsackie B1 virus.

Reviewing their own eight proved, fatal cases and a further 33 fatal cases in the literature in which evidence of Coxsackie virus group B disease was documented, Kaplan *et al* determined that, except for one infant who died on day 90, death occurred within the neonatal period.² To our knowledge a clinical course of progressive myocarditis with myocardial calcification and severe cardiac dysfunction, resistance of the arrhythmia and congestive cardiac failure to medical treatment, and a prolonged downhill course with failure to thrive and death at age 14 months has not been previously described in association with fatal Coxsackie virus B infection of neonatal onset.

The authors thank Dr Rahel Hanscher of the Central Virology Laboratory of the Ministry of Health, Tel Hashomer, Israel, for determination of the antibody titres.

References

- ¹ Cherry JD. Coxsackie viruses B. In: Feigin RD, Cherry JD, eds. *Textbook of pediatric infectious diseases*. Philadelphia: WB Saunders, 1986:1322–69.
- ² Kaplan MH, Klein SW, McPhee J, Harper RG. Group B Coxsackievirus infections in infants younger than three months of age: a serious childhood illness. *Rev Infect Dis* 1983;**5**: 1019–32.
- ³ Barson WJ, Craenen J, Hosier DN, Brawley RL, Hilty MD. Survival following myocarditis and myocardial calcification associated with infection by Coxsackie virus B-4. *Pediatrics* 1981;**68**:79–81.
- ⁴ Reyes MP, Lerner AM. Coxsackievirus myocarditis – with special reference to acute and chronic effects. *Prog Cardiovasc Dis* 1985;**27**:373–94.
- ⁵ Baker DA, Phillips CA. Maternal and neonatal infection with Coxsackievirus. *Obstet Gynecol* 1980;**55**(suppl):12–5.
- ⁶ Reyes MP, Ho KL, Smith F, Lerner AM. A mouse model of dilated-type cardiomyopathy due to coxsackievirus B3. *J Infect Dis* 1981;**144**:232–6.

Correspondence to Dr M Kaplan, Department of Neonatology, Shaare Zedek Medical Center, PO Box 3235, Jerusalem 91031, Israel.

Accepted 1 September 1988