

Treatment of chronic liver disease caused by 3β -hydroxy- Δ^5 - C_{27} -steroid dehydrogenase deficiency with chenodeoxycholic acid

H Ichimiya, H Nazer, T Gunasekaran, P Clayton, J Sjövall

Abstract

Deficiency of 3β -hydroxy- Δ^5 - C_{27} -steroid dehydrogenase, the second enzyme in the sequence that catalyses the synthesis of bile acids from cholesterol, leads to chronic liver disease in childhood as well as to malabsorption of fat and fat soluble vitamins. A 4 year old boy with this condition has been successfully treated by oral administration of a bile acid—chenodeoxycholic acid. He had been jaundiced since birth, grew poorly because of rickets, and had severe pruritus. Plasma transaminase activities were persistently raised. Chenodeoxycholic acid 125 mg twice daily for two months, and then 125 mg daily, cured his jaundice and pruritus, returned his transaminase activities to normal, and eliminated the need for calcitriol for prevention of rickets. On this treatment he has so far remained well for two years. A diagnosis of 3β -hydroxy- Δ^5 - C_{27} -steroid dehydrogenase deficiency should be considered in any child with unexplained chronic hepatitis or cirrhosis, especially if the liver disease is accompanied by a clinically obvious malabsorption of fat soluble vitamins. A simple colorimetric test of the urine confirms the diagnosis and effective treatment can be started.

Department of
Physiological Chemistry,
Karolinska Institute,
Stockholm,
Sweden
H Ichimiya
J Sjövall

Department of
Paediatrics,
King Faisal Specialist
Hospital and
Research Centre,
Riyadh,
Saudi Arabia
H Nazer
T Gunasekaran

Department of
Child Health,
Institute of Child Health,
30 Guilford Street,
London WC1N 1EH
P Clayton

Correspondence to:
Dr Clayton.

Accepted 19 May 1990

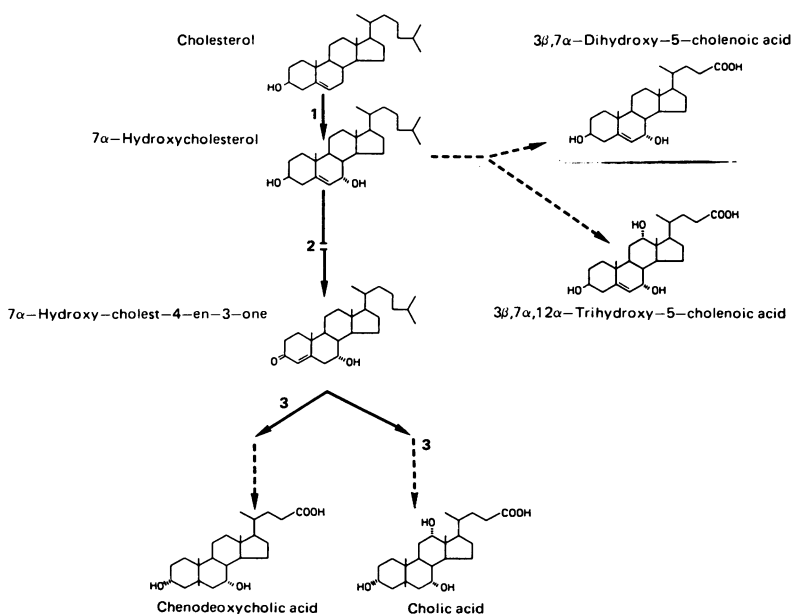


Figure 1 Pathway for the synthesis of bile acids from cholesterol. Reaction 1 catalysed by cholesterol 7 α -hydroxylase is inhibited by chenodeoxycholic acid (feedback inhibition). Reaction 2 is catalysed by 3β -hydroxy- Δ^5 - C_{27} -steroid dehydrogenase; deficiency of the enzyme leads to synthesis of 3β -hydroxy- Δ^5 bile acids. Reaction 3 is catalysed by 3-oxo- Δ^4 -steroid 5 β -reductase.

In the principal pathway for the synthesis of chenodeoxycholic acid and cholic acid from cholesterol in the liver (fig 1), the first (and rate limiting) step is catalysed by cholesterol 7 α -hydroxylase.¹ 7 α -Hydroxycholesterol is then converted to 7 α -hydroxy-cholest-4-en-3-one by a 3β -hydroxy- Δ^5 - C_{27} -steroid dehydrogenase/isomerase. This enzyme was shown to be deficient in the cultured fibroblasts of a boy from Saudi Arabia who was one of three siblings who had chronic cholestatic liver disease.^{2 3} When first studied at the age of 3 months, the patient had undetectable concentrations of chenodeoxycholic acid and cholic acid in his plasma despite clear evidence of cholestasis. Instead of synthesising the usual primary bile acids, he was producing large amounts of 3β , 7 α -dihydroxy-5-cholenoic acid and 3β , 7 α , 12 α -trihydroxy-5-cholenoic acid—that is, bile acids formed from precursors in which normal conversion of the 3β -hydroxy- Δ^5 structure to a 3α -hydroxy-5 β (H) structure had not occurred. The unsaturated bile acids were present at high concentration in the urine in sulphated form. They did not seem to be able to promote bile acid dependent bile flow and the absorption of fat and fat soluble vitamins from the intestine. The infant had conjugated hyperbilirubinaemia from birth, steatorrhoea, and low plasma concentrations of vitamins A, D, and E. There was also evidence that either the production of abnormal bile acids or the failure to produce cholic and chenodeoxycholic acids was causing progressive liver damage. The patient had raised transaminase activities and liver biopsy specimens taken from his affected siblings showed a giant cell hepatitis that progressed to a micronodular cirrhosis.

We argued that if this patient were given chenodeoxycholic acid or cholic acid, or both, these bile acids would be retained within the enterohepatic circulation and could promote bile acid dependent bile flow and facilitate micellar solubilisation of fats and fat soluble vitamins. As cholesterol 7 α -hydroxylase is inhibited by cholic and chenodeoxycholic acids, we could also hope for a reduction in the synthesis of abnormal metabolites of 7 α -hydroxycholesterol. This report describes the progress of this patient who was not treated until the age of 4.3 years, at which time he was started on treatment with chenodeoxycholic acid.

Case report

The family history and the initial presentation of this patient have previously been described.²

He was lost to follow up but then presented at the King Faisal Specialist Hospital and Research Centre, Riyadh at the age of 2.8 years. A variable degree of jaundice had persisted since infancy with dark urine and stools that were pale or yellow. He had severe pruritus, had retarded growth, and did not walk until the age of 2 years. His parents had noted bowing of his legs. On examination his weight was 13.6 kg (25th centile), height 82.5 cm (below the 3rd centile), and head circumference 50.5 cm (50th centile). Growth failure was associated with clinical rickets, with widening of wrists and a rachitic rosary in addition to his bowed legs. His liver was palpable 4 cm from the right costal margin and was firm. The spleen was not palpable.

Investigation confirmed persistent jaundice, hepatic dysfunction and vitamin D malabsorption. The plasma bilirubin concentration was 41 $\mu\text{mol/l}$ (direct 36 $\mu\text{mol/l}$); alanine aminotransferase activity 56 IU/l (reference range 10–25); aspartate aminotransferase activity 57 IU/l (reference range 10–40); and alkaline phosphatase activity 1085 IU/l (reference range 100–300). The albumin concentration was 47 g/l and prothrombin time and partial thromboplastin time normal. Calcium concentration was 1.67 mmol/l (reference range 2.13–2.62) and phosphate concentration 1.36 mmol/l (reference range 1.29–1.78). Radiography of the wrist showed florid rickets. Ultrasound scan of the liver confirmed that it was enlarged, with normal echogenicity.

Between the ages of 2.8 and 4.3 years he was treated with supplements of fat soluble vitamins. The vitamin D was given as the 1,25-dihydroxy derivative (calcitriol, 0.5 $\mu\text{g/day}$). His rickets improved clinically, radiologically, and biochemically (calcium concentration 2.44 mmol/l, alkaline phosphatase activity 300 IU/l). The jaundice and raised transaminase activities persisted, however (fig 2). Chenodeoxycholic acid was undetectable in plasma (as it had been at 3 months) but some cholic acid was present in both plasma (<4.3 $\mu\text{mol/l}$) and in bile.

At the age of 4.3 years, treatment with chenodeoxycholic acid (Chendol, Weddel) was started, initially in a dose of 125 mg (one capsule) twice daily (18 mg/kg/day), reducing to 125 mg daily after two months. At the time of writing treatment has continued for two years. After the first two months he was already feeling better. He was more active and his appetite had improved. The pruritus had disappeared and his urine had become normal in colour. The size of the liver was unchanged. His plasma bilirubin concentration had fallen to within the reference range for the first time in his life and the transaminase activities were almost normal (alanine aminotransferase 35 and aspartate aminotransferase 44 IU/l). The improvement was maintained over the ensuing months (fig 2) and he had no problem with diarrhoea as a result of the chenodeoxycholic acid treatment.

By the age of 5.3 years, he had achieved considerable catch up growth. His weight was 19.2 kg (50th centile) and height 105 cm (above 10th centile) but limb deformities as a result of his previous rickets were still evident and he had

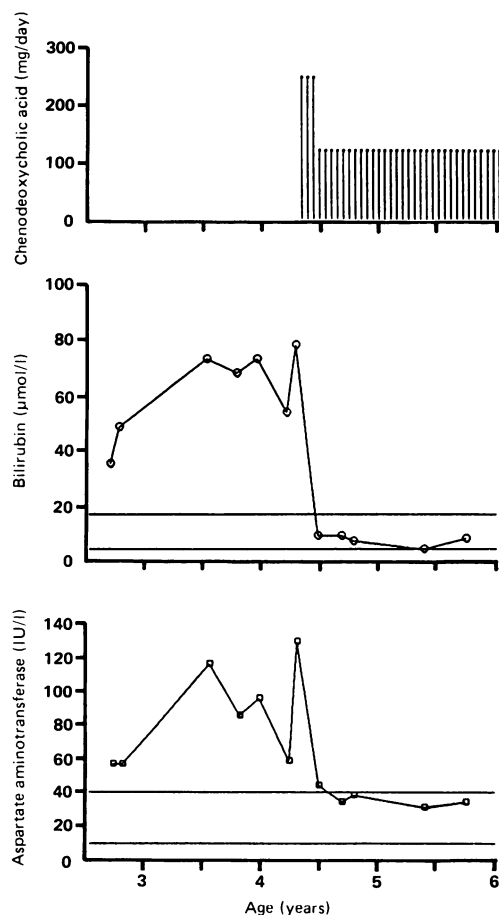


Figure 2 Effect of treatment with chenodeoxycholic acid started at the age 4.3 years on the patient's bilirubin concentration and aspartate aminotransferase activity.

carious teeth. The liver was palpable 5 cm from the costal margin (span 8.5 cm). Bilirubin concentration and transaminase activities were all within the reference ranges. His serum cholesterol concentration was normal (4.86 mmol/l). Plasma chenodeoxycholic acid concentration was 1.6 $\mu\text{mol/l}$, which is within the physiological reference range. Skeletal radiographs confirmed complete healing of the rickets. Plasma 25-hydroxyvitamin D and vitamin E concentrations were at the upper limit of the reference range when his dietary intake was supplemented with 800 units of vitamin D and 200 mg of α -tocopherol acetate daily. The vitamin D supplement was subsequently reduced to 240 units daily and the alkaline phosphatase activity has remained normal.

Discussion

Without permission to do a liver biopsy it was difficult to estimate the extent of our patient's liver disease at the age of 4 years. It seemed unlikely that it was as severe as that of his brother, who had an established micronodular cirrhosis by the age of 3.8 years.² The index case had no signs of portal hypertension and plasma albumin concentration and clotting times were normal. The bilirubin concentration and transaminase activities, though persistently raised, were slightly lower than they had been at the age of 3 months. It would seem therefore that liver disease in siblings with 3β -hydroxy- Δ 5-

C_{27} -steroid dehydrogenase deficiency may progress at different rates. This may be related to the degree of synthesis of normal bile acids that occurs in the different siblings. In the absence of the normal 3β -hydroxy- $\Delta 5$ - C_{27} -steroid dehydrogenase enzyme, oxidation of 7α -hydroxycholesterol or 3β -hydroxy- $\Delta 5$ bile acids might be catalysed by hepatic 3β -hydroxy- $\Delta 5$ -steroid dehydrogenases not normally concerned in bile acid synthesis,⁴ or by similar enzymes in the gut flora.⁵ In the case of our patient, some glycocholic acid was found in bile—as much as 30% of the total C_{24} bile acids at the age of 4.3 years.

Our index case had severe pruritus. The concentration of cholic acid in his plasma was <4.3 $\mu\text{mol/l}$ (which is within the reference range) and chenodeoxycholic acid was undetectable. We must conclude, therefore, that pruritus can be caused either by bile acids with a 3β -hydroxy- $\Delta 5$ structure, or by the accumulation of something other than bile acids in patients with cholestasis.

Our patient continued to have severe malabsorption of vitamin D until treatment with bile acids was started. Treatment of his rickets required the use of calcitriol which, unlike dietary vitamin D, can be absorbed directly into the portal circulation.⁶

The rationale for treatment with bile acids has been given in the introduction to this paper. To create a roughly normal pool of bile salts it would have been necessary to give both cholic and chenodeoxycholic acid; cholic acid is not readily available for therapeutic use. On the other hand, chenodeoxycholic acid and ursodeoxycholic acid are extensively used to treat gall stones. Chenodeoxycholic acid is also effective in the treatment of another inborn error of bile acid synthesis, cerebrotendinous xanthomatosis, in which the aim of treatment is to give enough bile acid to inhibit cholesterol 7α -hydroxylase and hence reduce the synthesis of bile alcohols from cholesterol.^{7, 8} Ursodeoxycholic acid does not inhibit cholesterol 7α -hydroxylase,⁹ or suppress the production of abnormal metabolites in cerebrotendinous xanthomatosis.¹⁰ We wanted to suppress the synthesis of abnormal metabolites and so chenodeoxycholic acid seemed the best choice. Chenodeoxycholic acid has, however, some hepatotoxic properties when used in patients with gall stones,^{11, 12} and it is also considered to contribute to the damage to hepatocytes that occurs in patients with cholestasis.¹³ Thus before starting treatment with chenodeoxycholic acid we confirmed that concentrations of chenodeoxycholic acid were low in both bile and in blood, and during treatment we ensured that plasma concentrations did not rise above the physiological range.

The choice of dose of chenodeoxycholic acid that we used was somewhat empirical and based partly on the fact that 125 mg capsules are readily available. We estimated that a 4 year old boy with a normal pool of bile acids should synthesise and lose in the faeces about 3 mg/kg/day of bile acids and so this was the minimum dose.¹⁴ The dose of chenodeoxycholic acid used in adults for dissolution of gall stones and for

suppression of abnormal metabolite synthesis in cerebrotendinous xanthomatosis is about 12.5 mg/kg/day.⁷ Patients with cerebrotendinous xanthomatosis have some endogenous chenodeoxycholic acid synthesis and we felt that a higher dose may be required for our patient. Thus a dose of two capsules (18 mg/kg/day) was chosen, reducing to one capsule when there was no longer any biochemical evidence of cholestasis.

Clinically the benefit of chenodeoxycholic acid was evident within two weeks. The bilirubin concentration was normal within four weeks, and the aspartate transaminase activity by three months. This meant that we had a baseline of normal liver function tests against which to look for possible long term toxicity of chenodeoxycholic acid but none has been detected during almost two years.

In addition to the possible toxic effects of chenodeoxycholic acid, we had two other concerns about the treatment. The first was that if high doses of vitamin D were given, and absorption of fat soluble vitamins was stimulated by producing effective intestinal bile salt concentrations, our patient might develop the effects of hypervitaminosis D. Thus the calcitriol was discontinued before starting chenodeoxycholic acid, and a modest vitamin D supplement (800 units) was given. On this regimen no hypercalcaemia was detected and plasma 25-hydroxyvitamin D remained within the reference range. To avoid hypervitaminosis A, high doses of vitamin A were also avoided during treatment with chenodeoxycholic acid.

A second cause of concern was the possibility of raised serum concentrations of cholesterol during treatment with bile acids.¹⁵ Catabolism to bile acids is an important way of eliminating cholesterol. Treatment with chenodeoxycholic acid should reduce cholesterol catabolism by inhibiting cholesterol 7α -hydroxylase. The treatment should also improve absorption of cholesterol from the gut and these two mechanisms might together contribute to a rise in serum cholesterol concentration. While receiving treatment our patient's serum cholesterol concentration was within the reference range.

The success of treatment with chenodeoxycholic acid in 3β -hydroxy- $\Delta 5$ - C_{27} -steroid dehydrogenase deficiency makes it important that this diagnosis be considered in any child with chronic hepatitis particularly if it is accompanied by fat soluble vitamin malabsorption. The diagnosis can be made in any clinical chemistry laboratory by a colorimetric test on the urine (the Lifschütz reaction) and it can then be confirmed by fast atom bombardment mass spectrometry or gas chromatography/mass spectrometry in specialised centres.² If the latter methods are used to screen for inborn errors of bile acid metabolism, patients with reduced activity of 3-oxo- $\Delta 4$ -steroid 5β -reductase (the third enzyme in the sequence leading from cholesterol to chenodeoxycholic acid) will also be detected because the urine contains characteristic 3-oxo- $\Delta 4$ bile acids.^{16, 17} We would not advocate the use of chenodeoxycholic acid in these patients without careful assessment for a number of reasons.

Firstly, the patient may not have a primary defect of 3-oxo- Δ^4 -steroid 5 β -reductase but some other disease such as fumaryl acetoacetase deficiency.¹⁶

Secondly, plasma concentrations of chenodeoxycholic acid in these patients are usually considerably increased. It is likely that concentrations in hepatocytes are also increased and this may be damaging.¹³

Thirdly, experience has shown that chenodeoxycholic acid can be harmful. Giving chenodeoxycholic acid to one infant excreting 3-oxo- Δ^4 bile acids in his urine aggravated his cholestasis and transaminase activity increased (H Nazer, T Gunasekaran, J Sjövall, unpublished observations). Bilirubin concentration and transaminase activities then returned to pretreatment measurements when chenodeoxycholic acid was withdrawn.

- 1 Björkhem I. Mechanism of bile acid biosynthesis in mammalian liver. In: Danielsson H, Sjövall J, eds. *Sterols and bile acids. New comprehensive biochemistry*. Vol 12. Amsterdam: Elsevier, 1984:231-78.
- 2 Clayton PT, Leonard JV, Lawson AM, et al. Familial giant cell hepatitis associated with synthesis of 3 β , 7 α -dihydroxy- and 3 β , 7 α , 12 α -trihydroxy-5-cholenic acids. *J Clin Invest* 1987;79:1031-8.
- 3 Buchmann MS, Kvittingen EA, Nazer H, Gunasekaran T, Clayton PT, Sjövall J. Lack of 3 β -hydroxy- Δ^5 -C₂₇-steroid dehydrogenase/isomerase in fibroblasts from a child with urinary excretion of 3 β -hydroxy- Δ^5 -bile acids—a new inborn error of metabolism. *J Clin Invest* 1990 (in press).
- 4 Wikvall K. Purification and properties of a 3 β -hydroxy- Δ^5 -C₂₇-steroid oxidoreductase from rabbit liver microsomes. *J Biol Chem* 1981;256:3376-80.
- 5 Björkhem I, Gustafsson J-A. Mechanism of microbial transformation of cholesterol into coprostanol. *Eur J Biochem* 1971;21:428-32.
- 6 Maisolos M, Silver J, Fainaru M. Intestinal absorption of vitamin D sterols: differential absorption into lymph and portal blood in the rat. *Gastroenterology* 1981;80:1528-34.
- 7 Wolthers BG, Volmer M, van der Molen J, Koopman BJ, de Jager AEJ, Waterreus RJ. Diagnosis of cerebrotendinous xanthomatosis (CTX) and effect of chenodeoxycholic acid therapy by analysis of urine using capillary gas chromatography. *Clin Chim Acta* 1983;131:53-65.
- 8 Batta AK, Shefer S, Batta M, Salen G. Effect of chenodeoxycholic acid on biliary and urinary bile acids and bile alcohols in cerebrotendinous xanthomatosis; monitoring by high performance liquid chromatography. *J Lipid Res* 1985;26:690-8.
- 9 Heuman DM, Hernandez CR, Hylemon PB, Kubaska WM, Hartman C, Vlahcevic ZR. Regulation of bile acid synthesis. I. Effects of conjugated ursodeoxycholate and cholate on bile acid synthesis in chronic bile fistula rat. *Hepatology* 1988;8:358-65.
- 10 Koopman BJ, Wolthers BG, van der Molen JV, Nagel GT, Waterreus RJ, Oosterhuis HJGH. Capillary gas chromatographic determination of urinary bile acids and bile alcohols in CTX patients proving the ineffectivity of ursodeoxycholic acid treatment. *Clin Chim Acta* 1984;142:103-11.
- 11 Fisher RL, Anderson DW, Boyer JL, et al. A prospective morphological evaluation of hepatic toxicity of chenodeoxycholic acid in patients with cholelithiasis: the National Cooperative Gallstone Study. *Hepatology* 1982;2:187-201.
- 12 Phillips MJ, Fisher RL, Anderson DW, et al. Ultrastructural evidence of intrahepatic cholestasis before and after chenodeoxycholic acid therapy in patients with cholelithiasis: the National Cooperative Gallstone Study. *Hepatology* 1983;3:209-20.
- 13 Greim H, Trürlsch D, Czygan P, et al. Bile acids in human livers with or without biliary obstruction. *Gastroenterology* 1972;63:846-50.
- 14 Colombo C, Roda A, Roda E, et al. Bile acid malabsorption in cystic fibrosis with and without pancreatic insufficiency. *J Pediatr Gastroenterol Nutr* 1984;3:556-62.
- 15 Albers JJ, Grundy SM, Cleary PA, Small DM, Lachin JM, Schoenfield LJ. National Cooperative Gallstone Study. The effect of chenodeoxycholic acid on lipoproteins and apolipoproteins. *Gastroenterology* 1982;82:638-46.
- 16 Clayton PT, Patel E, Lawson AM, et al. 3-Oxo- Δ^4 bile acids in liver disease. *Lancet* 1988;iii:1283-4.
- 17 Setchell KDR, Suchy FJ, Welsh MB, Zimmer-Nechemias L, Heubi J, Balistreri WF. Δ^4 -3-Oxosteroid 5 β -reductase deficiency described in identical twins with neonatal hepatitis. A new inborn error in bile acid synthesis. *J Clin Invest* 1988;82:2148-57.