

Pathogenesis and management of aspergillosis in cystic fibrosis

SIR,—It is always a pleasure to read the lucid expositions produced in the papers of Dr Hiller. The annotation is timely and deals with a recurrent problem.¹ Unfortunately we would like to take issue with certain assertions made by Dr Hiller from the basis of the accumulated experience of the Bristol Cystic Fibrosis Clinic which one of the authors (FC) has run for the last 17 years. This clinical practice is rather similar to Dr Hiller's; currently our centre has 90 patients attending with cystic fibrosis. In Bristol a convincing case of bronchopulmonary aspergillosis producing lung damage has not been found. This does not imply that the possibility of making the diagnosis has not been enthusiastically pursued in many patients, but years spent attempting to establish definitive cases after our first publication² have disillusioned us as to the correctness of the reported frequency of this syndrome. The frequency of diagnosis presumably decreases with the increase in rigor with which the diagnosis is established. The central bronchiectatic lesion produced in asthmatic subjects and said to be characteristic in that annotation has not been encountered despite the enthusiastic and extensive use of standard chest radiography, computed tomography,

and even magnetic resonance imaging. Accordingly we do not believe that 'allergic bronchopulmonary aspergillosis is possibly underdiagnosed'. It is interesting that Bristol has so little experience of this 'complication' because the centre is an enthusiastic utiliser of nebulised antibiotics and only rarely utilises corticosteroids yet both these factors could increase the prevalence of the 'disease'. The immune reaction pattern in patients with cystic fibrosis in Bristol has been reported.³

The review also asserts that 'the major problem in cystic fibrosis is allergic bronchopulmonary aspergillosis in which tissue damage is due to the immune reaction of the host'. That is not established. Our most recent study⁴ reviews after 11 years the well documented patients who had positive immediate skin reactions to *Aspergillus fumigatus* as reported in our previous study. It is apparent from the figure showing forced expiratory volume in one second (FEV₁) that lung function deterioration has not been increased by the continuing presence of a positive skin test.

We would agree with Dr Hiller that at the present time the use of antifungal drugs is not warranted for such 'disease'. A multicentre trial of bronchopulmonary aspergillosis that has been proved on lung biopsy and using itraconazole or some other antifungal on a double blind basis would be required to establish the

importance of even such a tissue based diagnosis.

F CARSWELL

A HAMILTON

Royal Hospital for Sick Children,
St Michael's Hill,
Bristol BS2 8BJ

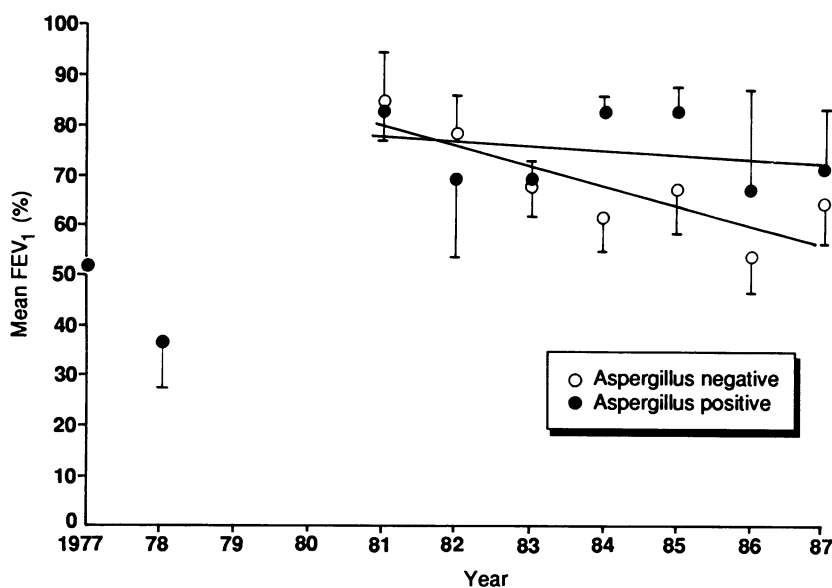
- Hiller EJ. Pathogenesis and management of aspergillosis in cystic fibrosis. *Arch Dis Child* 1990;65:397-8.
- Silverman M, Hobbs FDR, Gordon IRS, Carswell F. Cystic fibrosis, atopy, and airways liability. *Arch Dis Child* 1978;53:873-7.
- Carswell F, Oliver J, Silverman M. Allergy in cystic fibrosis. *Clin Exp Immunol* 1979;35:141-6.
- Hamilton A, Carswell F. The prevalence of cutaneous hypersensitivity and its relationship to pseudomonas colonisation and outcome in cystic fibrosis. *Clinical and Experimental Allergy* 1990;20:415-20.

Dr Hiller comments:

The incidence of diagnosed aspergillosis in cystic fibrosis clearly varies considerably, and the lack of cases in Bristol contrasts with the Leeds' experience published recently.¹ My statement that 'the major problem in cystic fibrosis is allergic bronchopulmonary aspergillosis in which tissue damage is due to the immune reaction of the host' is quoted out of context. I was discussing the different ways in which *Aspergillus fumigatus* can affect the lung, not the causes of lung damage in cystic fibrosis which are mainly the consequences of infection.

About one third of cystic fibrosis patients have a positive immediate skin test reaction to *A. fumigatus*, as I described, and from the Bristol data this alone does not appear to be associated with a more rapid decline in FEV₁ than that seen in patients with a negative skin test, though the numbers of patients in each group is not given. A positive skin test indicates an IgE response. Total and specific IgE concentrations have been shown to have no correlation with clinical scores or lung function,² whereas IgG antibody showed close correlation with both. The nature of the immune response presumably determines the degree of tissue damage, and must vary in different individuals.

- Simmonds EJ, Littlewood JM, Evans EGV. Cystic fibrosis and allergic bronchopulmonary aspergillosis. *Arch Dis Child* 1990;65:507-11.
- Forsyth KD, Hohmann AW, Martin AJ, Bradley J. IgG antibodies to *Aspergillus fumigatus* in cystic fibrosis—a laboratory correlate of disease activity. *Arch Dis Child* 1988;63:953-7.



Deterioration in FEV₁ in patients related to whether skin test positive or negative for *A. fumigatus* in 1977.