

## REJOINDER

## Blue breath holding is benign

J B P Stephenson

Southall *et al* described 51 infants and young children with recurrent episodes of cyanosis and loss of consciousness of whom 'eight died suddenly and unexpectedly'.<sup>1</sup> The authors alleged that 'these cyanotic episodes [which] included both intrapulmonary shunting and prolonged expiratory apnoea . . . are a cause of sudden unexpected death in infancy and early childhood'. Many readers will have inferred that the message of this article is that blue breath holding attacks carry a mortality, indeed a mortality of 16%.

I have recently had the opportunity to review the clinical features and mechanisms of the many syncopes and anoxic seizures that afflict the young.<sup>2</sup> In terms of outcome, these tend to fall into one of two groups, the hazardous and the benign. First there are those fits or faints in which a treatable component should be recognised by the doctor to avoid a substantial risk of brain damage or death. Examples include those anoxic seizures induced by forcible smothering<sup>3</sup> and those associated with ventricular tachyarrhythmias or sick sinus syndrome. Secondly there are those syncopes in which a negative feedback or fail safe mechanism normally operates, with automatic recovery however horrific the episode appears to the observer. Here, the doctor's main function is to provide reassurance and dissolution of parental anxiety. In this benign group I have placed breath holding attacks (cyanotic and 'mixed')<sup>2 (52-59)</sup> and so called 'reflex anoxic seizures'<sup>2 (69-92)</sup> (previously

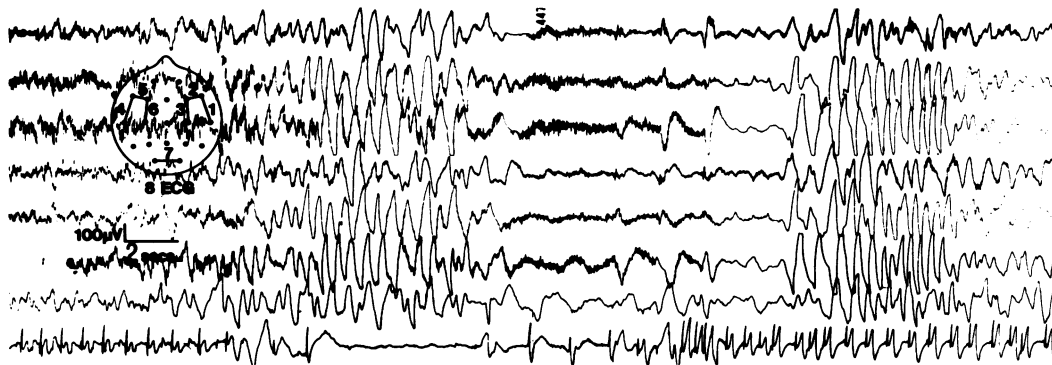
called 'white breath holding' attacks<sup>4</sup>). Indeed, the cornerstone of management of breath holding spells is that one says to the parents that *these attacks will not do harm*,<sup>5</sup> echoing well established opinion.<sup>6,7</sup>

Southall *et al* appear to have reached fundamentally different conclusions.<sup>1</sup> The writer of one editorial has interpreted their data as demonstrating a 15% mortality in a disorder perceived as similar to but not identical to breath holding.<sup>8</sup> It is therefore important to determine first whether the patients reported in the papers of Southall *et al* did have breath holding spells as usually understood, and if so whether their paper contains the scientific basis for breath holding spells having a high mortality and being a mechanism for sudden infant death.

## Is breath holding the subject matter?

Southall *et al* specified that 'In all 51 patients most of the cyanotic episodes began when the child was awake, usually after a naturally occurring stimulus such as pain, fear or anger resulting in a cry or an attempt to cry . . . Episodes commonly began with a series of expiratory cries without inspiratory efforts, often with a widely open mouth. Sometimes an episode began with a single prolonged cry that was silent, the expiratory apnoea beginning immediately'.

The authors stated that such episodes 'have been previously described as cyanotic breath



Ambulatory cassette recording (seven channel EEG, one channel ECG) of a breath holding spell. Time calibration bar on left of figure is two seconds. The slow-flat-slow appearance on the EEG indicates severe cerebral hypoxia. This begins at maximum forced expiration, coincident with the onset of eight seconds cardiac asystole. The asystole is neither a consequence of the hypoxia nor the cause of the EEG flattening, but reflects a strong simultaneous vagal discharge. 'Intrapulmonary shunting' is presumably minimal during such a cardiac standstill.

The figure is reproduced with permission from 'Fits and faints' by J B P Stephenson, published by Mac Keith Press/Blackwell Scientific, 1990 (see pages 47-54 and figure 7-8).<sup>2</sup>

Fraser of Allander Unit,  
Royal Hospital for  
Sick Children,  
Yorkhill,  
Glasgow G3 8SJ

Correspondence to:  
Dr Stephenson.

holding attacks', with a 'presentation . . . identical to that described as "cyanotic breath-holding"',<sup>1</sup> but as some have doubted this identity<sup>8</sup> I have sought further clarification. During a recent scientific meeting (Scottish Cot Death Trust SIDS Research meeting, Royal College of Physicians and Surgeons of Glasgow, 28 November 1990) Dr David Southall agreed that the patients he was talking about had *identical* cyanotic episodes to those which I had recorded on videotape.

This videotape was of two typical breath holding spells in a 15 month old girl as illustrated in the figure. To make this meaningful to the clinical reader, the history is briefly summarised:

Breath holding spells began aged 7 months, five days after diphtheria, pertussis, and tetanus immunisation. Their frequency varied from two to six or more daily. Rarely there had been two days without spells, but more usually the interval was two hours. Provocations included being frightened or her mother going out of the room, but were not always obvious. The parents' description was 'starts to cry, doesn't really cry, no cry come out, goes blue bluey-red darkish, stiffens up arms out straight, head back, unconscious'. Because some of these breath holding spells were followed by rhythmic limb twitching for up to three minutes ('anoxic-epileptic' seizures,<sup>2 (112 135)</sup> videorecording and cassette electroencephalography (EEG)/electrocardiography (ECG) recording was undertaken. A total of 15 spells were recorded, all anoxic rather than anoxic-epileptic. Continuous rapid (3 per second) expiratory grunting led to rapid cyanosis and opisthotonus with EEG flattening within 40 to 45 seconds. Vocalisation was then followed by a stare and chewing while the EEG showed high voltage slow waves; alertness returned about 70 seconds after onset. The ECG showed bradycardia with asystole of 2-8 seconds beginning just before first signs of hypoxic EEG change, but this had no obvious additional effect on the clinical or EEG changes and atropine did not prevent the appearance of the spells in their usual form. Ocular compression induced simultaneous 2-3 per second expiratory gasping and asystole for 7 seconds, with no obvious loss of consciousness and only minor EEG slowing (2-2.5 cycles per second for 4 seconds). At the age of 2.5 years spells continued at the same rate, but the parents did not wish treatment. The child showed strong personality and good intelligence.

#### Is cyanotic breath holding dangerous?

In a previous paper Southall *et al* state: 'The rapid onset of severe hypoxaemia suggest[s] that this form of apnoea [cyanotic breath holding] may be an important cause of sudden death . . . the fact that none of the subjects reported here has died leaves the relation to SIDS open to further investigation'.<sup>9</sup>

This recent paper provides no scientific support for the suggestion that there is an excess of sudden unexpected death in those with prior breath holding spells.<sup>1</sup> There is no means by which the reader can tell from what population the 51 infants and young children who form the subject matter originated. Of the four children who are said to have died in a cyanotic attack, one had a repaired tracheo-oesophageal fistula, one a cleft palate, and the remaining two suffered developmental delay and (iatrogenic) tracheostomy. Of these two latter children one (case 23) must surely have had *primary* progressive cerebral atrophy (but the neuropathology is not reported), and the details of the other (case

18) are totally inadequate. As the only case in which extraordinary intrapulmonary shunting is suggested by the very limited evidence provided, case 18 surely must be published in full.

Four additional boys are cited as having died suddenly and unexpectedly after earlier typical breath holding attacks. One was found to have a brainstem glioma.<sup>10</sup> In the remaining three, there are no population data or other way of knowing whether this coincidence was improbable, that is, not expected by chance. My only surprise is that more examples were not discovered.

There is a potential second hypothesis (not explicitly introduced in the opening to the article by Southall *et al*<sup>1</sup>) that a novel form of intrapulmonary shunting is the basis of cyanotic breath holding spells, but is not clear why their results cannot be explained by a combination of low lung volume and rapid oxygen consumption.<sup>11 12</sup>

A third hypothesis, combining these two, is that intrapulmonary shunting is a mechanism for sudden death. As I have alluded to above, the terminal events in case 18 seem to bear precisely on this question. Adequately documented details would allow the reader to judge this issue.

#### Literature review

Southall *et al* appear to ignore the extensive studies on breath holding spells undertaken by the authors of yesteryear, whether on prognosis<sup>6 7</sup> or regarding mechanism.<sup>11 12 13</sup> The extensive studies of Gastaut<sup>2 (187 8) 14</sup> receive no mention. No consideration is given to the observation that apparently vagal mediated asystole may occur in a child who also has cyanotic breath holding on other occasions,<sup>6 7 13</sup> nor to the observation that vagal asystole may also be a part of so called 'mixed' breath holding, as in the figure.

#### Clinical criticisms

The authors clearly believed the parents that their children's episodes were life threatening, and the death of a number of children would bolster that belief: 'Investigations . . . and uncontrolled trials of treatment were considered essential . . . the need for resuscitation [my italics], and ethical concerns limited the information that could be collected'.<sup>1</sup> It is a difficult and delicate area in which to venture (the more so with the authors' dedication to four of the children) but the question has to be asked, if the prognosis was worse than expected from previous studies, whether any aspect of management might have tilted the balance in an adverse direction. It has long been known that tracheostomy does not prevent cyanotic breath holding.<sup>12</sup>

#### Future studies

I am not convinced that Southall *et al* have demonstrated an excess mortality from breath holding spells in otherwise healthy children. None the less hints of autonomic disturbance

may deserve further study,<sup>8 15 16</sup> provided investigators—even in the face of daily and severe attacks—can withstand the temptation to ‘resuscitate’ or give uncontrolled treatments.

Insufficient attention has been paid to the neurological basis of the active expiration which is an essential feature of breath holding attacks, but which may also be seen in those pallid syncopes (associated with cardiac asystole) induced by ocular compression in the laboratory.<sup>13</sup> Obviously the oculorespiratory reflex is no more involved in natural breath holding than is the oculocardiac reflex in those ‘reflex anoxic seizures’ mediated by cardiac asystole, but it can be studied safely and ethically<sup>17</sup> and it is not confined to man. What is self evident is that if continued brainstem neuronal drive is necessary to inhibit active inspiration and/or cardiac systole, then sufficient hypoxia and/or ischaemia must reverse this inhibition.

### Summary

In their recent publication in this journal, Southall *et al* described typical cyanotic breath holding spells, both in otherwise healthy children and in those with brainstem lesions and other malformations.<sup>1</sup> Their suggestions regarding possible autonomic disturbances may require further study, but they have adduced no scientific evidence to contradict the accepted view that in the intact child blue breath holding spells are benign.

Those families in which an infant suffers an ‘apparently life threatening event’ deserve immense understanding and help, and it behoves investigators to exercise extreme care and self criticism in the presentation of new

knowledge which may bear upon their management and their morale.

- 1 Southall DP, Samuels MP, Talbert DG. Recurrent cyanotic episodes with severe arterial hypoxaemia and intrapulmonary shunting: a mechanism for sudden death. *Arch Dis Child* 1990;65:953–61.
- 2 Stephenson JBP. *Fits and faints*. London: Mac Keith Press/Blackwell Scientific, 1990.
- 3 Meadow R. Suffocation, recurrent apnea, and sudden infant death. *J Pediatr* 1990;117:351–7.
- 4 Stephenson JBP. Reflex anoxic seizures (‘white breath-holding’): nonepileptic vagal attacks. *Arch Dis Child* 1978;53:193–200.
- 5 Stephenson JBP. Prolonged expiratory apnoea in children. *Lancet* 1985;ii:953.
- 6 Lombroso CT, Lerman P. Breathholding spells (cyanotic and pallid infantile syncope). *Pediatrics* 1967;39:563–81.
- 7 Laxdal T, Gomez MR, Reiher J. Cyanotic and pallid syncopal attacks in children (breath-holding spells). *Dev Med Child Neurol* 1969;11:755–63.
- 8 Hunt CE. Relationship between breath-holding spells and cardiorespiratory control: a new perspective. *J Pediatr* 1990;117:245–7.
- 9 Southall DP, Talbert DG, Johnson P, *et al*. Prolonged expiratory apnoea: a disorder resulting in episodes of severe arterial hypoxaemia in infants and young children. *Lancet* 1985;ii:571–7.
- 10 Southall DP, Lewis GM, Buchanan R, *et al*. Prolonged expiratory apnoea (cyanotic ‘breath-holding’) in association with a medullary tumour. *Dev Med Child Neurol* 1987;29:789–93.
- 11 Gauk EW, Kidd L, Prichard JS. Mechanism of seizures associated with breath-holding spells. *N Engl J Med* 1963;268:1436–41.
- 12 Gauk EW, Kidd L, Prichard JS. Aglottic breath-holding spells. *N Engl J Med* 1966;275:1361–2.
- 13 Maulsby R, Kellaway P. Transient hypoxic crises in children. In: Kellaway P, Petersen I, eds. *Neurological and electroencephalographic correlative studies in infancy*. New York: Grune and Stratton, 1964:349–60.
- 14 Gastaut H. A physiopathogenic study of reflex anoxic cerebral seizures in children (syncopes, sobbing spasms and breath-holding spells). In: Kellaway P, Petersen I, eds. *Clinical electroencephalography of children*. Stockholm: Almqvist and Wiksell, 1968.
- 15 Kahn A, Rebuffat E, Sottiaux M, Muller MF, Bochner A, Grosswasser J. Brief airway obstructions during sleep in infants with breath-holding spells. *J Pediatr* 1990;117:188–93.
- 16 DiMauro FJ, Chee CM, Berman PH. Pallid breath-holding spells. Evaluation of the autonomic nervous system. *Clin Pediatr (Phila)* 1990;29:17–24.
- 17 Blanc VF, Jacob J-L, Milot J, Cyrenne L. The oculorespiratory reflex revisited. *Canadian Journal of Anaesthesia* 1988;35:468–71.

## Cyanotic ‘breath holding’ and sudden death

M P Samuels, D G Talbert, D P Southall

Dr Stephenson raises an important issue concerning the risk of sudden death during cyanotic breath holding. Our recent paper describes investigations to understand further the *pathophysiological mechanisms* responsible for severe cyanotic breath holding and did not attempt to estimate the risks of this disorder.<sup>1</sup> To do this would require a population based study, ideally prospective in nature, in which there was almost complete follow up. The historical studies mentioned by Dr Stephenson are unable to confirm that no deaths occurred. Thus in the study of Laxdal *et al*<sup>2</sup> and Lombroso and Lerman,<sup>3</sup> 18% and 43% respectively were lost to follow up. One possible reason for a lack of response to posted questionnaires might have been the death of a child.

We trusted that readers would not automatically infer from reading our paper that there is mortality of 16% in cyanotic breath holding. As stated, our patients were at the severe end of the

spectrum and therefore not representative of the whole population of ‘breath holders’. Furthermore, Hunt in his recent editorial did not claim that 15% of breath holders die, but was specifically referring to our collection of patients.<sup>4</sup> Our cases were ‘selected’ by virtue of their referral to us by their paediatrician who, with the parents, was concerned about the severity of the hypoxaemic episodes.

Dr Stephenson omits to mention our own prospective population based study of sudden deaths between 1 and 5 years of age.<sup>5</sup> This involved the follow up of 9856 infants all of whom were tagged for future death by the Office of Population Censuses and Surveys. Two of the deaths between 1 and 5 years in these 9856 children occurred during cyanotic breath holding. Based on Lombroso and Lerman’s estimated incidence of cyanotic breath holding as 2·8% of all children,<sup>3</sup> around 276 of our 9856 cohort should have suffered from this