

Dysequilibrium/ataxic diplegia with immunodeficiency

Richard L Soutar, Ruth E Day

Abstract

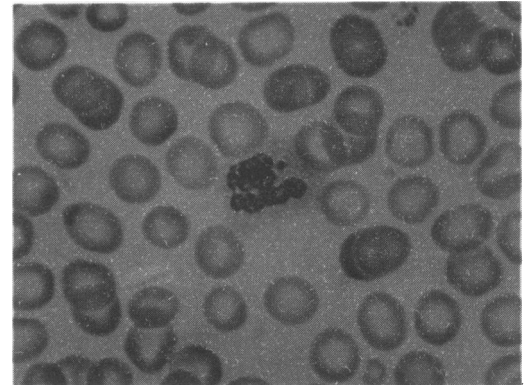
A girl with purine nucleoside phosphorylase (PNP) deficiency is described. The nature of the motor disorder is similar to other children since found to have PNP deficiency. It is suggested that the diagnosis be considered in any child with unexplained dysequilibrium/ataxic diplegia. Other previously unreported features are intracytoplasmic neutrophil inclusion bodies and an improvement in the neutropenia after intravenous immunoglobulin.

Severe congenital immunodeficiency states generally present with recurrent infections as maternal passive immunity declines. Children with purine nucleoside phosphorylase (PNP) deficiency can, however, present with a non-progressive motor disorder before the onset of the immunodeficiency giving an opportunity for treatment before secondary complications occur and for genetic advice. This requires a clearer definition of the nature of the motor disorder than had previously been available.

Case history

A 1 year old girl presented with delay in motor development. She had been rolling since 9 months, could sit supported only with a 'C' shaped back, and could not crawl or weight bear. She gave the appearance of hypotonia, although examination demonstrated slightly increased tone and brisk reflexes. She could use her hands crudely, tucking in her thumbs, but had a full range of supination. She appeared bright and alert. Birth had been normal with a birth weight of 4400 g. Her parents were healthy and unrelated. Computed tomography of the brain was normal. She learned to sit, propping herself, at 16 months and at 19 months was able to pull herself to standing. Although her balance remained very poor, she was able to walk with her hands held at 26 months and at 3 years take a few unsteady steps. Fine hand movements were mildly ataxic, her speech clear, and intellectual development normal.

At age 26 months she began to suffer severe recurrent urinary tract infections despite prophylactic antibiotic treatment. She had had no previous significant infections. Ultrasonography showed pelvicaliceal dilatation, progressing to frank hydronephrosis within six months. A micturating cystogram confirmed severe vesicoureteric reflux. Haematological indices were normal at 33 months.



Intracytoplasmic inclusion in peripheral blood neutrophil (haematoxylin and eosin stain $\times 1000$).

When admitted with a further urinary tract infection at 3 years she was noted to have oral candida, right cervical lymphadenopathy, and to be both neutropenic (neutrophil count $1.0 \times 10^9/l$) and lymphopenic (lymphocyte count $1.2 \times 10^9/l$). A bone marrow aspirate showed megaloblastoid nuclei, dyserythropoiesis, and myeloid maturation arrest with bizarre intracytoplasmic inclusion bodies; this was also seen in peripheral blood neutrophils (figure). Immunoglobulins were normal, tetanus toxoid antibodies were present in normal amounts, isohaemagglutinins were weakly present, nitroblue tetrazolium test was equivocal, and HIV antibody was negative. Total lymphocyte and T_4 and T_8 subset numbers were severely depressed ($0.4 \times 10^9/l$, $0 \times 10^9/l$, and $0.02 \times 10^9/l$ respectively) and were functionally unresponsive to mitogens. Adenosine deaminase activities were raised, however, and PNP was absent. Maternal and paternal values were 53% and 55% of normal respectively. A lymph node biopsy specimen showed lymphoblastic/immunoblastic non-Hodgkin's lymphoma.

Her clinical condition deteriorated and as there was no compatible bone marrow donor it was decided, after discussion, to give purely palliative lymphoma treatment. The child died 20 days later.

Discussion

PNP deficiency was first described in 1975.¹ Enzyme substrates inosine, deoxyinosine, guanosine, and deoxyguanosine accumulate and enzyme products urate and guanosine triphosphate are depleted. The principle systems affected are the lymphoid system and central nervous system.

Neurological dysfunction primarily affecting

Royal Hospital For Sick Children,
Glasgow
Richard L Soutar
Ruth E Day

Correspondence to:
Dr Richard L Soutar,
Department of Haematology,
Glasgow Royal Infirmary,
86 Castle Street,
Glasgow G4 0SF.

Accepted 20 April 1991

(Arch Dis Child 1991;66:982-3)

motor development is clearly recognised in association with PNP deficiency, often being the presenting feature.² The characteristics of the motor disorder have not been clearly defined, however, with previous papers referring to spastic quadriplegia or spastic diplegia.^{2,3}

Two siblings described as having familial dysequilibrium/diplegia with T lymphocyte deficiency⁴ have now retrospectively been found to have PNP deficiency, using cultured fibroblasts, at this hospital. Both parents had heterozygote values for PNP. These children were thought to be similar to those described by Hagberg *et al* as having familial ataxic diplegia with deficient cellular immunity.⁵ The four children described in these two papers, plus our own case, point to a fairly characteristic and identifiable clinical picture. This would seem to consist of a disequilibrium—that is, pronounced difficulty in maintaining posture and upright position giving rise to an early hypotonia, very unsteady and delayed sitting, and great difficulty in walking independently. In contrast there is either no, or only a mild, intention tremor or clumsiness. There is evidence of a spastic diplegia on clinical examination with brisk reflexes, upgoing plantars, and sometimes ankle clonus and restriction of passive dorsiflexion of the ankles. When walking this is masked by trunkal ataxia, however, particularly as the child gets older. The neurological picture appears to be non-progressive, may relate to the degree of guanosine triphosphate depletion and is non-infective in aetiology.² Intelligence may be normal as in this case.

The haematological and immunological consequences of PNP deficiency relate to the depressed T cell numbers and function, leading to repeated infections with viral illnesses often being the cause of death. These children should not receive live vaccinations. Lymphomas, often of a B cell origin, are also a complication of other immunodeficiency states, for example, AIDS, and have been described in PNP deficiency.³

Haematological findings in PNP deficiency are pure red cell aplasia, megaloblastic anaemia, autoimmune haemolytic anaemia,^{2,6} and maturation arrest at the myelocyte/metamyelocyte stage in bone marrow aspirates.³ Intracytoplasmic

neutrophil inclusions (figure) have not been previously described; they persisted after resolution of sepsis and in addition, identical inclusions were seen in the paternal blood film. Similar inclusions are well recognised during treatment with drugs that interfere with DNA synthesis such as azathioprine, chlorambucil, and appear to be fragments of DNA. DNA synthesis is impaired in PNP deficiency suggesting a similar aetiology.

Autoimmune disease is another complication of immune deficiency including PNP deficiency.² Suspecting the neutropenia to be immune mediated, we treated our patient with 2 g/kg intravenous immunoglobulin over two days. There followed a dramatic rise in the neutrophil count ($0.4-2.8 \times 10^9/l$). The patient had been persistently neutropenic for two months before this.

In conclusion, recognition of PNP deficiency before onset of severe infection or malignancy is important so that bone marrow transplantation from a suitable donor can be considered while the patient is well. Successful engraftment has already been documented in this condition.^{3,6} In addition, antenatal diagnosis is now possible for measuring PNP in chorionic villus samples. We consider familial dysequilibrium/diplegia with T lymphocyte deficiency and familial ataxic diplegia with deficient cellular immunity should no longer be considered separate disease entities, but reclassified as cases of PNP deficiency.

We thank Mr R Webber for his photographic and technical assistance.

- Giblett ER, Ammann AJ, Wara DW, Sandman R, Diamond LK. Nucleoside phosphorylase deficiency in a child with severely defective T-cell immunity and normal B-cell immunity. *Lancet* 1975; *i*:1010-3.
- Simmonds HA, Fairbanks LD, Morris GS, *et al*. Central nervous dysfunction and erythrocyte guanosine triphosphate depletion in purine nucleoside phosphorylase deficiency. *Arch Dis Child* 1987; *62*:385-91.
- Watson AR, Evans DK, Marsden HB, Miller V, Rogers PA. Purine nucleoside phosphorylase deficiency associated with a fatal lymphoproliferative disorder. *Arch Dis Child* 1981; *56*:563-5.
- Graham-Pole J, Gibson AAM, Stephenson JBP. Familial dysequilibrium-diplegia with T lymphocyte deficiency. *Arch Dis Child* 1975; *50*:927-32.
- Hagberg B, Hansson O, Liden S, Nilsson K. Familial ataxic diplegia with deficient cellular immunity. *Acta Paediatr Scand* 1970; *59*:545-6.
- Hong R. Diseases due to immunologic deficiency. In: Behrman RE, Vaughan VC, eds. *Nelson textbook of pediatrics*. Philadelphia: W B Saunders, 1987:461-7.

Fulminant hepatitis B in an infant born to a hepatitis Be antibody positive, DNA negative carrier

J Vanclaire, Ch Cornu, E M Sokal

Abstract

A boy was born to a mother who was a chronic hepatitis B virus (HBV) carrier. She was hepatitis Be (HBe) antibody positive and HBe antigen and HBV-DNA negative. The boy had

not received hepatitis B vaccine and died from fulminant hepatitis at 3 months of age. This case demonstrates the need to vaccinate babies of HBe antibody positive, HBe antigen negative carriers.

Catholic University
of Louvain,
Cliniques Universitaires
Saint-Luc, 1301,
B-1200 Brussels,
Belgium,
Department of
Paediatrics
J Vanclaire
E M Sokal

Department of Virology
Ch Cornu

Correspondence to:
Dr Sokal.

Accepted 2 April 1991
(*Arch Dis Child* 1991; *66*:983-5)