

A biotinidase K_m variant causing late onset bilateral optic neuropathy

V Th Ramaekers, T M Suormala, M Brab, R Duran, G Heimann, E R Baumgartner

Abstract

A patient with a newly recognised variant of biotinidase deficiency presented with acute loss of vision at the age of 10 years. Progressive bilateral optic neuropathy, spastic paraparesis, and a predominantly motor type neuropathy developed over the next five years. Metabolic investigations revealed biotin depletion causing multiple carboxylase deficiency. The basic defect was a biotin recycling disorder due to a mutant biotinidase with residual activity of 4.4% assayed routinely. Biocytin excretion in urine was only slightly increased. Further investigations on plasma biotinidase revealed biphasic kinetics with two different reduced values for maximum reaction velocity (V_{max}) and two for the Michaelis constant (K_m), one being almost normal and the other considerably raised. In contrast to this patient, two age matched children with partial biotinidase deficiency (2.8% and 2.9% of normal), but with a normal K_m for biocytin, remained asymptomatic. After six months of oral substitution with 10 mg biotin per day the coecentral and peripheral scotomata regressed, the pyramidal signs in the lower limbs disappeared, and further progression of the motor neuropathy arrested.

We conclude that the differential diagnosis of unexplained bilateral optic neuropathy of juvenile onset, particularly when associated with upper and lower motor neuron disease, should include biotinidase deficiency.

found. Despite rapid clinical and biochemical improvement after treatment with pharmacological doses of biotin, neurological damage such as sensorineural hearing loss, optic atrophy, ataxia, and mental retardation has been reported to persist.^{3 5 6} Since the introduction of neonatal screening a number of children with partial biotinidase deficiency have been detected of whom most have remained clinically asymptomatic.^{7 8} In the present paper a new variant of biotinidase deficiency with delayed onset of symptomatology is described. In addition the effect of biotin treatment will be presented.

Case report

The patient was the single child of healthy non-consanguineous parents born in Poland after an uneventful pregnancy and delivery; his birth weight was 3250 g. Neurodevelopmental progress and growth in the first decade were reported to have been completely normal. At the age of 10 years the patient complained of acute visual loss during the course of a 'flu'-like illness. Bilateral optic atrophy was found and visual acuity was decreased to 20/100 with small bilateral coecentral scotomata (see fig 1, upper section). Computed tomography, electroencephalography, and routine laboratory investigations gave normal results. He was treated empirically with parenteral vitamin B-12 but his vision continued to deteriorate. From the age of 14 he complained of fatigue, particularly after exercise, with weakness in the hands particularly when opening boxes or unscrewing bottles.

Upon referral at the age of 15 years visual acuity was 20/200 on the right and 20/400 on the left and a mixed colour discrimination defect of red-green and blue-yellow type was found. Both optic discs showed appreciable temporal pallor with increased retinal transparency along the temporal arcuate fibre bundles. Coecentral as well as peripheral scotomata had become enlarged (see fig 1, middle section). Other ocular findings were bilateral ptosis and mild chronic conjunctival injection. There was intense perspiration of the extremities but no signs of organ failure, alopecia, or dermatitis.

Psychometric assessment showed a full scale intelligence quotient of 90. There were no cranial nerve abnormalities apart from mild ptosis and lack of facial expression. In the upper limbs considerable thenar muscle wasting with finger fasciculation was observed and grip was very weak. In the lower limbs there was distal muscle wasting with bilateral pes cavus and hammer toes. His gait was stiff and shuffling but he was not ataxic. Tendon reflexes in the

Biotinidase deficiency represents an autosomal recessive inborn error of biotin metabolism causing late onset, biotin responsive, multiple carboxylase deficiency.¹⁻³ Biotinidase acts by recycling biotin through liberation from biocytin (ϵ -aminobiotinyl lysine) or from short biotinyl peptides formed during proteolytic degradation of the biotin dependent carboxylases: propionyl-CoA carboxylase (PCC; EC 6.4.1.3), 3-methylcrotonyl-CoA carboxylase (MCC; EC 6.4.1.4), pyruvate carboxylase (PC; EC 6.4.1.1), and acetyl-CoA carboxylase (ACC; EC 6.4.1.2.). In biotinidase deficiency biocytin is lost in urine⁴ leading to progressive biotin depletion and subsequently to multiple carboxylase deficiency.³

Biotinidase deficiency in its classical form usually presents during the first year of life with variable neurological signs (hypotonia, seizures, ataxia), dermatitis, alopecia, and recurrent infections. Metabolic acidosis and organic aciduria due to decreased activities of the biotin dependent carboxylases are inconsistently

Department of
Paediatrics and
Ophthalmology,
Technical University of
Aachen, Germany
V Th Ramaekers
M Brab
G Heimann

Metabolic Unit,
University Children's
Hospital, Basel,
Switzerland
T M Suormala
E R Baumgartner

Metabolic Unit,
University Children's
Hospital 'het Wilhelmina
Kinderziekenhuis',
Utrecht,
The Netherlands
R Duran

Correspondence to:
Dr V Th Ramaekers,
Department of Paediatrics,
Technical University
of Aachen, Pauwelsstrasse 30,
D-5100 Aachen,
Federal Republic of Germany.

Accepted 25 July 1991

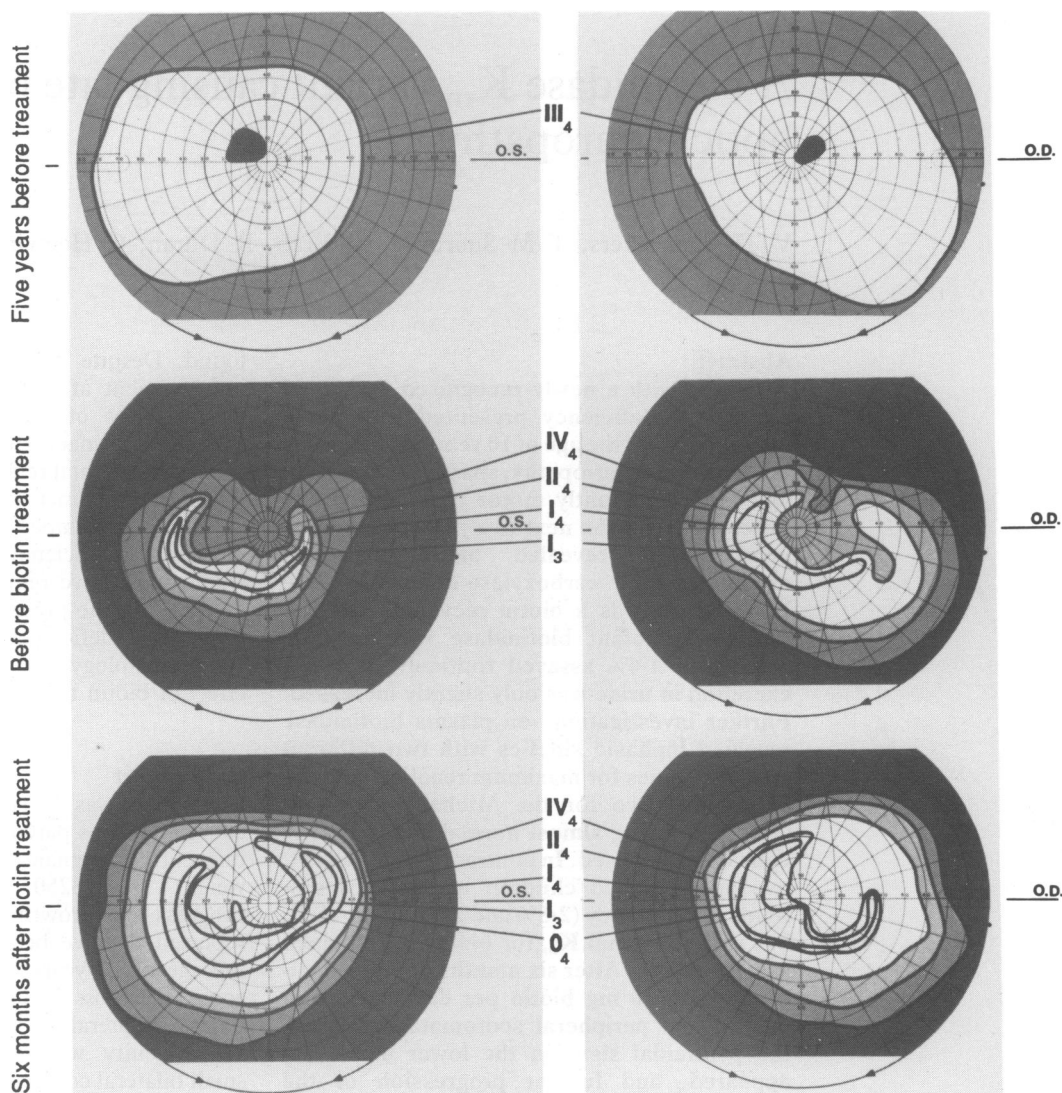


Figure 1 Visual fields. Top: initial examination at the age of 10 years in Poland showed an enlarged blind spot extending into the central visual field. Middle: at the age of 15 years the visual fields demonstrated enlarged coecocentral scotomas with wedgelike extensions into the temporal visual field breaking through to the periphery. Bottom: six months after treatment with 10 mg biotin/day the visual fields had improved with reduction of depth and extent of the coecocentral scotomas and opening up of the peripheral visual field borders. The roman numbers from 0 to IV represent the identification borders for differently sized object, from the size of 1/16 mm² (O) to 16 mm² (IV) respectively. Increasing light intensity is indicated by arabic numbers from 1 to 4. The most important scotomas have been shaded by a grey-white scale.

upper limbs were normal but in the legs they were symmetrically exaggerated with extensor plantar responses and ankle clonus. There was slight reduction of vibration sense distally in the lower limbs.

Electroneuromyography in median, tibial, and common peroneal nerves was consistent with severe neuroaxonal denervation. Motor and sensory conduction velocities were normal. Sensory nerve action potentials derived from the sural and median nerve were normal. Audiometry, brain stem and sensory evoked responses were also normal. The normal electroretinogram excluded any defects at the level of the retinal photoreceptor-ganglion cell unit. The pattern visual evoked response (stimulus size=80 minutes of arc) was extinguished on the right and equivocal on the left. Brightness stimuli showed plump responses with diminished amplitudes and prolonged latencies. The findings on electroretinography and from evoked visual responses suggested

severe axonal fibre loss and conduction disturbance.

In peripheral nerve, measurements of neurofilament density indicated shrinking of axons of myelinated nerve fibres but the ultrastructure of non-myelinated nerve fibres appeared normal. A muscle biopsy specimen showed light microscopic changes indicative of a slowly progressive neurogenic muscle atrophy.

Despite normal macroscopic appearance of skin and hair, microscopy of a skin biopsy specimen showed chronic inflammatory changes characteristic of chronic dermatitis. On light microscopy a conjunctival biopsy specimen showed extensive inflammatory changes consistent with chronic conjunctivitis.

Computed tomography, magnetic resonance imaging, electroencephalography, cardiac function, analysis of protein in the cerebrospinal fluid, and routine laboratory tests gave normal results. The first screening of urinary organic acid excretion showed a moderately raised

excretion of 3-OH-isovaleric acid and a trace of 3-OH-propionate (courtesy of Dr Lehnert, Freiburg). A colorimetric screening test for biotinidase was positive. Neurological assessment, ophthalmological and neurophysiological examination in both parents gave normal results. Other family members were not available for ophthalmological studies.

EFFECT OF BIOTIN TREATMENT

Before detection of the metabolic inborn error the patient's diet was normally balanced and was lacking food substances rich in biotin. After confirmation of partial biotinidase deficiency daily substitution with 10 mg biotin was started. After six months on biotin treatment the co-central scotomata regressed and peripheral visual fields showed recovery to near normal (fig 1, bottom section). Colour discrimination had also improved. These clinical findings could be substantiated by examination of his visual evoked responses. While pattern visual evoked response (representing the central 5–10° of arc) remained unaltered, the brightness stimuli demonstrated appreciable recovery of amplitudes and latencies. Subjective improvement with less fatigue over the daytime and after exercise was reported by the patient. After biotin supplementation further deterioration of the motor neuropathy arrested. Eight months after biotin supplementation the pyramidal signs in the lower limbs had disappeared.

Special biochemical studies

METHODS

Biochemical data obtained in the patient were compared with those of two age matched girls who had residual biotinidase activities of 2.8% and 2.9% of mean normal (table 1). In contrast to the patient these 15 year old girls appeared perfectly healthy and were neurologically normal.⁸

Informed consent was obtained from the parents and patient before the samples of blood, cerebrospinal fluid, and urine were collected. Organic acids were quantified using gas chromatography/mass spectrometry. Biotin concentrations were determined in plasma and urine samples by a microbiological assay using *Lactobacillus plantarum*-ATCC 8014.⁹ Biocytin

concentrations in urine were measured by a modified high performance liquid chromatography (HPLC).^{4,8} The activities of biotin dependent mitochondrial carboxylases (PCC, MCC, PC) in lymphocytes were measured before and after in vitro activation of apocarboxylases with excess of biotin as described previously.¹⁰ ACC activity was assayed in lymphocytes by measuring the citrate activated incorporation of [¹⁴C]-bicarbonate into malonyl-CoA.¹¹ Biotinidase activity in plasma was measured colorimetrically using 0.15 mmol/l biotinyl-p-aminobenzoate as substrate.¹² Kinetic studies on biotinidase were performed by a sensitive HPLC method that uses the natural substrate biocytin.⁸ Plasma from one of the girls with partial biotinidase deficiency was analysed in the same set of assays as that of the patient. To measure the maximum reaction velocity (\dot{V}_{max}) and Michaelis constant (K_m) for biotinidase initial velocities were measured using several biocytin concentrations varying from 0.00125 to 2.0 mmol/l assay mixture. The results were plotted using Eadie-Hofstee reciprocal plots, from which the respective \dot{V}_{max} and K_m values were derived.

Results

Before biotin treatment organic acid analysis showed only moderate abnormalities in urine with a slight rise of 3-OH-isovalerate of 30 $\mu\text{mol}/\text{mmol}$ creatinine (normal $8 \pm 4 \mu\text{mol}/\text{mmol}$) and a trace of 3-OH-propionate. Plasma concentrations of 3-OH-isovalerate (9 $\mu\text{mol}/\text{l}$), 3-OH-propionate (12 $\mu\text{mol}/\text{l}$), and 3-OH-butyrate (44 $\mu\text{mol}/\text{l}$) were also moderately increased. The latter organic acids, except for 3-OH-butyrate, are not normally detectable in plasma. However, in cerebrospinal fluid the concentration of 3-OH-isovalerate was 250 $\mu\text{mol}/\text{l}$, that is, 27 times the concentration in plasma. Plasma and cerebrospinal fluid lactate and pyruvate were all within the normal range. Tiglylglycine, methylcitrate, and 3-methyl-crotonylglycine were not detected in any of the body fluids investigated. Prompt response to biotin supplementation was shown after 24 hours by normalisation of 3-OH-isovalerate concentrations in plasma (1 $\mu\text{mol}/\text{l}$) and urine (9.7 $\mu\text{mol}/\text{mmol}$ creatinine). After four weeks a repeated lumbar puncture showed return of the 3-OH-isovalerate

Table 1 Biotinidase activity in plasma and kinetic parameters for plasma biotinidase calculated from Eadie-Hofstee reciprocal plots presented in figure 2

Subject	Activity (nmol/min/ml plasma)*	Kinetic parameters**		Factors†
		\dot{V}_{max} (nmol/min/ml plasma)	K_m ($\times 10^{-6}$ mol/l)	
Patient	0.275	$0.101 = \dot{V}_{max1}$ $2.38 = \dot{V}_{max2}$	$5.56 = K_{m1}$ $1000 = K_{m2}$	F=2495 p<0.0001
Girls with partial biotinidase deficiency:				
(1)	0.181	0.206	3.22	r=-0.984
(2)	0.172	0.135	3.27	r=-0.974
Patient's mother	6.76	7.35	3.44	r=-0.984
Patient's father	5.71	5.59	2.38	r=-0.966
Normal controls:				
Mean (SD)	6.24 (0.92)	5.86 (1.6)	3.06 (0.78)	
Range	4.59-8.25	3.60-8.50	2.10-4.88	
	(n=23)	(n=10)	(n=10)	

*Routine colorimetric method: biotinyl-para-aminobenzoate as substrate 0.15 mmol/l assay mixture. **HPLC method: biocytin as substrate (for details see text and reference 4). †r = Pearson correlation coefficient for linear regression lines using the least square method. F = F value as measure of significance of the curve fitting.

concentration in the cerebrospinal fluid to the normal range. Plasma biotin concentrations before biotin treatment were undetectable (table 2). The mitochondrial carboxylase activities in lymphocytes of the patient were appreciably decreased (12–20% of mean normal values), and ACC activity was within the normal range. Biotin responsiveness could be demonstrated in vitro by the normalisation of the carboxylase activities after preincubation with excess biotin. In the two girls with partial biotinidase deficiency the mitochondrial carboxylases were only moderately decreased to 30–58% of mean normal values.

Compared with controls and the girls with partial biotinidase deficiency the urinary biocytin excretion in the patient before and during biotin

treatment was slightly raised, but was only 10% compared with the mean of biocytin excretion determined in 11 patients with complete biotinidase deficiency (mean (SD): 24.9 (8.3) nmol/mmol creatinine, range: 10.6–36.6).

Biotinidase activity in the plasma of the patient measured by the colorimetric method was decreased to 4.4% of mean normal (table 1). Surprisingly, biotinidase activities in plasma of the parents were within the normal range (table 1).

The Eadie-Hofstee plots obtained from the kinetic analysis of biotinidase are shown in fig 2 and the calculated K_m and \dot{V}_{max} values are listed in table 1. The girls with partial biotinidase deficiency as well as the parents of the patient showed linear plots by the least square method. The kinetic parameters were within the normal range except that the girls with partial deficiency had a decreased \dot{V}_{max} . For the patient the plot was bilinear and could be resolved into two lines by computed least square fit according to the statistical methods used for resolving non-linear Scatchard plots.¹³ The data correlated best with the assumption of two different enzyme molecules with different kinetic properties ($F=2495$, $p<0.0001$). The first K_m with the lower \dot{V}_{max} of 1.7% of mean normal was only slightly above the normal range. The second K_m value with the \dot{V}_{max} of 41% of mean normal was 326 times the mean normal value. In the patient this kinetic pattern was reproducible in different fresh and stored plasma samples. Mixing experiments failed to show any inhibitory factors in his plasma.

Table 2 Biotin concentrations in plasma and biotin and biocytin concentrations in urine

Subject	Biotin treatment	Plasma biotin (nmol/l)*	Urine (nmol/mmol creatinine)	
			Biotin	Biocytin
Patient†	Nil	<0.4 (n=4)	0.67–3.6 (n=5)	0.87–2.4 (n=5)
	10 mg/day	67.5	308–3503 (n=8)	0.92–2.4 (n=8)
Girls with partial biotinidase deficiency†:				
(1)	Nil	0.66, <0.4	2.4–3.5 (n=3)	0.29–0.58 (n=3)
(2)	Nil	0.69, <0.4	3.0–8.0 (n=3)	0.26–0.33 (n=3)
Normal controls:				
Mean (SD)		1.77 (0.72)		
Range		0.90–4.14 (n=71)	2.7–141 (n=71)	0.05–0.53 (n=17)

*Limit of detection 0.4 nmol/l.

†The numbers in parentheses indicate the number of tests performed on different samples from the same patient.

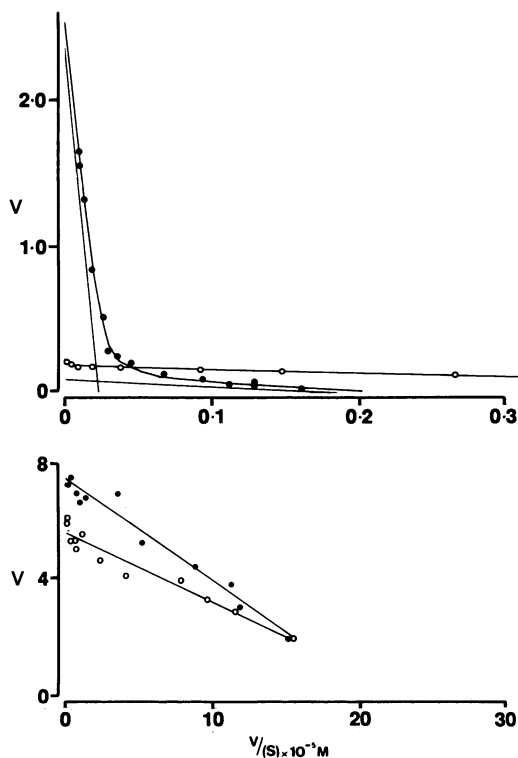


Figure 2 Eadie-Hofstee reciprocal plots of the plasma biotinidase assay data. The ordinate with the symbol V indicates the biotinidase enzyme kinetic activity in nmol/min/ml plasma. The abscissa represents the value for kinetic activity divided by the used biocytin substrate concentration in 10^{-3} mol/l. The upper part shows the data for the patient (closed circles) and for one of the age-matched girls (1) with partial biotinidase deficiency (open circles). The lower graph shows the data for the mother (closed circles) and father (open circles) of the patient. The plots were analysed either by computed least square fit (patient non-linear plot) or by the least square method (linear plots). The kinetic parameters calculated are listed in table 2. For details see text.

Discussion

This patient presented with acute onset optic neuropathy, spastic paraparesis, and a predominantly motor type neuropathy of the neuroaxonal type. At first the typical neuro-ophthalmological findings suggested Leber's hereditary optic neuropathy, most commonly a maternally inherited disease due to a mitochondrial DNA mutation.^{14, 15} However, in our patient there was no evidence for maternal transmission. Other distinguishing features were the presence of mild conjunctivitis and dermatitis, the latter being evident only on light microscopy. Our studies showed that the underlying defect in our patient is a biotin recycling disorder caused by a mutant biotinidase with biphasic kinetics. Phenotypic expression of classical biotinidase deficiency is highly variable; clinical features commonly include seizures, hypotonia, ataxia, breathing problems, hearing loss, optic atrophy, developmental delay, skin rash, conjunctivitis, and alopecia.^{3, 5, 6} Acutely ill patients may present with fungal infections probably due to abnormal immunoresponse. Most, but not all, symptomatic children exhibit metabolic acidosis and organic aciduria. The age of onset in 38 classical cases with biotinidase deficiency varied from 1 week to 2 years with a median age of 3 months.³

In our patient the first symptom was acute onset of bilateral optic neuropathy at the much later age of 10 years followed by other neurological abnormalities. He had no significant

organic aciduria and macroscopic skin or hair abnormalities were absent. Another surprising finding was the absence of hearing abnormalities, whereas the majority of symptomatic patients who were diagnosed late suffered from hearing loss. It should be emphasised that the history of our patient did not show any evidence of increased dietary intake of free biotin that might explain the delayed onset of clinical symptoms. Biotin treatment in our patient led to considerable improvement of the optic neuropathy, disappearance of pyramidal signs, and arrest of progression of the neuropathy. However the long term outcome is not yet known. In other patients with delayed onset of biotin supplementation there was prompt reversal of the metabolic derangement and of most clinical symptoms with the exception of optic atrophy and hearing abnormalities which persisted in some of them. The selective vulnerability of the central nervous system in biotinidase deficiency has been observed previously in a single case resembling Leigh's disease. This phenomenon was attributed to earlier depletion of biotin stores in the brain than in other tissues,¹⁶ which was confirmed by postmortem enzyme studies of brain, liver, and kidney.¹¹ In the present patient the 27-fold higher 3-OH-isovalerate concentration in cerebrospinal fluid compared with plasma supports this hypothesis.

The relationship between the unusual clinical course in our patient and the enzymatic findings is not understood. To our knowledge similar biphasic kinetics have never been observed in plasma of other patients with complete or partial biotinidase deficiency. In our patient biocytin excretion was significantly lower than in patients with complete biotinidase deficiency indicating a considerable recycling of biotin. On the other hand, biotin recycling in our patient was more severely compromised than in the girls with similar residual biotinidase deficiency but a normal K_m value. This is reflected by his 2-4 fold higher excretion of biocytin compared with the girls with partial deficiency.⁸ The absence of symptoms in these two 15 year old girls suggests that residual biotinidase activity as low as 2-3% with normal K_m maintains biotin concentrations high enough to result in sufficiently active carboxylases avoiding pathogenic consequences.⁸ However, in our patient similar residual activity in combination with an abnormal K_m does not allow sufficient recycling of biotin to prevent neurological abnormalities.

Further investigations are needed to clarify the molecular basis of the biphasic kinetics of this biotinidase K_m variant. It is of interest that biotinidase activity in the patient's parents was normal in contrast to the intermediate activity observed in parents of patients with complete or partial biotinidase deficiency.^{7, 8}

In conclusion we recommend looking for K_m

variants in biotinidase deficient patients with an unusual clinical course. Disorders of biotin metabolism should be included in the differential diagnosis of patients presenting with unexplained sudden visual failure as early detection and biotin supplementation will prevent visual or neurological deterioration. The basic screening for disorders of the biotin cycle should include both urinary organic acid analysis as well as the colorimetric biotinidase assay on plasma by using three different substrate concentrations. Testing of biotinidase activity at different substrate concentrations will roughly detect biotinidase K_m variants.

Part of this work was supported by the Deutsche Forschungs Gemeinschaft (German Research Foundation). The biochemical part of the work was supported by the Swiss National Science Foundation grant No 3.871-0.88. We thank Ms J Engler and her group (Department of Vitamin and Nutrition Research, F Hoffmann-La Roche and Co Ltd, Basel, Switzerland) for the biotin determinations in plasma and urine. Last but not least we are most grateful to Dr J Wilson (consultant paediatric neurologist, Hospital for Sick Children, London), for his expert advice and help in preparing the manuscript.

- Sweetman L, Nyhan WL. Inheritable biotin-treatable disorders and associated phenomena. *Annu Rev Nutr* 1986;6: 317-43.
- Wolf B, Grier RE, Allen RJ, Goodman SI, Kien CL. Biotinidase deficiency: the enzymatic defect in late-onset multiple carboxylase deficiency. *Clin Chim Acta* 1983;131: 273-81.
- Wolf B, Heard GS. Disorders of biotin metabolism. In: Scriver CR, Beaudet AL, Sly WS, Valle D, eds. *The metabolic basis of inherited disease*. New York: McGraw-Hill, 1989:2083-103.
- Suormala TM, Baumgartner ER, Bausch J, Holick W, Wick H. Quantitative determination of biocytin in urine of patients with biotinidase deficiency using high-performance liquid chromatography (HPLC). *Clin Chim Acta* 1988;177: 253-70.
- Wolf B, Heard GS, Weissbecker KA, Secor McVoy JR, Grier RE, Leshner RE. Biotinidase deficiency: initial clinical features and rapid diagnosis. *Ann Neurol* 1985;18:614-7.
- Wastell HJ, Bartlett K, Dale G, Shein A. Biotinidase deficiency: a survey of 10 cases. *Arch Dis Child* 1988;63: 1244-9.
- Secor McVoy JR, Levy HL, Lawler M, et al. Partial biotinidase deficiency: clinical and biochemical features. *J Pediatr* 1990;116:78-83.
- Suormala TM, Baumgartner ER, Wick H, Scheibenreiter S, Schweitzer S. Comparison of patients with complete and partial biotinidase deficiency: biochemical studies. *J Inherited Metab Dis* 1990;13:76-92.
- Frigg M, Brubacher G. Biotin deficiency in chicks fed a wheat-based diet. *Int J Vitam Nutr Res* 1976;46:314-21.
- Suormala TM, Wick H, Bonjour JP, Baumgartner ER. Rapid differential diagnosis of carboxylase deficiencies and evaluation of biotin responsiveness in a single blood sample. *Clin Chim Acta* 1985;145:151-62.
- Baumgartner ER, Suormala TS, Wick H, et al. Biotinidase deficiency: a cause of subacute necrotizing encephalomyelopathy (Leigh syndrome). Report of a case with lethal outcome. *Pediatr Res* 1989;26:260-6.
- Knappe J, Brummer W, Biederbick K. Reinigung und Eigenschaften der Biotinidase aus Schweineieren und *Lactobacillus casei*. *Biochemische Zeitschrift* 1963;338: 599-613.
- Ziegler K. Misuse of nonlinear Scatchard plots. *Trends Biochem Sci* 1989;14:314-7.
- Singh G, Lott MT, Wallace DC. A mitochondrial DNA mutation as a cause of Leber's hereditary optic neuropathy. *N Engl J Med* 1989;320:1300-5.
- Wallace DC. Maternal genes: mitochondrial diseases. In: McKusick VA, Roderick TH, Mori J, Paul NW, eds. Birth defects original article series. *Medical and experimental mammalian genetics: a perspective*. New York: Alan R Liss, 1987;23:137-90.
- Baker H, Frank O, DeAngelis B, Feingold S. Vitamins in human blood and cerebrospinal fluid after intramuscular administration of several B-vitamins. *Nutrition Reports International* 1983;27:661-70.