

MEDICAL MEMORANDA

Pancreatic Ascites Treated by Irradiation of Pancreas

HYMIE KAVIN, JACK D. SOBEL, ALON J. DEMBO

British Medical Journal, 1971, 2, 503-504

Ascites in an alcoholic is usually due to cirrhosis of the liver. Massive ascites, however, can complicate chronic pancreatitis (Cameron *et al.*, 1967) and surgery is regarded as the treatment of choice (Cameron *et al.*, 1969). We describe a case of pancreatic ascites successfully treated by a single dose of irradiation to the pancreas when definitive surgery was impossible.

Case History

A 46-year-old white man was admitted to hospital in December 1969 because of epigastric pain, progressive abdominal distension, and loss of 16 kg in weight. He had been drinking about 1 litre of whisky or gin daily for 25 years. In 1967 he had been admitted to hospital for chronic relapsing pancreatitis and pancreatic pseudocyst, but had refused surgery and discharged himself.

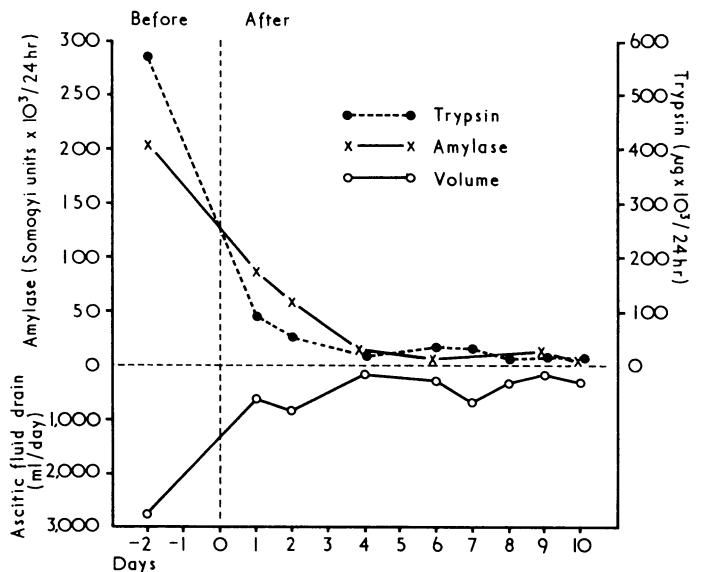
He was cachectic and had massive ascites. There was no hepatomegaly, splenomegaly, or evidence of liver failure. The full blood count, serum urea and electrolytes, serum lipids, bromsulphalein retention, prothrombin time, serum aspartate aminotransferase, bilirubin, and alkaline phosphatase were normal. The serum albumin was 2.6 g/100 ml, globulin 4.2 g/100 ml. The Westergren erythrocyte sedimentation rate was 95 mm in the first hour. A glucose tolerance test showed a fasting blood sugar of 95 mg and a two-hour value of 120 mg/100 ml. Faecal fat excretion was 5.1 g/24 hours. Barium-meal examination showed nothing abnormal and pancreatic calcification was not noted. An oral cholecystogram was normal.

Ascites secondary to alcoholic cirrhosis was diagnosed and treatment was begun with salt restriction and diuretics. When there was no response an alternative diagnosis was sought. Liver biopsy material was normal. Ascitic fluid contained protein 4.1 g/100 ml, amylase 3,160 Somogyi units/100 ml, and no cells. The serum amylase varied from 250 to 1,820 Somogyi units/100 ml. On the basis of these findings pancreatic ascites was diagnosed.

At laparotomy the liver was found to be normal, but owing to extensive fat necrosis in the omentum and numerous thick fibrinous adhesions careful dissection of the pancreas was impossible. A pseudocyst was not identified and pancreatography could not be performed. A peritoneal catheter was left in situ and the abdomen closed. About 3 litres of ascitic fluid containing large quantities of amylase and trypsin drained daily and the patient's general condition rapidly deteriorated.

On the 13th postoperative day it was decided to irradiate the pancreas. One anterior and one posterior field were used, both 20 by 8 cm, and a single treatment (500-rad skin dose) was given to each via an orthovoltage machine. (The factors were 200 kV, filter 0.5 mm copper, half-value layer 1.0 mm copper.) The estimated

dose at the midline was 112%, which is approximately 560 rads to the pancreas. Within 24 hours there was a dramatic decrease in ascitic fluid output and in its enzyme content (see Chart). By 10 days drainage almost ceased and the catheter was removed. For 14 days after radiotherapy the patient had severe non-infective diarrhoeas which required symptomatic therapy. By three months, however, he had gained 15 kg, and his general condition was much improved. At this stage a glucose tolerance test showed a



Ascitic fluid volume and enzyme concentration before and after irradiation of the pancreas.

two-hour blood glucose of 175 mg/100 ml. The serum albumin was 2.12 g/100 ml and daily stool fat excretion 8g. Duodenal aspirate after a test meal (Lundh, 1962) contained a mean two-hour amylase concentration of 491 Somogyi units/ml (normal above 620 units/ml) and a mean two-hour trypsin concentration of 555 µg/ml (normal above 600 µg/ml). Eight months postoperatively there was no recurrence of ascites and the serum albumin was 4.12 g/100 ml. He had gained a further 11 kg in weight and was asymptomatic.

Comment

Disruption of the pancreatic duct system in chronic pancreatitis is usually followed by localization of the free exocrine secretions by surrounding tissue reaction and the formation of a pseudocyst. When this reaction is incomplete the liberated secretions act on the peritoneal lining and large amounts of enzyme-rich fluid with properties of an exudate accumulate.

Most workers claim good results from duct drainage in pancreatic ascites. The purpose of radiotherapy is quite different—it is to inhibit enzyme secretion and thus allow the disrupted duct to seal. Animal studies (Orndorff *et al.*, 1926; Rauch and Stenstrom, 1952) and evidence in man (Wachtfeldl and Vitez, 1968) indicate that irradiation of the pancreas inhibits secretion within hours. Normal function returns in one to three weeks, and permanent morphological changes are rare, even after high doses (Volk and Wellman, 1968). Moreover, cutaneous pancreatic fistulae have been successfully treated with irradiation (Culler, 1920; Volkova and Sarova,

Johannesburg Hospital, Johannesburg, South Africa

HYMIE KAVIN, M.B., DIP. MED., Senior Physician, Gastrointestinal Unit

JACK D. SOBEL, M.B., F.C.P.S.A., Late Registrar

ALON J. DEMBO, M.B., B.CH., Intern

1964; Salek *et al.*, 1965). Unfortunately our patient was too ill for studies of pancreatic function immediately before and after radiotherapy, but irradiation clearly resulted in a rapid inhibition of exocrine pancreatic secretion. The effect was transient: 12 weeks later pancreatic function was only slightly impaired.

Though pancreatic ascites has resolved after conservative management and after diagnostic laparotomy (Barua *et al.*, 1962; Cameron *et al.*, 1969) the rapid cessation of pancreatic secretion after irradiation in our case clearly suggests a cause and effect relationship and that irradiation of the pancreas may be a useful treatment of pancreatic ascites, particularly when surgery is inadvisable or impossible.

We should like to thank Dr. H. M. Salmon, superintendent of the Johannesburg Hospital, for permission to report this case, and Mrs. Rosemarie Bunker for expert technical assistance. We are

indebted to the photographic unit, department of medicine, University of the Witwatersrand, for the Chart.

References

- Barua, R. L., Villa, F., and Steigmann, F. (1962). *American Journal of Digestive Diseases*, 7, 900.
 Cameron, J. L., Anderson, R. P., and Zuidema, G. D. (1967). *Surgery, Gynecology and Obstetrics*, 125, 328.
 Cameron, J. L., Brawley, R. K., Bender, H. W., and Zuidema, G. D. (1969). *Annals of Surgery*, 170, 668.
 Culler, R. M. (1920). *Journal of the American Medical Association*, 75, 20.
 Lundh, G. (1962). *Gastroenterology*, 42, 275.
 Orndorff, B. H., Farrell, J. I., and Ivy, A. C. (1926). *American Journal of Roentgenology*, 16, 349.
 Rauch, R. F., and Stenstrom, K. W. (1952). *Gastroenterology*, 20, 595.
 Salek, M., Lomsky, J., and Prensil, J. (1965). *Rozhledy v Chirurgii*, 44, 811.
 Volk, B. W., and Wellman, K. F. (1968). In *Gastrointestinal Radiation Injury*, ed. M. F. Sullivan, p. 73. Amsterdam, Excerpta Medica.
 Volkova, L. P., and Sarova, L. A. (1964). *Terapevticheski Arkhiv*, 36, 21.
 Wachtfeidl, V., and Vitez, M. (1968). *American Journal of Surgery*, 116, 853.

Intractable Hiccuping in Acute Myocardial Infarction

HAMID IKRAM, ROBIN T. ORCHARD, SUSAN E. C. READ

British Medical Journal, 1971, 2, 504

Intractable hiccuping severe enough to pose problems of management in acute myocardial infarction is rare. We report two cases.

Case Reports

Case 1.—A man aged 67 was admitted to hospital with an acute infarction of the posterior, lateral, and diaphragmatic areas of the heart. Two days later he developed severe paroxysms of hiccuping at about two-hourly intervals and lasting up to one hour. His clinical state deteriorated alarmingly during the paroxysms. A mixture of 5% CO₂ in oxygen was administered without effect. Chlorpromazine 25 mg intramuscularly and repeated after 30 minutes was also ineffectual, though it caused a pronounced fall in blood pressure. Blocking the left phrenic nerve was performed with 15 ml of xylocaine, and hiccuping stopped in 15 minutes and did not recur for three hours. There was no alteration in the blood pressure or cardiac

rhythm. The next spasm was milder and shorter in duration. The nerve block was repeated twice in the next two days and a similar response obtained each time. After each block the paroxysms were milder and eventually were controlled by chlorpromazine alone. They disappeared after eight days.

Case 2.—A man aged 65 developed distressing intermittent attacks of hiccuping three days after admission to hospital with an extensive acute myocardial infarction involving the anterior and lateral surfaces of the heart. On the fifth day hiccuping became almost continuous. Chlorpromazine 100 mg intramuscularly four-hourly to six-hourly failed to stop the hiccups and caused pronounced hypotension. Inhalation of 5% CO₂ was also unsuccessful. The patient was unable to sleep or eat. After left phrenic nerve block the hiccups decreased in severity and were controlled thereafter by chlorpromazine 25 mg intramuscularly as required.

Comment

The aetiology of hiccuping is poorly understood. It can be medicated by central mechanisms, as in encephalitis and brain-stem injury (Harrison *et al.*, 1962), and in renal disease. The commonest cause is a lesion in the vicinity of the diaphragm. The phrenic nerves constitute the motor path of the reflex arc. Blocking both phrenic nerves would cause complete diaphragmatic palsy and severe respiratory impairment. The common feature in our patients was involvement of the lateral surfaces of the left ventricle. This led us to block only the left phrenic nerve, and the satisfactory response suggests that involvement of the left phrenic nerve was a major factor in the development of the hiccuping.

Charing Cross Hospital, London WC2N 4DZ

HAMID IKRAM, M.B., M.R.C.P. (LOND., ED.), Senior Medical Registrar
 ROBIN T. ORCHARD, M.B., M.R.C.P., Medical Registrar
 SUSAN E. C. READ, M.B., B.S., Research Assistant

Reference

- Harrison, T. R., Adams, R. D., Bennett, I. L., Wintrobe, M. M., and Thorn, G. W. (editors) (1962). *Principles of Internal Medicine*, 4th edn., p. 1567. New York, McGraw-Hill.