

# ANCA associated glomerulonephritis in a patient with mixed connective tissue disease

G Hernández-Molina, E Reyes, J C Crispín

*Ann Rheum Dis* 2006;**65**:410–411. doi: 10.1136/ard.2005.039834

We report the case of a 47 year old woman with a 19 year history of mixed connective tissue disease (MCTD) diagnosed according to Alarcón-Segovia classification criteria.<sup>1</sup> She had Raynaud's phenomenon, arthritis, swollen hands, and anti-ribonucleoprotein antibodies (anti-RNP 1/1280). She received low doses of prednisone and her clinical course was uneventful, except for sporadic Raynaud's phenomenon. Her drug treatment was stopped 10 years ago, but medical supervision continued without evidence of pulmonary, gastrointestinal or renal disease during her follow up.

In 2003, she sought medical attention complaining of malaise during the past 3 months. Physical examination disclosed paleness, facial telangiectases, and hypertension (160/100). Laboratory findings were high—erythrocyte sedimentation rate (102 mm/1st h), normocytic/normochromic anaemia (haemoglobin 90 g/l), severely decreased renal function (creatinine had tripled to 250 µmol/l), and heavy proteinuria (6.5 g/day). Creatinine clearance was 20 ml/min. Urinary sediment exhibited dysmorphic red blood cells. Complement was normal and ANCA were positive with a perinuclear staining pattern (1/320). Previously, ANCA had not been determined. Anti-myeloperoxidase (MPO) specificity was detected (9.3 U; normal <9.0). Two days later her serum creatinine increased to 360 µmol/l. A renal biopsy was performed, yielding a necrotising glomerulonephritis with fibrocellular crescents (fig 1). Immunofluorescence was negative for immunoglobulins and complement. No other clinical or laboratory feature reminiscent of microscopic polyangiitis was found.

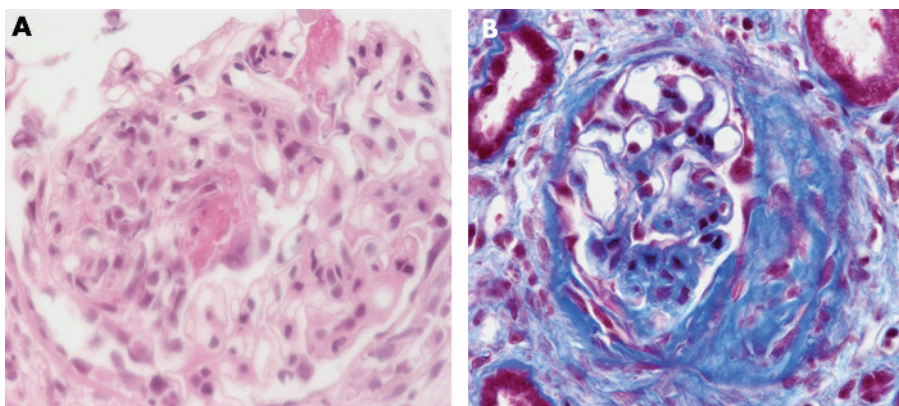
Methylprednisolone pulse therapy was started, followed by intravenous cyclophosphamide. The patient continued with prednisone and monthly cyclophosphamide (nine doses) and achieved complete remission after 6 months. Serum creatinine decreased to 100 µmol/l, proteinuria to 255 mg/day, creatinine clearance reached 55 ml/min, and the microhaematuria disappeared. Azathioprine was started as maintenance treatment. She has remained in complete clinical remission during the past 14 months.

This is an unusual clinical association, reported only once.<sup>2</sup> In both cases, patients with a clinically benign, longstanding MCTD developed a rapidly progressive glomerulonephritis with anti-MPO antibodies, and responded favourably to treatment.

Clustering of systemic and organ-specific autoimmune disease can occur in the same person or among several family members.<sup>3</sup> This finding led to the proposal of the concept named *shared autoimmunity*.<sup>4</sup> Accordingly, McDonagh and Isenberg reported at least one additional autoimmune disease in nearly 30% of a retrospective cohort of patients with systemic lupus erythematosus.<sup>5</sup> Thus, a person who has an autoimmune disease may be more susceptible to developing a second one. These associations are likely to be triggered by unknown factors in genetically predisposed subjects.

The coexistence of necrotising glomerulonephritis (NGN) with organ-specific or systemic autoimmune diseases has been reported.<sup>6</sup> Endo *et al* found anti-MPO antibodies in 6% of patients with systemic sclerosis (SSc) during the development of rapidly progressive renal failure.<sup>7</sup> Further, this entity has also been reported in about 10% of 112 renal biopsies from patients with rheumatoid arthritis (RA) and renal disease.<sup>8</sup> In this setting, is noteworthy the relationship between SSc and RA with NGN because findings similar to both conditions (SSc and RA) form part of the clinical manifestations grouped under the term MCTD.

The diagnostic and therapeutic procedure in a patient with MCTD who presents with rapidly progressive renal failure deserves some comments. Glomerulonephritis can be present in up to 20% of patients with MCTD. These glomerular diseases occasionally produce a rapid progressive renal failure.<sup>9</sup> In such a case, the presence of a scleroderma-like renal crisis must be strongly considered.<sup>10</sup> Finally, when rapidly progressive renal dysfunction develops in a patient with a collagen disease, ANCA associated NGN is another diagnostic consideration. A renal biopsy must be performed to rule out vasculitis because the treatment depends highly on the histological findings.



**Figure 1** (A) Necrotising glomerulonephritis in a patient with MCTD and (B) extracapillary proliferation and crescent formation.

.....  
**Authors' affiliations**

**G Hernández-Molina, J C Crispin**, Department of Immunology and Rheumatology, Instituto Nacional de Ciencias Médicas y Nutrición Salvador Zubirán, Mexico City, Mexico

**E Reyes**, Department of Pathology, Instituto Nacional de Ciencias Médicas y Nutrición Salvador Zubirán, Mexico City, Mexico

Acting editor A D Woolf.

Correspondence to: Dr J C Crispin Department of Immunology and Rheumatology, Instituto Nacional de Ciencias Médicas y Nutrición Salvador Zubirán, Vasco de Quiroga 15, Tlalpan 14000, Mexico City, Mexico; joseccrispin@yahoo.com

Accepted 5 July 2005

**REFERENCES**

- 1 **Alarcón-Segovia D**. Classification and diagnostic criteria for mixed connective tissue disease. *J Rheumatol* 1976;**3**:191.
- 2 **Makita N**, Katori H, Takemoto F, Yokota M, Kitamura Y, Ubara Y, *et al*. A case of mixed connective tissue disease complicated with MPO-ANCA-related necrotizing glomerulonephritis. *Clin Nephrol* 2000;**54**:164–8.

- 3 **Alarcón-Segovia D**, Alarcón-Riquelme ME, Cardiel MH, Caeiro F, Massardo L, Villa AR, *et al*. Familial aggregation of systemic lupus erythematosus, rheumatoid arthritis, and other autoimmune diseases in 1,177 lupus patients from the GLADEL cohort. *Arthritis Rheum* 2005;**52**:1138–47.
- 4 **Alarcón-Segovia D**. Shared autoimmunity: the time has come. *Curr Rheumatol Rep* 2004;**6**:1771–4.
- 5 **McDonagh JE**, Isenberg DA. Development of additional autoimmune disease in a population of patients with systemic lupus erythematosus. *Ann Rheum Dis* 2000;**59**:230–2.
- 6 **Tanemoto M**, Miyakawa H, Hanai J, Yago M, Kitaoka M, Uchida S. Myeloperoxidase-antineutrophil cytoplasmic antibody positive crescentic glomerulonephritis complicating the course of Graves' disease: report of three adult cases. *Am J Kid Dis* 1995;**26**:774–80.
- 7 **Endo H**, Hosono T, Kondo H. Antineutrophil cytoplasmic autoantibodies in 6 patients with renal failure and systemic sclerosis. *J Rheumatol* 1994;**21**:864–70.
- 8 **Harper I**, Cockwell P, Howie A, Richards M, Savage C, Wheeler D, *et al*. Focal segmental necrotizing glomerulonephritis in rheumatoid arthritis. *Q J Med* 1990;**90**:125–32.
- 9 **Bennet R**, Spargo B. Immune complex nephropathy in mixed connective tissue disease. *Am J Med* 1977;**63**:534–41.
- 10 **Sato K**, Imai H, Yasuda T, Wakui H, Mirua A, Nakamoto Y. Sclerodermatous renal crisis in a patient with mixed connective tissue disease. *Am J Kidney Dis* 1994;**24**:215–18.

# Three dimensional power Doppler ultrasonography confirms early reduction of synovial perfusion after intra-articular steroid injection

**J Strunk, K Strube, U Müller-Ladner, U Lange**

*Ann Rheum Dis* 2006;**65**:411–412. doi: 10.1136/ard.2005.041210

**H**yperaemia caused by vasodilatation is one of the earliest detectable pathological changes at the start of synovitis, and angiogenesis is an important feature of pannus formation, which has a crucial role in the maintenance of synovitis. Thus imaging of synovial perfusion and vasculature at the microvascular level by contrast enhanced magnetic resonance imaging (MRI) and power Doppler ultrasonography (PDUS) are promising methods of assessing and monitoring arthritic activity.<sup>1</sup> Several studies have shown a high correlation between MRI and PDUS determination of synovial perfusion.<sup>2–3</sup> A high correlation has also been found between MRI and PDUS imaging, on the one hand, and the histologically determined blood vessel density, on the other.<sup>4–5</sup>

Because measurement of synovial perfusion by PDUS is still difficult, most investigators use semiquantitative four step grading: 0 = no flow, 1 = mild flow, 2 = moderate flow, 3 = intense flow. Other approaches such as the computerised analyses of the number of colour pixels and the use of the resistance index have been reported to be helpful tools for measuring synovial hyperaemia.<sup>6–7</sup>

Recently, three dimensional (3D) PDUS has been described as a method which allows the spatial demonstration of synovial blood vessels in the peri- and intra-articular region of inflamed joints in patients with rheumatoid arthritis.<sup>8</sup> We used 3D imaging to assess changes in synovial vascularity after intra-articular steroid injection (triamcinolone 20–40 mg). Six patients with rheumatoid arthritis (four female and two male, mean age 54 years; four with wrist arthritis, one with knee arthritis, and one with elbow arthritis) and two patients with psoriatic arthritis (one female and one male, mean age 55 years; one with elbow and one with

acromioclavicular arthritis), who underwent injection during routine treatment, were studied. In a region with high Doppler signal intensity in conventional 2D power Doppler mode, a 3D volume was acquired by a free hand sweep. The online 3D power Doppler software (3D CPA) provided by the HDI 5000 (L12-5/38, ATL/Philips, Bothell, WA, USA) was used to generate a 3D image of a peri- and intra-articular blood vessel tree, in which grey scale information of the surrounding tissue was already subtracted. One of two experienced ultrasound investigators (JS or KS) performed the sonographic examination under supervision of the other before and after therapeutic injection (mean time 6.5 days). The degree of vascularity in the 2D mode was estimated using the above mentioned semiquantitative four step grading from 0 to 3. The architecture of the 3D blood vessel formation was evaluated with regard to morphological vascular patterns and their alterations during treatment.

Comparison of grading levels before and after steroid injection in the 2D mode showed a significant reduction of microvascular power Doppler flow ( $p < 0.01$ , sign test for paired samples). By means of 3D PDUS it was possible to discriminate between peri- and intra-articular blood vessels and to recognise unchanged periarticular vessels after steroid injection in 5/8 patients. A formerly strong and well established intra-articular 3D blood vessel tree disappeared after intra-articular injection in 7/8 patients.

These findings suggest that glucocorticosteroids may affect very early on, the endothelial cells and synovial blood vessels, because at the time of the second PDUS examination, effusion and joint swelling were still persistent, in contrast with the almost complete reduction of synovial blood flow in the examined region of interest. The opportunity to observe