

## ACCESSORY LOBES OF THE LIVER\*

CHARLES G. FRASER, M.D.

TUCSON, ARIZONA

GROSS ABNORMALITIES of the liver are rare in spite of its complex development. The more common gross abnormalities are irregularities in form, in the number of lobules, and in the presence of cysts. A less common abnormality is the occurrence of one or more accessory livers or lobes.

The normal liver of a pig, dog, and of a camel is divided into distinct and separate lobules by strands of connective tissue. Occasionally, the human liver may show this reversion in varying degrees. Moser<sup>5</sup> has described a liver with 16 lobes.

### EMBRYOLOGY

Bradley<sup>1</sup> has done much to elucidate the development of the mammalian liver. The liver begins as a ventral outgrowth of the entodermal tube. The primary vessels are the two vitalline veins which are invaded by liver tissue. Sooner or later the right umbilical vein begins to disappear. About the fifth week of embryonic life the left umbilical vein establishes a communication with the vascular plexus of the liver so that placental blood as well as blood from the intestines then passes through the liver. Soon after this a large channel, the ductus venosus, forms, connecting the proximal and distal vitalline sinusoids so that a large part of the placental blood is conveyed directly to the heart. It is believed that the mammalian liver consists essentially of three main lobes which develop about the

liver veins. The central lobe with its right and left lobules develops about the umbilical veins. The right lobe with its processus caudatus and processus spigelii grows along the right omphalomesenteric vein, and the left lobe along the left omphalomesenteric vein.

The cause of the fissures in the liver has not been fully explained and the picture is complicated by the possibility of mesodermic septa separating the liver into lobes at an earlier embryonic period.

### OCCURRENCE OF ACCESSORY LOBES

Most abnormalities of the liver due to accessory lobes are without clinical significance and are found either at necropsy or at the time of operation for another condition. These lobes are generally small and on the undersurface of the liver, so that they usually are not discovered clinically.

These accessory lobes may be attached to the liver by liver parenchyma or by a mesentery. If attached by a mesentery it must of necessity contain hepatic artery, hepatic vein, portal vein, and a bile duct in order to function.

Accessory lobes are found in numerous places. Three cases have been reported where an accessory lobe sprang from the gallbladder separately.<sup>2</sup> Several instances of accessory lobes found in the suspensory ligament appear in the literature.<sup>3, 4, 7</sup>

In one instance,<sup>2</sup> normal liver tissue was reported imbedded in the adrenal gland. An accessory liver lobe the size of a hazelnut was described<sup>2</sup> attached by a pedicle to the edge of the gastrohepatic ligament. Its vessels were thought to be independent of the liver but directly connected to the

\* Reviewed in the Veterans Administration and published with the approval of the Chief Medical Director. The statements and conclusions published by the author are the result of his own study and do not necessarily reflect the opinion or policy of the Veterans Administration. Submitted for publication April, 1951.

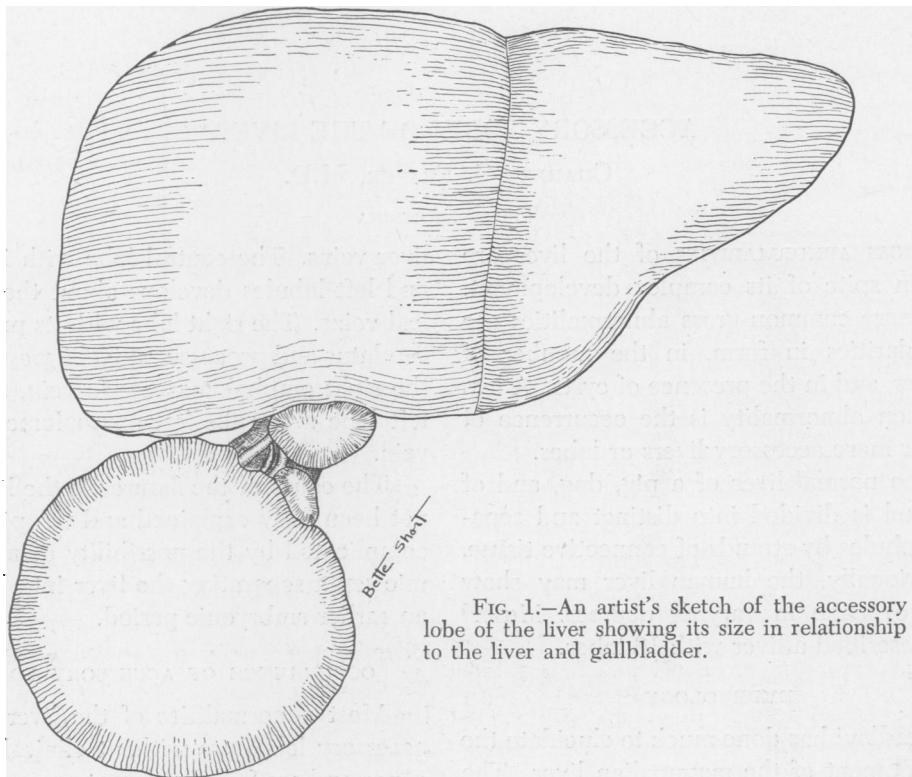


FIG. 1.—An artist's sketch of the accessory lobe of the liver showing its size in relationship to the liver and gallbladder.

common duct, portal vein, and hepatic artery.

When a portion of the diaphragm is congenitally lacking, part of the liver may be found in the pleural cavity. Sometimes the pleural portion is connected with the abdominal portion merely by a narrow pedicle of hepatic tissue.<sup>6</sup> A portion of liver has been found in an amniotic hernia at birth.<sup>2</sup>

#### CLINICAL SIGNIFICANCE OF ACCESSORY LOBES

The author has been able to trace just one incidence in which an accessory lobe demanded surgical intervention.<sup>2</sup> An accessory lobe 12 cm. in diameter attached to the right lobe of the liver became twisted upon its pedicle, causing strangulation of the accessory lobe and producing symptoms of epigastric pain, nausea, and vomiting. Abdominal exploration was imperative.

Riedel's lobe is common by comparison to the rare accessory lobes, but this down-

ward tongue-like projection of the right lobe of the liver into the iliac fossa seldom gives rise to symptoms. Because it is not an accessory lobe it need not be discussed further here.

This paper presents a case of a freely movable and easily palpable large tumor of the right quadrant due to an accessory lobe of the liver. Abdominal exploration was necessary to determine its true nature.

#### CASE HISTORY

Mr. A. is a 41-year-old male who has had chronic pulmonary tuberculosis for five years. During a routine physical examination an abdominal mass was discovered.

*General Physical Examination.* Aside from pulmonary tuberculosis, the general examination was negative. A firm mass, 12 cm. in diameter, was palpable in the right upper quadrant. The mass was movable, it could be separated from the liver edge, and it shifted with changes in position, being palpable in the right lower quadrant when the patient sat up.

*Laboratory Data.* Blood and urine studies were normal. I. V. pyelograms were negative ex-

cept for medial displacement of the lower right ureter. Gallbladder series were negative. Barium enema showed evidence of a tumor mass depressing the right side of the bowel in the region of the ascending and transverse colon.

*Course in the Hospital.* An abdominal exploration was then performed to determine the nature of the mass. An accessory lobe of the liver, 12 cm.

symptoms of strangulation until surgically relieved.

The author has presented a case of a large, movable accessory lobe of the liver which presented itself as an unexplained abdominal mass until exploration uncovered its true nature.

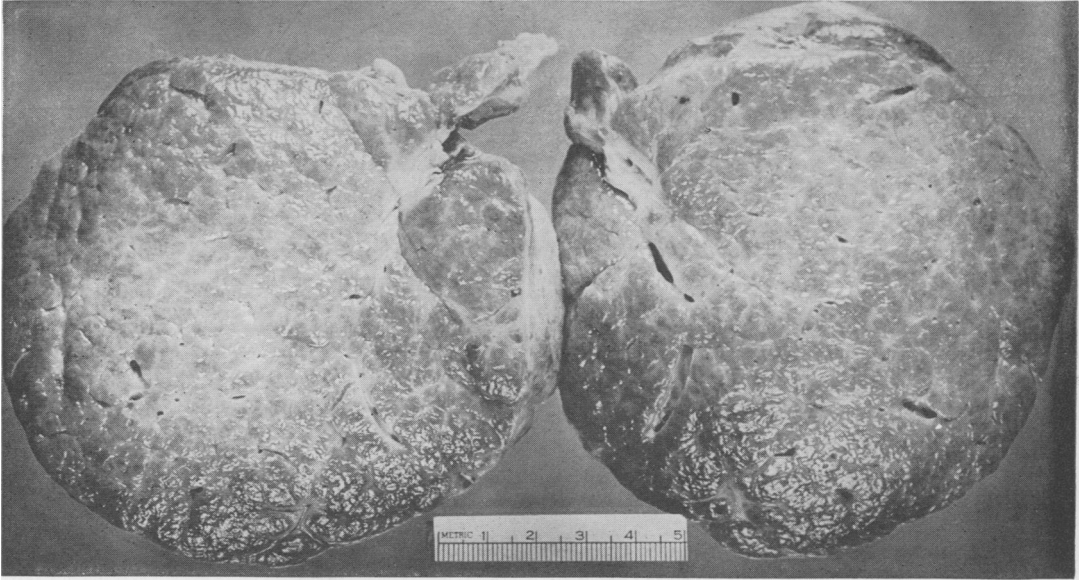


FIG. 2.—Cut section of the removed accessory lobe.

in diameter and 3 cm. in thickness (Figs. 1 and 2), was found near the gallbladder attached to the liver and gallbladder by a short, fibrous stalk through which passed an hepatic artery, an hepatic vein, a portal vein, and a bile duct. Microscopic examination of the liver lobule removed showed normal hepatic architecture with some degree of fibrosis. The accessory lobe was removed without incident.

#### SUMMARY

Although the embryonic development of the liver is complex and the early embryonic organ is multilobular, accessory lobes of the liver are very rare.

Because these accessory lobes are quite small and usually on the undersurface of the liver, before necropsy, they have made their presence known in only a few instances.

The literature contains a case record of a large accessory lobe, 12 cm. in diameter, which twisted on its pedicle, producing

This makes but two traceable instances in which abdominal exploration was undertaken due to the presence of an accessory lobe of the liver.

#### BIBLIOGRAPHY

- 1 Bradley, O. C.: A Contribution to the Morphology and Development of the Mammalian Liver. *J. Anat. & Physiol.*, **43**: 1, 1908-1909.
- 2 Cullen, T. S.: Accessory Lobes of the Liver; *Arch. Surg.*, **11**: 718, 1925.
- 3 Gruber, Wenger: *Beobachtungen aus der Menschlichen und Vergleichenden Anatomie.* Berlin 1879. Part 1, p. 48.
- 4 Kolb: *Wein Med. Wchnschr.*; pp. 1357-1404, 1868.
- 5 Moser, W.: A Liver with 16 Lobes. *Med. Rev.*, **53**: 671, 1898.
- 6 Pozzi, S.: *Hernie Diaphragmatique Gauche*; *Bull. Soc. Anat. de Paris*, **47**: 90, 1872.
- 7 Tarozzi, G.: *Osservazioni e Ricerche sopra le Inclusioni epatiche nel Legamento Triangolare sinistro del fegate Sperimentale.* *Arch. di Biol.*, **58**: 499, 1904.