

# THE PORTACAVAL VENOUS SHUNT

WITH SPECIAL REFERENCE TO SIDE-TO-SIDE PORTACAVAL ANASTOMOSIS\*

ALFRED LARGE, M.D., CHARLES G. JOHNSTON, M.D., AND  
D. E. PRESHAW, M.D.

DETROIT, MICHIGAN

FROM THE DEPARTMENT OF SURGERY, WAYNE UNIVERSITY COLLEGE OF MEDICINE, THE DETROIT RECEIVING HOSPITAL,  
AND THE DEARBORN VETERANS ADMINISTRATION HOSPITAL

In 1945 WHIPPLE<sup>1</sup> and Blakemore<sup>2</sup> established the feasibility of venous shunts for the treatment of patients with portal hypertension. The operation that they devised has been further developed and modified by Blakemore,<sup>3, 4</sup> Blalock,<sup>5</sup> Linton,<sup>6</sup> Welch<sup>7</sup> and others, and the procedure now has been done in a sufficient number of cases to prove its value in the treatment of bleeding esophageal varices. That the operation has not gained more widespread popularity we believe due chiefly to technical difficulties and dangers, and to lack of evidence that the shunt can be expected to remain open. There also seems to be little unanimity of opinion as to the exact type of venous anastomosis which is to be preferred. The present study was undertaken in an attempt to find a solution to some of these problems.

## EXPERIMENTAL

Using dogs as experimental animals, a simple and satisfactory method for portacaval anastomosis was developed. Part of the lumen of the vena cava was occluded by a special clamp† (Fig. 1) designed to

utilize the principle established by Joani,<sup>8a</sup> Stewart,<sup>8b</sup> and others, and popularized recently by Potts.<sup>9</sup> The anastomosis then was performed with everting sutures of fine silk, as shown in the accompanying illustrations (Figs. 2 and 3). It has been found that both complete (end-to-side) and partial (side-to-side) shunts of the portal blood may be performed without difficulty by using this technic. Side-to-side portacaval anastomoses were performed in 12 dogs, and the portal vein left open between the shunt and the liver (Fig. 3E) so that only a partial shunt of the portal blood was obtained. The animals were sacrificed at intervals of one month to one and a half years postoperatively and all 12 anastomoses were found to be widely patent at autopsy (Fig. 4). This indicates that venous shunts prepared in this way can be expected to remain open whether or not a pressure or flow differential exists at the point of anastomosis.

Liver function studies were performed upon animals after partial and complete shunt of the portal blood to the vena cava. These studies, which are reported in detail elsewhere,<sup>10</sup> showed (a) that bromsulphalein retention occurs to a greater degree in animals with complete shunt (Eck fistula) of the portal blood than in either those with partial shunts or in controls, and (b) that Eck fistula animals tolerate carbon tetrachloride poisoning poorly, develop

\* Published with permission of the Chief Medical Director, Department of Medicine and Surgery, Veterans Administration, who assumes no responsibility for the opinions expressed or conclusions drawn by the authors. Submitted for publication January, 1951.

† This clamp is made by the Sklar Instrument Manufacturing Company.

bromsulphalein retention and die much more rapidly than do controls or those with partial shunts.

#### CLINICAL

It may be inferred from the experiments just described that venous shunts for portal hypertension in the human ought to be performed in such a manner as to avoid complete diversion of the portal blood flow away from the liver. Side-to-side portacaval anastomosis or splenectomy with end-to-side splenorenal anastomosis would satisfy these requirements.

Such anastomoses have been performed in 18 patients. This number includes all the patients who have had venous shunt procedures done for portal hypertension at the Dearborn Veterans Administration Hospital and the Detroit Receiving Hospital since this study was begun early in 1948. Pre-shunt portal pressures were 250 mm. of water or over in all but two of the patients (Cases 11 and 15) whose pressure determinations were unsatisfactory but who presented other clear cut evidence of portal hypertension.

Several types of anastomosis have been used, but in general we prefer the portacaval anastomosis, which has been done in 13 patients. The technic is the same as that described for animals. Satisfactory exposure is obtained through a right upper abdominal approach. The operation is illustrated in Figures 5 and 6. It is particularly comforting to know from the animal experiments that the clamp may be applied so tightly to the vena cava that it cannot possibly slip off during the anastomosis, and yet that no damage to the vein wall need be feared. It has been found anatomically feasible to construct side-to-side anastomoses of this type in each of the 13 cases in which it has been attempted. For splenorenal anastomosis the same clamp is used as for the portacaval shunt, except that here it is used to occlude part of the lumen

of the left renal vein. The end of the splenic vein is then anastomosed to the side of the renal vein with everting sutures of fine silk.

Anticoagulants have not been used in any case because of the danger of wound hematoma and infection with possible subsequent thrombosis of the anastomosis, and because no anticoagulants were necessary in the experimental work.

#### RESULTS

Brief summaries of the 18 cases operated upon are given in Tables I, II and III. There were two operative deaths, an operative mortality of 11 per cent. The procedure most often done was side-to-side portacaval anastomosis, and the tables show that the overall results have been very satisfactory to date.

In Table I are included all patients who were operated on for bleeding esophageal varices and who did not have ascites. Of the 12 patients in this group, all had good liver function preoperatively, and nine excellent results were obtained. By "excellent" is meant that no further hemorrhage has occurred since operation, and that the patients are able to be up and about, and in most cases, can work. One of these patients (Case 2) merits special comment.

Case 2.—D. S., a 25-year-old white male, who had had a previous splenectomy for Banti's disease, was admitted to the hospital with massive exsanguinating upper gastro-intestinal hemorrhage. The bleeding was controlled by balloon tamponade, as described by Patton and Johnston.<sup>11</sup> Esophagogram revealed very extensive esophageal varices (Fig. 7A). It was felt that this patient had an extrahepatic obstruction of the portal vein, so that portacaval anastomosis would not be possible, and it was anticipated that the splenic vein would be thrombosed or too small to use for splenorenal anastomosis. Accordingly a side-to-side anastomosis was performed between the superior mesenteric vein and the inferior vena cava, below the level of the duodenum, as shown in Figure 8. The operation was accomplished without difficulty and the patient has been free of bleeding for the 2 years that have elapsed since operation. There is, however,

some evidence that his liver disease is slowly progressing. Esophagogram a year after operation revealed almost complete disappearance of the varices (Fig. 7B).

Three poor results occurred in this group of bleeders. Their case records may be summarized as follows.

Case 4.—M. B., a white female of 43 years, did not bleed from her varices following side-to-side portacaval anastomosis, but died as a result of progression of hepatic disease. She failed to follow medical advice, continued to drink large quantities of alcohol, and died in hepatic coma 6 months after operation. Autopsy disclosed a widely patent anastomosis.

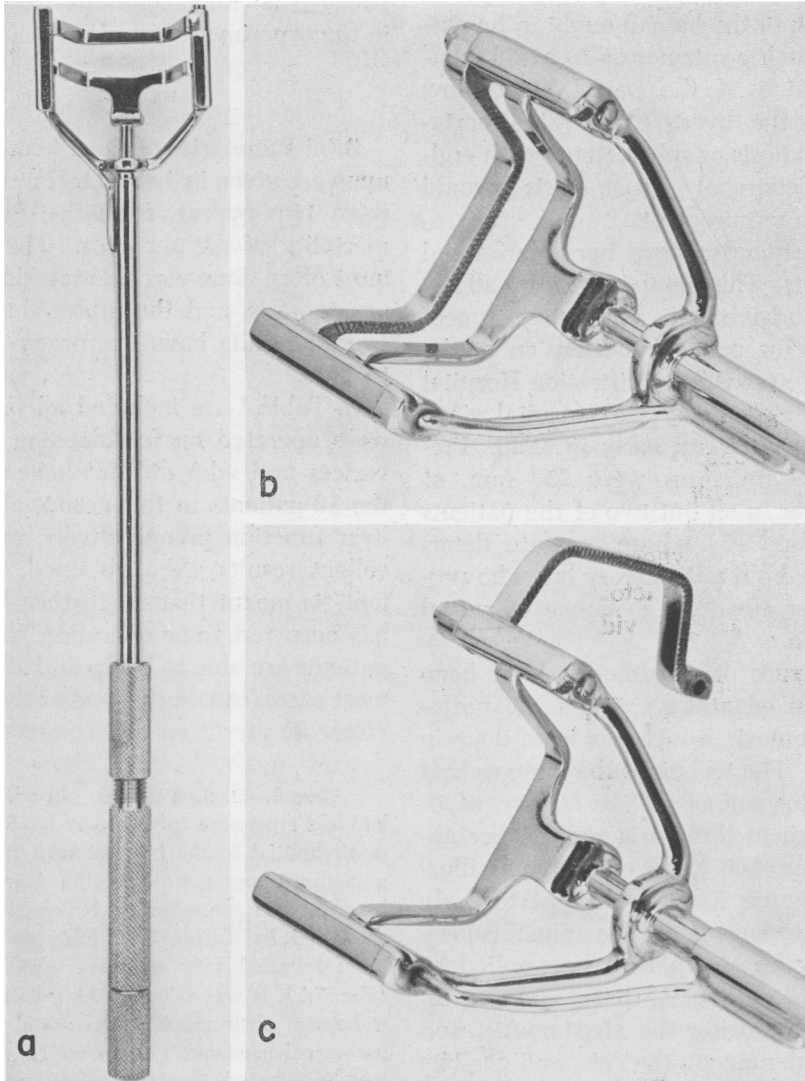


FIG. 1.—Photographs of clamp used to occlude partially the vena cava during the portacaval anastomosis. The clamp, designed by Mr. G. Eidt of the Wayne University College of Medicine, utilizes the principle popularized by Potts<sup>9</sup> for the maintenance of partial blood flow through a vessel during anastomosis. (a) The U-shaped steel blades are approximated by a threaded knob in the handle of the clamp. (b) and (c) The release of a simple locking mechanism allows the blades to fall apart so that the clamp can be removed easily at the conclusion of the procedure.

## THE PORTACAVAL VENOUS SHUNT

**Case 14.**—S. K., a 47-year-old white male, has been followed for 10 months since side-to-side portacaval anastomosis, and has had one definite and another questionable bout of upper gastrointestinal bleeding. At the time the former occurred, his plasma thrombin level was 30 per cent of normal. Thus, although this case must be recorded as an unsuccessful result, there is a reason-

themia rubra vera, has shown progression of his disease without much if any benefit from operation.

Table II shows that three patients were operated upon for rapidly recurring ascites. These patients were treated medically until no further improvement could be expected,

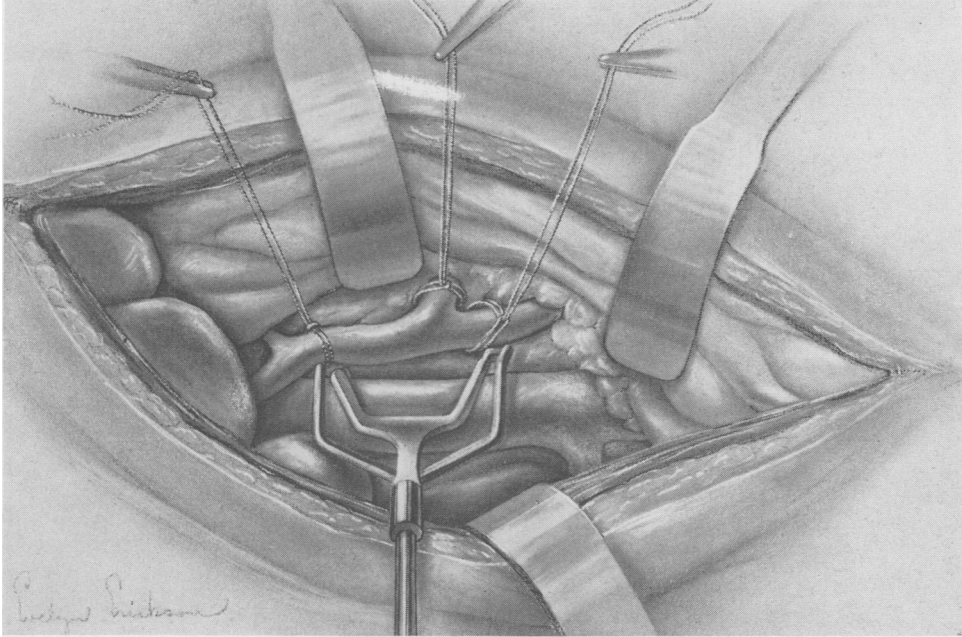


FIG. 2.—Drawing to show the clamp in place, occluding the anterior part of the vena cava, and slip knot ties or loops of heavy braided silk on the portal vein and its tributaries, ready to occlude temporarily the portal vein.

able chance that the hemorrhage was due to progress of liver disease rather than to closure of the anastomosis.

**Case 11.**—R. H., a 42-year-old colored male, suffered from bleeding esophageal varices and portal hypertension due to intrahepatic portal vein thrombosis, proved by liver biopsy. A shunt was done between a very large omental vein and the left renal vein, with improvement. However, the underlying disorder in this man was polycythemia rubra vera, and he continues to bleed sporadically into various parts of the body, most recently into the retroperitoneal tissues.

Thus, of 12 patients operated upon for bleeding alone, nine have had no further hemorrhage, the tenth died six months after operation in hepatic coma, the eleventh is now well but has bled again on at least one occasion, and the twelfth, who has polycy-

but still were disabled by the rapid reaccumulation of fluid after paracentesis. All three patients are alive and have no ascites at present, but all of them developed ascites very rapidly in the immediate postoperative period, and did not begin to show improvement until a month or more after the shunt had been done. Furthermore, one of us (G. G. J.) has performed shunt operations upon two private patients (not included in this series) for massive ascites, without benefit from operation and with progress of liver disease to hepatic coma and death in the postoperative period.

Hence, although benefit resulted from operation in the three cases of ascites included in this report, it is our impression

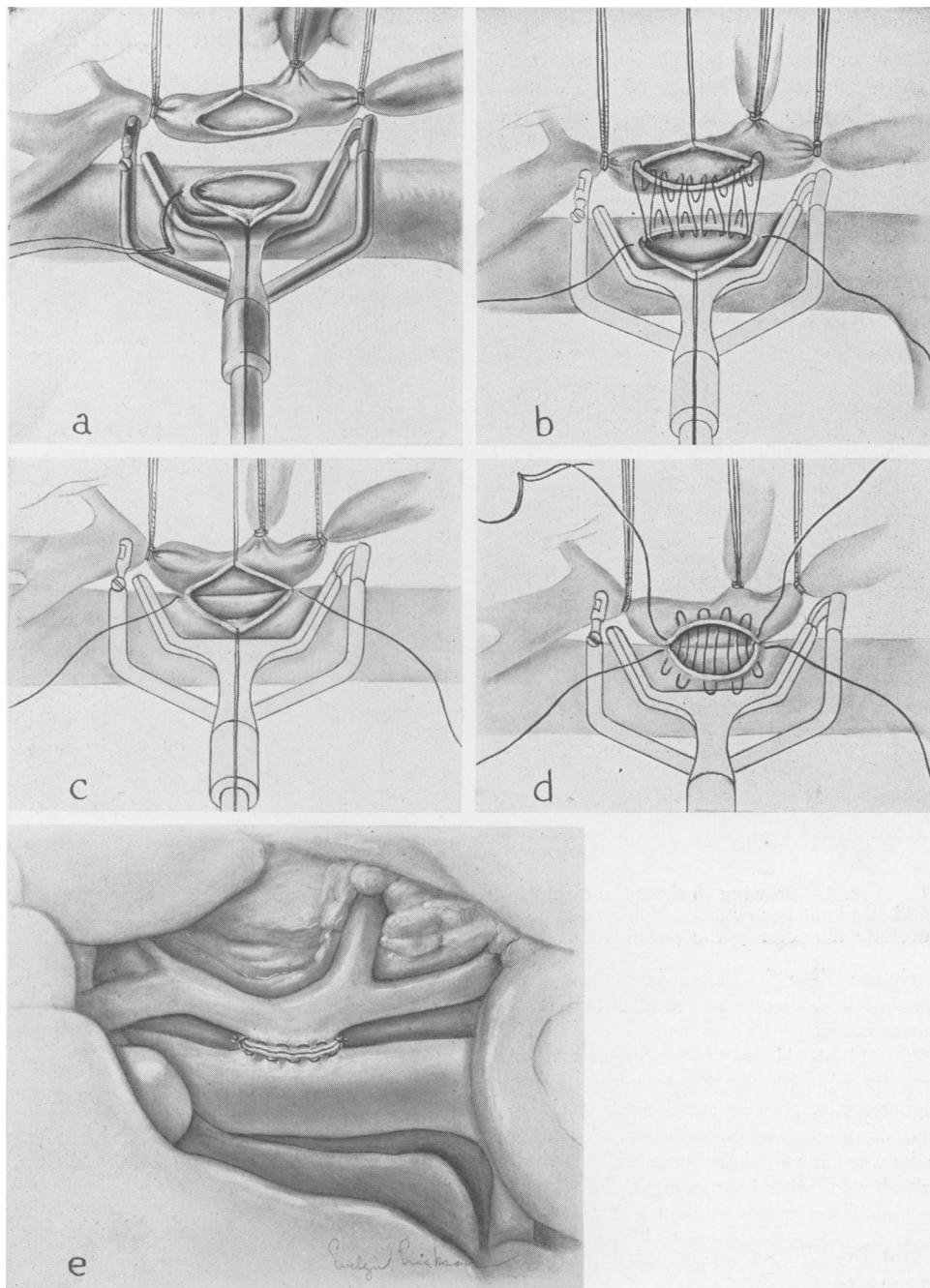


FIG. 3.—Drawing of the operative procedure—side-to-side anastomosis. (a) Elliptical segments of portal and vena cava wall removed, stay sutures in place, anastomosis being started. (b) Posterior continuous suture of waxed 00000 Deknatel surgical silk in place. (c) Posterior suture pulled up, thus everting the intima. (d) Anterior continuous mattress suture in place but not tightened. This suture is drawn up and its ends are approximated and tied to the corresponding ends of the posterior suture, following which the clamp, and then the slip knots on the portal, are removed. (e) The completed anastomosis, the portal vein remaining open.

For the end-to-side anastomosis a similar technic is employed. The portal vein is cut across, the hepatic end ligated, and the other end anastomosed to the side of the vena cava.

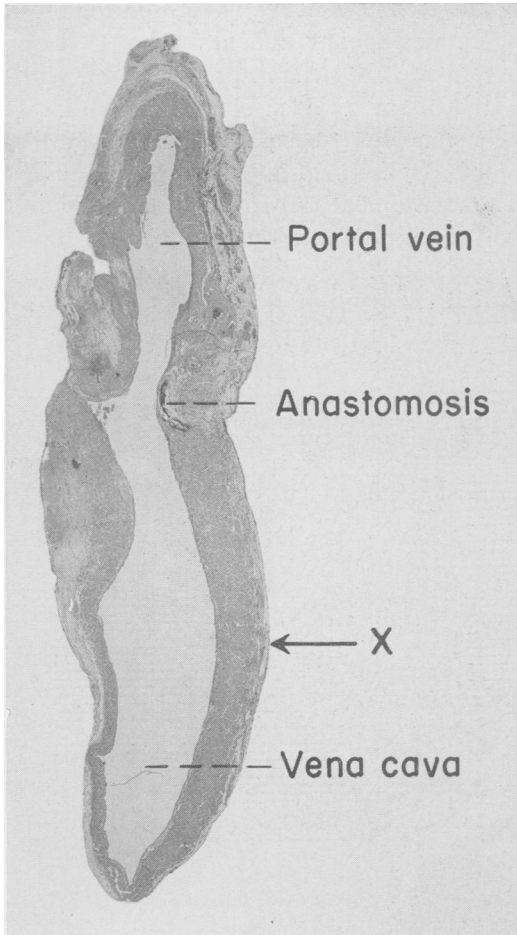


FIG. 4.—Photomicrograph (x12) of cross section of vein walls at level of side-to-side portacaval anastomosis. In this experiment the portal vein was left open as shown in Figure 3e. The animal was sacrificed one month after operation and specimens taken for section. The presence of a widely patent anastomotic channel indicates that a pressure differential between the two veins is not necessary for the maintenance of patency of the anastomosis.

The point x marks the level of previous application of the clamp to the vena cava. No histologic evidence of damage visible.

that the benefit is not as striking as the table may tend to indicate.

In Table III are included the three patients who had both hemorrhage and ascites. The only two operative deaths fell into this group. Both cases (No. 5 and No. 10) had such poor liver function preoperatively that, in retrospect, probably neither should have been operated upon. Both died

in hepatic coma within one month after operation. Autopsy was performed in Case 5, and the anastomosis found to be widely patent. The third patient in this group (Case 8) had no further bleeding and was free of ascites for almost one year after operation but then developed rapidly increasing liver failure with jaundice and ascites and died at another hospital. Autopsy disclosed a patent portacaval anastomosis.

#### DISCUSSION

Bleeding esophageal varices constitute an extremely lethal complication of cirrhosis of the liver. The majority of patients with this complication will probably die within one year of the first bleeding episode<sup>12</sup> if the portal hypertension remains untreated.

Analysis of this small series of cases indicates that excellent results may be obtained in the prevention of further bleeding by the performance of some type of portacaval venous anastomosis. The risk is small provided only that patients with reasonably good liver function are selected for operation. Analysis of our cases suggests that sufficient hepatic reserve to make the patient a satisfactory operative risk likely is present if the serum albumin is over 3.0 Gm. per 100 cc., the bromsulphalein retention under 15 per cent in three-quarters of an hour, and the prothrombin value 60 per cent of normal or better. These figures in general agree with those suggested by Blakemore.<sup>13</sup> It must also be admitted, however, that we have been surprised occasionally to find very extensive liver damage evident histologically, even when the various laboratory tests were well above the "critical" levels.

The results of shunt for hemorrhage have been clear cut and excellent, whereas the results in the treatment of ascites have been only fair. When both hemorrhage and ascites are present, liver damage is likely to be advanced, and the patient's chances of surviving the operation are small. There

is little, if any, evidence to suggest that the course or progress of cirrhosis of the liver has in any way been altered by the shunt operation in the entire group of 18 cases, but the follow-up period (maximum of two and a half years) is too short to allow one to gain more than an impression on this point.

The technic that we have used for these operations is not difficult. The 18 cases herein reported were operated upon without incident by each of a number of surgeons, including several senior surgical residents. Operating time averaged four hours. The anastomosis is performed leisurely and with safety because the vena cava clamp is

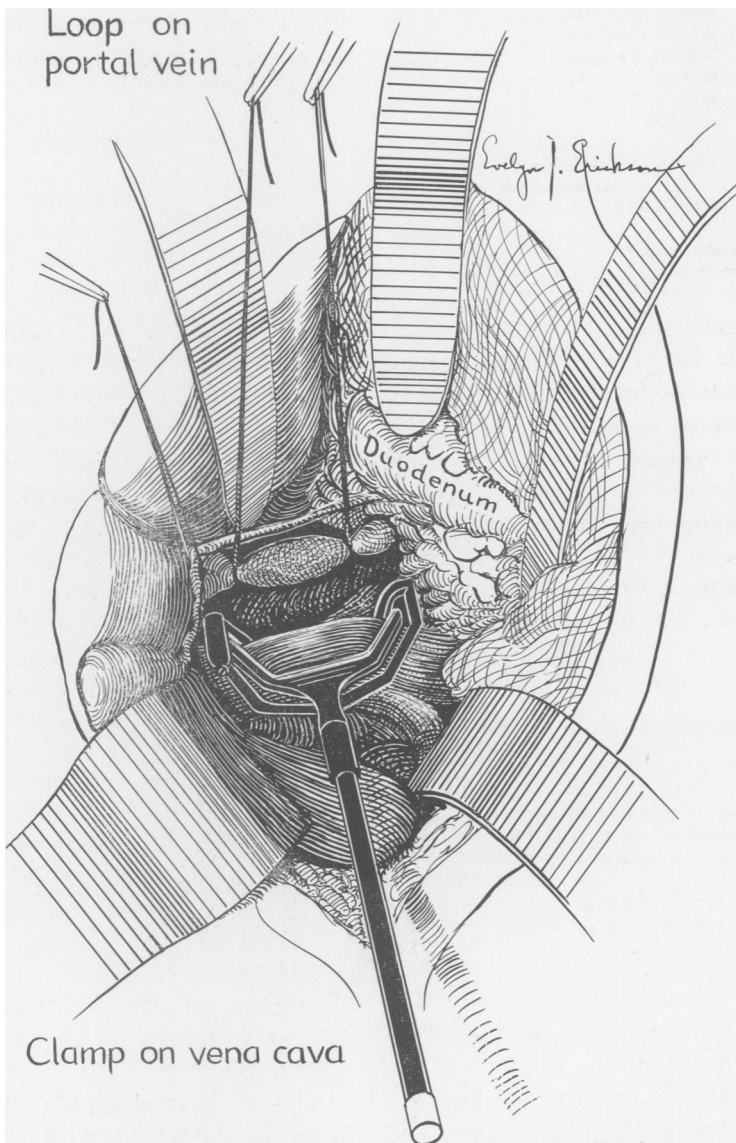


FIG. 5.—Drawing of the exposure for side-to-side portacaval anastomosis in patients. Through a right subcostal incision the duodenum is mobilized and retracted downward, with the intestines. The common bile duct is mobilized and held out of the way by a tape passed around it. The portal vein then is freed up as shown and temporarily occluded with loops of umbilical tape. The drawing also illustrates the clamp in place on the vena cava, ready for the construction of the anastomosis. The renal veins and the posterior aspect of the vena cava with its lumbar tributaries can be completely disregarded when this technic is employed.



THE PORTACAVAL VENOUS SHUNT

TABLE I.—Patients With Hemorrhage.

Case No.	Initial	Age, Color, Sex	Diagnosis	Pre-operative Liver Function	Pre-shunt Portal Pressure mm. Water	Type of Shunt	Follow-up Months	Result
1	P.D.	57 WF	Cirrhosis	Good	300	Splenorenal	30	Excellent
2	D.S.	26 WM	Banti's*	Good	300	Sup. mesenteric to IVC	25	Excellent
9	M.H.	60 WM	Cirrhosis	Good	600	Side-to-side PC	13	Excellent
12	P.S.	33 WM	Banti's*	Good	300	Splenorenal	11	Excellent
13	A.W.	40 WM	Cirrhosis	Good	330	Side-to-side PC	11	Excellent
15	M.M.	43 WF	Cirrhosis	Good	210†	Side-to-side PC	10	Excellent
16	T.M.	58 WM	Cirrhosis	Fair	340	Side-to-side PC	7	Excellent
17	J.M.	61 WM	Cirrhosis	Good	250	Side-to-side PC	6	Excellent
18	G.T.	56 WM	Cirrhosis	Good	400	Side-to-side PC	5	Excellent
4	M.B.	43 WF	Cirrhosis	Good	350	Side to side PC		Hepatic coma and death 6 months post-operatively
11	R.H.	42 CM	Polycythemia portal thrombosis	Good	230†	Omentorenal	11	Improvement questionable
14	S.K.	47 WM	Cirrhosis	Good	280	Side-to side PC	10	Well. Has bled once

\* Extrahepatic portal obstruction.  
† Pressure determinations unsatisfactory.

applied so tightly that it cannot slip off. It is reasonable to believe that the anastomoses in our patients have remained patent, because (a) similar anastomoses in animals have remained open for as long as one and a half years, even in the absence of a pressure differential between the two veins; (b) except for one case, there has been no recurrence of bleeding from esophageal varices in the 12 patients who have had shunts performed because of bleeding; (c) autopsies were performed upon three patients who

prefer the side-to-side portacaval anastomosis in patients with portal hypertension resulting from cirrhosis of the liver, the largest group of patients seen. Those with extrahepatic portal bed block, such as thrombosis or cavernomatous transformation of the portal vein (Cases 2 and 12) had best be treated by splenectomy with splenorenal shunt. More difficult cases, such as those who have had previous splenectomy, are harder to manage, but it is likely that some type of venous shunt may

TABLE II.—Patients With Ascites.

Case No.	Initial	Age, Color, Sex	Diagnosis	Pre-Operation Liver Function	Pre-shunt Portal Pressure mm. Water	Type of Shunt	Follow-up Months	Result
3	N.R.	24 WM	Cirrhosis	Good	390	Umbilical vein to vena cava	23	Good
6	L.Z.	61 WM	Cirrhosis	Fair	350	Side-to-side PC	20	Fairly good
7	G.P.	26 WF	Cirrhosis	Poor	380	Side-to-side PC	18	Good

died in hepatic coma one month, six months, and one year after operation. All three had widely patent anastomoses at postmortem examination; and (d) the one patient with radiologic evidence of extensive varices (Case 2) showed almost complete disappearance of the varices on esophagogram one year after operation (Fig. 7).

The type of anastomosis to be performed must be decided for the individual case. We

be anatomically feasible in the majority of these individuals.

Recently, other methods of treatment of patients with portal hypertension have been reported. These include (a) injection of the varicose vessels in the lower esophagus,<sup>14, 15</sup> stripping the esophageal veins<sup>16</sup> and mediastinal packing,<sup>17</sup> all designed to decrease the blood flow through the submucosal varices; (b) extirpation of the lower esoph-



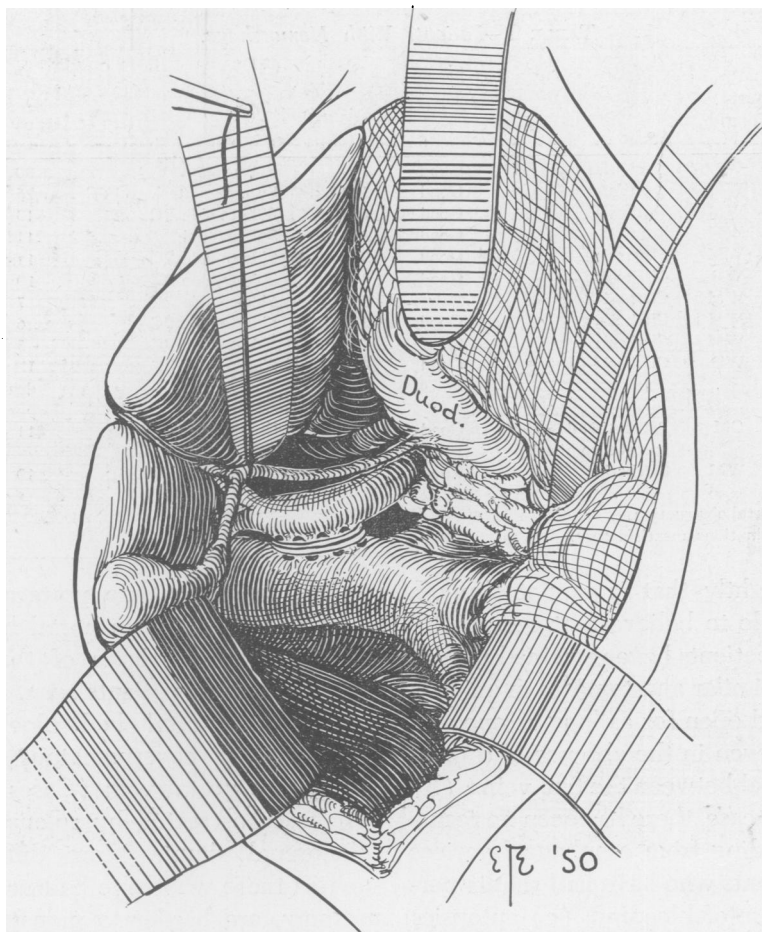


FIG. 6.—The completed anastomosis. The everting type of mattress suture is well shown. The anastomotic opening is made about the same size as the diameter of the portal vein, and thus not quite as large as is shown in the drawing.

agus and upper stomach<sup>18</sup> in an effort to completely remove the involved area; and (c) subtotal or total gastrectomy<sup>19, 20</sup> or vagotomy,<sup>16</sup> to reduce gastric acidity so as to avoid erosion of the lower esophagus.

Immediate results of these various procedures have been moderately good. It must be remembered, however, that such procedures as splenectomy<sup>21</sup> and omentopexy<sup>22, 23</sup> in the past have given good short term results, but have not been very successful over a long period of time. One wonders whether these more recently suggested procedures will also prove unsatisfactory as time goes on, since the underlying portal hypertension remains un-

changed. Ligation of the splenic artery<sup>24-26</sup> or other vessels may be worth trying in patients whose condition is too poor to consider a more major procedure, but permanent arrest of hemorrhage is unlikely. Because the creation of large venous shunts between the portal and systemic circulation will reduce the pressure in the portal system permanently if the shunt remains open, it seems to us that this method of treatment is to be preferred over any other less physiologic type of approach.

Although a much longer period of follow-up will be necessary, we believe that the results obtained so far are encouraging. It is our opinion that these results, when

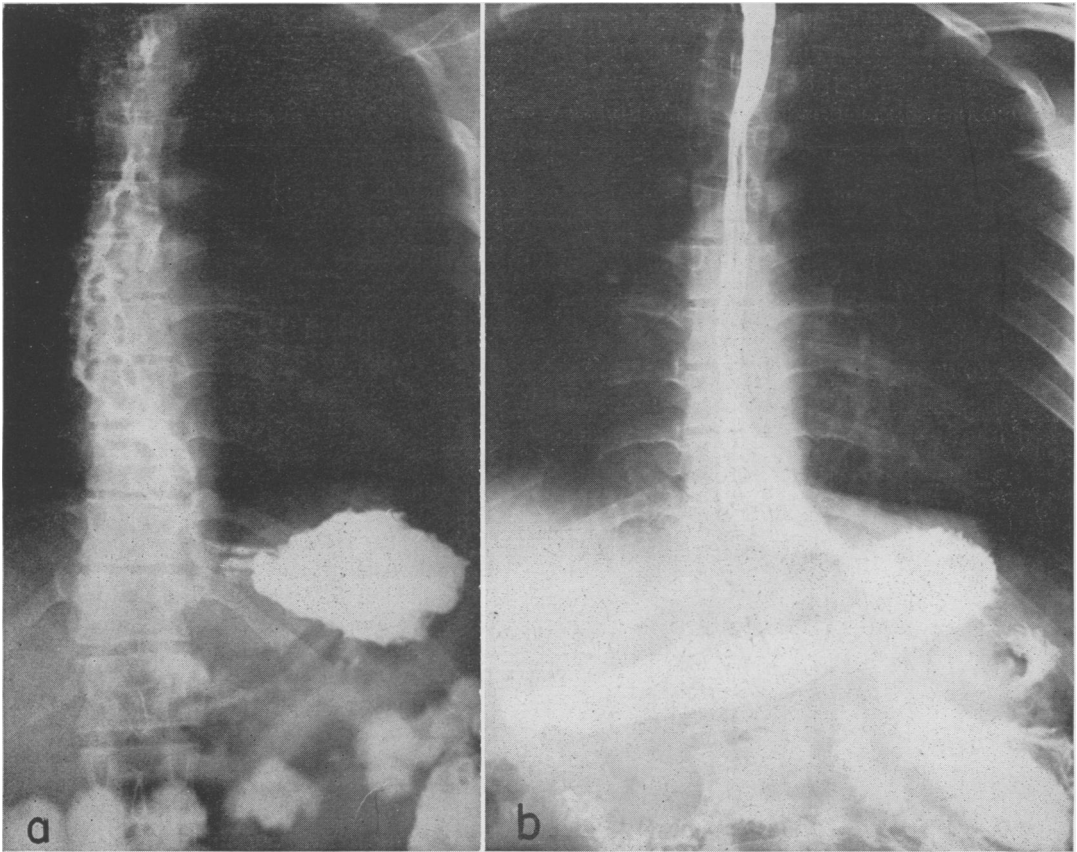


FIG. 7.—Roentgenograms of the esophagus of D.S. (Case 2) following barium swallow. (a) Before the shunt operation. The varices, which are numerous and very large, can be seen to extend up to the patient's neck. (b) One year after venous shunt, the esophagus is smooth and straight. Except for a small questionable area near the diaphragm, all radiologic evidence of varicosities has disappeared. No bleeding has taken place for two years.

considered with the more extensive experience of Blakemore<sup>27-29</sup> and others, justify, from the practical point of view, the recommendation of portacaval or splenorenal anastomosis as the operation of choice for the elective treatment of patients with bleeding esophageal varices associated with portal hypertension.

#### CONCLUSION

The construction of large shunts between the portal and caval systems of veins is a satisfactory method of treatment for patients with portal venous hypertension.

Experimental evidence suggests that these shunts are best performed in such a

manner as to avoid complete diversion of the portal flow away from the liver. Side-to-side portacaval anastomosis is a reasonable method of accomplishing this objective and has given good results in the 13 patients in whom it has been performed. Splenectomy with splenorenal shunt will also satisfy these requirements.

The results of venous shunts performed in 18 patients with portal hypertension have been excellent in the 12 patients with good liver function who were operated upon for bleeding esophageal varices, fair in three patients who suffered recurring and disabling ascites, and poor in three patients with both hemorrhage and ascites.

TABLE III.—Patients With Hemorrhage and Ascites.

Case No.	Initial	Age Color, Sex	Diagnosis	Pre-	Pre-shunt	Type of Shunt	Follow-up Months	Result
				Operation Liver Function	Portal Pressure mm. Water			
5	S.M.	60 WM	Cirrhosis	Poor	350	Side-to-side PC	Died 1 mo. postoperatively	
8	A.F.	66 WM	Cirrhosis	Good	300	Side-to-side PC	Died 13 mo. postoperatively	
10	O.H.	29 WF	Cirrhosis	Poor	420	Side-to-side PC	Died 12 days postoperatively	

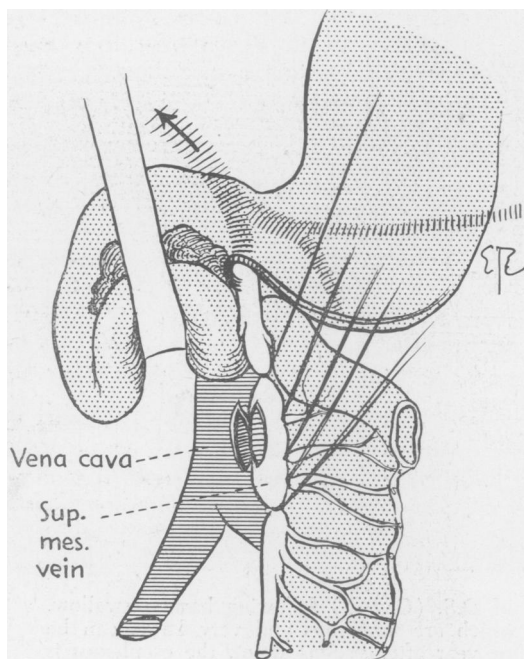


FIG. 8.—Drawing of the anastomosis performed in D.S. (Case 2). The tributaries of the superior mesenteric vein are temporarily occluded with loops of umbilical tape, the clamp (not shown) applied to the front of the vena cava, and side-to-side anastomosis constructed below the level of the duodenum, using everting sutures of fine silk.

It is hoped that our experience will stimulate others to employ more frequently the operation of side-to-side portacaval anastomosis, as we believe it both theoretically and practically to be the ideal operation for the treatment of portal hypertension in patients who have cirrhosis of the liver. Although the progress of the cirrhosis probably remains unaffected by the operation, many of these patients can look forward to arrest or retardation of the cirrhotic process if they carefully follow an adequate

medical regimen, and the shunt operation can be expected to eliminate the ever-present possibility of death from hemorrhage.

## BIBLIOGRAPHY

- Whipple, A. O.: The Problem of Portal Hypertension in Relation to the Hepatosplenopathies (E. Starr Judd lecture). *Ann. Surg.*, **122**: 449, 1945.
- Blakemore, A. H., and J. W. Lord, Jr.: The Technic of Using Vitallium Tubes in Establishing Portacaval Shunts for Portal Hypertension. *Ann. Surg.*, **122**: 476, 1945.
- Blakemore, A. H.: Indications for Portacaval Anastomosis—Analysis of Cases. *Surg., Gynec. & Obst.*, **84**: 645, 1947.
- Blakemore, A. H.: The Portacaval Shunt in the Surgical Treatment of Portal Hypertension. *Ann. Surg.*, **128**: 825, 1948.
- Blalock, A.: Use of Shunt or By Pass Operations in Treatment of Certain Circulatory Disorders Including Portal Hypertension and Pulmonic Stenosis. *Ann. Surg.*, **125**: 129, 1947.
- Linton, R. R., I. B. Hardy and W. Volwiler: Portacaval Shunts in the Treatment of Portal Hypertension. *Surg., Gynec. & Obst.*, **87**: 129, 1948.
- Welch, C. S.: A Technique for Portacaval Anastomosis (Eck fistula). *Surg., Gynec. & Obst.*, **85**: 492, 1947.
- Joani, quoted in Keen's "Surgery, Vol. V, pg. 127-128. W. B. Saunders Co., 1909.
- Stewart, G. N.: A Clamp for Isolating a Portion of the Lumen of a Blood Vessel without Stopping the Circulation Through the Vessel. *J. A. M. A.*, **55**: 647, 1910.
- Potts, W. J., S. Smith and S. Gibson: Anastomosis of the Aorta to a Pulmonary Artery. *J. A. M. A.*, **132**: 627, 1946.
- Preshaw, D. E., A. Large and A. F. Johnson: The Effect of Portacaval Venous Shunt Upon Bromsulphalein Retention. *Arch. Surg.*, To be published.
- Patton, T. B., and C. G. Johnston: A Method of Control of Bleeding from Esophageal Varices. *Arch. Surg.*, **59**: 502, 1949.

- 12 Ratnoff, O. D., and A. J. Patek, Jr.: The Natural History of Laennec's Cirrhosis of the Liver. *Medicine*, **21**: 207, 1942.
- 13 Blakemore, A. H.: Preoperative Evaluation of Liver Function in Patients with Cirrhosis of the Liver. *Surg., Gynec. & Obst.*, **89**: 357, 1949.
- 14 Crafoord, C., and P. Frenckner: New Surgical Treatment of Varicose Veins of the Esophagus. *Acta Otolaryng.*, **27**: 422, 1939.
- 15 Moersch, H. J.: Treatment of Esophageal Varices by Injection of a Sclerosing Solution. *J. A. M. A.*, **135**: 754, 1947.
- 14 Gray, H. K., and F. B. Whitesell, Jr.: Hemorrhage from Esophageal Varices; Surgical Management. *Ann. Surg.*, **132**: 798, 1950.
- 17 Som, M. L., and J. H. Garlock: New Approach to the Treatment of Esophageal Varices. *J. A. M. A.*, **135**: 628, 1947.
- 18 Phemister, D. B., and E. M. Humphreys: Gastroesophageal Resection and Total Gastrectomy in the Treatment of Bleeding Varicose Veins in Bantist's Syndrome. *Ann. Surg.*, **126**: 397, 1947.
- 19 Wangenstein, O. H.: Discussion of Reference No. 18. *Ann. Surg.*, **126**: 408, 1947.
- 20 Baronofsky, I. D.: Portal Hypertension with Special Reference to the Acid-Peptic Factor in the Causation of Hemorrhage and Extensive Gastric Resection in Its Treatment. *Surgery*, **25**: 135, 1949.
- 21 Rousselot, L.: Role of Congestion (Portal hypertension) in So-called Banti's Syndrome: Clinical and Pathologic Study of 31 Cases with Late Results Following Splenectomy. *J. A. M. A.*, **107**: 1788, 1936.
- 22 Talma, S.: Chirurgische Geffnung Neuer Seitenbahnen fur das Blut der Vena Porta. Berlin, *Klin. Wehnschr.*, **35**: 833, 1898.
- 23 Morison, R.: A Case of Ascites Due to Liver Cirrhosis Treated by Operation. *Ann. Surg.*, **38**: 361, 1903.
- 24 Blain, A. W.: Ligation of Splenic Artery. *Surg., Gynec. & Obst.*, **26**: 660, 1918.
- 25 Everson, T. C., and W. H. Cole: Ligation of the Splenic Artery in Patients with Portal Hypertension. *Arch. Surg.*, **56**: 153, 1948.
- 26 Blain, A. W., and A. Blain, III: Ligation of Splenic Artery, Operation of Choice in Selected Cases of Portal Hypertension and Banti's Syndrome. *Ann. Surg.*, **131**: 92, 1950.
- 27 Blakemore, A. H.: The Portacaval Shunt for the Relief of Portal Hypertension. *Mississippi Doctor*, **27**: 1, 1949.
- 28 Blakemore, A. H.: Portacaval Anastomosis for Portal Hypertension. *Surgery*, **26**: 99, 1949.
- 29 Blakemore, A. H.: The Portacaval Shunt in the Treatment of Portal Hypertension. *South. Surgeon*, **16**: 386, 1950.