

## THE CONTROLLED LABORATORY PRODUCTION OF HEMOGLOBINURIC NEPHROSIS\*

CHESTER B. ROSOFF, M.D., AND CARL W. WALTER, M.D.

BOSTON, MASSACHUSETTS

FROM THE LABORATORY FOR SURGICAL RESEARCH, HARVARD MEDICAL SCHOOL AND DEPARTMENT OF SURGERY,  
PETER BENT BRIGHAM HOSPITAL

MANY PATIENTS sustaining wounds of the soft parts and skeleton, as well as those suffering from incompatible transfusion reactions, severe burns, and other clinical states marked by hemoglobinemia, succumb days to weeks after injury because of the development of renal insufficiency.<sup>4, 10, 15</sup> In most instances this kidney failure is the result of tubular damage, which appears to be reparable locally if the patient survives, and is termed "hemoglobinuric nephrosis" or "lower nephron nephrosis." This paper reports the results of a laboratory study of the etiology of the lesion and its production in dogs.

One of the earliest experimental papers on this subject described the intraluminal precipitation of hemoglobin with blockage of the renal tubules in rabbits infused with hemoglobin solutions.<sup>1</sup> The lesion depended on the urine being acid and having a chloride concentration of more than 1 per cent. As a result of this work, the alkalinization of patients with hemoglobinemic states has been widely carried out in an attempt to prevent urinary block. This original work has been repeated in dogs by one group, only to be refuted by similar experiments of others.<sup>2, 6, 8</sup> The latter workers feel that antecedent tubular damage is more important than the urinary pH in the development of the lesion and that large amounts of homologous hemoglobin can be infused into normal animals with no apparently ad-

verse effects until the dosage exceeds 4-6 Gm./Kg. body weight with a serum hemoglobin concentration greater than 3700 mg. per 100 cc. immediately after the infusion. This would support the importance of prior damage.

The relation of renal anoxia to this concept of antecedent injury can be supported by observations in both the clinical and experimental fields. Review of autopsy material and case histories at the Army Institute of Pathology gave credence to this etiologic combination of renal anoxia and a hemoglobin compound.<sup>14</sup> As early as 1931, it was shown by plethysmography that solutions of crystalline hemoglobin caused a sharp, though transient, fall in the volume of the kidney itself, a fall which was not dependent on change in blood pressure.<sup>16</sup> This effect, shown to be mediated by a vasoconstriction of the afferent arterioles, could not be reproduced by injections of red cell stroma. More recent functional studies have shown that there is a marked and severe fall in renal blood flow following the hypotension of a shock from various causes or from clamp ischemia of the kidney itself.<sup>13, 21</sup> The decrease in filtration rate and effective plasma flow is greater than the reduction of arterial blood pressure observed, and although they increase with rising blood pressure, they do so with quite a lag. This lag in response to therapy of the shock state is further prolonged in animals with denervated kidneys and sug-

\* Submitted for publication July, 1951.

gests that the use of spinal anesthesia is not wise either in treating the primary injury or the renal anoxia.<sup>5</sup> The conclusion is, therefore, that some active renal vasoconstriction persists and that it would seem to be a sensitization to circulating vasoconstrictor agents. The role of intrarenal vascular shunts in this problem is far from settled and is mentioned only to emphasize the complexity of the problem.<sup>22</sup>

The precise interrelationship of vasoconstriction or other causes of anoxia and the presence of free pigment in the plasma remains to be elucidated. It was our purpose to observe their effects both singly and in combination in the experimental subject and to study their role in the production of renal failure.

#### METHODS

The role of anoxia and hemoglobin in the production of nephrosis was studied by employing two experiments. The animals used were healthy laboratory dogs weighing 10 to 15 Kg. in whom the kidneys had been previously explanted bilaterally to a subcutaneous position by a modified technic.<sup>19</sup> They were permitted to partake of the routine kennel food and water as desired.

**Experiment 1.** Following medication with 0.015 Gm. morphine sulfate, a 45-minute period of hypotension with a mean systolic level of 40 to 50 mm. of mercury was produced by bleeding into a sterile reservoir. During the last 30 minutes of this period, a solution of homologous methemoglobin\* in a dosage range of 1 Gm./Kg. body weight was given intravenously at a rate of 8 to 10 cc. per minute.

\* Solutions of oxyhemoglobin and methemoglobin were prepared under aseptic conditions from freshly drawn, heparinized canine blood. The blood was centrifuged, and after the plasma was aspirated the cells were washed with normal saline and then laked by the addition of sufficient distilled water to re-establish the original volume. A total hemoglobin was determined and the solution refrigerated at 5-10°C. until use later the same day. When the met form was to be used, sterile sodium nitrite solution was added in the necessary amounts (4 moles NaNO<sub>2</sub> per mole hemoglobin) and the concentration of the respective forms determined.<sup>7, 9</sup>

The blood collected in the reservoir was then infused intra-arterially into the dog. Urinalysis, non-protein nitrogen levels, serum hemochromogens and biopsies (under local anesthesia) were done daily.<sup>9</sup> All renal tissues were immediately fixed in 10 per cent Formalin-Zenker's solution, prepared with the standard paraffin block technic and then stained with hematoxylin and eosin.

**RESULTS:** Five animals were subjected to the infusion of methemoglobin during prolonged shock. One acute experiment was performed. Number 181-49 was sacrificed as soon as the methemoglobin was infused. The tissues were prepared for histologic examination and as might be predicted, no lesions were visible. Three animals (Nos. 54-49, 207-49 and 222-49) developed signs of tubular damage demonstrated histologically by swelling of the proximal convoluted tubules, loss of nuclei, obliteration of the lumens of tubules, etc. The first two animals also showed elevations of blood non-protein nitrogen to approximately 70 mg. per 100 cc. The fifth animal (No. 117-49) became completely anuric postoperatively, showed a rise in non-protein nitrogen to 160 mg. per 100 cc. on the third postoperative day and died on the fourth postoperative day. The histologic picture was one of complete necrosis of the proximal and distal convoluted tubules. A more extensive histologic description will be included as part of the next experiment described below. One animal (No. 131-49) received methemoglobin with inadequate and brief hypotension and when sacrificed five days later, showed no lesions, either in the gross or microscopic examination. This evidence suggested that a renal tubular lesion could be produced in the dog by the combination of prolonged deep shock and the infusion of methemoglobin solution.

**Experiment 2.** It was felt that the role of shock should be further investigated and it was postulated that it worked its ill effects on the kidney by causing renal anoxia. In order to produce this renal anoxia without the additive effects of a systemic oxygen lack, occlusion of the renal artery for a definite period was proposed. Para-amino-hippurate and creatinine clearance studies in dogs demonstrated the relative innocuousness of renal artery occlusion for short periods and the increasingly severe functional damage produced by anoxia prolonged beyond 90 to 120 minutes.<sup>20</sup> A 45-minute occlusion was felt to be comparable to the shock period used in the previous experiment and safely within the danger period as outlined above. By making use of a noose placed around one renal artery, the contralateral kidney could be utilized as a control for all factors except the renal anoxia itself. This was controlled separately as described below.

FIG. 2

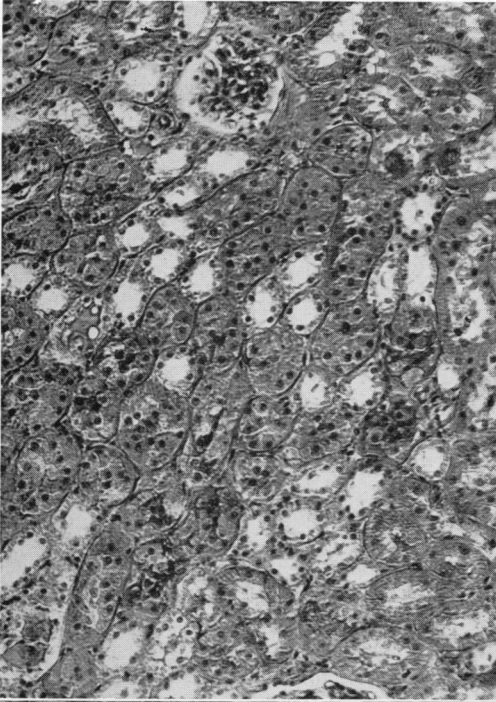


FIG. 1

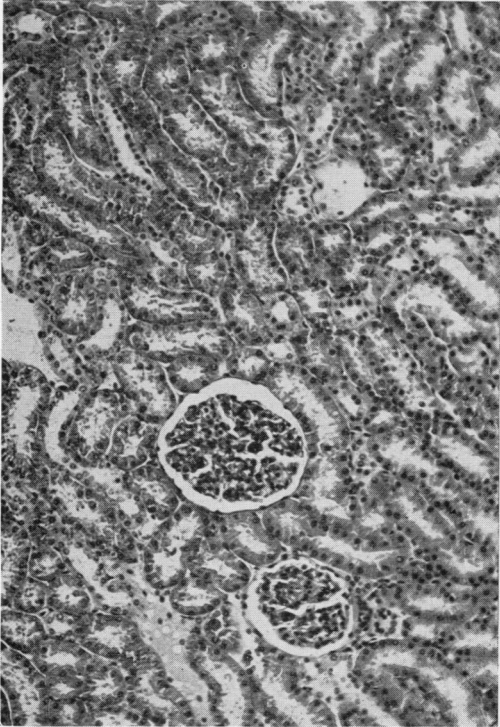


FIG. 4

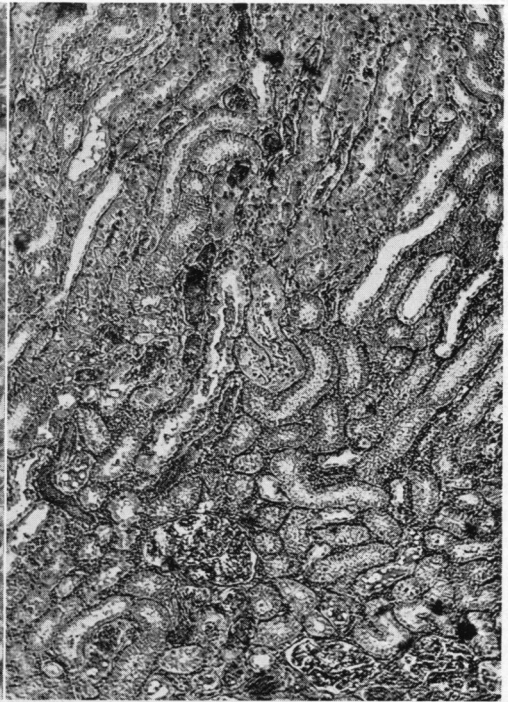
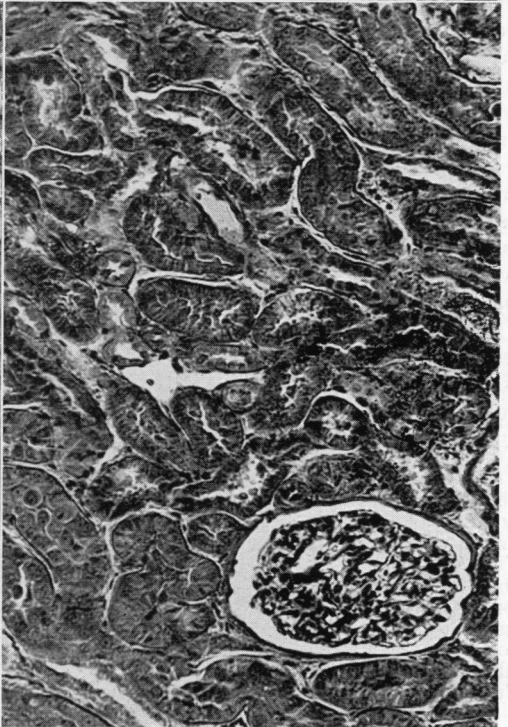


FIG. 3



See opposite page for legends.

At the time of the bilateral renal explanation, a non-reactive polyvinylite tube and flattened snare were placed in such fashion around the renal artery of one kidney that its distal tip lay in a subcutaneous position for easy access, yet leaving the hilar nerves, renal vein and ureter undisturbed. All capsular branches fed by vessels other than the renal artery were ligated and divided at the time of explantation so that this noose gave complete control of the renal blood flow to one side. Approximately ten to 14 days after this first procedure, the animals were premedicated with 0.015 Gm. of morphine sulfate and the end of the snare exposed through a 1 cm. long skin incision under local 2 per cent procaine anesthesia. The renal artery was then occluded by tightening the noose a predetermined distance and the kidney rendered anoxic for a 45-minute period. By palpation, the kidney could be shown to shrink markedly in size when the snare was tightened and thus demonstrated that the artery was actually occluded. During the last 30 minutes of this period, a solution of either oxyhemoglobin or methemoglobin in a dosage range of 1 to 2 Gm./Kg. of body weight was infused into a leg vein at the rate of 8 to 10 cc./minute. The noose and snare were then removed from the wound and the small incision closed with a single subcuticular suture. The animals withstood this manipulation well and were relatively undisturbed by it. Biopsy of both the affected and the contralateral control kidney was done daily or as often as the investigation required. The biopsies were performed in premedicated animals (0.015 Gm. morphine sulfate) under local 2 per cent procaine anesthesia. A 2 to 3 cm. long skin incision was made, the renal cortex exposed and a wedge of tissue removed. The bleeding was controlled by implantation of absorbable sponge (Oxycel) and the wound closed. These biopsy specimens and the postmortem tissues were fixed in Formalin-Zenker's solution, sectioned after imbedding in paraffin and stained with hematoxylin and eosin. A control series of three animals (Nos. 260-49, 67-50, 81-50) to study the effect of the renal artery occlusion

FIG. 1.—Normal dog kidney. ( $\times 130$ ).

FIG. 2.—Early renal changes showing swelling and migration of tubular cells with obliteration of many lumens 24 hours after period of renal anoxia combined with methemoglobinemia ( $\times 130$ ).

FIG. 3.—Forty-eight hours after renal injury by anoxia and methemoglobinemia, extensive damage to convoluted tubules can be seen with shedding of lining cells, occasional mitoses, stromal edema, and occlusion of lumens. There is no evident glomerular pathology ( $\times 230$ ).

FIG. 4.—Increase in number of mitotic divisions with continued damage to tubular cells is evident three days after exposure to combined renal anoxia and hemoglobin pigment. Note hemoglobin casts and relatively normal loops of Henle ( $\times 85$ ).

without hemoglobin was set up and biopsies of the anoxic and contralateral kidneys taken. In this fashion, it was felt that data on all the variables were accumulated.

RESULTS: A. *Controls*. When the kidneys were subjected to anoxia with no hemoglobin free in the plasma, a very mild swelling of proximal and distal convoluted tubular loops developed. This appeared on the first postoperative day. In addition, one occasionally could see a clear amorphous, eosinophilic-staining material in Bowman's capsule, the convoluted tubules, and descending loops of Henle. In no instance was any cellular debris or cell necrosis seen. There was no evidence of interstitial reaction. The glomerular tufts appeared normal.

The contralateral control kidney showing the effects of the hemoglobin compound without anoxia presented a picture in which the glomeruli appeared normal, but both proximal and distal convoluted tubules showed mild, spotty swelling of lining cells and frequent accumulations of hemoglobin in their lumens. There was no budding or shedding of tubular cells, evidence of mitoses or stromal edema. The swelling of the tubular cells was maximum on postoperative days one to two and subsided and disappeared by postoperative days four to five.

B. *Experimental*. The combination of anoxia with either oxyhemoglobin or methemoglobin resulted in histologic changes far in excess of the sum of the component factors. Ten animals were studied in this group, six of which received methemoglobin and four oxyhemoglobin. These changes may be characterized as follows: The glomeruli were normal. The proximal convoluted tubules gave evidence of having been the most severely damaged, although these changes were shared by the proximal limb of Henle's loop and to a lesser extent by the distal convoluted tubules. The time schedule varied with the severity of the renal reaction. In general, during the first 24 to 36 hours there was evidence of marked swelling of the convoluted tubular cells with pigment particles lying intracellularly. The lumens were for the most part obliterated by swelling of the lining cells which in many cases showed vacuolization as well. During the next 36-hour period the swelling approached a maximum, which was sustained for four to five days. Cell disruption appeared during this period with signs of nuclear changes ranging from varying states of mitotic division to degeneration. The cell membranes became indistinct and the nuclei tended to migrate, forming pseudo "giant cells" lying within the confines of the basement membrane. Occasional diffuse collections of mononuclear cells could be seen in the peritubular area.

The hemoglobin casts remained as before and seemed to be tolerated without reaction. It is at this time, three to six days after injury, that clumps of tubular cells appeared to "bud" into the lumen, that others passed down the nephron and formed part of a cast composed of hemoglobin, acellular debris and these swollen, isolated, shed cells. In one of the animals (No. 254-49) complete necrosis of many tubules was apparent on the third postoperative day with recovery taking place during the succeeding days. Another (No. 13-50) showed the same necrosis of the convoluted tubules but in spotty locations; the other tubules revealing less severe damage.

In general, the reaction to methemoglobin was more severe than to oxyhemoglobin but the type of reaction was the same. The increased incidence and early appearance of mitoses in the tubular cells injured by anoxia and oxyhemoglobin suggests a more active reparative phase. Complete repair was the rule in this injury, whether the result of the methemoglobin or the oxyhemoglobin form. This again varied in the time required but seemed to be histologically completed in about two weeks for the milder forms of injury and in approximately three weeks for the most serious cases.

Serum hemochromagen levels taken at the close of the infusion varied from 800 mg. per 100 cc. to 2000 mg. per 100 cc. but could not be correlated with the severity of the lesion produced. This hemochromagen level fell rapidly to normal levels within two to four days, since the animals had normally functioning contralateral kidneys with which to excrete the compounds.

#### DISCUSSION

The significance of this study lies in its experimental support of an old clinicopathologic observation; namely, that the combined effect of anoxia and free hemoglobin results in the production of a nephrosis. That this nephrosis is reversible has been demonstrated many times clinically, providing that the patient can be kept alive during the period of renal insufficiency long enough for regenerative repair to take place. It is this reversibility that holds out so much hope for the therapeutic aspects of the disease, whether by conservative, careful fluid management and restriction or by use of the "artificial kidney"—extracorporeal hemodialysis.<sup>17, 18</sup> The latter would seem to be a most valuable tool in the early stages

of the disease as a means of maintaining adequate hydration, possible clearance of potentially toxic factors and later in re-establishing the normal electrolyte and metabolic status by correcting the effects of the period of renal insufficiency. The roles played by electrolyte abnormalities and dehydration, with their resulting effects on acid-base balance in hemoglobinuric nephrosis, have not been fully elucidated. Much has been written on this subject, and while the results do not seem to indicate a primary etiologic role for these factors, there is suggestive evidence which assigns them some part in determining severity or duration of the disease state.<sup>12, 23</sup>

It would seem likely that the damage that results from a state of shock associated with hemoglobinemia occurs early during the injury period, perhaps in a matter of a few hours, and that the histologic changes that may be seen during the succeeding days is merely a reflection of spatial and physical changes in injured or dying cells. This concept suggests that preventive measures would be unsuccessful, however specific, unless they were carried out extremely early during the initial insult or soon thereafter. Additional damage to the renal tubules, of course, might occur as a result of unwarranted dehydration, prolonged hypotension, etc., but in all probability this is a less important phase in the production of the lesion.

It should be apparent that extremely prolonged anoxia, whether in the form of shock or otherwise, results in cellular damage or death which need not be localized to the kidney. The fact that a hemoglobin compound hastens and augments renal injury after comparatively short periods of anoxia leads one to speculate as to the nature of its interference. A recent paper suggests that the iron in the heme molecule eventually takes the toxic form of ferric hydroxide and thus produces cell death.<sup>11</sup> The evidence for this and all other hypotheses delineat-

ing the mode of damage is still uncertain. It is known that the cytochromes are closely related chemically to heme.<sup>3</sup> It is possible that heme competes with the cytochromes in the oxidative processes of the tubular cells and by so doing destroys or damages

the cell. This would explain why those renal cells that process hemoglobin compounds in their passage through the kidney, the convoluted tubules, suffer the most in this nephrosis, for it is these cells that do the most work and are the most active meta-

FIG. 5

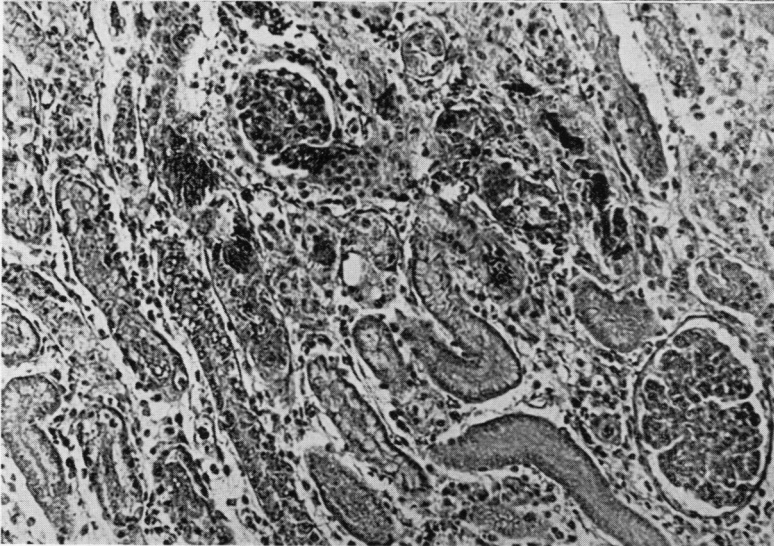
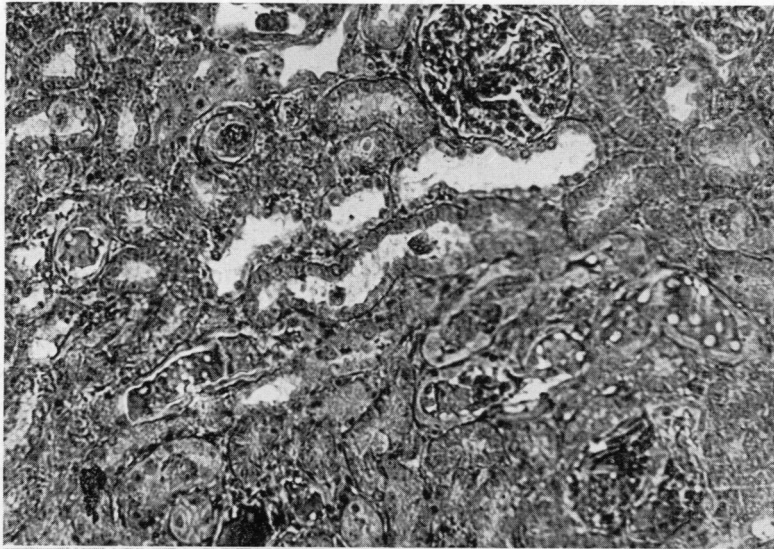


FIG. 6

FIG. 5.—Four days following renal insult by anoxia and met hemoglobinemia, major areas of injured tissue can be seen with tubular cell necrosis, swelling, mitoses, and casts, but with little or no glomerular damage (175x).

FIG. 6.—By five or six days after exposure to methemoglobinemia and renal anoxia, extensive necrosis of tubular cells with marked stromal edema is seen. There is decreased vascularity of glomerular tufts and some interstitial edema (x130).

bologically. It might also explain the greater toxicity of the met forms of hemoglobin. It may well be that if the patient is seen during the period of the renal "insult," one might prevent or minimize the renal damage by increasing the availability of one or another of the enzymes damaged. For the present, extra-renal dialysis seems the most valuable means of keeping patients alive until their own renal function improves to the point where it can take over and re-establish the normal regulatory mechanisms. Prevention or prompt treatment of shock and avoidance of those anesthetic agents known to reduce renal blood supply would help to minimize the damage. The early determination of serum hemochromagens in suspected cases helps to predict which patients might logically be expected to develop renal insufficiency of this nature and prevent unfortunate excesses of water and electrolytes.

#### SUMMARY AND CONCLUSIONS

Clinical and pathologic reports have emphasized the presence and apparently combined effect of hemoglobinemia and shock in hemoglobinuric nephrosis. Numerous experimental workers have shown that prolonged renal anoxia may result from the shock state. A reproducible, recoverable hemoglobinuric nephrosis has been produced in dogs by combining anoxia, whether by shock or as a result of unilateral renal artery occlusion with intravenous infusions of oxyhemoglobin or methemoglobin. This nephrosis is characterized by convoluted tubule damage, predominantly proximal in location, marked by swelling and exfoliation of cells, production of cellular and hemoglobin casts, the appearance of mitotic figures during the reparative phase and finally recovery. This lesion, while not identical with that seen in human beings, is quite comparable and is strongly suggestive that a similar chain of events occurs in men. Further, it offers for future investigative

work an animal preparation heretofore not available. It has been emphasized that until the exact mechanism of the damage is accurately known, clinical efforts must consist of minimizing the occurrence of duration of hypotension and other causes of renal anoxia, instituting careful electrolyte and fluid therapy if hemoglobinemia develops and the employment of extracorporeal hemodialysis as it becomes necessary.

1. Blood loss hypotension combined with an intravenous infusion of either oxyhemoglobin or methemoglobin resulted in a recoverable tubular lesion in dogs with explanted subcutaneous kidneys, as shown by serial renal biopsies.

2. Unilateral renal anoxia in association with hemoglobinemia caused the development of a severe proximal and distal convoluted tubule injury which, in some cases, progressed to complete necrosis.

3. Anoxia for comparable periods in the absence of a hemoglobin compound resulted in minimal, if any, renal lesions.

4. A tubular lesion reasonably similar to that seen in man has been produced in dogs, thus making available an experimental preparation for further investigation.

5. The significant etiologic agency appears to be the combination of a hemoglobin compound and prolonged renal anoxia.

The help and encouragement of Dr. Francis D. Moore is gratefully acknowledged.

#### BIBLIOGRAPHY

- <sup>1</sup> Baker, S. L., and E. C. Dodds: Obstruction of the Renal Tubules During the Excretion of Hemoglobin. *Brit. J. Exper. Path.*, **6**: 247, 1925.
- <sup>2</sup> Bing, R. J.: Effect of Hemoglobin and Related Pigments on Renal Functions of Normal and Acidotic Dog. *Bull. Johns H6pkins Hosp.*, **74**: 161, 1944.
- <sup>3</sup> Bodansky, M.: *Introduction to Physical Chemistry*. New York, 1938, John Wiley and Sons, Inc.
- <sup>4</sup> Bywaters, E. G. L., and D. Beall: Crush Injuries with Impairment of Renal Function. *Brit. M. J.*, **1**: 427, 1941.

- 5 Corcoran, A. C., and I. H. Page: Effects of Hypotension Due to Hemorrhage and of Blood Transfusion on Renal Function in Dogs. *J. Exper. Med.*, **78**: 205, 1943.
- 6 DeGowin, E. L., E. D. Warner and W. Randall: Renal Insufficiency from Blood Transfusion; Anatomic Changes in Man Compared with Those in Dogs with Experimental Hemoglobinuria. *Arch. Int. Med.*, **61**: 609, 1938.
- 7 Evelyn, K. A., and H. T. Malloy: Microdetermination of Oxyhemoglobin, Methemoglobin and Sulfhemoglobin in a Single Sample of Blood. *J. Biol. Chem.*, **126**: 655, 1938.
- 8 Flink, E. B.: Blood Transfusion Studies; Relationship of Hemomoglobinemia and of pH of Urine to Renal Damage Produced by Injection of Hemoglobin Solutions into Dogs. *J. Lab. & Clin. Med.*, **32**: 223, 1947.
- 9 Flink, E. B., and C. J. Watson: Method for Quantitative Determination of Hemoglobin and Related Heme Pigments in Feces, Urine and Blood Plasma. *J. Biol. Chem.*, **146**: 171, 1942.
- 10 Goodpastor, W. E., *et al.*: Clinical and Pathologic Study of Kidney in Patients with Thermal Burns. *Surg., Gynec. & Obst.*, **82**: 652, 1946.
- 11 Hampton, J. K., Jr., and H. S. Mayerson: Hemoglobin Iron as a Stimulus for the Production of Ferritin by the Kidney. *Am. J. Physiol.*, **160**: 1, 1950.
- 12 Lalich, J. J.: Urine, Volume, Non-protein Nitrogen and Pigment Cast Studies in Rabbits with Hemoglobinuric Nephrosis. *Am. J. Med. Sci.*, **219**: 65, 1950.
- 13 Lauson, H. D., S. E. Bradley and A. Courmand with V. V. Andrews: The Renal Circulation in Shock. *J. Clin. Invest.*, **23**: 381, 1944.
- 14 Lucke, B.: Lower Nephron Nephrosis (Renal Lesions of Crush Syndrome, of Burns, Transfusions and Other Conditions Affecting Lower Segments of Nephron). *Mil. Surgeon*, **99**: 371, 1946.
- 15 Mallory, T. B.: Hemoglobinuric Nephrosis in Traumatic Shock. *Am. J. Clin. Path.*, **17**: 427, 1947.
- 16 Mason, J. B., and F. C. Mann: Effect of Hemoglobin on Volume of Kidney. *Am. J. Physiol.*, **98**: 181, 1931.
- 17 Merrill, J. P., *et al.*: The Use of an Artificial Kidney. II. Clinical Experiences. *J. Clin. Invest.*, **29**: 425, 1950.
- 18 ———: The Use of an Artificial Kidney. I. Technic. *J. Clin. Invest.*, **29**: 412, 1950.
- 19 Page, I. H., and A. C. Corcoran: Renal Venipuncture: Method of Explantation of Kidney for Venipuncture in Dogs. *Surgery*, **7**: 389, 1940.
- 20 Phillips, R. A., and P. B. Hamilton: Effect of 20, 60 and 120 Minutes of Renal Ischemia on Glomerular and Tubular Function. *Am. J. Physiol.*, **152**: 526, 1948.
- 21 Selknot, E. E.: Relation of Renal Blood Flow to Effective Arterial Pressure in Intact Kidney of Dog. *Am. J. Physiol.*, **147**: 537, 1946.
- 22 Trueta, J., *et al.*: Studies of the Renal Circulation. Springfield, Ill., 1947, Charles C. Thomas.
- 23 Yuile, C. L., M. A. Gold and E. G. Hinds: Hemoglobin Precipitation in Renal Tubules; Study of Its Causes and Effects. *J. Exper. Med.*, **82**: 361, 1945.