

## TOTAL PANCREATECTOMY FOR RECURRENT CALCAREOUS PANCREATITIS\*

E. F. McLAUGHLIN, M.D. AND JAMES S. C. HARRIS, M.D.

PHILADELPHIA, PA.

FROM THE GERMANTOWN HOSPITAL, PHILADELPHIA

THE TREATMENT of recurrent pancreatitis has been varied but progressive in recent years. The literature contains an increasing number of articles on methods used to alleviate this condition. We are reporting the clinical history of a patient who, following a previous bilateral splanchnicectomy, continued to have progressive symptoms, sufficient in severity to require a total pancreatectomy for relief.

A. M. (71031), a 28-year-old white female, entered the Germantown Hospital with complaints of nausea, vomiting and recurrent abdominal pain, of 3 years' duration. She had been previously studied in this institution in 1947, at which time she had given a history of heavy indulgence in alcohol, and of recurrent upper abdominal pain. Slight hepatomegaly was noted, but all studies, including liver function tests, were negative. She was discharged improved and with a questionable diagnosis of early liver cirrhosis. In May, 1948, the patient began to have intermittent attacks of upper abdominal pain, followed by nausea and vomiting. She was studied elsewhere in December, 1948, but was discharged without treatment. She was then followed by her family physician, but soon it was necessary to use Demerol for pain relief. This state continued until April, 1949, when she had a staged bilateral splanchnicectomy in still another hospital. Following these procedures, relief from pain was noted for a period of time. However, 7 months later, in November, 1949, her colicky abdominal pain, nausea and vomiting returned. These symptoms progressed in severity, and she was found to be diabetic and had become a confirmed narcotic addict. Once again she was admitted to the Germantown Hospital on February 2, 1950. Physical examination revealed a small thin patient of 91 pounds (she had lost 24 pounds

in 3 months), with evidence of dehydration and nutritional deficiency. The abdomen contained a round, firm, extremely tender mass about 7 cm. in diameter in the epigastrium. The liver seemed enlarged, but the spleen and kidneys were not palpable. On admission her temperature was 98 degrees F, pulse 102, respirations 22. Laboratory studies showed red blood cells, 4.2 million; hemoglobin 12.5 Gm.; white blood cells 12,500; blood sugar 179 mg. per 100 cc.; serum amylase 105 mg. per 100 cc.

Roentgen studies: "There is a large, soft tissue tumor mass nesting in the arm of the duodenal loop retroperitoneally measuring 10 cm. in its greatest dimension. There are multiple pancreatic calculi. The distal stomach and duodenal loop are deformed, compressed and separated by the presence of the mass. I am quite certain we are dealing with a tumor, cyst or pseudocyst of the pancreas. There is no evidence of intrinsic disease of the esophagus, stomach, duodenum or upper small bowel." (Figs. 1 and 2).

Due to the acute abdominal picture the patient was put on intravenous fluid and blood. The mass in the abdomen regressed to some degree, and she improved clinically. The patient's condition, however, was a dire one. Because of the progression of the disease, the severity of the symptoms, the failure of previous conservative surgery to give relief, and the development of an epigastric mass, it was decided that a direct operative attack on the pancreas itself should be attempted. Accordingly, on the fifth hospital day the abdomen was opened.

A large nodular, edematous, cystic mass in the region of the pancreas was found. The pathologic process involved the entire pancreas; head, body and tail. There was considerable inflammatory induration surrounding the organ and involving the adjacent structures. Parts of the tumor mass were very hard, other parts fluctuant.

A total pancreatectomy was carried out, during which various pathologic states were noted in the affected organ. There were some areas which were completely calcified, others showed cystic-like

\* Presented before the Philadelphia Academy of Surgery, December 3, 1951. Submitted for publication April, 1952.

cavities filled with a milky or cottage cheese-like deposit. Still others contained a translucent grayish liquid. In most of the intervening spaces, large amounts of fibrous tissue were present and in some areas there was the congestion of recent inflammation. No evidence of biliary inflammation, calculi, or other intra-abdominal disease was found.

In conjunction with the pancreatectomy, resection of the duodenum, the pyloric end of the stomach, and the spleen was carried out, and an end-to-side gastrojejunostomy and choledochojejunostomy were used to reconstitute the gastrointestinal tract and its adjacent organs.

Postoperatively the patient did fairly well. Her Levine tube was removed on the second postoperative day, and all the intravenous fluid therapy discontinued by the fifth postoperative day. She was placed on Pancreatin 5 Gm. 3 times a day, which was later reduced to 3 Gm. Her diabetes was controlled with considerable difficulty. Daily fractional urinalyses and fasting blood sugars were routine. Her blood sugar studies showed a marked rise following operation (Fig. 3). She was placed on a calculated caloric diet, which was frequently altered during the recovery period. Insulin was used according to demand. At the time of discharge in April, 1950, (60 days postoperatively) she was on a 2880 calorie diet consisting of protein, 120 Gm.; carbohydrate, 330 Gm.; and fat, 120 Gm. She received Protamine zinc insulin 20 units per day.

Stool studies were done on 2 occasions and showed increased fat and nitrogen losses following total pancreatectomy.

STOOL EXAMINATIONS

	3-11-50	3-29-50	Normal Values
Total weight, stool 24 hr. specimen	114 Gm.	190.5 Gm.	
Total fat 24 hours	7.6 Gm.	19.0 Gm.	Less than 7.0 Gm.
Total nitrogen	4.0 Gm.	4.5 Gm.	Less than 1.5 Gm.

From these, it was evident that at the time of the tests she was losing considerable amounts of fat and nitrogen by stool, perhaps explained in part by her large oral intake. Her general improvement since would indicate that a balance was struck and that she is able to retain sufficient fat and nitrogen for body needs.

Since discharge, the patient has had 3 other admissions to this hospital for control of her diabetes and nutritional deficiency. At last appearance to her physician in February, 1952, the patient was very well; her weight being 104

pounds. Her caloric intake was 5000 to 6000 calories daily, and she used Protamine zinc insulin, 20 units, daily. The patient is not on any pancreatic substitution therapy, she has no pain and is no longer addicted to the use of narcotics. Her stools are still of a bulky fatty nature.

DISCUSSION

**Etiology.** Bockus<sup>2</sup> has modified R. Jones' classification of the etiology of acute pancreatitis into three main categories: (1) pancreatitis of infectious origin; (2) pancreatitis of non-infectious origin, *e.g.*, bile reflux, pancreatic duct obstruction, trauma, vascular accidents; and (3) a combination of any two factors given. Opie<sup>20</sup> and Archibald<sup>1</sup> first suggested that chronic pancreatitis was frequently due to regurgitation of bile into the pancreatic duct by a common biliary-pancreatic passage. This regurgitation resulted from a disturbance to the sphincter of Oddi. This work has been confirmed by others (Jones<sup>16</sup>). R. Jones, reviewing the etiology of this disease, points out that the common-channel theory is tenable in only 60 per cent of patients, that vascular damage, infection or trauma account for 30-40 per cent and in perhaps 10 per cent a common-channel is formed due to a lodgement of a small biliary calculus at the ampulla of Vater. Concerning the calcium deposits seen by roentgen ray and found in the pancreas at operation, it appears that the recurrent pancreatitis is the important factor in the disease; that the recurrent inflammation and not the calcification is the core of the problem. As Bowers<sup>3</sup> has remarked, "We pay no attention to the calcification, but treat the pancreatitis." Calcification then, is but a late signpost, and in early recurrent cases is not seen.

**Pathology.** The pathologic changes found in acute pancreatitis may vary from the mild, edematous, enlarged gland to the severe type with serious intrapancreatic hemorrhage, extensive fat necrosis of the gland, and even extension of these processes into the surrounding fatty tissue

areas. Abscess formation may follow, and/or pseudo-cyst formation occur. In the recurrent cases with variable periods of inactivity, the organ is converted into a hard, irregular, nodular mass. There is progressive replacement by sclerotic fibrous tissue and a loss of acini and islets of Lan-

plaint. However, splanchnicectomy only approaches this problem in the strict consideration of pain and pain fibers. Mallet-Guy<sup>17</sup> and his co-workers first reported in 1945 the use of this method for such relief of pain. More recently, he has listed 70 patients treated in this fashion with favor-

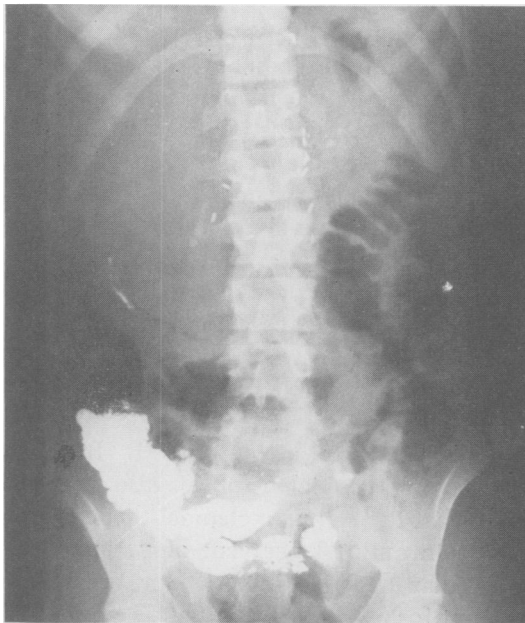


FIG. 1

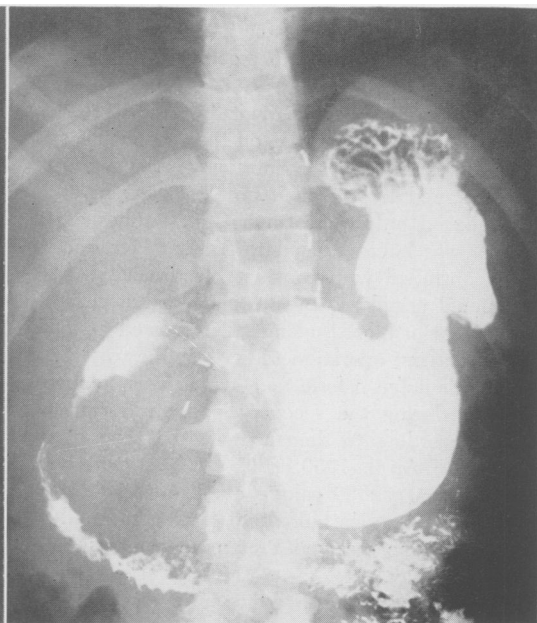


FIG. 2

FIG. 1.—Roentgen film showing extensive calcification of the pancreas. Metal clips indicate previous bilateral splanchnicectomy.

FIG. 2.—Barium study illustrating enlarged duodenal loop with deformity of distal stomach, suggesting pancreatic mass. Calcification of head of pancreas noted.

gerhands. Calcification appears as a late manifestation, and Priestley<sup>23</sup> emphasizes that the progress of the disease should be halted before it arrives at such an advanced stage.

**Treatment.** Surgical procedures recommended for treatment of this condition fall into four categories: Those aimed at (1) relief of pain, (2) prevention of progression of the disease, (3) eradication of the disease, and (4) miscellaneous procedures.

1. *Relief of Pain:* Essentially all of the procedures discussed are directed toward the relief of pain, as this is a major com-

able results in 83 per cent.<sup>18</sup> Other investigators have confirmed his results.<sup>5, 15, 24, 26</sup> Bowers cautions, however, that the type of sympathectomy must be considered; e.g., the intra-abdominal ones are postganglionic in type and the regeneration tendency thus may give only temporary relief. He believes that thoracic sympathectomies appear of greater value. Ray and Console<sup>24</sup> have reported four cases with good results; deTakats *et al.*<sup>27</sup> list five patients and Grimson<sup>15</sup> and his group, and Rienhoff<sup>26</sup> have reported its use with improvement in their patients.

2. *Prevention of Progression of the Dis-*

ease: Sphincterotomy as described by Doubilet and Mulholland,<sup>9-12</sup> and chole-  
dochojejunostomy as Bowers and Green-  
field<sup>5</sup> have recommended, is included in this  
group. Using Opie's etiologic concept

have reported the use of choledocho-  
jejunostomy Roux-en-Y technic in five  
patients. The underlying principle of this  
method is a "shunt" procedure, in that bile  
is completely diverted into the small intes-

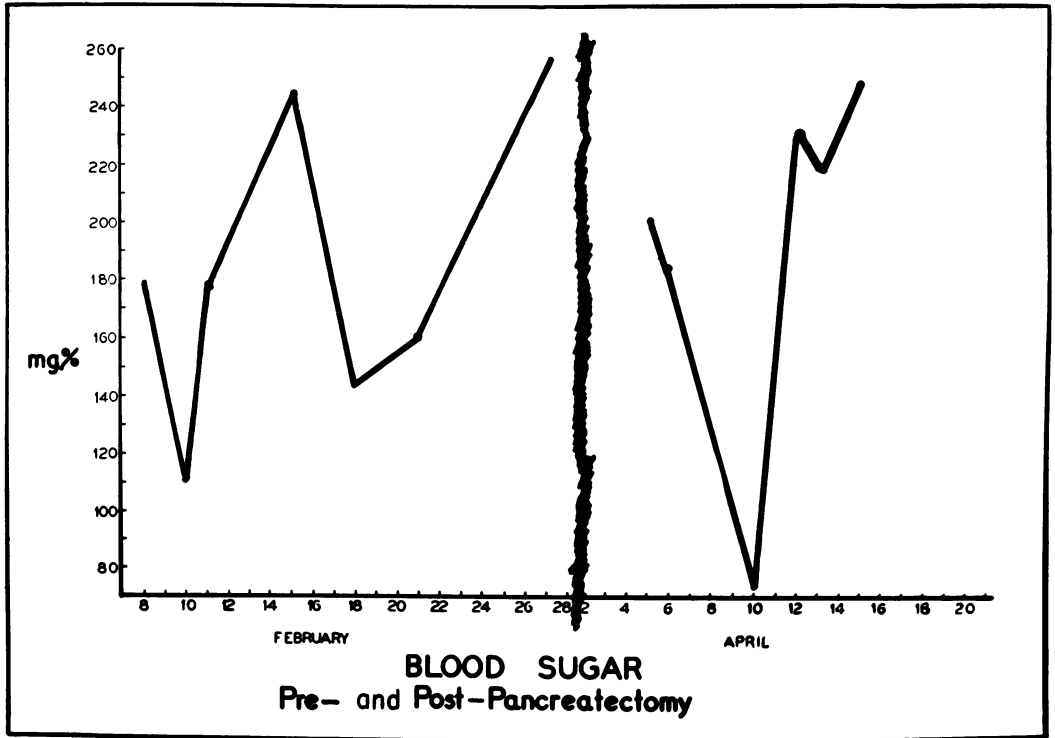


FIG. 3.—Graph illustrating wide range of fasting blood sugar levels, both before and following pancreatectomy.

of bile reflux into the pancreatic ducts, Doubilet and Mulholland's plan of the division of the sphincter of Oddi is logical. Their results in 73 cases<sup>12</sup> are most promising and Dragstedt,<sup>13</sup> Elman,<sup>14</sup> and Bowers<sup>3</sup> agree on the physiologic basis for this procedure. By this method, the bile reflux is lessened or prevented and thus the progression of the pancreatitis and its inevitable gland deterioration and calcinosis is halted. Furthermore, Doubilet and Mulholland stress that operative section of the sphincter of Oddi should be done even in the absence of pain to prevent progression of the disease.<sup>12</sup>

More recently, Bowers and Greenfield<sup>5</sup>

tine without possible reflux into the pancreas. All five of their cases have responded favorably and all without evidence of cholangitis. Such a procedure with division of the common duct is a radical one, and they have left a T-tube in their patients at the choledochal anastomosis for three months. Poth<sup>22</sup> also has used a Roux-en-Y technic to drain the biliary tract in recurrent pancreatitis. He reports five cases, of which one was done by choledochojejunostomy and four by cholecystojejunostomy.

3. *Pancreatectomy.* Whipple<sup>20</sup> has reported five patients for whom total or partial pancreatectomy was done for the

intolerable pain associated with pancreatic fibrosis, calcinosis and calculi. All were relieved by such a method. Clagett,<sup>28</sup> Parsons,<sup>21</sup> and Zininger<sup>30</sup> have also used this method, although Clagett's patient later died from hypoglycemic reaction as did Zininger's patients two and one-half months later. The removal of the dis-

of other methods now available to prevent this progression to calcinosis, it would seem that pancreatectomy will rarely be required in the future. However, in the case of the patient we are reporting, the previous bilateral splanchnicectomy was insufficient for such far-advanced disease. The probable continued bile regurgitation, or

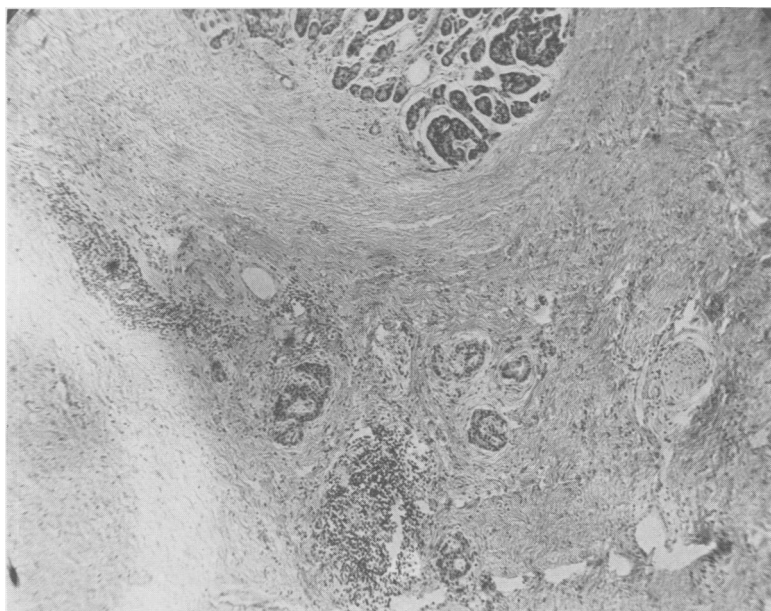


FIG. 4.—Photomicrograph (x75) of pancreas. Note marked destruction of acini with replacement by dense fibrous tissue.

eased pancreas is advantageous in as far as its pathologic process is concerned. However, such a procedure is most formidable. The operation is time consuming and tedious mainly because the involved tissues are so firm and bound down and because the adjacent tissues have by contiguity become involved in the chronic inflammatory process and are difficult to separate, especially veins. The morbidity and mortality, which one would expect to be very high, are not overwhelmingly so in the small number of reported cases. The postoperative complications, e.g., diabetes, digestive disturbances, frequently force the patient to permanent attention to these problems. Of course, in the consideration

pancreatic duct obstruction, was so great that progression was the only possible outcome. It should be reiterated that in this patient the abdominal mass felt on admission regressed before operation. We suggest that this was probably due to the relief of the obstruction of the pancreatic duct with drainage of some of the cystic areas. It would thus lend support to the pancreatic duct obstruction theory, especially since bile was absent from the organ removed in this case. And finally, this woman illustrates what progression of the disease does to a patient, and points the lesson that treatment should be instituted early before such manifestations are present. It is only with great reluctance that

we did a pancreatectomy, but because of the long-standing disease, the patient's addiction, and a burned out, fibrotic, cystic, calcified pancreas with irreversible changes, it was the only course.

4. *Miscellaneous Procedures.* (A) Subtotal gastrectomy and vagotomy: Richman and Colp<sup>25</sup> have reported three patients with chronic pancreatitis treated with subtotal gastrectomy, and two of these with complementary vagotomy. All three patients complained of pain, diarrhea, and dyspepsia. Two were relieved by the operation. The third had pain relief also, but his diabetes became progressively worse and he died in diabetic coma. The rationale of their method lies in the elimination of the hormonal phase of gastric secretion with lessened hydrochloric acid production. This reduction, plus further neutralization of the gastric acid by regurgitated alkaline duodenal contents through the gastroenteric stoma, decreases the amount of secretin formation and produces, therefore, a lessened volume of pancreatic juice, less pancreatic duct distention and therefore, less pain.

(B) Vagotomy: McCleery *et al.*<sup>19</sup> have recently reported the use of vagotomy in 11 patients suffering from recurrent attacks of acute pancreatitis, with improvement in all. He believes that psychogenic stimuli play an important role in the etiology of recurrent acute pancreatitis through emotionally induced spasm of the sphincters. Vagotomy thus (a) prevents any ampullary and pancreatic duct spasm of psychogenic origin, (b) prevents increased pancreatic enzyme production of psychogenic origin, (c) decreases the enzyme secretion resulting from the presence of peptones and hydrochloric acid in the duodenum, (d) prevents increased hydrochloric acid production by the stomach in response to emotional stimuli, and (e) ameliorates the effects of the increased gastric acidity formed in response to excessive alcohol intake.

(C) Biliary tract surgery: As Bowers<sup>4</sup> discusses so clearly, in many instances pancreatitis has associated cholecystitis, cholelithiasis, common duct stone, or combinations of these with or without a demonstrable channel between the common and pancreatic ducts. With the known relationship of pancreatitis and biliary tract infection (42-80 per cent)<sup>16</sup> it would appear that sphincter spasm may result from the biliary disease. Many cases, therefore, may well be remedied by biliary tract surgery.

#### SUMMARY

1. A report of a case of advanced recurrent calcareous pancreatitis with a full range of pathologic changes is given.
2. Total pancreatectomy was done with success.
3. We believe that there are various factors contributing to the causation of the disease, and that, while the exact mechanism of its development is not completely known, obstruction of outflow to pancreatic secretions is a most important factor.
4. We believe that as to treatment, different approaches are indicated in cases which represent different degrees of severity of the disease.
5. We feel that for the pancreas that has multiple, irreversible, pathologic changes throughout its structure, which are giving unbearable pain, total pancreatectomy is justified despite prolonged duress to the patient and exhaustion to the operator.

#### BIBLIOGRAPHY

- 1 Archibald, E.: The Experimental Production of Pancreatitis in Animals as the Result of Resistance of the Common Duct Sphincter. *Surg., Gynec. & Obst.*, **28**: 529, 1919.
- 2 Bockus, H. L.: *Gastroenterology*. W. B. Saunders & Co., 1946.
- 3 Bowers, R. F.: Discussion of Doubilet & Mulholland. *Ann. Surg.*, **132**: 794, 1950.
- 4 Bowers, R. F.: Surgical Therapy for Chronic Pancreatitis. *Surgery*, **30**: 116, 1951.

- <sup>5</sup> Bowers and Greenfield: J. Choledochojejunostomy. *Ann. Surg.*, **134**: 99, 1951.
- <sup>6</sup> Cattell, R. B.: Partial Pancreatectomy: Excision of the Tail and Body of the Pancreas. *S. Clin. North America*, **29**: 779.
- <sup>7</sup> Cattell, R. B.: Discussion of A. O. Whipple. *Ann. Surg.*, **124**: 1006, 1946.
- <sup>8</sup> Connolly, J. E., and V. Richards: Bilateral Splanchnicectomy and Lumbodorsal Sympathectomy for Chronic Relapsing Pancreatitis. *Ann. Surg.*, **131**: 58, 1950.
- <sup>9</sup> Doubilet, H., and J. H. Mulholland: The Surgical Treatment of Recurrent Acute Pancreatitis by Endocholedochal Sphincterotomy. *Surg., Gynec. & Obst.*, **86**: 295, 1948.
- <sup>10</sup> Doubilet, H., and J. H. Mulholland: Recurrent Acute Pancreatitis; Observation on Etiology and Surgical Treatment. *Ann. Surg.*, **128**: 609, 1948.
- <sup>11</sup> Doubilet, H., and J. H. Mulholland: The Surgical Treatment of Pancreatitis. *S. Clin. North America*, **29**: 339, 1949.
- <sup>12</sup> Doubilet, H., and J. H. Mulholland: Surgical Treatment of Calcification of the Pancreas. *Ann. Surg.*, **132**: 786, 1950.
- <sup>13</sup> Dragstedt, L. R.: Discussion of Doubilet and Mulholland. *Ann. Surg.*, **132**: 786, 1950.
- <sup>14</sup> Elman, R.: Discussion of Doubilet and Mulholland. *Ann. Surg.*, **132**: 786, 1950.
- <sup>15</sup> Grimson, K. S., F. W. Hesser and W. W. Kitchen: Early Clinical Results of Transabdominal Coeliac and Superior Mesenteric Ganglionectomy, Vagotomy, or Transthoracic Splanchnicectomy in Patients with Chronic Abdominal Visceral Pain. *Surgery*, **22**: 230, 1947.
- <sup>16</sup> Jones, R.: The Etiology and Pathogenesis of Acute Hemorrhagic Pancreatitis. *Am. J. Med. Sci.*, **205**: 277, 1943.
- <sup>17</sup> Mallett-Guy, P., R. Jeanjean and P. Serrettaz: Ré sultats éloignés de la splanhnicectomie unilatérale dans le traitement des pancréatites chroniques. *Lyon, Chir.*, **40**: 293, 1945.
- <sup>18</sup> Mallett-Guy, P., and M. J. Beaujeu: Treatment of Chronic Pancreatitis by Unilateral Splanchnicectomy. *Arch. Surg.*, **60**: 233, 1950.
- <sup>19</sup> McCleery, R. S., J. E. Kesterson and W. R. Schaffarzick: A Clinical Study of the Effect of Vagotomy on Recurrent Acute Pancreatitis. *Surgery*, **30**: 130, 1951.
- <sup>20</sup> Opie, E. L.: The Etiology of Acute Hemorrhagic Pancreatitis. *Bull. Johns Hopkins Hosp.*, **12**: 182, 1901.
- <sup>21</sup> Parsons, W. B.: Discussion of B. S. Ray and C. L. Neill. *Ann. Surg.*, **126**: 724, 1947.
- <sup>22</sup> Poth, E. J.: Discussion of Bowers. *Surgery*, **30**: 145, 1951.
- <sup>23</sup> Priestley, J. T.: Discussion of Doubilet and Mulholland. *Ann. Surg.*, **132**: 796, 1950.
- <sup>24</sup> Ray, B. S., and A. D. Console: The Relief of Pain in Chronic (Calcareous) Pancreatitis by Sympathectomy. *Surg., Gynec. & Obst.*, **89**: 1, 1949.
- <sup>25</sup> Richman, A., and R. Colp: Chronic Relapsing Pancreatitis, Treatment by Subtotal Gastrectomy and Vagotomy. *Ann. Surg.*, **131**: 141, 1950.
- <sup>26</sup> Rienhoff, W. F., and B. M. Baker: Pancreolithiasis and Chronic Pancreatitis, Preliminary Report of a Case of Apparently Successful Treatment by Transthoracic Sympathectomy and Vagotomy. *J. A. M. A.*, **134**: 20, 1947.
- <sup>27</sup> deTakats, G., L. E. Walter and J. Lasner: Splanchnic Nerve Section for Pancreatic Pain. *Ann. Surg.*, **131**: 44, 1950.
- <sup>28</sup> Waugh, J. M., C. F. Dixon, O. T. Clagett, J. L. Bollman, R. G. Sprague and W. W. Comfort: *Proc. Mayo Clin.*, **21**: 25, 1946.
- <sup>29</sup> Whipple, A. O.: Radical Surgery for Certain Cases of Pancreatic Fibrosis Associated with Calcareous Deposits. *Ann. Surg.*, **124**: 991, 1946.
- <sup>30</sup> Zininger, Quoted by Whipple: *Ann. Surg.*, **124**: 991, 1946.