

ANASTOMOSIS OF RIGHT BRONCHUS TO TRACHEA FORTY-SIX DAYS FOLLOWING COMPLETE BRONCHIAL RUPTURE FROM EXTERNAL INJURY*

WILSON WEISEL, M.D., AND ROBERT J. JAKE, M.D.

MILWAUKEE, WISCONSIN

FROM THE DEPARTMENT OF SURGERY, VETERANS ADMINISTRATION HOSPITAL, AND MARQUETTE UNIVERSITY SCHOOL OF MEDICINE
WOOD, WISCONSIN

THE SUCCESSFUL REIMPLANTATION of the right bronchus into the trachea for the return and preservation of right lung function, following complete bronchial rupture due to external injury 46 days previously, we believe, is of sufficient interest to warrant the following case report. In addition to the surgical therapy, however, the opportunity to study the effect of this unusual lesion on the bronchial structure and on the ability of the lung to regain function after prolonged bronchial obstruction has been unique.

CASE REPORT

R. S., a 32-year-old white male veteran was transferred to this hospital from another institution on April 29, 1952. The history on admission was obtained largely by telephone conversation with the patient's referring physician. On April 4, 1952, the patient had been severely injured in an automobile accident and was admitted to the former hospital in a critical state. Diagnoses of fractures of the right 2nd, 3rd, 4th, 5th and 6th ribs, right pneumo-hemothorax, subcutaneous emphysema, fracture of right acetabulum and anterior subluxation of the right femoral head were made. The patient was treated by complete bed rest, right thoracentesis and bandage immobilization of the chest. On April 6, 1952, a right thoracotomy was performed through a lateral type of approach, with

excision of small segments of the right 3rd, 4th and 5th ribs, apparently for the evacuation of blood and the suture of lacerations of the right upper lobe. At this time, the patient also received blood transfusions. A closed reduction of the right hip was performed on April 19, 1952. Because of lack of expansion of the right lung, a bronchoscopy was done on April 24, 1952, and a diagnosis of right main stem obstruction or stenosis was made. The patient was later transferred to this hospital by ambulance as recounted.

On admission, the patient was obviously critically ill. He was pale, dyspneic, extremely apprehensive, and at times appeared to be almost moribund. The temperature was 101°F., pulse rate 140; respirations 38. The blood pressure was 98/56. The chest showed a marked flattening and paradoxical motion of the right chest. The entire right chest was dull to percussion, and breath sounds were absent over the right chest. The heart apex beat was shifted slightly to the left. The patient complained of constant pain in the right chest and arm. The right shoulder was almost completely frozen with the arm at the side of the chest. A boot cast was present on the right lower leg with an incorporated bar to maintain external rotation.

Clinical studies revealed a hemoglobin of 10.5 Gm.; red blood cells numbered 3,800,000; the white blood cells 15,000; the sedimentation rate was 100 and the serum protein value was 6 Gm. per 100 cc. Roentgenologic examination of the chest showed almost complete opacity of the right thorax (Fig. 1). There were, in addition, fractures of the 2nd to 7th right ribs with portions of the 3rd, 4th and 5th ribs missing, and fractures of the anterior left 2nd, 3rd and 4th ribs. Radiologic examination of the spine and extremities showed a small stellate fracture of the right acetabulum which was apparently healing.

The patient was treated by administration of nasal oxygen. Demerol for pain relief, 600,000

* Sponsored by the Veterans Administration and published with the approval of the Chief Medical Director. The statements and conclusions published by the authors are a result of their own study and do not necessarily reflect the opinion or policy of the Veterans Administration. Submitted for publication September, 1952.

units of penicillin daily and by blood transfusion, 500 ml. of whole blood. After orthopedic consultation, the right lower leg cast was removed in preparation for ambulation of the patient. Neurologic examination showed a foot drop of the right foot and weakness of the right arm consistent with a brachial plexus lesion; physiotherapy was started intensively to correct these apparent traumatic nerve injuries. In addition, the patient was started on orientation physiotherapy directed at eventual resumption of right chest function. Aspiration of the right lower lateral chest gave a dry tap.

Bronchoscopy, performed on May 1, 1952, showed a complete occlusion of the right bronchial orifice at the level of the carina. It was our impression that complete bronchial rupture had occurred with sealing of the former orifice. Because of the patient's septic clinical course, it was decided to treat him intensively with various antibiotics before attempting definitive surgical therapy of the right thoracic pathologic condition. He was given in addition to the penicillin, streptomycin, 1 Gm. daily, and in rotation for 5 day courses, aureomycin and chloromycetin 1000 mg. daily. The patient became afebrile after 4 days, and remained so until operation was performed. During this time, he also received intensive physiotherapy, occupational therapy, and was given a well rounded diet. His general condition appeared to improve, although he continued to be markedly dyspneic on the slight exertion of taking 4 or 5 steps. Pulmonary function studies were impossible to obtain at this time because of the patient's inability to cooperate in the studies. By May 19, however, the temperature was normal, the blood hemoglobin was up to 14.5 Gm. and the serum protein was 6.55 Gm. per 100 ml. of blood.

On May 20, 1952, a right thoracotomy was performed through a posterolateral incision under general endotracheal anesthesia, with the patient in a left lateral decubitus position. The right pleural space was entered through the fourth intercostal space and was found to be obliterated by old blood clots and heavy fibrinous and fibrous bands. The blood clots were removed manually. During this process, a loculated empyema cavity was found in the apex, and after the pus was evacuated for culture, the entire wall was removed by decortication from the mediastinal surface and the parietal pleura. The lung was found to be collapsed into a small oval about 6 cm. in diameter, against the pericardium by a dense fibrous membrane.

Decortication of the lung was performed by traction and sharp dissection of the peel. The mediastinal structures were then dissected, and after ligation and division of the azygos vein, the lower trachea was exposed. The area of right

bronchus position was replaced by an irregular nub of scar tissue along the lateral edge of the lower trachea at the level of the left bronchial junction. The distal end of the right bronchus was found completely closed and retracted within the hilus of the collapsed right lung 6.5 cm. from the carinal portion of the trachea (Fig. 2). The pulmonary artery and superior and inferior veins were isolated and found to be intact and normal to palpation.

After identifying the hilar structures, the right lung was mobilized. The right distal bronchus was then opened by excision of the fibrous, granulomatous tissue which closed it. From the opened bronchus a tenacious, black mucoid material extruded which was somewhat reminiscent of meconium. This material was carefully removed from the bronchial tree by the application of suction applied through a catheter introduced into the bronchi and by gentle milking of the lung. After cleaning, the right lung was partially inflated by positive pressure supplied by an aseptic syringe applied through a catheter placed in the bronchial lumen (Fig. 2). The wound edges of the bronchial stump were then debrided and the stump was found to be partially made up by the superior wall of the upper lobe bronchus. The edge of the bronchial wall bled when cut and grossly appeared normal, and the decision was made to reimplant the bronchus into the trachea.

A tracheal window was made by excising a portion of the right lateral wall above the carina about the size of the distal bronchial stump (Fig. 3). By intermittent suction, the trachea and left bronchus were cleared of secretions and blood. Interrupted sutures of 000 cotton were placed through all layers of the new opening in the trachea and the distal bronchial stump. At intervals, the tracheal window was occluded by the finger tip to allow application of positive pressure assistance to the left lung. The previously placed sutures were then pulled taut together and tied securely, thereby producing accurate apposition of the tracheal and bronchial wound edges. Before approximating the 2 structures, however, a previously prepared long endotracheal tube was threaded into the right intermediate bronchus from the trachea past the anastomosis (Fig. 3). Perforations in this tube provided for aeration of the left lung and the right upper lobe orifice. The anastomosis was completed by placing additional 0000 cotton sutures between those previously placed. The lung was then expanded by positive pressure by the anesthesiologist.

The diaphragm which was adherent in a high position to the lateral chest wall, was mobilized and the remaining peel of the hemothorax was removed from the parietal chest wall. Hemostasis was obtained and 5 catheters were placed for subaqueous

drainage of the pleural space. The wound was closed in anatomic layers with interrupted cotton sutures. The patient received 2000 ml. of whole blood during the procedure, and he was returned to the recovery room in good condition.

The endotracheal tube which we utilized as a bronchial splint was taped securely to the patient's mouth, and it was aspirated with a small catheter at 30 minute intervals for the next 3 days. A constant negative pressure of 5 to 10 cm. of water was applied to all of the subaqueous drainage bottles

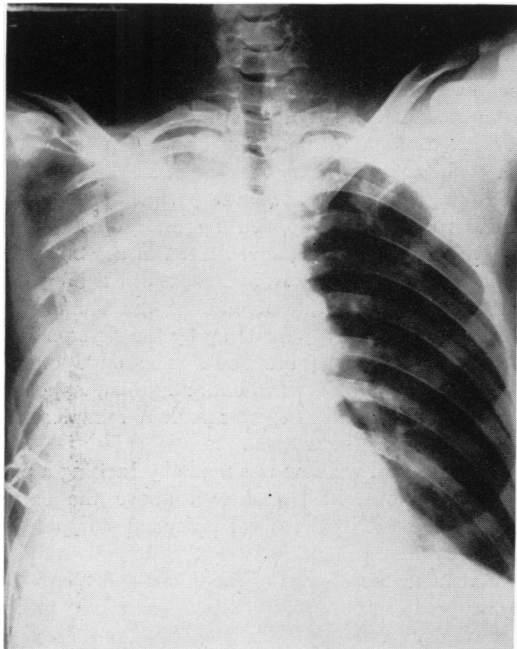


FIG. 1.—Roentgenogram on admission showing opacity of the right chest and rib fractures as described in the text.

by means of multiple Stedman pumps. The penicillin and streptomycin were continued in the postoperative period. Soon after operation, the patient was allowed to sit on the edge of his bed with his legs dependent, and physiotherapy was resumed. He was ambulant the first postoperative night, and gradually and consistently increased ambulation during his postoperative period.

Cultures of the material obtained at surgery from the chest revealed *E. coli* and beta hemolytic streptococci. Pathologic examination of the material removed was diagnosed as moderate pleuritis. The patient had an elevation of temperature up to 100°F. for 5 days. He then became afebrile and remained so for the remainder of his convalescence.

Postoperative roentgen examination of the chest showed about 80 per cent reëxpansion of the right lung (Fig. 4). On the fourth day after thoracotomy, a tracheotomy was performed under local infiltration anesthesia, and the endotracheal tube was removed. The tracheotomy tube was in turn removed 4 days later, when it was evident that the danger of laryngeal edema and obstruction was past. The chest catheters were removed singly from the fifth to the twelfth postoperative day.

The patient's general improvement after that time was dramatic. His appetite improved markedly; his dyspnea gradually disappeared and with intensive physiotherapy, the motions of the right arm and leg were gradually increased. Because of his continued improvement, he was given a series of "passes" from the hospital to visit his family, and he responded well to the increased activity (Fig. 5).

A repeat bronchoscopy was performed on June 24, 1952, for the purpose of examining the bronchotracheal anastomosis. The latter was well healed and covered by smooth normal epithelium, except for one small area where a cotton suture had eroded through the wall at the anastomotic line; this suture was removed by a ball-bearing forceps. The variations from normal which could be observed were the fact that the opening was about two-thirds normal size; the upper lobe spur presented prominently within the lumen, and the secondary upper lobe divisions could be easily seen; but a number 7 x 40 Jackson scope was easily passed into the intermediate portion of the bronchus to visualize the middle and lower lobe bronchi; the edges of the bronchial entrance were rigid and there was no movement or collapse with respiratory motions or coughing. The left bronchial opening appeared slightly depressed and there was no definite tracheal carina.

As mentioned above, the patient demonstrated a gradual, favorable increase in his exercise tolerance which coincided with improved chest expansion and disappearing paradoxical motion of the chest wall. We attempted to study these changes objectively at intervals. Ventilatory studies performed on June 26, 1952, revealed a vital capacity of 2189 cc.; the walking ventilation was 11.6 L. per minute, and the maximum breathing capacity 72.6 liters, or 60 per cent of his expected. These factors gave a walking ventilation to maximum breathing capacity ratio of 0.16. These same studies were repeated July 16, 1952, with the following results: vital capacity 2365 cc.; maximum breathing capacity 94 liters or 76 per cent of expected; walking ventilation 12 liters; walking ventilation/maximum breathing capacity ratio 0.12.

ANASTOMOSIS OF RIGHT BRONCHUS TO TRACHEA

A bronchspirometry was performed on July 17, 1952. Although the Zavod catheter was readily placed in the left bronchus, the procedure and kymograph tracings were technically unsatisfactory for reasons which were not readily ascertainable. It was evident that the right lung was participating in the oxygen uptake, but after considerable manipulation, the procedure was abandoned because of progressive and marked apprehension of the patient. It was the opinion of Dr. Francis Landis who performed the test, that partial occlusion of the right bronchial lumen occurred with

occurred during inspiration and the chest expansion was markedly improved. Moderate restriction of abduction of the right arm was still present due to contraction of the teres major (Fig. 8) and a slight foot drop of the right foot was still present. The patient, however, had improved sufficiently to return to his former occupation.

DISCUSSION

The amenability of the larger bronchi and trachea to surgical procedures for pres-

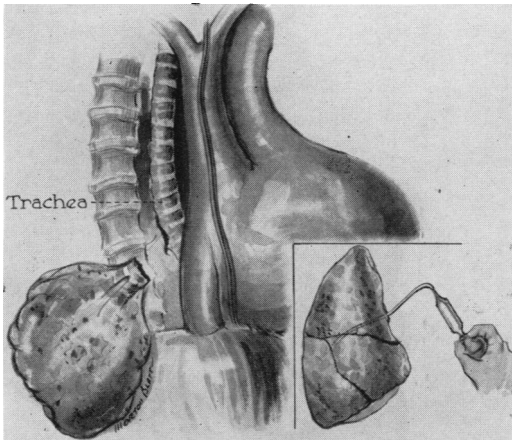


FIG. 2.—Artist's diagrammatic expression of pathologic condition seen following decortication of the right lung. Note separation of right bronchus from trachea with fibrous sealing of bronchial and tracheal wounds. Insert shows method of demonstrating inflatability of right lung after opening right bronchus.

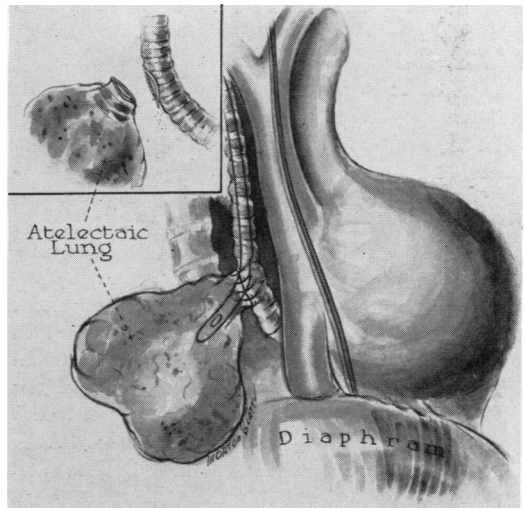


FIG. 3.—Artist's diagrammatic demonstration of the preparation (insert) of the bronchus and trachea for anastomosis and the completion of the procedure (large drawing) with the endotracheal catheter placed in the right bronchus.

inflation of the catheter balloons. This procedure was satisfactorily repeated on August 14, 1952, by enlarging the tracheal opening of the Zavod catheter. The results of this procedure were as follows: Oxygen consumption right lung 37.3 per cent, left lung 62.7 per cent; minute volume right lung 4,980 cc., left 6000 cc.; tidal air right lung 249, left 300; ventilatory equivalent right lung 3.0, left lung 2.1; the vital capacity right lung 913, left lung 1826 and the supine vital capacity was 2739.

A bronchogram with lipidol was performed on July 23, 1952. Except for a minor distortion of the endobronchial pattern, the bronchogram was significant for its normal appearance. There was no evidence of bronchiectasis (Figs. 6 and 7).

After a series of leaves from the hospital, the patient was discharged August 15, 1952, because it was thought that he had received maximum improvement under a hospital regimen. At the time of his discharge, slight flattening of the right chest was present, but normal motion of the chest

ervation of pulmonary function and reconstructive measures has been proven by experimental and clinical reports during the past few years.^{4, 6, 7, 8, 9, 10, 12, 15, 23, 25, 28, 31, 35} The healing properties of the bronchus and trachea have been well illustrated by the case herein reported, and the tremendous value to the patient of this ability requires no emphasis. It is worthwhile pointing out, as others have previously shown, that although the bronchial circulation was completely severed by the traumatic injury, in this case, the healing qualities of the bronchus were not impaired.

The clinical recognition of traumatic bronchial rupture from extrathoracic injury

FIG. 4

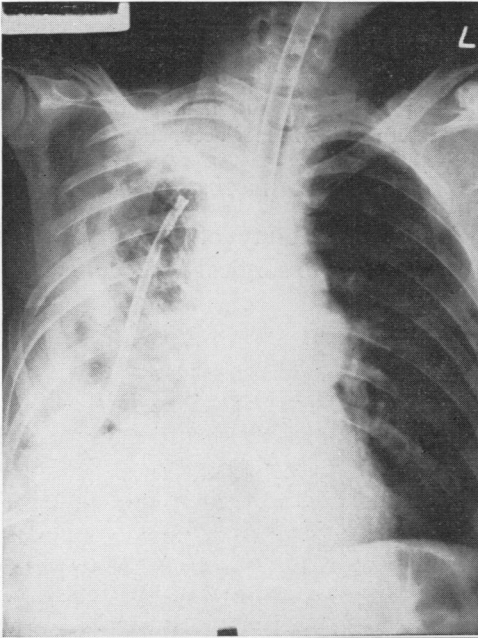


FIG. 5

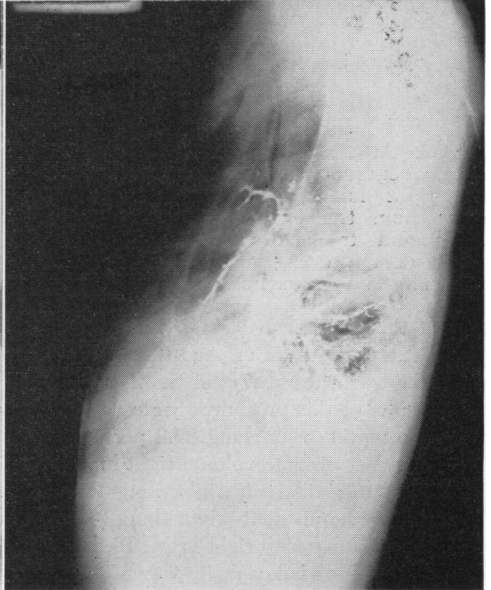
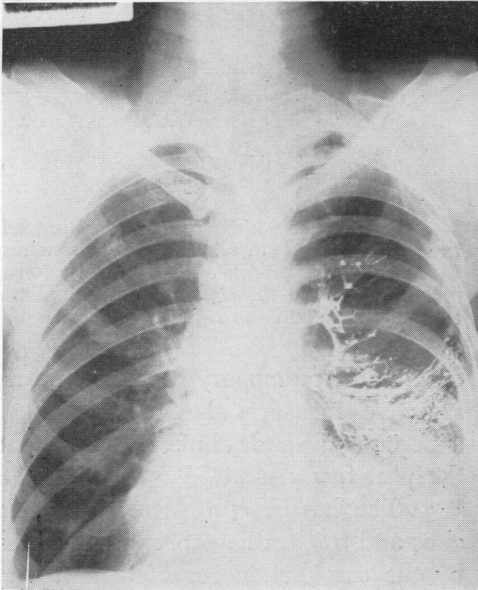
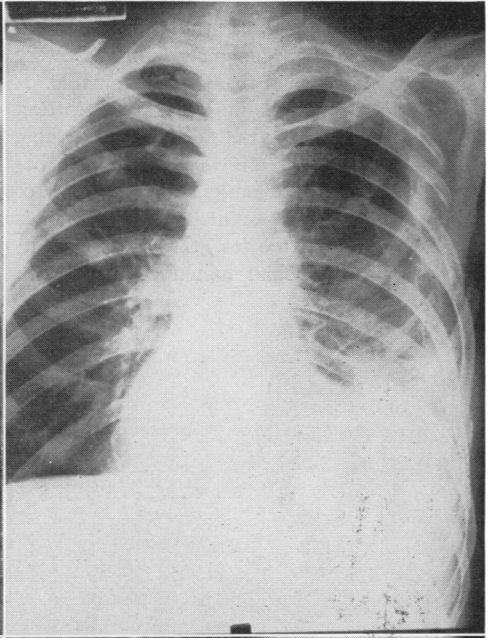


FIG. 6

FIG. 7

FIG. 4.—Postoperative roentgen ray of chest showing initial reexpansion of the right lung; intrapleural catheters in place for subaqueous drainage; endotracheal tube to the right bronchus in place.

FIG. 5.—Roentgenogram taken of the chest about one month postoperative showing almost complete re-expansion of the right lung and clearing of the pleural reaction.

FIG. 6.—PA roentgenogram following instillation of lipiodol into the right bronchus. Slight distortion of right bronchial relationships but no evidence of bronchial block or bronchiectasis.

FIG. 7.—Lateral view of thorax after bronchogram showing no evidence of bronchial block or dilatations.

should be made more frequently in view of the large number of auto accidents occurring yearly. Although this lesion has apparently been rarely diagnosed in the past, as pointed out by Paulson,²⁸ about 50 cases have been reported in the literature.^{1, 2, 5, 11, 13, 14, 16, 17, 18, 19, 20, 21, 24, 26, 27,}

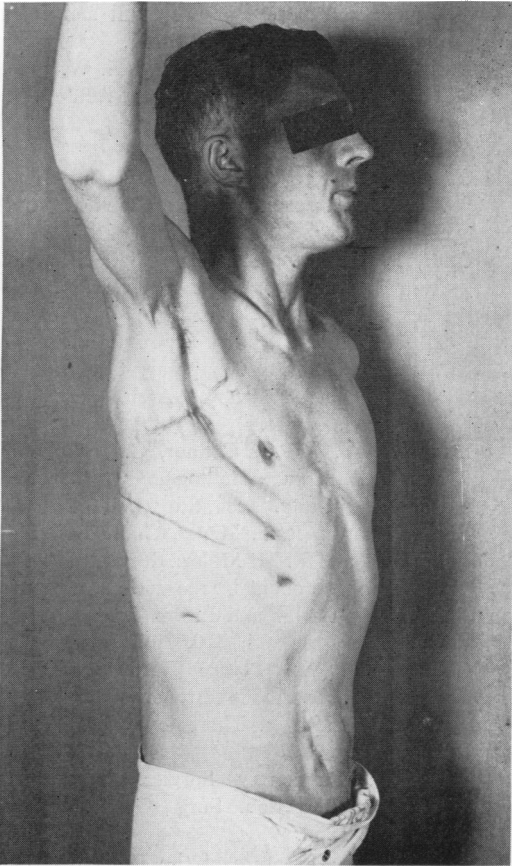


FIG. 8.—Lateral view of patient one month after operation showing scar of previous thoracotomy performed elsewhere below right axilla, anterior end of posterolateral scar, ability of patient to abduct arm and the fixation in axilla largely due to contraction of the teres major.

has increased steadily. It is interesting, however, that in the large number of thoracic wounds seen in World War II, few wounds of the large bronchi were encountered.^{3, 22, 30}

The highly successful outcome of the results of early repair of accidental bronchial tears, ruptures or divisions which have been reported,^{11, 23, 31, 35} clearly indicates the importance of early diagnosis and direct surgical therapy in reducing the high mortality and marked morbidity in these lesions. Other forms of therapy have been previously described or suggested,^{11, 14, 16, 18, 21} such as bronchial dilatation, electrocoagulation of strictures, use of pneumothorax or other collapse measures, lung resection, or the negative policy of allowing a fibrothorax to develop. However, the authors of these articles have implied that a more definitive approach to the problem would be preferable.

There has been no exactly similar case to that reported described in the literature which we have reviewed. The chief features demonstrated by this case have been previously pointed out, however, by other authors. The apparent small amount of pathologic change and infection in the lung and bronchi caused by prolonged complete bronchial occlusion coincides with the pathologic description of removed specimens,^{14, 19} and with the findings of experimental work on rabbits by Tannenberg and Pinner.³⁴ The ability of the lung to return to almost normal function after a completely disabling lesion and the efficacy of a direct and accurate anastomosis of the bronchus to tracheal wall, we believe, have been adequately proven by this case.

In the diagnosis of these lesions, the most important procedure is a careful bronchoscopic examination; whether in the immediate or late period following the injury. The history of trauma and the signs of severe tension pneumothorax, hemoptysis or persistent lung collapse may lead to the suspicion of a ruptured bronchus, but the

^{29, 31, 32, 33, 36} From an historical standpoint, the first case of bronchial rupture to be identified was reported by Sheild³³ in 1889, whereas the first patient to be reported who survived this injury was presented by Krinitzki¹⁹ in 1927. Since that time, the number of cases reported in the literature

surest method of confirmation short of thoracotomy is by endoscopic visualization. In a patient seen two years ago, a partial rupture of the right bronchus was readily seen on bronchoscopic examination during the immediate post-injury period, and in the patient reported, the pathologic process was evident at endoscopy. Bronchography has also been described as a method of delineating these lesions, but we have felt that its use was superfluous, and the introduction of the foreign material in the presence of respiratory distress might be dangerous, and therefore unjustified.

The question of the eventual fate of the bronchotracheal anastomosis cannot be determined at this time, but in our previous experience, we would expect evidence of at least beginning bronchial closure to be present at this point, and in our opinion, this has not occurred. We also expect a gradual improvement in the ventilatory function and oxygen uptake of the right lung in keeping with the progressive improvement which we have noted following decortication and pulmonary resection in previous patients. The patient will be followed to ascertain these points in the future.

SUMMARY

1. An unusual case of complete rupture division of the right bronchus, from external trauma to the chest, is described.

2. The definitive surgical treatment of the patient 46 days following injury by thoracotomy, decortication of the lung, aspiration of the occluded bronchus and anastomosis of the bronchus to the trachea is presented.

3. The satisfactory recovery of the patient is reviewed and study of the salvaged lung by bronchoscopy, bronchography and ventilatory function tests reported.

4. The most useful adjunct in the diagnosis of bronchial rupture is bronchoscopic examination, and the treatment of choice is

surgical repair of the injury at the earliest and most advantageous time.

BIBLIOGRAPHY

- 1 Barford, J. L.: A Case of Extensive Rupture of the Trachea with Complete Detachment of the Left Bronchus without External Injury. *Lancet*, 2: 1509, 1906.
- 2 Bowen, W. H., and N. May: A Case of Double Depressed Fracture of the Skull and Pneumothorax. *Lancet*, 2: 694, 1907.
- 3 Burbank, C. B., W. H. Falor and H. W. Jones: Three Hundred Seventy-four Acute War Wounds of the Thorax. *Surgery*, 21: 730, 1947.
- 4 Clagett, O. T., J. H. Grindlay and H. J. Moersch: Resection of the Trachea. *Arch. Surg.*, 57: 253, 1948.
- 5 Clerf, L. H.: Rupture of the Main Bronchus from External Injury. *Surgery*, 7: 276, 1940.
- 6 Davis, H. A., W. B. Gordon, E. W. Hayes and M. T. Wasley: Effects Upon the Lung of Varying Periods of Temporary Occlusions of the Pulmonary Artery. *Arch. Surg.*, 64: 464, 1952.
- 7 Davis, H. A., J. P. O'Connor, G. J. Coloviras and D. L. Strawn: Homologous Transplantation of the Lung. *Arch. Surg.*, 64: 745, 1952.
- 8 Ehrlich, R. W., R. P. Meyer, C. B. Taylor, G. M. Hass and E. M. Miller: Reconstruction of the Tracheobronchial Tree with Resection of the Lung, Carina and Lower Trachea. *Surg., Gynec. & Obst.*, 94: 570, 1952.
- 9 Gebauer, P. W.: Plastic Reconstruction of Healed Tuberculous Bronchostenosis with Dermal Grafts. *J. Thoracic Surg.*, 19: 604, 1950.
- 10 -----: Pulmonary Surgical Salvage by Bronchial Resection. *Surg., Gynec. & Obst.*, 94: 347, 1952.
- 11 Griffith, J. L.: Fracture of the Bronchus. *Thorax*, 4: 105, 1949.
- 12 Grindlay, J. H., O. T. Clagett and H. J. Moersch: Experimental Surgery of the Trachea and Its Bifurcation; Preliminary Report. *Proc. Staff Meet., Mayo Clin.*, 24: 555, 1949.
- 13 Hodes, P. J., J. Johnson and J. P. Atkins: Traumatic Bronchial Rupture with Occlusion. *Am. J. Roentgenol.*, 60: 448, 1948.
- 14 Holinger, P. H., A. R. Zoss and K. C. Johnston: Rupture of Bronchus Due to External Chest Trauma; Report of Three Cases with Recovery. *Laryngoscope*, 58: 817, 1948.
- 15 Jackson, T. L., P. Lefkin, W. Tuttle and F. Hampton: An Experimental Study in

- Bronchial Anastomosis. *J. Thoracic Surg.*, **18**: 630, 1949.
- ¹⁶ Jones, F. W., and P. P. Vinson: Nonfatal Rupture of Left Main Bronchus from External Trauma. *Surgery*, **5**: 228, 1939.
- ¹⁷ King, C.: Rupture of the Right Bronchus by Injury. *Brit. M. J.*, **1**: 1238, 1907.
- ¹⁸ Kinsella, T. J., and L. W. Johnsrud: Traumatic Rupture of the Bronchus. *J. Thoracic Surg.*, **16**: 571, 1947.
- ¹⁹ Krinitzki, S. I.: Zur Kasuistik einer vollständigen Zerreiung des rechten Luftrherrastes. *Arch. f. Path. Anat. u. Physiol.*, **266**: 815, 1927.
- ²⁰ Leckie, A. S. B.: Traumatic Rupture of the Right Bronchus from Intrathoracic Pressure. *Brit. M. J.*, **1**: 486, 1912.
- ²¹ Lffler, W., and F. Nager: Ueber Traumatische Bronchostenose und ihre Behandlung. *Schweiz. med. Wehnschr.*, **71**: 293, 1941.
- ²² Mackler, S. A.: Experience with Thoracic and Thoracoabdominal Wounds in an Evacuation Hospital. *J. Thoracic Surg.*, **16**: 538, 1947.
- ²³ Mathey, J., and G. Oustrieres: End-to-end Bronchial Anastomosis after Accidental Division of the Stem Bronchus. *Thorax*, **6**: 71, 1951.
- ²⁴ Meade, R. H., and J. B. Graham: Rupture of a Primary Bronchus from Compression of the Thorax without Bone Injury. *Ann. Surg.*, **92**: 154, 1930.
- ²⁵ Meyer, R. P., R. W. Ehrlich, C. B. Taylor, G. M. Hass and J. M. Dorsey: Experimental Bronchotracheal Anastomosis. *Arch. Surg.*, **62**: 753, 1951.
- ²⁶ Nicod, J. L., and E. Ureck: Rupture Gurie D'Une Bronche Principale. *Ann. d'anat. path.*, **13**: 485, 1936.
- ²⁷ Patrick, J.: Rupture of Left Bronchus from Trachea. *Brit. M. J.*, **2**: 359, 1917.
- ²⁸ Paulson, D. L.: Traumatic Bronchial Rupture with Plastic Repair. *J. Thoracic Surg.*, **22**: 636, 1951.
- ²⁹ Rienhoff, Wm. F.: Readjustments in the Thoracic Cage and Its Contents Following Total and Partial Pneumonec-tomy. *South. M. J.*, **29**: 445, 1936.
- ³⁰ Sanger, P. W.: Evacuation Hospital Experiences with War Wounds and Injuries of the Chest. *Ann. Surg.*, **122**: 147, 1945.
- ³¹ Scannell, J. G.: Rupture of the Bronchus Following Closed Injury to the Chest. *Ann. Surg.*, **133**: 127, 1951.
- ³² Schnberg, S.: Bronchial Rupturen bei Thoraxkompression. *Klin. Wehnschr.*, **49**: 2218, 1912.
- ³³ Sheild, M.: Complete Rupture of Bronchus. *Lancet*, **1**: 577, 1889.
- ³⁴ Tannenberg, J., and M. Pinner: Atelectasis and Bronchiectasis. *J. Thoracic Surg.*, **11**: 571, 1942.
- ³⁵ Tuttle, W.: Discussion of paper reference 15 above. *J. Thoracic Surg.*, **18**: 641, 1949.
- ³⁶ Tyson, M. D., and J. S. Lyle: Traumatic Obstruction of a Main Bronchus. *New England J. Med.*, **226**: 192, 1942.