

COLECTOMY IN THE TREATMENT OF MASSIVE MELENA SECONDARY TO DIVERTICULOSIS

REPORT OF A CASE*

WILLIAM R. CATE, JR., M.D.

NASHVILLE, TENNESSEE

FROM THE DEPARTMENT OF SURGERY, VANDERBILT UNIVERSITY SCHOOL OF MEDICINE, NASHVILLE, TENNESSEE

RECTAL BLEEDING HAS become recognized in recent years as a fairly common symptom of diverticulitis of the colon. It is more difficult to ascertain its incidence secondary to otherwise uncomplicated diverticulosis.

Ochsner and Barger² report an incidence of rectal bleeding in eight (5 per cent) of 151 cases of diverticulosis of the colon and in five (22 per cent) of 23 cases of diverticulitis. Willard and Bockus⁶ found no difference in the incidence of bleeding. It was noted in 18 per cent of their patients both with diverticulitis and with simple diverticulosis.

There have been few published reports of massive melena secondary to either. Conservative measures have sufficed in all recorded cases. We were recently confronted by the problem of a patient with protracted severe hemorrhage from the rectum and diverticulosis involving the cecum and colon to the mid-sigmoid region. No other etiological factor was demonstrable. A radical subtotal colectomy with ileosigmoidostomy was performed with successful outcome.

CASE REPORT

O. S. (219611), a 40-year-old colored female, was admitted to the medical service of the Vanderbilt University Hospital on May 11, 1952. She gave no history of significant gastro-intestinal complaints until 4½ hours prior to admission. At that time she noted the onset of cramping abdominal

discomfort which was relieved by the passage of a stool consisting almost entirely of dark red blood. This sequence of events was repeated 3 or 4 times before admission to the hospital. During this period the patient noted the onset of weakness and palpitation. Except for a history of treatment for hypertension 2 to 3 years prior to admission, the systems review was not contributory. The patient was moderately obese with cool, moist extremities. Blood pressure was 192/120; pulse was 120; and the temperature was 99.2° F. There was slight abdominal distension with hyperperistalsis. No masses were palpable. Rectal examination was negative except for dark red blood on the examining finger.

The hemoglobin was 12.0, packed cell volume 38. The prothrombin time was 13.0 seconds, control 11.6 seconds. Bleeding time was 2 minutes, clotting time (Lee-White) 5 minutes and clot retraction adequate. A sickle cell preparation revealed no sickling. Gastric analysis revealed no free acid and no blood. A proctoscopic examination was within normal limits.

The patient received only 500 ml. whole blood during the first 72 hours following admission, despite a gradually declining packed cell volume. However, on a regimen of sedation and a bland diet, she had apparently stabilized fairly well and was passing only 1 or 2 bloody stools per day.

On the morning of the fourth hospital day the patient again began to pass numerous dark stools. The packed cell volume was 28 at that time. Despite the administration of 2500 ml. whole blood, the patient became critically ill with blood pressure 120/80 and a rapid, thready pulse. Because of tenderness which had developed in the right lower quadrant with a questionable palpable mass, it was felt that the hemorrhage was likely from the cecum or ascending colon. Roentgenogram examination had not been felt advisable previously, but due to the urgency of the situation, an emergency barium enema was performed. Mul-

* Submitted for publication November, 1952.

COLECTOMY IN TREATMENT OF MASSIVE MELENA

tiple diverticula of the cecum and colon were noted, being most concentrated in the descending colon (Fig. 1). As well as could be determined under difficult circumstances, the distal sigmoid colon appeared to be spared. Other than the diverticula, no significant findings were noted.

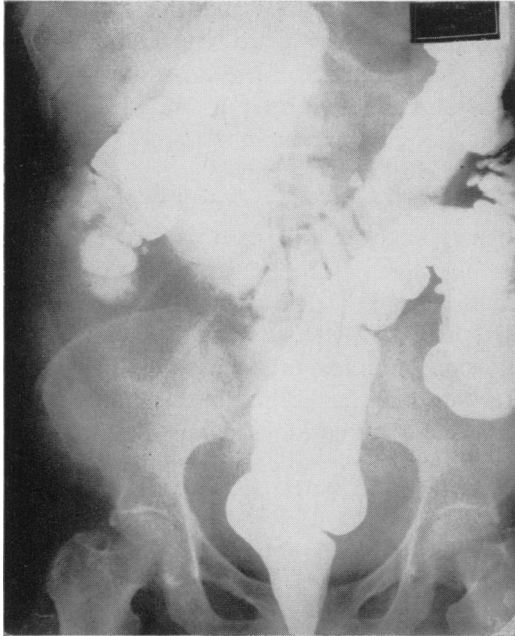


FIG. 1.—Barium enema revealing multiple diverticula. None are visualized in the distal sigmoid colon.

The patient was transferred to the surgical service and laparotomy through a right rectus muscle splitting incision performed. Careful exploration failed to reveal a cause for the bleeding other than the multiple diverticula. There was no evidence of previous episodes of diverticulitis. The entire colon and cecum were filled with blood, none being present in the small intestine. The cecum was opened along the anterior tenia and no bleeding point identified in the cecum or ascending colon. It was not felt advisable at the time to subject the patient to further operative manipulations. She was returned to the floor in fair condition, having received 1500 ml. whole blood during the procedure.

The patient continued to pass bloody stools repeatedly. Her packed cell volume declined from 41.5 to 34 over a period of 12 hours after operation despite 2000 ml. whole blood. She became semicomatose. It seemed apparent that there was going to be no cessation of bleeding and that the patient could not survive without operative intervention.

Since no isolated bleeding point could be localized, it was reasoned that resection of the colon from the cecum to the lower sigmoid region would be necessary. It was felt that the distal sigmoid could be spared, since the blood passed per rectum had consistently been dark and no diverticula had been demonstrated in that segment.

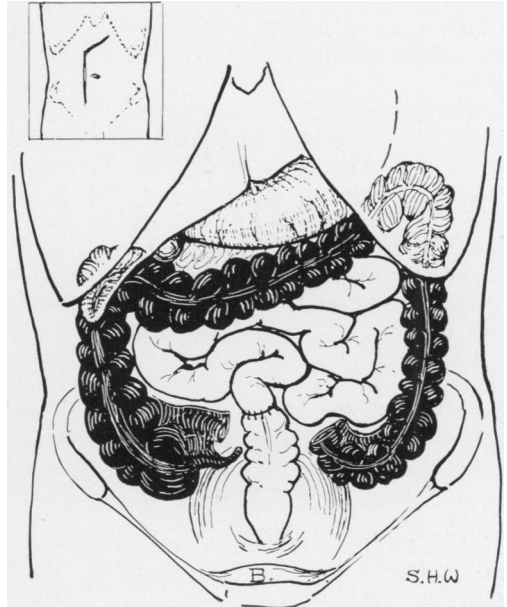


FIG. 2.—Diagram of the definitive operative procedure. The heavily shaded area depicts the extent of resection.

Approximately 18 hours after the initial procedure, the patient was returned to the operating room. The abdomen was reopened through the original incision with an oblique component extending into the left upper quadrant (inset Fig. 2). The distal 2 to 3 inches of ileum and the colon from the cecum to the distal sigmoid were resected (Fig. 2). An end-to-end ileosigmoidostomy was performed with an inner layer of interrupted 000 chromic catgut and an outer layer of inverting seromuscular 0000 silk. Stay sutures of braided silk were used to supplement the abdominal wound closure. Fifteen hundred ml. of blood were administered during the procedure.

Examination of the specimen revealed multiple diverticula throughout, most concentrated in the descending colon. There was clotted blood in many of the diverticula. No other lesions were noted. It was not possible to determine the exact region from which the hemorrhage had occurred.

The patient was maintained postoperatively on Wangensteen suction per Levin tube, penicillin and

streptomycin, and parenteral fluids. Although the packed cell volume gradually declined over the next 48 hours from 41 to 34, only a single grossly bloody stool was passed, on the second postoperative day. A stool was negative for occult blood on the eighth postoperative day, with no positive specimen subsequently. Five hundred ml. whole blood was administered on the second and third postoperative days. The packed cell volume had stabilized at 40 by the sixth postoperative day and was 40 when last checked on September 2, 1952.

The Levin tube was removed on the fourth postoperative day and progressive feeding instituted. It was necessary to digitalize the patient at that time because of progressive dyspnea and basal râles. Digitalization was discontinued 8 days later without further symptoms of cardiac failure. A partial wound disruption secondary to infection was closed on the thirteenth postoperative day.

The patient has had on the average 2 bowel movements a day, never more than 3. She returned to work 3 months after her operation and, with the exception of a ventral hernia, remains well.

COMMENT

We have been able to discover only one other similar case of diverticulosis in which laparotomy was performed for the purpose of controlling blood loss. This patient was one of a group of eight reported by Stone⁴ and included in a report on massive melena of obscure origin. Diverticulosis was the only lesion noted at the time of exploration. No definitive surgical procedure was performed, and the patient subsequently recovered with conservative treatment alone. Only two of the eight patients gave a history of symptoms suggestive of diverticulitis.

Rosser³ found that 12 of 40 patients with acute and chronic diverticulitis had noted rectal bleeding; four in large amounts. All responded to conservative measures. Hayes¹ reports two cases of massive melena secondary to diverticulitis. Operation was necessary in neither.

Twelve cases of melena secondary to diverticular disease of the colon are recorded by Turnbull.⁵ Three of the patients died as a result of exacerbation of coronary artery disease. Five with pre-existing cardiovascular disease became cardiac invalids. The author felt that this was at least in part a result of blood loss. One was subsequently found to have an associated carcinoma for which resection was performed. The remaining three recovered without complications.

That diverticulosis was the cause of hemorrhage in the case reported in this communication or in any of those previously reported, is not without question. Other unassociated lesions such as mucosal erosions and hemangiomas may have been responsible. In addition, this patient had hypertensive cardiovascular disease. The treatment was radical. It appears in this case that it was lifesaving.

SUMMARY

A case report of massive melena secondary to diverticulosis involving the cecum and colon to the mid-sigmoid region is recorded. A radical subtotal colectomy with ileosigmoidostomy was performed with successful outcome.

BIBLIOGRAPHY

- ¹ Hayes, H. T.: Quoted by Rosser.³
- ² Ochsner, H. C., and J. A. Bargon: Diverticulosis of the Large Intestine. An Evaluation of Historical and Personal Observations. *Ann. Int. Med.*, **9**: 282, 1935.
- ³ Rosser, C.: Surgical Management of Diverticulitis. *South. M. J.*, **32**: 1203, 1939.
- ⁴ Stone, H. B.: Large Melena of Obscure Origin. *Ann. Surg.*, **120**: 582, 1944.
- ⁵ Turnbull, G. C.: Massive Hemorrhage from Diverticula of the Colon. *Quart. Bull., Northwestern Univ. M. School*, **22**: 292, 1948.
- ⁶ Willard, J. H., and H. L. Bockus: Clinical and Therapeutic Status of Cases of Colonic Diverticulosis Seen in Office Practice. *Am. J. Digest. Dis. & Nutrition*, **3**: 580, 1936.