

# TRAUMATIC RETROPERITONEAL RUPTURE OF THE DUODENUM\*

LT. COL. ROBERT B. NEWELL, MC, U. S. A.,  
LT. COL. GEORGE R. ROSENBAUM, MC, U. S. A.,  
AND 1ST LT. NOLAND M. CANTER, JR., MC, U. S. A.

FROM THE U. S. ARMY HOSPITAL, FORT LEE, VIRGINIA

RETROPERITONEAL RUPTURE of the duodenum is so rarely encountered that it may be easily overlooked, with possible disastrous results. This case is presented as a matter of interest and to point out the diagnostic value of repeated roentgenograms. Forty-six cases of retroperitoneal rupture of the duodenum produced by blunt force were reported in the literature prior to 1916. Of this group of cases, 37 were explored but the lesion was missed at operation in 14 instances. Only five cases survived. From 1916 to 1943, 53 cases were reported, and of these 27 survived. The lesion was not found at operation in seven of these patients. The mortality of the first group was 89 per cent and in the second group, 49 per cent. Four additional cases were reported in the literature in the period from 1944 to 1949.<sup>1</sup> All of these patients survived.

## CASE REPORT

A white soldier, age 20, was injured when the car which he was driving struck the concrete abutment of a bridge on March 3, 1950. He was first admitted to a civilian hospital shortly after the injury, where he was treated for a severe laceration of the left supra-orbital region and was observed for possible intra-abdominal injury. The patient did not complain of any particular abdominal pain at this time.

Examination of the abdomen revealed slight spasm of the upper right rectus muscle. No tenderness was noted and peristalsis was reported as being normal. Roentgenograms of the abdomen, with the patient in the supine and erect positions, made 2 hours after the injury, showed nothing of significance. The patient was then transferred to the U. S. Army Hospital, Fort Lee, Va., for further treatment and observation. He was admitted to this installation approximately 12 hours after

the original injury. On admission he was found to be conscious and well oriented. He did complain of dull pain deep in the epigastrium. He stated that he had voided freely following the accident and had also passed flatus by rectum. Examination of the abdomen at this time revealed a suggestive mass just beneath the costal margin in the right nipple line. There was also moderate spasm and slight tenderness in the right upper quadrant. There was no distention and peristalsis was considered within the limits of normal. Temperature at this time was 101° F, pulse 100, and respiration 24. Blood and urine examinations were within the limits of normal. Roentgenograms of the abdomen in the supine and erect positions (Fig. 1), made 14 hours after the accident, showed free air retroperitoneally, most marked about the right kidney and psoas shadows. There was free air extending along both psoas shadows up to the level of the diaphragm. No free air was noted under the domes of the diaphragm. A diagnosis of retroperitoneal perforation of the duodenum was made on the basis of the roentgenogram. Examination of the patient's abdomen after the completion of the roentgenogram revealed that the abdomen had become almost board-like and that it was markedly distended. He was prepared for operation at once.

Under spinal anesthesia a right Kocher incision was made, dividing the right rectus and muscles of the abdominal wall laterally to a distance of 2.5 cm. beyond the insertion of the transversalis muscle. Immediately upon opening the peritoneum, a small amount of brown fluid was encountered and a crepitant retroperitoneal mass was noted. The posterior peritoneum was discolored and bile stained. Most of the landmarks could not be distinguished due to the displacement of the posterior peritoneum by the previously mentioned mass. The gallbladder was normal. The right kidney could be palpated through the crepitant mass. An incision was made in the posterior peritoneum at the lateral border of the duodenum and the duodenum reflected medially to expose the posterior surface. A 3.0 cm. transverse tear was found on the posterior surface of the second portion of the duodenum. The ampulla of Vater was visualized immediately beneath the medial edge

\* Submitted for publication September, 1950.

of the tear. The rent in the wall of the duodenum was repaired, using a continuous Connell suture of 00 chromic catgut to invert and approximate the mucosa. It was reinforced with interrupted horizontal mattress sutures of No. 40 cotton. A drain was placed in the right retroperitoneal space and

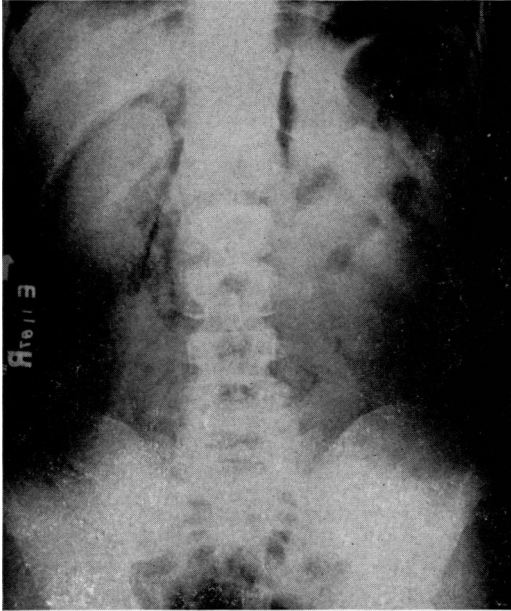


FIG. 1.—Roentgenogram of the abdomen in erect positions taken 14 hours after injury, showing marked retroperitoneal air around right kidney and both psoas shadows.

brought out through a stab wound in the flank. The incision was then closed in layers with interrupted sutures of cotton and the skin with Michel skin clips. The patient was returned to the ward in good condition. He was given 500 cc. of whole blood immediately after the operation. A Levin tube was passed into the stomach and continuous gastric suction instituted. There was very little postoperative reaction. Nutrition was maintained with parenteral fluids and intravenous protein hydrolysate. On the fourth day the abdomen was soft and the patient was passing flatus. The Levin tube was removed on the fifth day and the patient

was given small amounts of liquids by mouth. On the sixth day skin clips were removed and the incision was found to be well healed. It was noted, however, that there was copious bright yellow drainage mixed with gas bubbles exuding from the stab wound in the flank. A diagnosis of duodenal fistula was made after methylene blue, given by mouth, appeared in 30 minutes in the drainage from the stab wound. Continuous gastric suction was again instituted and in 3 days the drainage had ceased. On the tenth day the Levin tube was clamped off and Lipiodol was given by mouth. Under the fluoroscope it was seen to pass into the small intestine. The Levin tube was removed and the patient's convalescence was uneventful thereafter. The patient was discharged on a convalescent furlough for 30 days and upon his return he was found to be in good condition. On April 24, 1950, an upper gastro-intestinal roentgen series was done and no unusual findings were noted. The proximal duodenum was not dilated and no narrowing was noted at the site of the rupture. The patient was discharged to light duty on May 3, 1950. A note from him on August 15, 1950, reported that he was doing heavy field duty with his organization.

#### SUMMARY

A case of traumatic retroperitoneal rupture of the duodenum is presented. It was recognized by suspecting the possibility of such a lesion and definitely confirmed by roentgenographic study.

#### BIBLIOGRAPHY

- <sup>1</sup> Maingot, R.: *Abdominal Operations*. Appleton-Century-Crafts, 2d Ed. pg. 115.
- <sup>2</sup> Siler, V. E.: *Management of Rupture of the Duodenum due to Violence*. *Am. J. Surg.*, **78**: 1949.
- <sup>3</sup> Jacobs, E. A., G. J. Culver and E. C. Koenig: *Roentgenologic Aspects of Retroperitoneal Perforations of Duodenum*. *Radiology*, **43**: 563, 1944.
- <sup>4</sup> Koenig, E. C., and G. J. Culver: *Retroperitoneal Perforation of the Duodenum*. *Radiology*, **48**: 164, 1947.