

TRAPEZIUS PARALYSIS FOLLOWING MINOR SURGICAL PROCEDURES IN THE POSTERIOR CERVICAL TRIANGLE

RESULTS FOLLOWING CRANIAL NERVE SUTURE*

BARNES WOODHALL, M.D.

DURHAM, NORTH CAROLINA

FROM THE NEUROSURGICAL DIVISION, DUKE HOSPITAL AND MEDICAL SCHOOL, DURHAM

PARALYSIS OF THE TRAPEZIUS MUSCLE secondary to war wounds involving the accessory nerve has been widely recognized. It has formed a part of various neurologic syndromes involving the last four cranial nerves that have received such descriptive terms as "syndrome of the posterior retroparotid space" (Villaret) and "syndrome of the posterior lacerated foramen" (Vernet) and a number of others.³ An isolated trapezius paralysis may occur in war wounds when the accessory nerve is implicated in its more distal course.⁵ There is also a considerable amount of information concerning the disability from trapezius paralysis that has been derived from the neurosurgical procedure of spinal accessory-facial nerve anastomosis, used for the restoration of facial musculature function.^{1, 2, 9} Sufficient emphasis has not been directed to the observation that the superficial course of the accessory nerve in the posterior cervical triangle makes it peculiarly susceptible to injury during operative interventions in this portion of the cervical axis.

Eight cases of accidental surgical injury to the accessory nerve have been studied during the past 14 years and the typical clinical picture may be introduced by the case history of a single patient.

W. A. P., Duke Hospital No. A 31232, a high-way engineer and an officer in the National Guard, was admitted on December 18, 1939. For some years he had noted a small cyst in the back of his neck on the right side. Three months before admission a physician friend of his had removed this mass under local anesthesia and had termed it a sebaceous cyst. Immediately after the procedure the patient became aware of diffuse shoulder girdle weakness, inability to abduct his right arm above 90 degrees and an area of numbness in the right occipital scalp (Fig. 1). Three to four weeks later, atrophy appeared in the right shoulder musculature and progressed. He was unable to carry out a regulation Army salute and was faced with an early call to active duty which he desired. No pain was apparent but a pulling sensation was noticeable in the incisional area upon excessive arm motion.

The neurologic examination showed a diagonal operative incision 2 cm. in length in the posterior cervical triangle half way between the posterior border of the sternomastoid muscle and an atrophic superior border of the trapezius muscle. Beneath this was an oval area of tissue induration. There was atrophy of the upper third of the right trapezius muscle, weakness in elevation of the right shoulder girdle and loss of abduction of the right arm above 90 degrees. There was an oval area of hypesthesia and hypalgesia in the right occipital area, corresponding to the sensory distribution of the lesser occipital nerve.

On December 19, 1939, the accessory nerve was found divided. A small proximal neuroma and a distal glioma were resected, the nerve segments were mobilized and an end-to-end anastomosis was carried out with fine ophthalmic silk. Cervical plexus fibers forming the lesser occipital nerve were adherent to the point of injury but were in continuity and were dissected free.

On August 30, 1940, there was full abduction of the arm using the reinnervated trapezius muscle

* Read before the American Surgical Association, White Sulphur Springs, W. Va., April 16, 1952.

and the residual muscle atrophy in the upper third of the muscle could be barely seen. The sensory loss had improved. He was subsequently able to pass his induction examination and carried on full military duty.

The clinical histories of the remaining seven patients were essentially identical to this prototype. In four, the nerve injury occurred following lymph node biopsy; in three, following removal of a tumor which was called a cyst. All patients complained of generalized shoulder girdle and arm weakness, inability to abduct the affected arm above 90 degrees and some type of subjective sensory disturbance. This complaint varied from that of a pulling sensation in the region of the operative scar in one patient to generalized aching in the arm and shoulder in four. One patient noted extension of shoulder pain with tingling paresthesia into all fingers. Two patients experienced no subjective distress. All patients observed progressive muscle wasting in the affected muscle. Three patients complained of numbness in the ipsilateral occipital area of the scalp, a complaint not previously recorded in the meager clinical literature that is devoted to this subject.

In all patients, atrophy of the superior third of the trapezius muscle could be demonstrated. There was sagging of the shoulder on the affected side and weakness in elevation of the shoulder. The body of the scapula was rotated downward and outward. The slightly flared inferior angle was thus closer to the spine than the superior scapular angle. This position was accentuated when the arm was moved laterally against resistance and posterior accentuation of the entire vertebral border of the scapula was likewise thus produced (Fig. 2). On forward flexion, the slight flaring of the inferior angle of the scapula disappeared, in contrast to the usual deformity of serratus anticus paralysis. True abduction of the arm above 90 degrees was not possible in any patient. There was variable

weakness of all muscle groups in the affected extremity, probably due to disuse, secondary to failure of shoulder girdle stabilization. In three patients, there was hypalgesia and hypesthesia over some part of the sensory dermatomes of C 2 and C 3.

The nerve injury was explored in seven patients. The remaining patient was seen in consultation as a potential medicolegal problem. In four, the accessory nerve was found divided and an end-to-end anastomosis was done; in three, electrical stimulation at operation disclosed intact nerve fibers involved in the indurated operative scar. In these, external neurolysis was performed. In two cases of lymph node biopsy, the operator had described hemorrhage and ligation of a small artery. In these two cases, the accessory nerve was found tented-up and constricted by the vessel ligation. The earliest procedure for nerve repair was carried out six weeks after injury, the latest 12 months. No essential difference in results was noted in the few cases available for comparison. Neuropathologic studies were made in the four cases of nerve division. The pathologic nerve segments or nerve ends measured 1.0 to 3.5 cm. One resection of an unusual stretch paralysis of nerve secondary to traction by ligature has been portrayed in some detail in another publication.⁸

The postoperative status of six patients has been followed, and in all of these the primary disability of loss of abduction of the arm has been regained without the use of supplementary muscle movements. One patient, treated in an Army hospital by nerve suture, has not been observed beyond a three-month postoperative period. The three patients in whom only neurolysis was done, after injury, regained full muscle mass. In the three patients in whom nerve suture was done, minimal residual muscle atrophy was visible and the characteristic lateral rotation of the scapula could be per-

PARALYSIS OF THE TRAPEZIUS MUSCLE

ceived by comparison with the normal side (Figs. 3 and 4).

In terms of functional regeneration as contrasted to anatomical reinnervation, a

dentist carries on his profession without disability, an Army officer does full duty, a housewife does her usual work, a carpenter is not handicapped, a water plant operator

FIG. 1

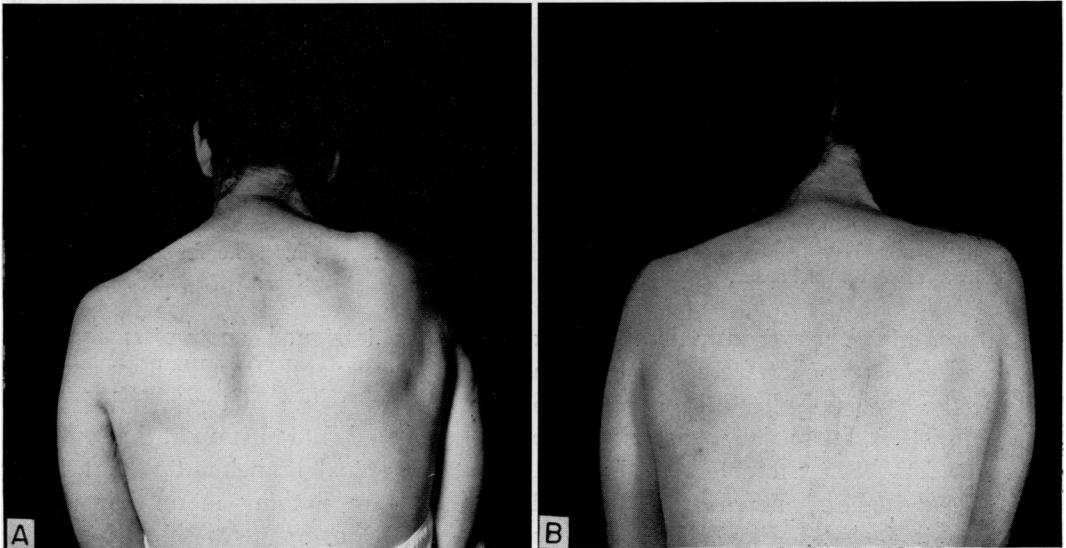
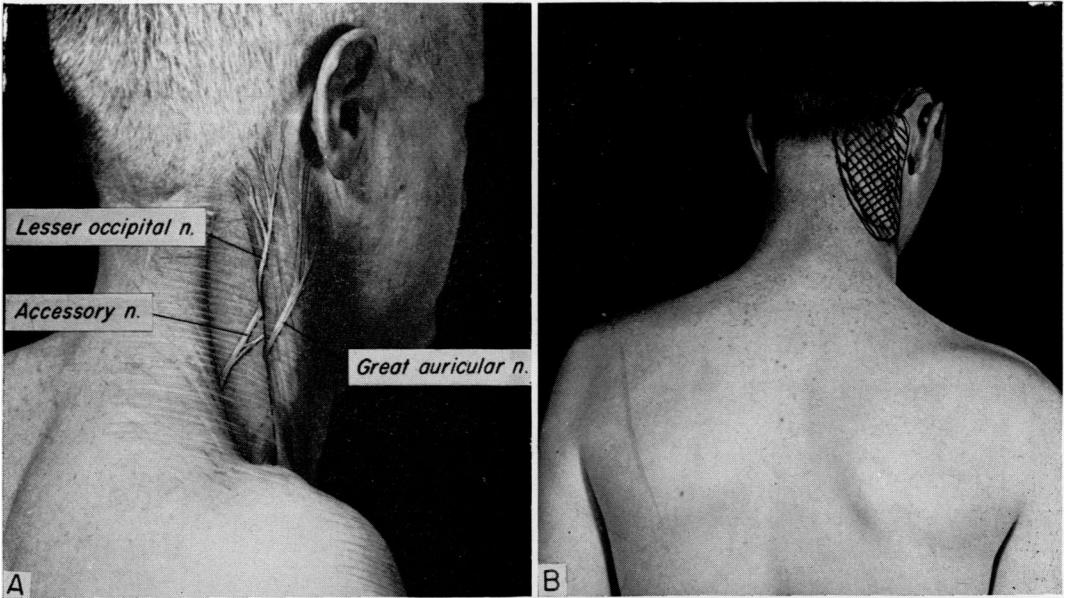


FIG. 2

FIG. 1.—(A) Relevant surgical anatomy of the posterior cervical triangle. (B) Hypalgesia, and in larger area, hypo-esthesia resulting from accidental injury to fibers of lesser occipital nerve. Note atrophy of superior third of right trapezius muscle secondary to accessory nerve division.

FIG. 2.—(A) Preoperative abduction against resistance. Note muscle atrophy, flaring of entire vertebral border of scapula and lateral deviation of scapula, right. (B) Postoperative, 28 months, abduction against resistance following cranial nerve suture. Note restoration of muscle mass, and relatively normal fixation of scapula to thoracic cage.

has no complaints and a gas station attendant denies any difficulty in his manual labors.

DISCUSSION

This neurologic complication of relatively minor surgical procedures may be more common than is evidenced by reports in the

sible injury to the accessory nerve during radical neck dissections for carcinoma and has advocated electrical isolation of the nerve segment.⁷

The double innervation of the sternomastoid and trapezius muscles from the spinal accessory nerve and the anterior rami of the upper cervical nerves is a circumstance

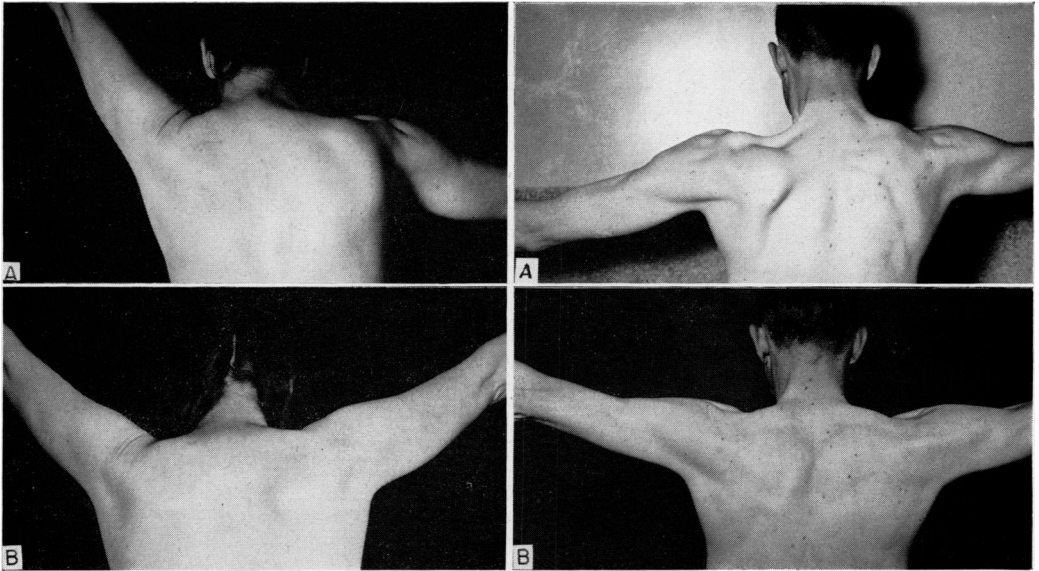


FIG. 3

FIG. 4

FIG. 3.—(A) Preoperative inability to abduct right arm above 90 degrees. Note muscle atrophy and scapular shift. (B) Postoperatively, 28 months, restoration of normal abduction of right arm. Note improvement in muscle mass and minimal residual flaring of vertebral border of scapula.

FIG. 4.—(A) Preoperative loss of abduction of right arm above 90 degrees. Note pronounced muscle atrophy and flaring of vertebral border of scapula. (B) Postoperative, ten months, restoration of muscle mass and ability to fully abduct arm. Note minimal residual flaring of vertebral border.

literature. Mead has recently described six cases of this type that were seen by him during the course of physical rehabilitation measures.¹⁰ A fairly full account of the disorder has been presented by Norden, who has advised early nerve exploration and suture if indicated.¹¹ Four of his 16 cases were treated by suture and two of these gave evidence of anatomical reinnervation. The earlier literature describes, for the most part, this injury as a complication of the removal of cervical tuberculosis lymphadenitis.^{4, 14} Lahey has also emphasized pos-

that has intrigued anatomists for many years. Strauss and Howell¹² have presented comparative neuro-anatomic and their own experimental data to support the contention that the spinal branches to the trapezius complex are nothing more than visceral (branchial) components that have shifted so as to follow a spinal pathway. They point out that the spinal accessory or eleventh cranial nerve is to be regarded as a derivative of the vagal complex and therefore of visceral origin. They support this conclusion by an analysis of the phylo-

geny of its motor nucleus, which has been derived from the dorsal motor nucleus of the tenth cranial nerve by caudo-ventral migration. Further evidence is found in the course of afferent fibers from the trapezius musculature into the tractus solitarius, a visceral sensory pathway. In general, the upper third of the trapezius muscle derives its major motor innervation from the accessory nerve, the lower two-thirds from the anterior rami of the upper cervical nerves. Overlap and variations from this static concept of muscle innervation are common and are probably the result of variable migration of its motor neurones.

Inman, Saunders and Abbott⁶ have studied the function of the shoulder joint through the use of comparative anatomy, a mechanical analysis of individual joint movement and myographic recordings. They point out that standard textbooks describe abduction of the shoulder joint as the sum of two independent joint movements, that of glenohumeral motion through the supraspinatus and deltoid muscles to an angle of 90 degrees, followed by elevation to 180 degrees by rotation of the scapula. These two motions can occur independently and glenohumeral movement to 90 degrees does occur with preliminary fixation of the scapula to the chest wall and with trapezius paralysis.⁵ In both cases, the power of abduction to this point is markedly reduced. They point out that elevation of the extremity, both in flexion and in abduction, at the glenohumeral joint is simultaneously accompanied by scapulo-thoracic movement. The part that the trapezius muscle plays in this rhythm of shoulder joint function has been analyzed by myographic studies.

The upper third of the trapezius, the levator scapulae and the upper digitations of the serratus anterior form a unit that passively supports the shoulder, actively elevates the shoulder and forms the upper component necessary for scapular rotation. Their function in an accessory respiratory

role will not be considered. To paraphrase their conclusions, all three muscles exhibit an action potential while at rest, evidence for the postural function of this group. With abduction, the superior third of the trapezius shows an action potential that rises in a linear form with some current undulation in the curve at 90 degrees of abduction where the supportive function of the muscle is changed to that of scapular rotation. The inferior third of the trapezius, with the lower four digitations of the serratus anterior, form the lower component of the scapular rotary force couple and the trapezius portion is most active in abduction. The middle third of the trapezius functionally seems to fix the scapula in its plane of motion during the abduction. When the trapezius muscle is paralyzed, the scapula fails of support and fixation and no fulcrum is available for the two components of the scapular force couple. True abduction then fails above 90 degrees, although, as pointed out by Sunderland,¹³ the substitutive power of the serratus anterior allows elevation of the arm in flexion. Myographic studies have also shown that the major component in the lower scapular couple in flexion, as compared to abduction, rests in the serratus anterior muscle. Loss of either component causes a distinct disability, as evinced by the clinical histories of these patients.

The superficial course of the accessory nerve in the posterior cervical triangle, and its susceptibility to injury, should interdict elective surgical procedures in this area. If surgical intervention is indicated, the location of the nerve should be identified by galvanic stimulation during the course of the dissection. In case of nerve division, useful function can be re-established by nerve suture.

BIBLIOGRAPHY

- 1 Coleman, C. C.: Results of Faciohypoglossal Anastomosis in the Treatment of Facial Paralysis. *Ann. Surg.*, **111**: 958, 1940.
- 2 Coleman, C. C., and J. C. Walker: Technic of Anastomosis of the Branches of the Facial

- Nerve with the Spinal Accessory for Facial Paralysis. *Ann. Surg.*, 131: 960, 1950.
- ³ Elkin, D. C., and B. Woodhall: Combined Vascular and Nerve Injuries of Warfare. *Ann. Surg.*, 119: 411, 1944.
 - ⁴ Hanford, J. M.: Surgical Excision of Tuberculous Lymph Nodes of the Neck. A Report on One Hundred and Thirty-one Patients with Follow-up Results. *S. Clin. North America*, 13: 301, 1933.
 - ⁵ Haymaker, W., and B. Woodhall: *Peripheral Nerve Injuries*, cit. p. 125. W. B. Saunders Company, pp. 227, Philadelphia, 1945.
 - ⁶ Inman, V. T., J. B. DeC. M. Saunders and L. C. Abbott: Observations on the Function of the Shoulder Joint. *J. Bone Surg.*, 26: 1, 1944.
 - ⁷ Lahey, F. H.: Radical Dissection of the Neck. *S. Clin. North America*, 29: 631, 1949.
 - ⁸ Lyons, W. R., and B. Woodhall: *Atlas of Peripheral Nerve Injuries*, cit. p. 201. W. B. Saunders Co., pp. 339, Philadelphia, 1949.
 - ⁹ McKenzie, F. G., and E. Alexander, Jr.: Restoration of Facial Function by Nerve Anastomosis. *Ann. Surg.*, 132: 411, 1950.
 - ¹⁰ Mead, S.: Posterior Triangle Operations and Trapezius Palsy. *Arch. Surg.*, 64: 752, 1952.
 - ¹¹ Norden, A.: Peripheral Injuries to the Spinal Accessory Nerve. *Acta. Chir. Scand.*, 94: 515, 1946.
 - ¹² Strauss, W. L., Jr., and A. B. Howell: The Spinal Accessory Nerve and Its Musculature. *Quart. Rev. Biol.*, 11: 387, 1936.
 - ¹³ Sunderland, S.: Voluntary Movements and the Deceptive Action of Muscles in Peripheral Nerve Injuries. *Australia, New Zealand J. Surg.*, 12: 160, 1944.
 - ¹⁴ Wulff, H. B.: The Treatment of Tuberculous Cervical Lymphoma: Late Results in 230 Cases Treated Partly Surgically and Partly Radiologically. *Acta. Chir. Scand.*, 84: 343, 1941.