

EXPERIMENTAL HYPERFUNCTION OF THE GASTRIC ANTRUM WITH ULCER FORMATION*

LESTER R. DRAGSTEDT, PH.D., M.D., HARRY A. OBERHELMAN, JR., M.D.,
AND CURTIS A. SMITH, M.D.

CHICAGO, ILLINOIS

FROM THE DEPARTMENT OF SURGERY OF THE UNIVERSITY OF CHICAGO

IN PREVIOUS STUDIES from this laboratory,¹ the antrum of the stomach was found to be the sole source of the gastric secretory excitant, gastrin, and to function as an endocrine organ. This evidence may be summarized as follows: When quantitative 24-hour collections of gastric secretion from Pavlov or Heidenhain pouch dogs were made, complete removal of the gastric antrum, with reconstruction of the continuity of the alimentary tract by anastomosing the body of the stomach with the side of the duodenum, produced a profound reduction in the amount of gastric juice secreted by the isolated pouch. Removal of one-half or even two-thirds of the antrum had little or no effect, but when the remaining remnant was removed, the usual profound reduction was secured. When the nervous phase of gastric secretion was absent as in Heidenhain pouch dogs, or following transthoracic complete vagotomy in Pavlov pouch dogs, subsequent removal of the antrum almost abolished the secretion of gastric juice from the isolated stomach pouch. These data suggest that the vagus nerves and the antrum of the stomach contain the key to the activity of the gastric glands, and since the effects of both can be easily removed by the surgeon, it is unnecessary to sacrifice the storage function of the body and fundus of

the stomach in order to reduce the secretion of gastric juice to a small fraction of its normal level. Further evidence concerning the function of the antrum of the stomach in its control of gastric secretion was obtained by transplantation experiments. When the antrum was removed from the stomach, converted into a closed pouch draining to the exterior by means of a fistula, the same reduction in gastric secretion by the body and fundus of the stomach was obtained as when the antrum was entirely removed. When this exteriorized antrum pouch was subsequently implanted into the side of the duodenum as a diverticulum, gastric secretion by the body and fundus of the stomach was restored to its normal amount. This experiment indicates that the antrum is functionless when isolated from contact with food or the usual content of the alimentary tract, and that it can function as a stimulator of gastric secretion even though deprived of its normal nervous connections. Transplantation of the antrum pouch into the colon as a diverticulum produced a surprising response. It was assumed that most food substances would have been absorbed from the colon content, and that when the antrum mucosa came in contact with the feces of the transverse colon, little or no stimulation would result. However, exactly the opposite was found. A persistent and excessive secretion of gastric juice by the body and fundus of the stomach occurred in all experiments when the antrum was transplanted into the colon. This persistent, excessive secretion of gastric juice induced in this manner has

* This work has been aided by grants from the Division of Research Grants and Fellowships of the National Institutes of Health, United States Public Health Service, and the Otho S. A. Sprague Memorial Institute. Read before the American Surgical Association, Washington, D. C., April 11, 1951.

provided a new tool for the production of experimental ulcers and for the study of the ulcer problem in general.

It is the purpose of the present communication to record the regular production of experimental gastric ulcers and gastroje-

upper and lower ends of the stomach closed. The vagus nerves were divided. A nylon plastic cannula was placed in the fundus of the stomach for the collection of gastric secretion. In such animals, only a very meager secretion of gastric juice is pro-

COMPARATIVE EFFECT OF ANTRUM TRANSPLANTATION INTO COLON AND DUODENUM

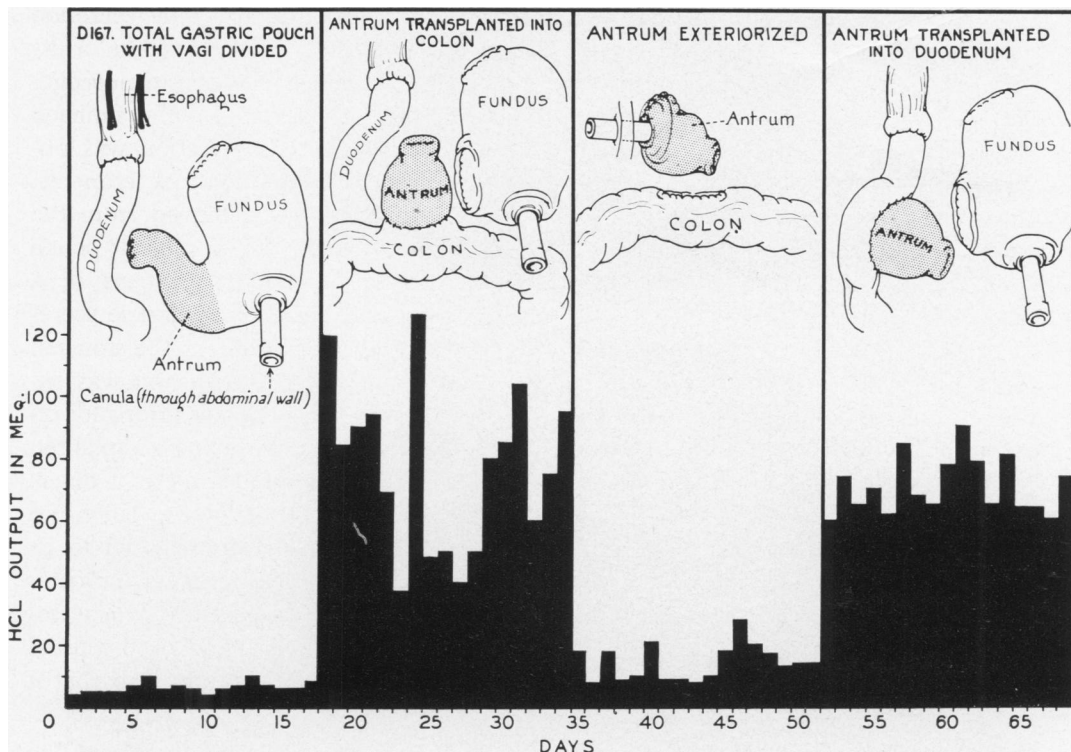


FIG. 1.—Diagrams illustrating the method of preparing the vagotomized total stomach pouch and subsequent transplantation of the antrum from the pouch into the colon and into the duodenum as a diverticulum. The 24-hour output of hydrochloric acid from the isolated stomach is illustrated graphically, and the profound increase in secretion produced by transplantation of the antrum into the colon or duodenum is very evident. Exteriorization of the antrum so that it does not come in contact with food produced almost as great a reduction in secretion as when the antrum was a part of the isolated stomach in the original experiment.

junal ulcers in dogs when a hypersecretion of gastric juice is induced by transplantation of the antrum of the stomach into the transverse colon.

EXPERIMENTAL PROCEDURE

Isolated total pouch dogs were prepared by transecting the stomach at the cardia and at the pylorus. The esophagus was anastomosed to the duodenum and the

produced in a 24-hour period, since both the nervous phase of gastric secretion and the antrum phase have been eliminated. It has been our experience with over 50 preparations of this type that ulcers do not develop spontaneously in the vagotomized isolated stomach. This has also been the experience of A. C. Ivy and his associates with this same preparation. When, however, the antrum was removed from the total pouch

and transplanted as a diverticulum into the colon, or into the side of the duodenum, a profound increase in gastric secretion by the isolated stomach occurred. One such experiment is illustrated in Figure 1. Approximately two months after the transplantation of the antrum into the colon, the animal

a vagotomized total stomach pouch 11 days after the antrum was removed from the pouch and transplanted as a diverticulum into the side of the transverse colon. Figure 5 illustrates a very large perforating ulcer which developed in a vagotomized total stomach pouch ten days after the antrum

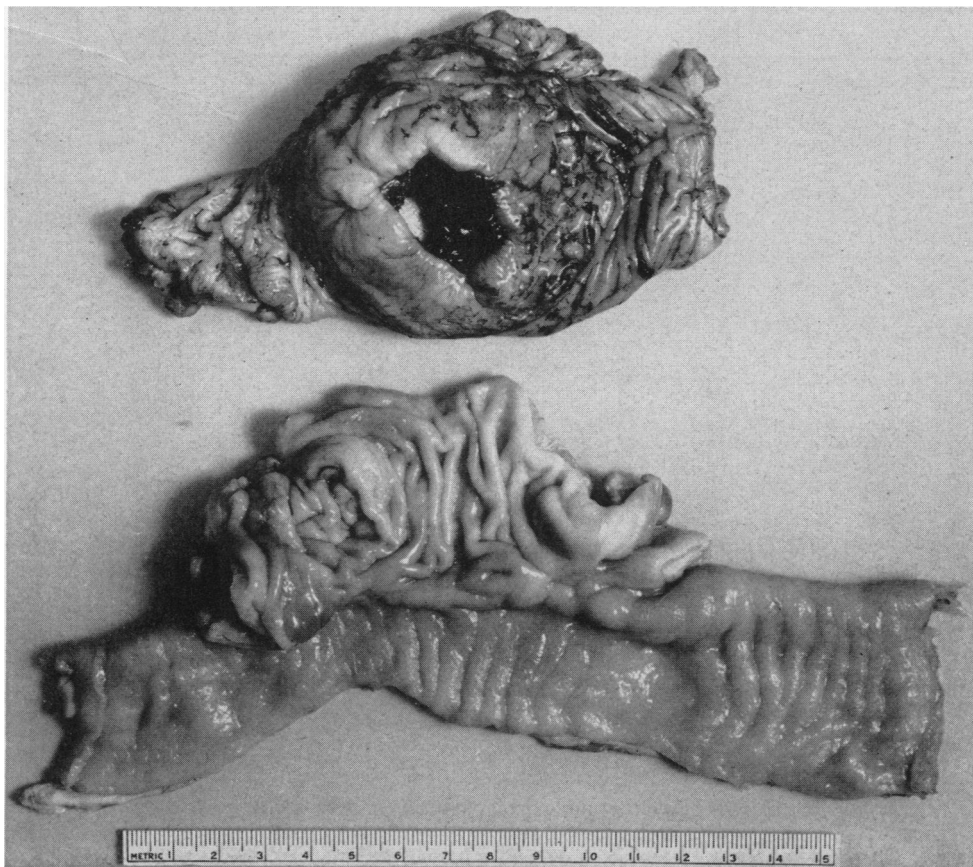

FIG. 2.—Photograph showing a very large perforating ulcer in the isolated stomach approximately 60 days after the transplantation of the antrum into the colon as illustrated in Figure 1. The bottom of the illustration shows the duodenum containing the antrum implant. No ulcers were ever found in the duodenum or colon adjacent to such antrum implants.

died of peritonitis, and at autopsy, a large, perforated gastric ulcer was found in the isolated stomach (Fig. 2). Figure 3 illustrates a perforating ulcer which developed in a vagotomized, isolated stomach pouch 11 days after the antrum was removed from the pouch and transplanted into the side of the duodenum as a diverticulum. Figure 4 illustrates a large ulcer which developed in

was removed from the isolated pouch and transplanted into the side of the transverse colon as a diverticulum.

In the experiments described above, the rapid formation of perforating ulcers in the vagotomized total stomach pouch in all probability are due to the profound increase in gastric secretion produced by removing the antrum from the isolated pouch and

transplanting it as a diverticulum into the duodenum, or into the colon. The fact that animals may survive for many months without the development of ulcers in a vagotomized isolated stomach pouch indicates that the mechanical effect of the cannula is not the cause of these lesions. Since neither food nor regurgitated duodenal secretions can enter the isolated stomach, the buffering effect of these substances is absent so

duodenum or colon, ulcers form with surprising rapidity.

In the following experiments, an attempt was made to determine if the hypersecretion of gastric juice induced by transplanting the antrum of the stomach into the colon could cause the development of an ulcer in the stomach in the presence of the neutralizing effect of food and the alkaline duodenal content. To secure data on this

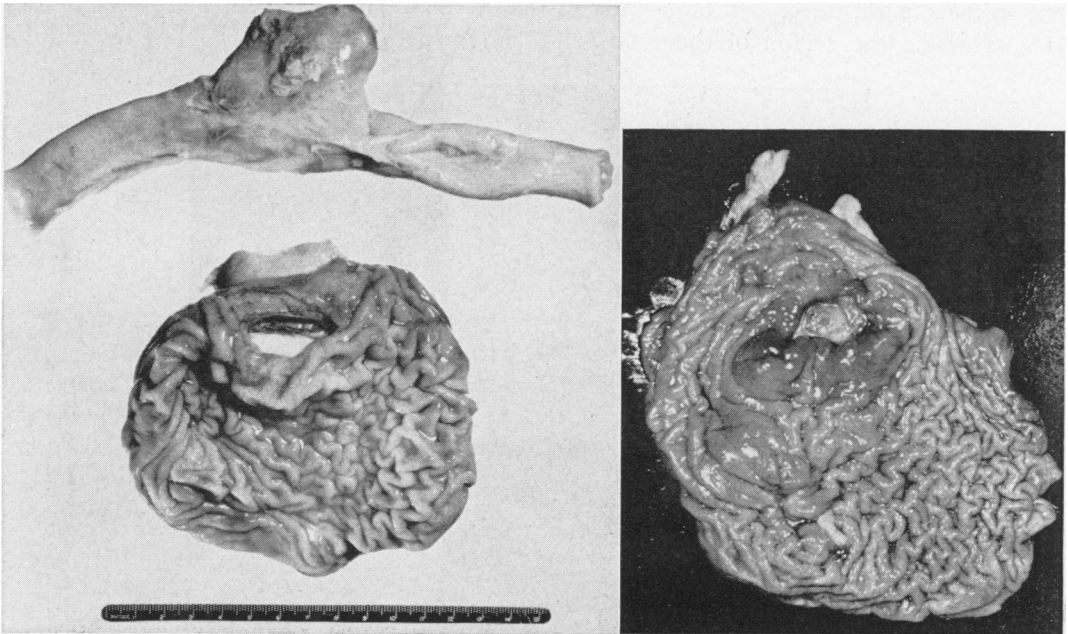


FIG. 3.—Photograph illustrating a perforated ulcer in a vagotomized total pouch following transplantation of the antrum into the duodenum. This ulcer developed and perforated 11 days after the transplantation.

FIG. 4.—Photograph illustrating a large ulcer which developed in a vagotomized total stomach pouch 11 days after the antrum was removed from the pouch and transplanted as a diverticulum into the side of the transverse colon.

that the situation is not comparable to that obtaining when the stomach has its normal relationships. However, even though this buffering effect of food and the duodenal secretions is absent from the vagotomized isolated total stomach pouch, ulcers do not develop in the presence of the meager gastric secretion characteristic of this type of preparation. When, however, such a stomach is stimulated to vigorous secretory activity by transplanting the antrum into the

point, 20 dogs were operated upon according to the method illustrated in the diagram in Figure 6. In ten of these animals, after the antrum had been transplanted into the side of the colon as a diverticulum, intestinal continuity was re-established by gastroduodenostomy utilizing the first portion of the duodenum, and in ten, intestinal continuity was re-established by gastrojejunostomy utilizing the first portion of the jejunum distal to the ligament of Treitz. Recovery from

the operation was uneventful, and for a time, all of the animals maintained good nutrition and their usual body weight on a diet of proprietary dog food supplemented by cooked horse meat and vitamin supplements. In from two to three weeks, however, the dogs in which continuity of the gastro-intestinal tract had been reconstructed by gastrojejunostomy began to refuse part of their food, and in several instances, the stools became bloody. Of these ten animals, eight developed large progressive ulcers in the region of the gastro-

condition until they were sacrificed. Only two of the ten dogs with gastroduodenostomy develops ulcers, and these were, on the whole, small as illustrated in Figure 11.

DISCUSSION

The regular development of gastric and stoma ulcers in experimental animals when the antrum of the stomach is transplanted into the colon is of interest for several reasons. In the first place, it provides a new experimental method for the production of ulcers that resemble clinical lesions, and the

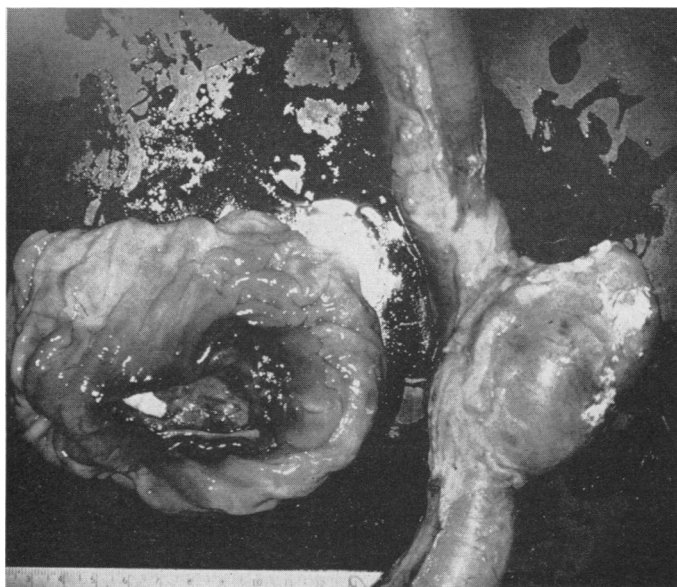

FIG. 5.—Photograph illustrating a large perforating ulcer which developed in a vagotomized total stomach pouch ten days after the antrum was removed from the pouch and transplanted into the side of the transverse colon.

terostomy stoma, some of which bled profusely, and some perforated, causing death by peritonitis. These ulcers appeared after an intervals of three to nine weeks, with the majority appearing within the first month after the operation. These ulcers are illustrated in Figures 7, 8, 9, and 10.

The animals in which intestinal continuity was re-established by anastomosis of the stomach with the first portion of the duodenum after the antrum had been transplanted into the colon remained in good

opportunity to explore the value of various prophylactic and therapeutic measures. The electrolyte balance of these animals remains normal, and their nutrition is excellent until the ulcer appears, when they lose appetite and avoid food, with consequent loss in body weight. In contrast, the animals with the Mann-Williamson preparation often become markedly cachectic, dehydrated, and demineralized before the ulcers appear, so there has been some question concerning the relative importance of

local factors and systemic alterations in the genesis of these lesions. While it is probable that these antrum hyperfunction ulcers and the histamine beeswax ulcers of Hay,

gastrojejunostomy when the first portion of the jejunum is employed for the anastomosis. In over a hundred such operations performed in this laboratory over the course

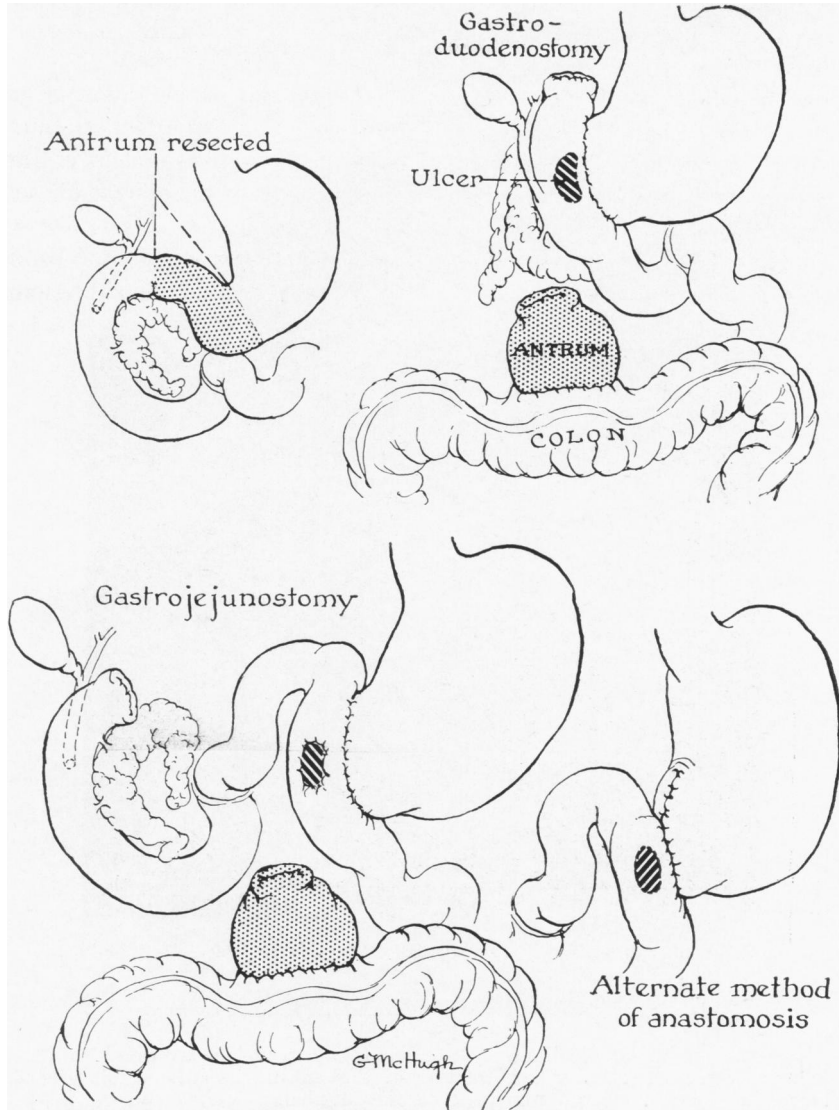


FIG. 6.—Diagrams illustrating the method of producing gastrojejunal and gastroduodenal ulcers by transplantation of the antrum of the stomach into the transverse colon.

Varco, Code and Wangensteen² are both dependent upon a hypersecretion of gastric juice, some objection has been voiced to the latter procedure in that it involves the administration of a foreign toxic agent. Stoma ulcers occur very rarely in normal dogs following either gastroduodenostomy or

of many years no stoma ulcer has been produced. Other investigators have had the same experience except under some special conditions, such as the production of a hematoma in the region of the anastomosis,³ an anastomosis utilizing a lower portion of the jejunum or ileum,⁴ or following the di-

FIG. 7





FIG. 8

FIG. 7.—Photograph illustrating a stoma ulcer which appeared in the jejunum three weeks after implantation of the antrum into the colon. The antrum and colon mucosa remained entirely normal.

FIG. 8.—Photograph illustrating multiple gastrojejunal ulcers, one of which perforated 20 days after the antrum was transplanted into the side of the colon.

version of the alkaline duodenal secretions from the region of the stoma.⁵ It is quite probable that it is the hypersecretion of gastric juice caused by the transplantation of the antrum into the colon that has resulted in the rapid production of large, penetrating stoma ulcers in these experiments.

These findings take on additional interest when we consider the circumstances

under which gastrojejunal ulcers commonly occur in man. It has been a rather uniform experience that gastrojejunal ulcers seldom develop following gastro-enterostomy or gastric resection for gastric ulcer or for carcinoma in the neighborhood of the pylorus. For the most part, stoma ulcer has been a complication of surgery for duodenal ulcer. It is now well established that

a hypersecretion of gastric juice both in the fasting stomach and in response to the ingestion of food occurs in most, if not all patients, with duodenal ulcers,¹ so that it seems most likely that the gastrojejunal ulcers which occur when gastro-enterostomy is done for this disease are brought about by the hypersecretion of gastric juice present, and that this is not eliminated by the gastro-enterostomy itself. The absence of gastro-

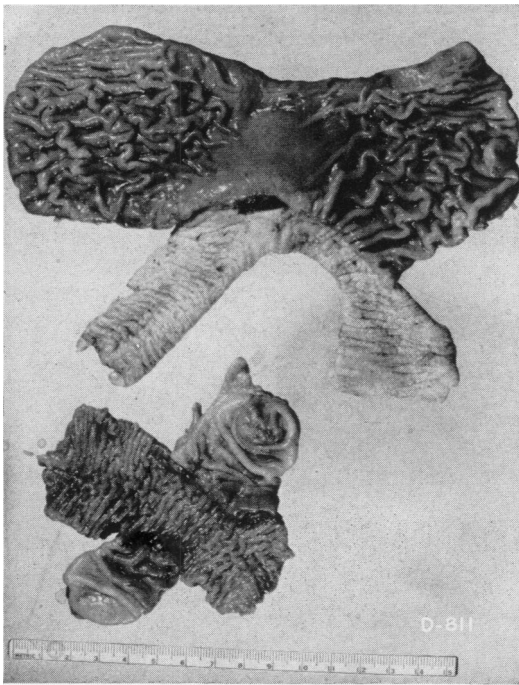


FIG. 9.—Photograph illustrating a gastrojejunal ulcer which developed in the suture line 21 days after transplantation of the antrum into the colon as a diverticulum.

jejunal ulcer following gastro-enterostomy for gastric ulcer or carcinoma of the pylorus may be attributed to the fact that gastric secretion is either normal or reduced in these patients.¹

If it be granted that a hyperfunction of the gastric antrum, such as can be produced in experimental animals by transplanting the antrum into the colon, can produce a hypersecretion and stoma ulcer in experimental animals, the question may be asked: "Is the hypersecretion present in duodenal ulcer patients due to hyperfunction of the

antrum, and is this the cause of the stoma ulcers which so commonly appear when gastro-enterostomy is done for this disease?" The possibility, of course, must be recognized, and patients should be carefully studied with this point of view in mind. It is not yet clear how transplantation of the antrum of the stomach into the colon produces a hyperfunction of this endocrine organ and whether any comparable situation occurs in human pathology. Contact of the antrum mucosa with feces would seem to occur only in the rare gastrojejuno-colic fistula, but whether an exaggerated secretion of gastric juice is produced by this complication is not known. The evidence that the hypersecretion of gastric juice in most duodenal ulcer patients is not of antrum origin and is not due to hyperactivity of this phase of gastric secretion may be stated as follows. Simple removal of the antrum, as was done when partial gastrectomy was first introduced for the treatment of duodenal ulcer, was found to be relatively ineffective in the prevention of gastrojejunal ulceration in these patients. The elimination of the nervous phase of gastric secretion by complete vagotomy has been found to abolish the hypersecretion of most, if not all, duodenal ulcer patients, and to guard against the subsequent development of gastrojejunal ulceration when gastro-enterostomy is performed as an ancillary operation.

The relatively few stoma ulcers that appeared in these experiments following gastroduodenostomy as compared with the high incidence and large size of the stoma ulcers that appeared following gastrojejuno-stomy would seem to indicate a much greater resistance of the duodenal as compared with the jejunal mucosa. These data are in harmony with the conclusions derived from other types of experiments, and suggest that gastroduodenostomy may be preferable to gastrojejuno-stomy as a drainage operation. The fact that ulcers appear in the totally isolated stomach pouch when a

hypersecretion of antrum origin is induced by transplanting the antrum into the colon indicates that the gastric mucosa itself will succumb to the digestant action of gastric juice when a hypersecretion is present. Previous injury to the gastric wall does not seem to be required. A number of years ago⁶ we reported the regular appearance of ulcers in the isolated stomach of dogs whose vagus innervation had been preserved, and for this reason secreted an abundant volume of gastric juice. Since no ulcers appear in the vagotomized totally isolated stomach, where both the nervous

into the colon so that a hypersecretion of the isolated stomach with ulcer formation occurs, these ulcers may be appropriately referred to as antrum hyperfunction, or "gastrin," ulcers.

SUMMARY

1. Transplantation of the antrum of the stomach in dogs into the side of the transverse colon as a diverticulum produces a profound increase in gastric secretion. This increase in gastric secretion is due to the excessive or long-continued production of a humoral agent, gastrin, since it occurs if all of the nervous connections between the

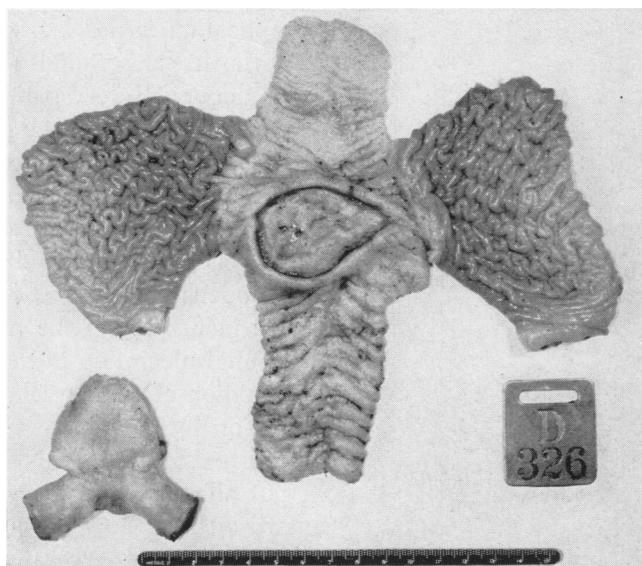


FIG. 10.—Photograph illustrating a large gastrojejunal ulcer which was found nine weeks after transplantation of the antrum into the colon as a diverticulum.

and the antrum phases of gastric secretion are excluded, we may conclude that the mere fact of isolation of the stomach from the gastro-intestinal tract, removal of the neutralizing effect of food or duodenal secretions, and trauma from the gastric cannula alone, are not the factors which produce the ulcers in these animals. When the vagus nerves are present, ulcers appear, and it would seem appropriate therefore to speak of these as neurogenic ulcers, and conversely, when the vagus nerves have been divided and the antrum transplanted

antrum and the stomach have been divided.

2. Transplantation of the antrum of the stomach into the colon with reconstruction of intestinal continuity by gastrojejunostomy resulted in the production of large stoma ulcers in 80 per cent of the animals operated upon.

3. Transplantation of the antrum of the stomach into the colon with reconstruction of intestinal continuity by gastroduodenostomy resulted in the formation of stoma ulcers in 20 per cent of the animals operated upon.

4. When the entire stomach is isolated from continuity with the intestinal tract, and its vagus innervation interrupted, a meager secretion of gastric juice is produced, and animals may be kept for many months, or indefinitely, without the production of ulcers in the isolated stomach. When the antrum is removed from the isolated stomach, however, and transplanted into the colon as a diverticulum, gastric secretion is markedly increased, and ulcers regularly develop in the isolated stomach, progress, cause hemorrhage, or perforate, in a relatively short time.

BIBLIOGRAPHY

- ¹ Dragstedt, L. R., E. R. Woodward, E. H. Storer, H. A. Oberhelman, Jr., and C. A. Smith: Quantitative Studies on the Mechanism of Gastric Secretion in Health and Disease. *Ann. Surg.*, **132**: 626, 1950. E. R. Woodward, R. R. Bigelow, and L. R. Dragstedt: Effect of Resection of Antrum of Stomach on Gastric Secretion in Pavlov Pouch Dogs. *Am. J. Physiol.*, **162**: 99, 1950.
- ² Hay, L. J., R. L. Varco, C. F. Code, and O. H. Wangensteen: The Experimental Production of Gastric and Duodenal Ulcers in Laboratory Animals by the Intramuscular Injection of Histamine in Beeswax. *Surg., Gynec. & Obst.*, **75**: 170, 1942.

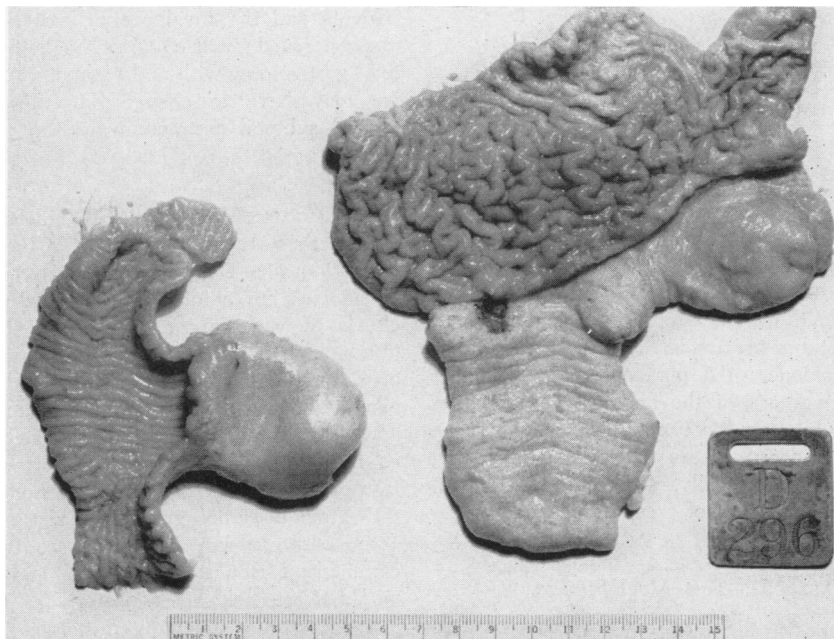


FIG. 11.—Photograph illustrating a small gastroduodenal ulcer which developed in the suture line 57 days after the antrum was transplanted into the colon and intestinal continuity re-established by an anastomosis between the stomach and the first part of the duodenum. This ulcer developed in close proximity to the bile and pancreatic ducts.

5. It is concluded that whereas a hypersecretion of gastric juice of antrum origin with resultant ulcer formation can be produced in experimental animals, evidence is not yet available to indicate that the hypersecretion of gastric juice characteristically found in duodenal ulcer patients is due to antrum hyperfunction, although this possibility should be kept in mind.

- ³ Montgomery, A. H.: Gastrojejunal Ulcer, An Experimental Study. *Arch. Surg.*, **6**: 136, 1923.
- ⁴ McMaster, A. H.: Effects of Diverting the Gastric Contents to the Lower Intestinal Levels. *Arch. Surg.*, **28**: 825, 1934.
- ⁵ Exalto, J.: Ulcus jejuni nach gastroenterostomie. *Mitt. a. d. Grenzgeb. d. Med. u. Chir.*, **23**: 13, 1911.
- ⁶ Dragstedt, L. R.: Some Physiological Principles Involved in the Surgical Treatment of Gastric and Duodenal Ulcer. *Ann. Surg.*, **102**: 563, 1935.