

# ANNALS OF SURGERY

VOL. 125

JANUARY, 1947



## EXPEDITIOUS CARE OF FULL-THICKNESS BURN WOUNDS BY SURGICAL EXCISION AND GRAFTING\*

OLIVER COPE, M.D., JOHN L. LANGOHR, M.D.,  
FRANCIS D. MOORE, M.D., AND RICHARD C. WEBSTER, JR., M.D.  
BOSTON, MASS.

FROM THE DEPARTMENT OF SURGERY OF THE HARVARD MEDICAL SCHOOL AND THE SURGICAL SERVICES AT THE MASSACHUSETTS GENERAL HOSPITAL, BOSTON.

AT THE TIME of the precipitous entry of the United States into World War II, when burns loomed as an incalculable loss of man power to the Armed Services, review of the burn problem suggested that changes in the surgical handling of the burn patient must be introduced. Considering the suddenness with which a limited number of trained medical personnel might be overwhelmed by a large number of burn casualties under conditions of warfare, too much time and attention were lavished on the wound to the neglect of the internal economy of the casualty. There was urgent need for simplification of the wound treatment. From studying the natural history of the burn wound it was found not only that tannic acid as a surface treatment was injurious but also that in burns of partial skin-thickness, which constitute the majority of burn wounds, the best care could be attained by ignoring the wound, except for protecting it with a simple ointment dressing, and abandoning the washing and débriding ritual of the tannic acid method. Experience with this simplified method was obtained under disaster conditions in the care of the victims of the Coconut Grove fire.<sup>1</sup> Subsequent experience with such therapy under civilian conditions will be considered in a subsequent paper.<sup>2</sup>

The simplified therapy of the burn wound, tailored for disaster conditions, introduced no reform in the care of the full-thickness wound. The slough of such a wound was allowed to separate spontaneously or by the aid of wet dressings applied at later dressings. Although invasive infection was usually held in abeyance by chemotherapy, all such full-thickness wounds became infected and it was necessary to linger and await the appearance of healthy granulations before contemplating grafting. By reducing contamination through observance of strict precautions at change of dressings and of maintenance of the optimum nutritional balance, it was feasible to graft some full-thickness wounds at 25 days after injury, but in other patients with more extensive burns, inevitable infection led to debility and the casualty languished for months

\* The work described in this paper was done under a contract recommended by the Committee on Medical Research, between the Office of Scientific Research and Development and Harvard University.

before all wounds were successfully healed. The full-thickness burn wound emerged during the course of the war as economically and psychologically the most important unsolved problem in the surgical management of the burn patient.

Rehearsal of the life span of the full-thickness burn wound suggested significant differences between it and that of the partial-thickness burn wound other than the absence of viable epithelium. Whereas, in the superficial burn the intact epidermis, even though dead, acts as a protective barrier against the entrance of organisms, in burns where the heat has been of sufficient intensity to cause full-thickness destruction, the epidermis is no longer intact. It is usually cracked or torn and the wound is, therefore, violated. Instead of being bathed by a fluid medium, the more intense heat has coagulated the tissues. Chemotherapeutic agents, able to permeate the wound of partial thickness, are unable to penetrate the coagulum of the full-thickness wound. Such devitalized tissue, devoid of a means of communication with the body fluids, and presumably of a lowered oxygen tension, offers an enticing culture medium to organisms, including the virulent anaerobe. Any counter measures which would intercept infection and lead to expeditious healing must, therefore, include prompt removal of this necrotic tissue. If removal were immediate, and closure of the wound accomplished by grafting, the inevitable contamination of the burn wound would be prevented from developing into an infectious process.

Since the multiplication and invasion of bacterial organisms is rapid, the only means which could possibly eliminate the necrotic tissue before infection develops, is direct surgical excision. The elimination of infection should be accompanied by improved nutrition of the patient and prompt closure of the wound followed by minimal scarring, disability and disfigurement. The early healing should achieve a short period of hospitalization, an economy of manpower and an hopeful outlook by the patient.

The limits of such aggressive surgery suggesting themselves were threatening physiologic imbalance of the patient, a meager amount of donor skin in the extensively burned patient, and inability to recognize with certainty full-thickness destruction of the skin. The physiologic imbalance could be thwarted by prompt and adequate shock therapy, and the quandary over the depth of destruction by increasing experience. The limitations of physiologic imbalance and difficulty of recognizing full-thickness destruction immediately would be exaggerated under conditions of warfare. Under such conditions it might not be possible to maintain adequate physiologic balance or to find the time for scrutiny of the burn wound. Indeed, hospital facilities might be elusive.

The refractoriness of the full-thickness burn has impressed a number of surgeons during the war years. Connor and Harvey, at New Haven, have approached the problem by dissolving the slough chemically. Pyruvic acid starch paste has been found to accelerate the separation of slough, permitting grafting of the area as early as six days after applying the acid.<sup>3</sup> Other workers have tried surgical excision of the slough. Young,<sup>4</sup> in 1942, reported a case, with a burn of 8 to 10 per cent total extent, part of which was excised and grafted three and one-half hours after injury. Ackman, *et al.*,<sup>5</sup> at Montreal,

have reiterated the importance of expediting the closure of the full-thickness burn wound and have, after surgical excision of the slough, grafted extensive wounds as early as 12 and 16 days following injury. We were privileged to see Gerrie, of this Montreal group, excise the slough of a full-thickness burn wound on the 12th day, with immediate grafting; the take was 80 per cent successful. Gerrie removed the slough by shaving it off with a sharp knife rather than by excision of the wound. Saltonstall and Lee<sup>6</sup> have reported the grafting of a patient on the 16th day following injury after excising the slough. More recently, McCorkle<sup>7</sup> has used surgical excision to expedite healing and has reported doing this on the 7th day following injury.

The rationale and theoretic limitations of the program for the expeditious care of full-thickness burn wounds by surgical excision and grafting have been tested. Certain patients received the ideal treatment, that is excision of the full-thickness wound destruction within the first hours after injury, with immediate closure of the wound by split-thickness grafts. Patients in whom physiologic balance was assured were chosen. In other patients, excision of the wound was arbitrarily postponed for a number of days and penicillin administered in that interval in order to see how successful this agent would be in holding invasive infection in abeyance. The initial interval chosen was seven days because it was considered that during this period from injury to excision and grafting it would be feasible for a burn casualty to be dressed and transported from, for example, France to a Base Hospital in England where surgical facilities were available, and physiologic balance of the patient secured. Later this interval was both shortened and lengthened for evaluation of the method.

#### CLINICAL OBSERVATIONS

The cases of full-thickness burns at this hospital which have been found suitable for early surgical excision and grafting have been divided into three categories according to the extent of the burn and the interval between injury and surgical care. The burns have included those produced by heat, chemicals and electricity. In all, 38 patients with 52 wounds have been so treated.

1. Circumscribed full-thickness burns excised and grafted within the first hours after injury constitute one category. There are ten such cases (Table I), and the report of one, illustrating features of this category, is given:

**Case 180.\***—Molten magnesium, inadvertently spilled into the shoe of the man while at work, ignited instantaneously, ripping the shoe and burning the side and dorsum of the foot. The patient arrived at this hospital one-half hour later, where examination showed a localized, demarcated burn (Plate I A). The burned skin consisted of a white, slightly gelatinous coagulum without sensation or visible sign of circulation. Bordering the white coagulum, and in contrast to it, was a tender zone of intense pink of dilated small vessels which blanched with pressure and became pink again immediately upon release of the pressure. This zone with active circulation is seen in Plate I A along the plantar margin of the burn.

---

\* The same case numbers are used in all articles on burn patients studied at this hospital under contract with the Committee on Medical Research. Numbers 1 through 39 refer to the Coconut Grove fire cases; numbers 40 through 96 to cases studied before the Coconut Grove fire; and numbers 97 through 278 to cases studied since the Coconut Grove fire.

TABLE I

Case No. Sex Age (Yr.)	Site of Wound	Wound Extent Per Cent		Time-Hours Injury to Excision	Operative Shock and Treatment	Result Graft Take Per Cent	Reason for Failure	Time-Days Injury to Healing	Time-Days Injury to Discharge
		Total	3°						
162 F 13	Rt. foot	1	1	5	None None	99	Suture line Loss	14	18
174 M 17	Lt. wrist	1	0.5	4	None None	100		11	12
175 M 34	Scalp, neck Lt. forearm	1.5	0.5	3	None None	100 <sup>1</sup>		10	5
180 M 35	Lt. foot	1.5	1.5	6	None None	100		14	39
192 F 39	Lt. arm and hand	3	3	8	None None	95	Suture line loss Hematoma	25	18
225 F 54	Lt. arm Lt. shoulder	3.5	3	53 <sup>2</sup>	None 500 cc. W. blood	75	Poor immobili- zation <sup>3</sup> Sepsis	75	71
240 M 5	Rt. leg	1.75	1.5	4.25	None 100 cc. plasma 250 cc. W. blood	95	Suture line loss Hematoma	19	19
248 <sup>4</sup> M 62	Rt. forearm Rt. hand	10	3	11	None 500 cc. W. blood 250 cc. plasma	95	Sepsis Refrigeration of donor skin	40	47
253 F 1	Rt. forearm	3	1.5	5	None 150 cc. W. blood	95	Poor immobili- zation	48	48
276 M 60	Rt. forearm	7	1	99	None None	100		27 <sup>5</sup>	69 <sup>6</sup>
Average.....								28.3	34.6

<sup>1</sup> Wound edge approximation, no graft (Case 175).

<sup>2</sup> Delayed for tissue sodium studies (Case 225).

<sup>3</sup> Uncooperative, mentally retarded epileptic (Case 225).

<sup>4</sup> General anesthesia not used because of burns about face and alcoholic intoxication. Delayed closure necessary because anesthesia used was inadequate for taking donor skin. At 48 hours after excision, grafts were taken but were refrigerated because excision of slough proved inadequate. At 5 days postexcision the base was not compatible with complete closure, the 3-day refrigerated grafts were laid as mosaics (Case 248).

<sup>5</sup> Healing of wound delayed because of incomplete excision of full-thickness destruction at one margin (Case 276).

<sup>6</sup> Discharge delayed because of burns of face including eyes (Case 276).

Aware that the skin of the dorsum of the foot is thin, the area of white coagulum was judged to be one of full-thickness destruction. Accordingly, six hours after injury the coagulum was excised under low spinal anesthesia (Plate I B). The excision was carried to the areolar tissue overlying the tendons; the areolar tissue was slightly edematous but judged not killed since the circulation was intact. The wound was closed with a split-thickness graft taken with the dermatome knife from the opposite thigh. The graft was sewn by running suture to the margin of the superficially burned skin (Plate I C). A molded, firm pressure dressing was applied. The patient was given penicillin postoperatively for 19 days. There was no clinical infection, and the take of the graft was complete (Plate I D and E). A circumscribed hematoma dissected its way into one area of the graft, but healing was not intercepted. Use of the foot was started on the 14th day. In order to prevent disruption of the newly formed vascular connections of the graft, an elastic bandage was applied whenever the foot was below the horizontal, and walking was intermittent and only gradually increased.

The burn site and extent,\* the interval from injury to closure of the

\* The total and full-thickness extents of the body surface burned are computed according to the Berkow scale.<sup>8</sup>

wound, and the results in the ten cases with circumscribed full-thickness burns are summarized in Table I. The anesthetic and chemotherapy used, duration of operation, and bacteriologic flora encountered are given in the protocol of each case.\*\* The largest area excised and grafted was estimated to be not more than 3 per cent of the body surface. In none of the cases did the total burn, incomplete as well as full-thickness, exceed 10 per cent of the body surface. In half of the patients almost the entire area burned was full-thickness. The areas of the body affected were various; in seven cases the excision and grafting was carried out over superficial tendons of forearm, wrist, lower leg or foot, so-called critical areas. In none was the destruction deeper than the subcutaneous fascia but in all, inspection of the excised tissue left little doubt but that the skin had been completely destroyed.

The operative procedures were carried out between three and 11 hours in eight cases, but not until the 53rd and 99th hours in the other two. The 53-hour delay was necessary in an epileptic (Case 225) who was unable to cooperate; (her burn tissues were also used for radioactive sodium studies). Failure to recognize full-thickness destruction on inspection at entry accounted for the delay in the other (Case 276). Sulfadiazine was given to two patients (Cases 162 and 175) and penicillin to the remainder.

The results are judged to be gratifying and to have been better than in the succeeding categories. The grafts took at least 95 per cent except in one case, that of the epileptic not grafted until the 53rd hour, in whom there was a 25 per cent failure of the initial graft (Case 225). Delay in healing of one wound (Case 276) was occasioned not by incomplete take of the graft but by failure to excise a 0.5-cm. margin of destroyed skin at one point.

Infection developed in two cases, seriously in one, the epileptic. In this latter case, though the infection may have been influenced by the delay in grafting, it was undoubtedly influenced by inadequate immobilization of the grafted areas in an ungovernable patient.

The final healing of the grafted areas has also been pleasing; there is a minimum of scarring, keloid, contractures and disability. The hospitalization and operation disturbed but little the equanimity of the patients. The nutritional status was adequately maintained except in one patient who was a chronic alcoholic (Case 248). The psychologic outlook was good except in the epileptic. The period of hospitalization varied from 5 to 71 days, with an average of 34.6 days. One may question whether chemotherapy had a chance to play a beneficial rôle in this group of patients.

2. Circumscribed full-thickness burns in which excision and grafting were delayed constitute a second category (Table II, 11 patients with 12 wounds). A summary of one case is given as an example:

**Case 153.**—A 69-year-old, vigorous man was admitted eight days after sustaining a deep burn of the back of a leg. His greasy dungarees caught on fire while he was tending a bonfire. His wound was treated at home by his local physician and wife, a

---

\*\* A protocol of each patient cited in this and the other papers of this series will be published after the final paper of the series.

TABLE II  
CIRCUMSCRIBED FULL-THICKNESS BURNS—EXCISION AND GRAFTING DELAYED BECAUSE OF INVASIVE INFECTION

Case No. Sex Age (Yr.)	Site of Wound	Wound Extent		Time-Days Injury to Admission	Time-Days Admission to Excision	Type of Closure	Operative Shock and Therapy	Result Graft Take Per Cent	Reason for Failure	Time-Days Admission to Healing	Time-Days Admission to Discharge
		Per Cent Total	Per Cent 3°								
129 M 72	Lt. leg	0.5	0.5	8	8	Delayed 2 days Complete	Excision: None None Graft: None None	100		18	31
133 F 53	Lt. thigh	2	1.5	8	4	Immediate Complete	None None	40	Inadequate immobilization Hematoma Trophic changes	97	37
151 M 78	Rt. thigh	12	2	3	6	Immediate Complete	Mild 500 cc. W. blood	95	Sepsis	48	56
152 M 52	Rt. foot	1.5	1	0	18 <sup>1</sup>	Immediate Complete	None None	100		34	55
153 M 69	Lt. thigh Lt. leg	10	9	8	4	Delayed 3 days Complete	Excision: Mild 500 cc. W. blood Graft: None 500 cc. W. blood	95	Incomplete excision Suture line loss Hematoma	47	53
154 M 50	Lt. leg Lt. foot	2	2	2	2	Delayed 2 days Complete	Excision: Mild None Graft: None None	85	Tension on grafts not optimal Sepsis	43	53
157 M 73	Rt. thigh Rt. leg	6	2.5	18	6	Delayed 2 days Complete	Excision: Mild 1000 cc. W. blood Graft: None None	100		22	127 <sup>2</sup>

FULL-THICKNESS BURN WOUNDS

TABLE II—Continued  
CIRCUMSCRIBED FULL-THICKNESS BURNS—EXCISION AND GRAFTING DELAYED BECAUSE OF INVASIVE INFECTION

Case No. Sex Age (Yr.)	Site of Wound	Wound Extent		Time-Days Injury to Admission	Time-Days to Excision	Type of Closure	Operative Shock and Therapy	Result Graft Take Per Cent	Reason for Failure	Time-Days Admission to Healing	Time-Days to Discharge
		Per Cent Total	3° Admission								
159 M 28	Rt. shoulder	3.5	0.5	4	5	Delayed 4 days Complete	Excision None None Graft	0	Inadequate immobilization Sepsis	40	28
182 M 25	Rt. arm	1.5	1	6	7	Delayed 2 days Complete (by edge approximation)	Excision None None Graft	100		22	19
206 M 68	Lt. foot	0.5	—	7	7 <sup>1</sup>	Delayed 2 days Complete	Excision None None Graft	100		18	21
	Rt. foot	0.5	—	—	—	Delayed 2 days Complete	Graft: None None	100		18	—
212 M 50	Finger	2x3 cm.	2x3 cm.	7	1	Immediate Complete	None None	100		7	4
Average.....											

<sup>1</sup> Delay in excision resulted from misjudgment at entry concerning depth of destruction. Should have been treated as patient of first category (Case 152).  
<sup>2</sup> Delay due to infected donor sites (Case 157).  
<sup>3</sup> Interval ordinarily would have been shorter but was prolonged for surgical treatment of carcinoma of the pharynx (Case 206).

trained nurse, with a petrolatum gauze dressing. No chemotherapy was given. When the presence of infection was recognized he entered the hospital.

Examination on entry disclosed an infected, sloughing, deeply cracked burn covering three-quarters of the dorsum of the left leg and thigh (Plate III A and B). There was also an irregular, narrow margin of partial-thickness destruction with bleb formation. The infection was judged to be invasive because of the irregular character of the inflammation flaring out from the area of deep destruction. Cultures were taken and the patient was started on penicillin systemically.

Four days after entry, when the patient was responding well clinically to hospital care and the visible and palpable inflammation was subsiding (Plate III C and D), the area of full-thickness destruction was excised under low spinal anesthesia. The excision was carried down to the muscles and tendons and included the deep subcutaneous fascia. The wound was dressed with fine-meshed gauze overlaid by rubber tubes for local irrigation of penicillin. Thickly impregnated petrolatum gauze strips were placed over the tubes to form a pocket for the irrigating fluid and a firm outer dressing was applied. For three days the local irrigation of penicillin was added to the systemic.

On the 15th day after injury, the 7th after the start of penicillin administration and the third after excision of the dead tissue, the patient's wound was dressed in the operating room. The invasive infection had disappeared; and the wound base was free of edema and exudate (Plate III E). Firm, minute granulation tufts were appearing here and there, but otherwise the surface was formed essentially of the tissue left after excision. On this healthy base the wound was closed without drainage by placing split-thickness dermatome grafts removed from the abdomen and opposite thigh (Plate III F). The intramuscular administration of penicillin was continued for 24 more days.

The take of the grafts was almost complete. There was necrosis along the margins of an occasional suture line (Plate III G), and over an hematoma (Plate III H). Healing was delayed, however, by failure to recognize and to excise a corner of full-thickness destruction on the medial aspect of the calf (Cf. Plate III D and H). The entire wound was judged closed by the 47th day and the patient was discharged home on the 53rd day. Mobilization was slow and graded; an elastic bandage was applied for the first two months when the leg was dependent. The result has been excellent; function has been good since discharge from the hospital and there is a minimum of residual scar (Plate III I). The patient was dejected on entry to the hospital, fearing that he was going to lose his leg because of his age and the infection. His prompt recovery and subsequent usefulness of his leg have amazed him.

Review of the bacterial flora grown on cultures suggests that penicillin was effective in controlling the invasive infection and did abet the surgery. Five gram-positive organisms grew on the cultures planted on entry, a *beta* and a *gamma* streptococcus, a *Staph. aureus* and two strains of *Cl. welchii*. The first three and one of the last were demonstrated to be penicillin-sensitive *in vitro*. The *Clostridia* disappeared and *E. coli* appeared before excision; the staphylococcus disappeared after excision of the slough.

The observations on the 11 patients of this category (circumscribed full-thickness burns in which excision and grafting were delayed) are summarized in Table II. The details of anesthesia, duration of operation, bacterial flora and chemotherapy are given in the protocols. The areas excised and grafted varied from 2 x 3 cm. to 9 per cent of the body surface, with the total area burned varying from 2 x 3 cm. to 12 per cent. The full-thickness burns included various body areas and, as in the first group, destroyed the subcutaneous fascia but not the deeper tissues. The reason for the delay in excision and grafting in all cases was the presence of active invasive infection. Only one of the cases was admitted on the day of the burn, and the burn of this patient



## COLOR PLATES

PLATE IA.—Case 180: The left foot of a 35-year-old man one hour after a burn from molten magnesium. Visible circulation and sensation were absent throughout the white area; full-thickness destruction of the skin was judged to have occurred since the skin in this area is thin. The intact circulation of the adjoining thick plantar skin is shown in the photograph as a rim of intense red. This red zone was hypersensitive.

B.—Case 180: The same site six hours after injury during excision of the white skin assumed to have been fully destroyed. The distal half of the dead skin has already been excised. There was slight edema of the subcutaneous areolar tissue. A tourniquet was not used. The few bleeding points were snapped and tied with silk.

C.—Case 180: The operation completed. The wound left after excision of the dead skin has been closed with a split-thickness graft removed from the opposite thigh.

D.—Case 180: The wound seven days after injury and excision and grafting. There has been a complete take of the graft. Blood, presumably from an unsecured vessel, has dissected its way into the midportion of the graft, discoloring but not preventing the healing of the graft.

E.—Case 180: The wound 44 days after injury and closure. There is slight keloid formation along the margins and in the center of the graft where the hematoma formed.

PLATE IIA.—Case 149: Both legs and thighs of a 20-year-old male two hours after sustaining a burn of 72 per cent of the body surface. The skin of the lower legs was firm, white, avascular, asensitive and denuded in part of epidermis; that of the posterior aspect of the thighs was parchment-like. The skin of these areas was considered to have been fully destroyed. The circulation of the skin over both knees was intact and the skin was judged to have been incompletely damaged.

B.—Case 149: Both legs and thighs from the left side on the day of injury. The left leg was judged to have received more extensive full-thickness destruction and was selected for surgical care on the 7th day. It was wrapped in petrolatum gauze without débridement. (The right leg was wrapped in pyruvic acid paste.)

C.—Case 149: Medial aspect of the left leg seven days after injury and immediately before surgical excision of the slough and grafting.

D.—Case 149: Medial aspect of left leg during excision of the dead skin. The vital skin around the knee with intact circulation is being saved. No tourniquet is being used.

E.—Case 149: Medial aspect of left leg immediately following closure with a stocking of split-thickness grafts removed from the anterior chest and abdomen, the only unburned portions of the body.

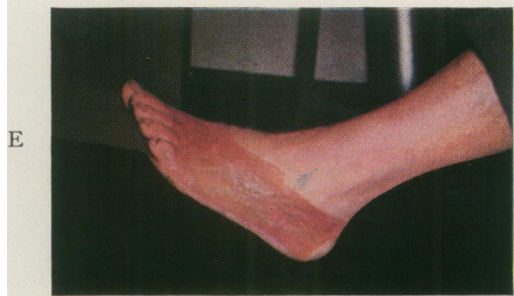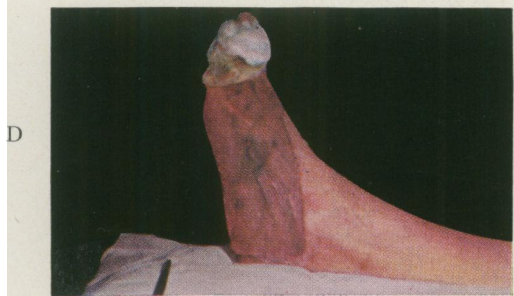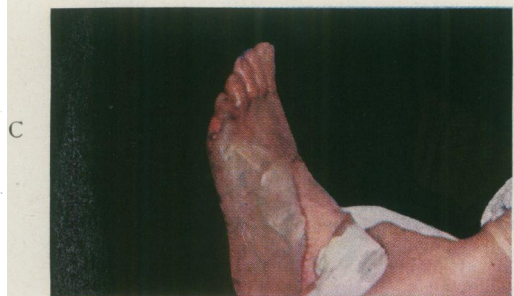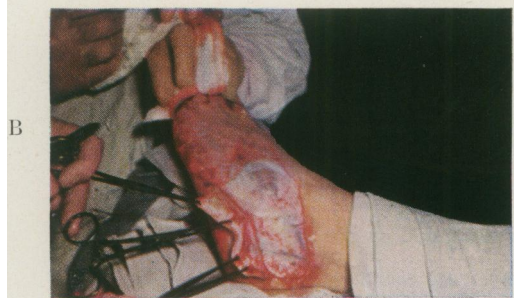


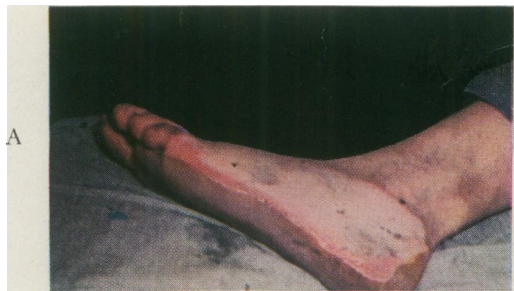PLATE I

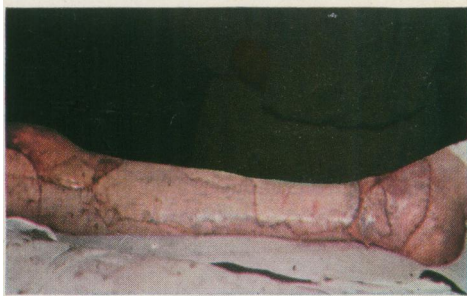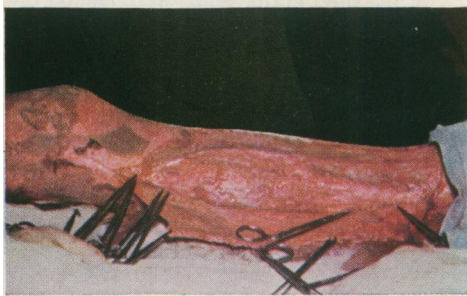

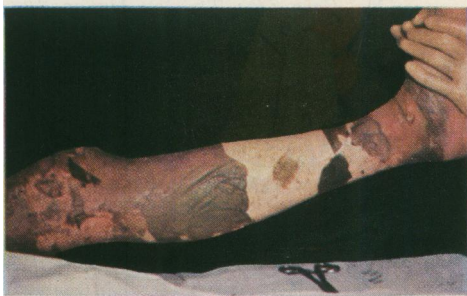
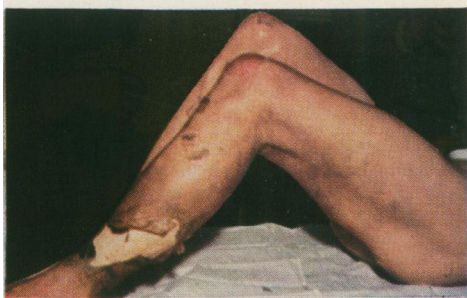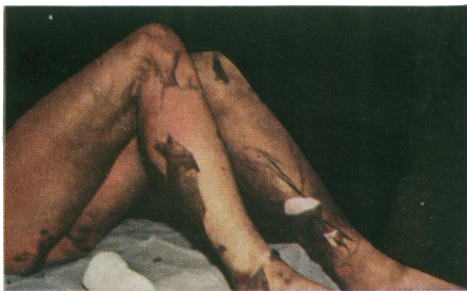PLATE II

PLATE II F.—Case 149: Lateral aspect of the left leg seven days after injury and immediately before surgical excision of the slough and grafting.

G.—Case 149: The popliteal space and posterior aspect of left thigh on the 7th day and prior to excision and grafting.

H.—Case 149: The line of excision of the dead skin on the outer aspect of the left ankle.

I.—Case 149: Excision of the slough of the left leg completed. No tourniquet used.

J.—Case 149: Left leg. Closure of the wound left after excision of slough has been completed by a stocking of grafts.

K.—Case 149: The left leg on the 17th day after grafting, the 24th after injury. There was pressure necrosis around the malleoli and along a few suture lines, otherwise the take of the graft was satisfactory.

L.—Case 149: Posterior aspect of thighs and right leg on the 47th day after injury when postage stamp grafts were placed on the wound areas the slough of which was left to separate spontaneously (left thigh) and with the help of pyruvic acid paste (right thigh and leg).

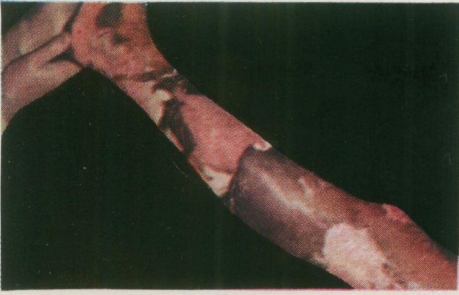M.—Case 149: The left leg on the 61st day after grafting, the 68th after injury.

N.—Case 149: The left popliteal space and thigh on the 68th day after injury, failing to reveal at this stage any better healing of the stocking graft which was placed on the excised base than of the later postage-stamp grafts which were placed on the granulating surface.

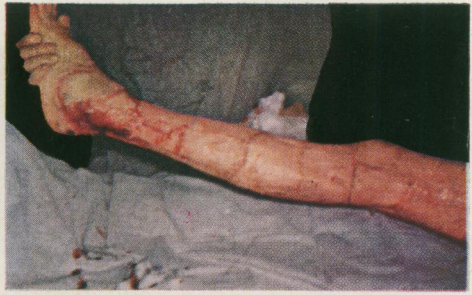O.—Case 149: Both legs on the 97th day after injury. Keloid scar has formed diffusely beneath the grafts laid on granulation tissue; contracture is apparent in the popliteal space. In contrast, there is no keloid scarring, except along the suture lines, of the sheet grafts which were laid on the base left after excision; there is no contracture in the popliteal space.



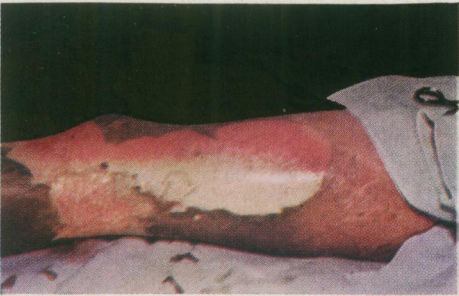F



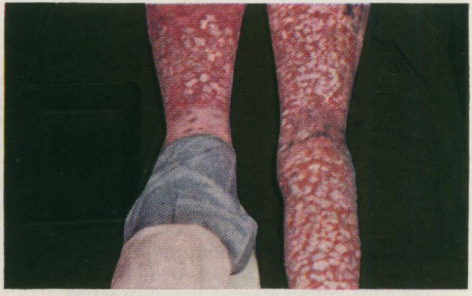K



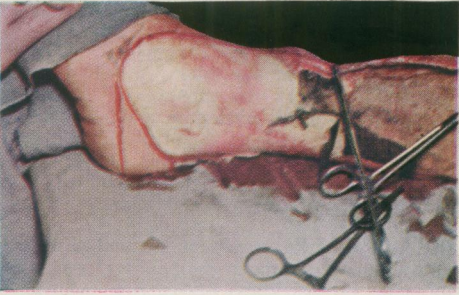
G



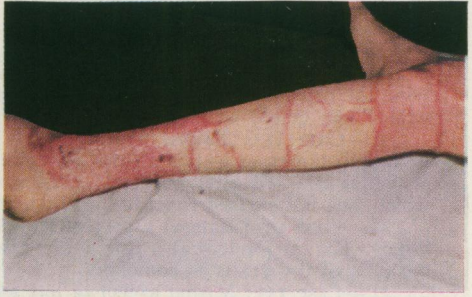L



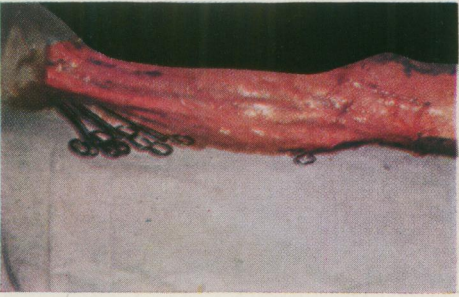
H



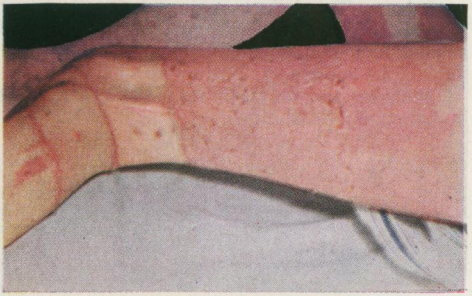
M



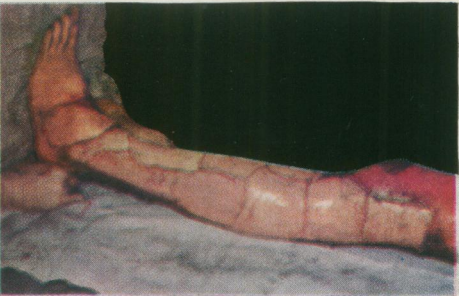I



N



J



O

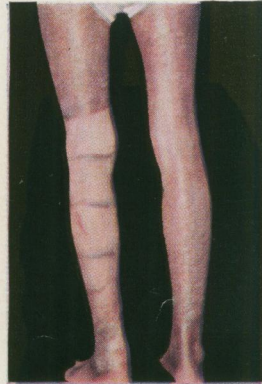

PLATE II (Cont'd.)

PLATE IIIA.—Case 153: Lateral aspect of the left leg of a 69-year-old man on admission to hospital, eight days after injury. The burn, from greasy trousers ignited by a bonfire, had been treated at home with a petrolatum gauze dressing and no chemotherapy. The inflamed irregular border surrounding the deep burn suggested invasive infection.

B.—Case 153: Medial aspect of left leg on day of admission, 8th after injury. The deep infected slough over the calf and popliteal space is to be contrasted with the more anterior incomplete-thickness burn with blebbing.

C.—Case 153: Lateral aspect of left leg on 12th day after injury, 4th day after admission and start of penicillin. The deep burn is more clearly demarcated and the invasive inflammation has decreased.

D.—Case 153: Medial aspect of left leg on 12th day after injury, 4th day after admission and start of penicillin and just before the deep slough was excised.

E.—Case 153: Lateral aspect of left leg on 15th day after injury, 7th after admission and start of penicillin and 3rd after excision of the slough. The tendinous fascia overlying the calf muscles is exposed. All evidence of invasive infection has disappeared. The wound was closed with grafts immediately after this photograph was taken.

F.—Case 153: Medial aspect of left leg immediately following closure of wound with split-thickness grafts on the 15th day after injury, 7th after admission and start of penicillin and 3rd after surgical excision of the slough. An area of doubtful thickness which was not excised is visible in the angle of the wound in the center of this figure.

G.—Case 153: Lateral aspect of left leg on the 7th day after grafting, the 22nd after injury. Except for loss at a few points along the suture line and over a small hematoma, the take of the grafts is complete.

H.—Case 153: Medial aspect of left leg on the 14th day after grafting, the 29th after injury. The failure of the take of the graft caused by the hematoma in the popliteal space and the line of demarcation of the area of questionable full-thickness destruction, which was not excised, are visible.

I.—Case 153: Follow-up of the left leg two years after injury. There is a minimum of scarring and no disability. The grafted skin of the popliteal space was pinched to demonstrate its flexibility.



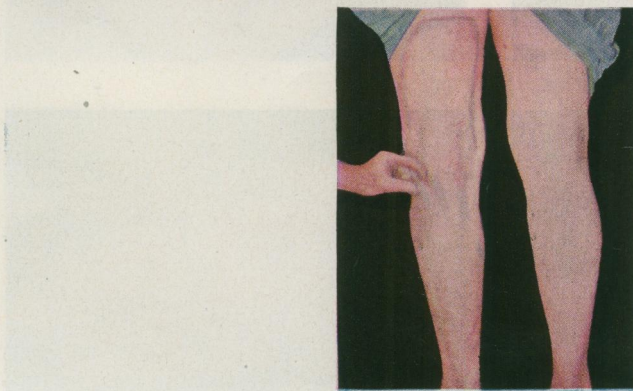
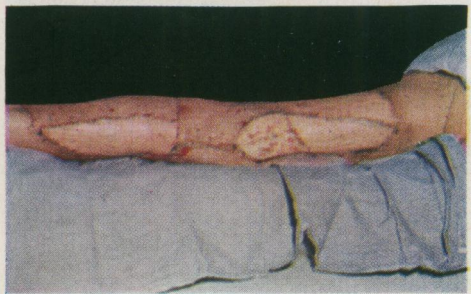
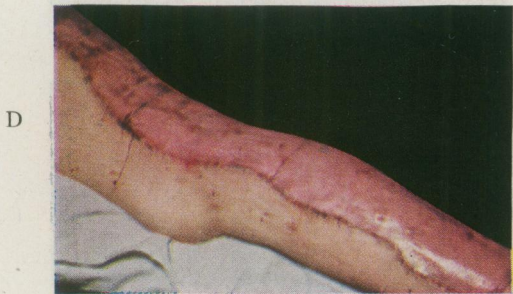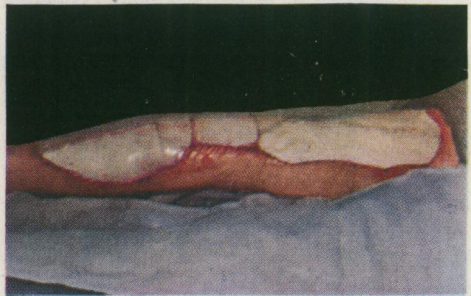
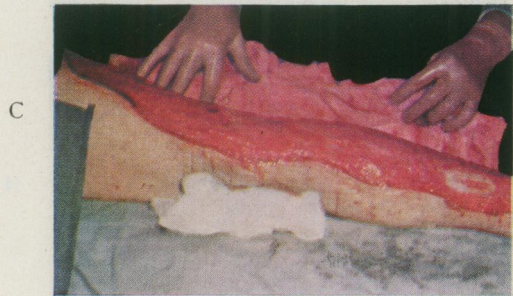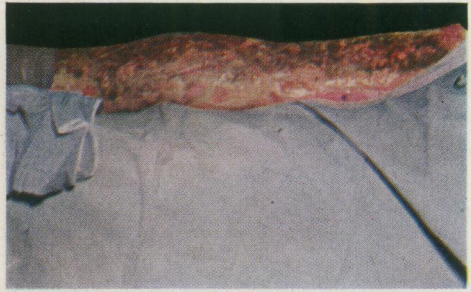


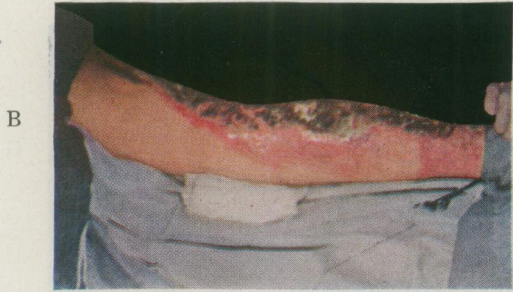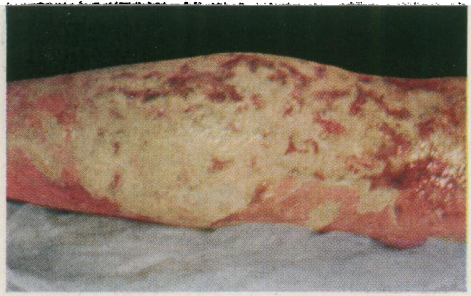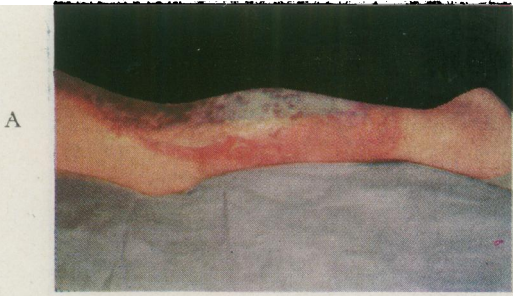PLATE III



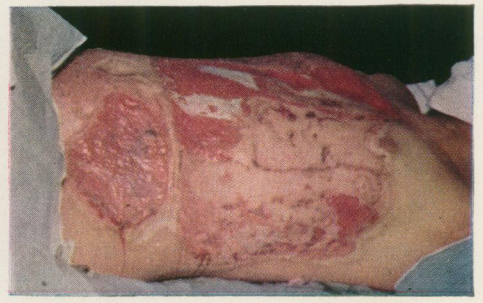
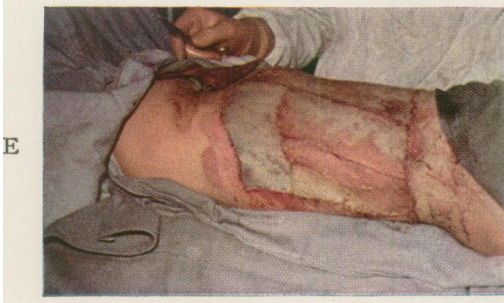
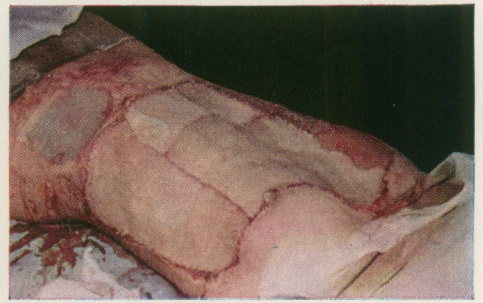
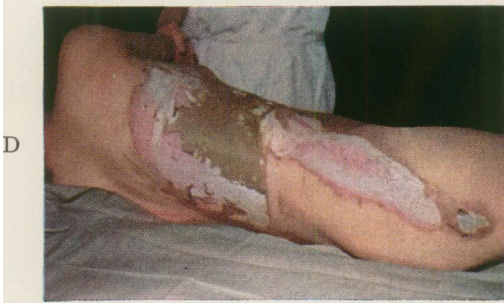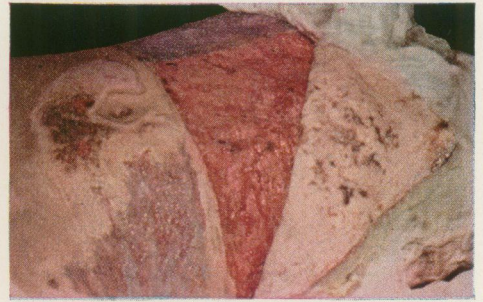

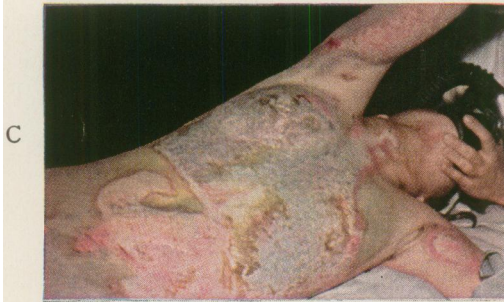
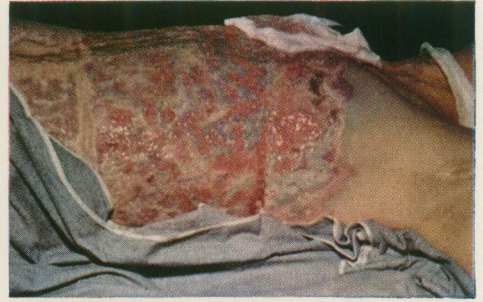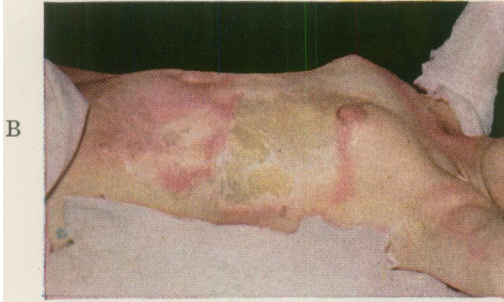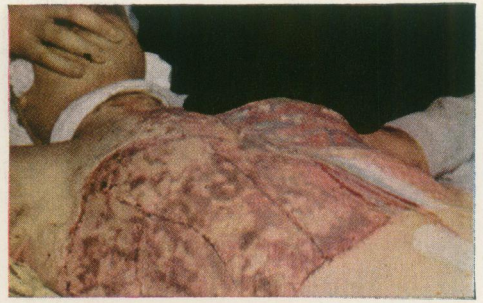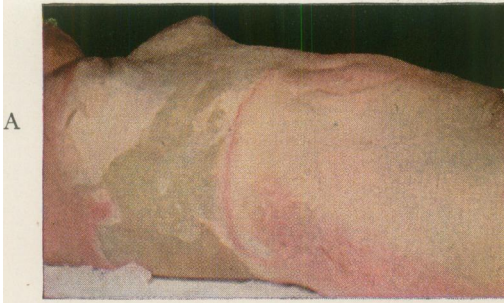PLATE IV



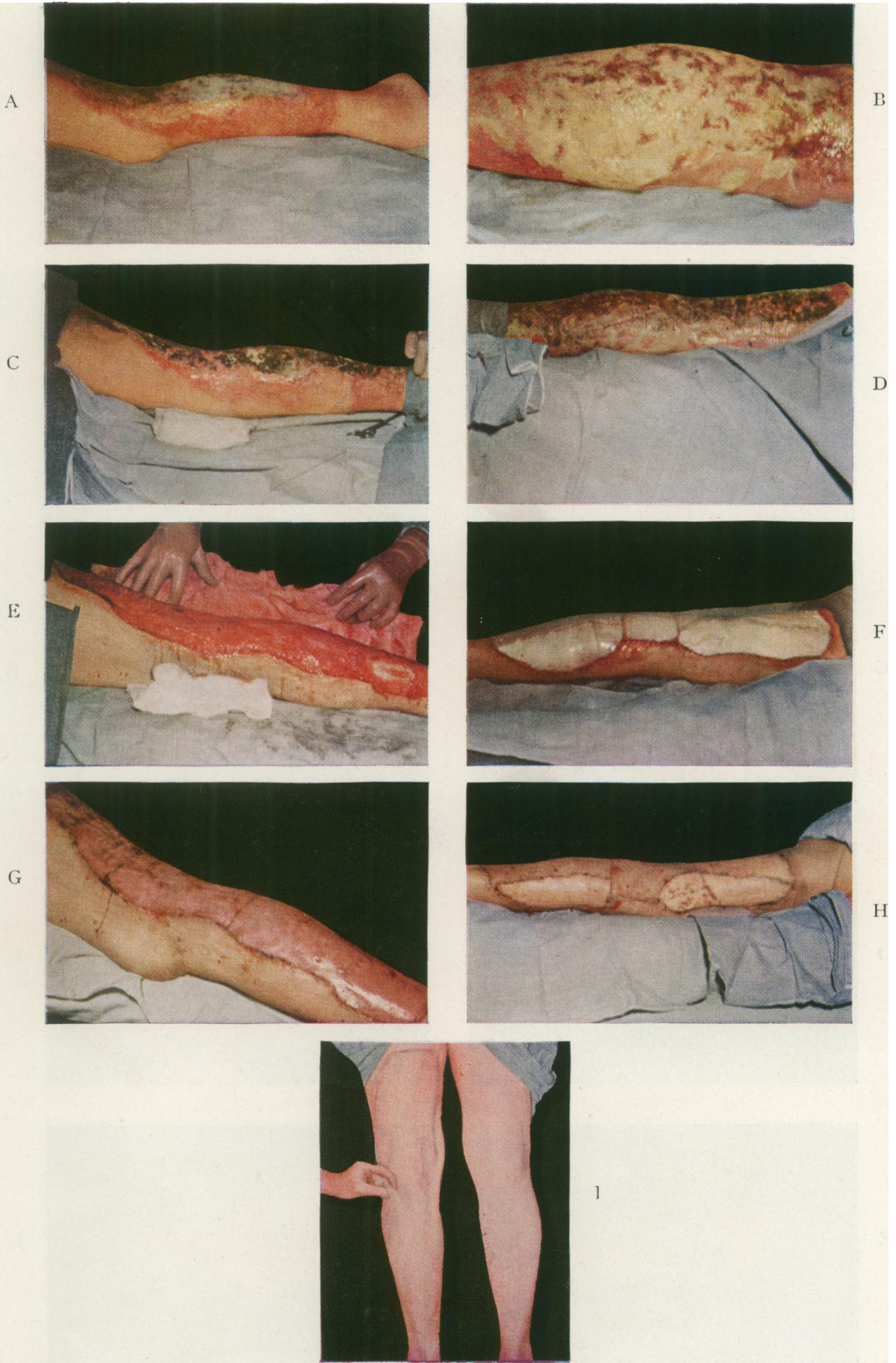
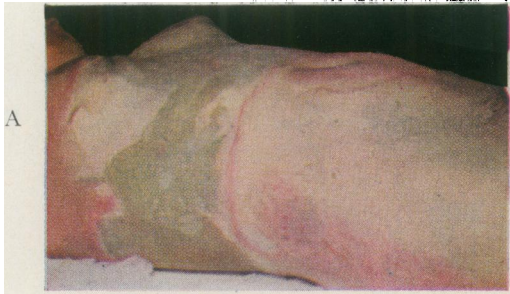

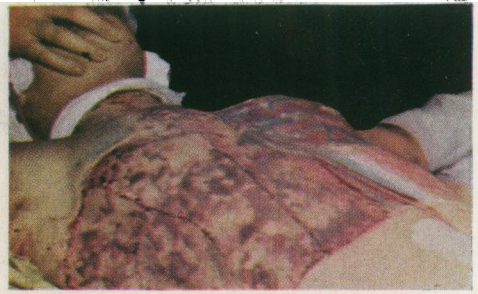PLATE III

NOTE: As the lettering on Plate III as printed in the paper by Drs. Cope, Langohr, Moore and Webster in the ANNALS OF SURGERY for January, 1947, was incorrect, this corrected plate has been prepared with gummed edges for insertion in its place.

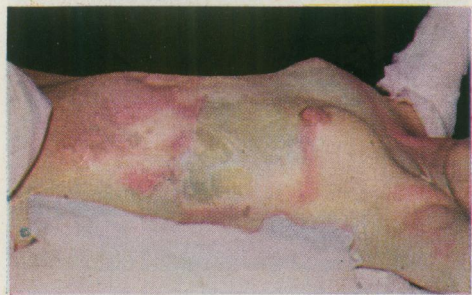



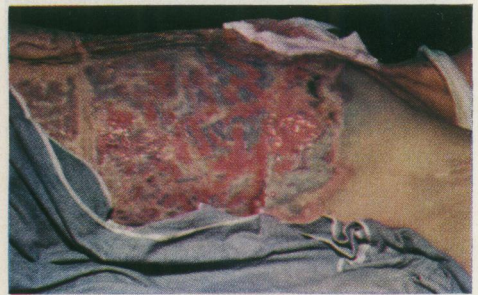A



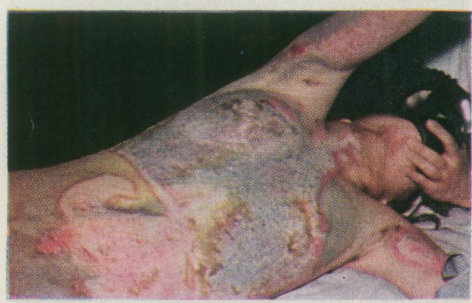F



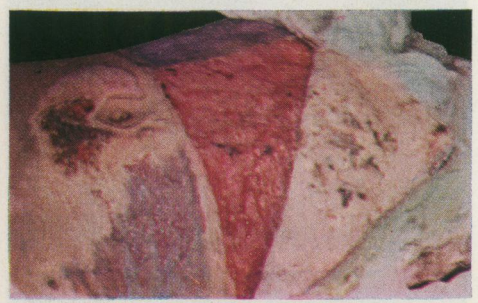
B



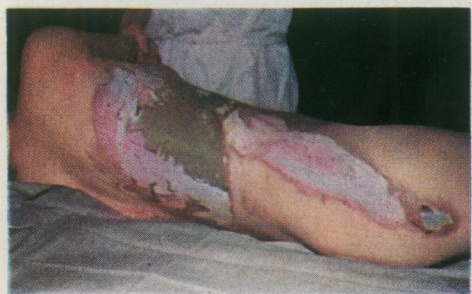G



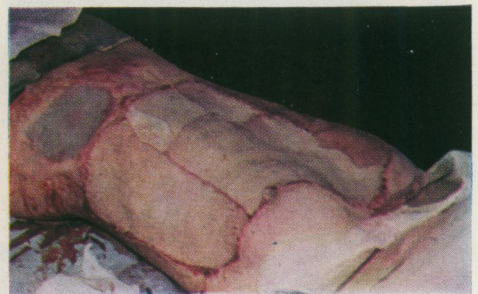
C



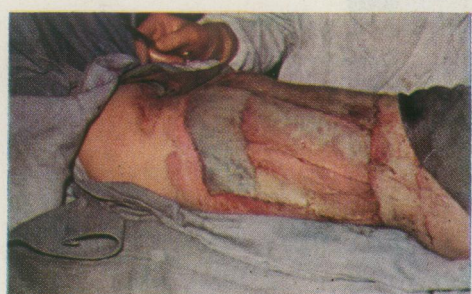H



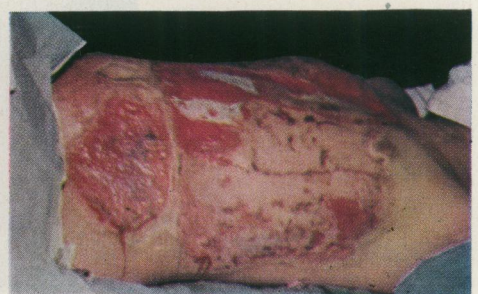
D



I



E



J

PLATE IV

was not immediately excised and grafted because the depth of injury was misjudged on entry to be of only partial skin thickness. The other patients were admitted from two to 18 days after injury.

Because invasive sepsis in all wounds was present at the time excision of the slough was contemplated, chemotherapy in all and delayed closure in the majority were resorted to. Penicillin, either parenterally or locally, was used in all cases, and accompanied by sulfadiazine in two cases (Cases 159 and 206) and tyrothricin in three cases (Cases 152, 153 and 157). A subsidence of the inflammatory reaction was observed in almost all wounds prior to the excision. In four cases the wound was closed immediately following excision. In the other nine an interval of from two to four days was allowed to elapse between excision and closure. In all cases closure was complete. To the excised, ungrafted wounds of the nine cases with delayed closure, penicillin was applied locally.

The results were surprisingly successful. In nine wounds the take of the grafts was virtually complete, a result comparable to the best in the patients of the first category. In the remaining three wounds the takes of the grafts were zero, 40 and 85 per cent. Inadequate tension and immobilization are believed to have accounted for lack of success in the first two of these, and sepsis in the third.

Owing to the clinical observation that the inflammation which was present prior to excision of the burn slough subsided during the parenteral adminis-

---

PLATE IV A.—Case 135: The right side of the trunk of a 16-year-old girl on entry two hours after a burn from an explosion of a gas stove. The deepest injury, a broad band of parchment-like skin, was outlined by her brassiere.

B.—Case 135: The left side of the trunk at entry. The parchment-like skin extended to the posterior axillary line. The wounds were dressed with petrolatum gauze, without débridement or cleansing. Excision and grafting were planned for the 7th day. Penicillin was started.

C.—Case 135: The slough on chest and abdomen on the 7th day, immediately before the initial excision and grafting. The bluish tint of the slough is from the blue dye, T-1824, used for the plasma volume determinations.

D.—Case 135: The right side and back of the chest on the 7th day, immediately before the initial excision and grafting.

E.—Case 135: The right side of the chest immediately following surgical excision of the slough and closure of the wound with split-thickness grafts. The excision was carried into edematous fat, on which base the grafts were laid.

F.—Case 135: The right side of the chest on the 7th day after excision and grafting, the 14th day after injury. There is sloughing above the suture over the right breast where the excision was incomplete. There are numerous small hematomas in the graft. The take of the graft, however, is complete.

G.—Case 135: The left and unexcised side of the chest on the 14th day after burning. The slough has already separated spontaneously over wide areas; nongranulating inflamed fat is exposed. The wound was excised immediately following the taking of this photograph and a wet penicillin pack dressing applied.

H.—Case 135: The left side of the chest on the 4th day after excision, the 18th after injury. In spite of the inflamed appearance of the base, split-thickness grafts were laid upon it, and the wound closed.

I.—Case 135: The left side of the chest immediately after closure with grafts on the 18th day after injury. The new grafts were sewed to those placed 11 days previously.

J.—Case 135: The left side of the chest on the 7th day after grafting, the 30th after injury. In contrast to the successful take of the grafts on the right side which were placed on the 7th day after injury, the take of these grafts, laid upon an inflammatory base on the 18th day after injury, did not exceed 55 per cent.

tration of chemotherapy, it is hard to escape the conclusion that chemotherapy helped in the successful outcome.

Review of the bacteriologic findings of this group yields evidence that penicillin may have been more effective in certain cases. *B. coli* and *B. proteus* were recovered only from the wounds which did not heal promptly. The recovery of five organisms, all gram-positive, and four penicillin-sensitive *in vitro*, in the case with the most extensive wound in this category, has already been cited in the case report.

The final outcome of the grafting has been varied. Some grafts are excellent, with minimal scarring and producing no disability, while other wounds have formed keloid. It is an impression that the keloid and scarring are roughly proportionate to the amount of the preëxisting infection.

No difficulty in the control of fluid and electrolyte balances or nutrition was encountered in these patients. The dejected psychologic state of some on entry was readily overcome by the promptness of the therapy. The period of hospitalization varied from 4 to 127 days (average 44 days). The time from admission to healing averaged 34.5 days.

3. Extensive full-thickness burns of recent origin constitute the third category in which surgical excision and grafting have been carried out. Thirty wound areas in 17 patients of this category have been so treated.

As an example of the perplexities which may be encountered and the benefits to be derived from prompt therapy, a brief outline is given of the management of the most extensively burned patient of this group in whom early closure was undertaken:

**Case 149.**—The patient was the driver of a full gasoline truck which, when forced off the road, overturned, caught on fire and exploded. He was extricated by passers-by from the burning cab and thrown into a nearby stream to extinguish his flaming clothing, but not before he had been severely burned. At the community hospital he was given morphine and reached this hospital by ambulance two hours after injury. On entry, it was estimated that 72 per cent of his body surface was burned, 38 per cent of the total surface being full-thickness. The deeper portions were charred and leathery; those of the forehead, ears, upper face, lower neck and over the manubrium, backs of both hands, both lower legs and the backs of both thighs were considered to be full-thickness, while those of the lower back and buttocks, even though tanned, were of questionable depth. The only unburned portions of the body were the lower anterior chest and abdomen.

It was decided to treat the full-thickness burns of one leg by surgical excision and grafting on the 7th day, the wounds to be covered in the meantime with a petrolatum gauze dressing without any débridement or cleansing, and the patient to be given penicillin intramuscularly; pyruvic acid paste, according to the method of Connor and Harvey, was to be applied to the wounds of the other leg. The right leg, the less severely burned of the two (Plate II A and B) was chosen for the pyruvic acid method.

Reasonable homeostasis was achieved and maintained by massive volumes of plasma, saline solution, whole blood and a high protein diet. The details of this therapy are given in the protocol and discussed in later papers under "Disordered Physiology."<sup>2</sup> Edema of the larynx developed and necessitated tracheotomy at the 30th hour.

Because physiologic equilibrium of the patient and undisturbed renal function were achieved, the operative program could be adhered to. It was hoped that his despondency over his disfigurement would be dissipated by the promise of early healing. On the 7th

day, under intravenous pentothal anesthesia, split-thickness grafts were removed with the dermatome from the entire unburned surface of the anterior chest and abdomen by one operating team while a second team excised the dead hide of the left leg from the ankle to above the popliteal space. Only that amount of full-thickness destruction (12 per cent of the body surface) was excised which could be covered by grafts from the unburned skin available. It was recognized that more of the left thigh would have to be grafted at a later date when skin was again ripe. The wound left after excision was closed by a stocking of grafts and without drainage. Plate II C through J shows the appearance of the necrotic skin before and during excision, the depth of the excision, the nature of the base upon which the grafts were placed and the wound after closure.

The take of the grafts was marred only by pressure necrosis behind the malleoli and Achilles tendon due to a faulty dressing (Plate II K). Separation of the slough of the right leg under the pyruvic acid paste was not prompt (perhaps due to faulty technic of application) and the wounds of this leg and the back of the left thigh were eventually covered on the 47th day by placing mosaic grafts on granulation tissue (Plate II L). The other areas of full-thickness destruction, forehead, face, dorsum of hands and fingers, were also covered by placing grafts on granulations following spontaneous separation of the slough. Each area was grafted as soon as the granulations appeared firm.

The patient responded to the aggressive therapy with excellent morale. He was discharged home, with all wounds closed, on the 85th day after injury and returned to work six weeks after leaving the hospital, or 15 weeks after injury. Cataracts were discernible in both eyes six months after injury, but they have not progressed to the extent of preventing continuous employment.

Follow-up examination showed that the grafts which were laid immediately upon the base left after excision of the slough healed with less scarring and greater mobility than those placed upon fibrous tissue granulations (Plate II M, N and O).

The observations and operations on the 17 patients of this category (recent extensive full-thickness burns) are summarized in Table III. The details of shock and chemotherapy, bacteriology, anesthesia, duration of operation, blood loss, and metabolic observations are given in the protocols, and in many cases also in the articles on bacteriology and disordered physiology.<sup>2</sup>

The area of full-thickness burns in these patients varied from 1 to 38 per cent and the total burn from 5 to 72 per cent of the body surface. Four of the patients, of whom two were children, had a total burn of less than 10 per cent; they are included in this category of extensive burns because homeostasis was sufficiently disturbed to require postponement of operation. The largest wound area excised and grafted at any one operation was 12 per cent. In some of the wounds in this group, deep structures were burned. The wounds were located in all areas of the body.

The interval between injury and initial operation varied from 1 to 35 days. In some the interval was conditioned by the continued physiologic imbalance of the patient. It was arbitrarily set in many cases on entry in order to explore the usefulness of penicillin in holding infection in the wounds in abeyance, and is longer than would now be practiced. Penicillin was administered intramuscularly from the time of entry to all patients, and locally on some wounds after excision. Sulfamerazine had been given to one patient prior to entry to this hospital (Case 170), otherwise no chemotherapeutic agent other than penicillin was used.



In one-half of the wound areas the grafting was 95 per cent, or more, successful. A few of the wounds excised and grafted after two weeks fall into this excellent group but, in general, the success of grafting diminished with the lengthening of the interval between injury and operation. In all of the areas where grafting failed there were signs of active infection, and the majority of the failures in the group are, therefore, attributed to sepsis. In two of these unsuccessful areas the excision had not been carried deep enough; it is believed that the residual necrotic tissue nourished the infection and prevented the blood supply from succouring the graft.

The decreasing success of grafting with an increasing interval between injury and excision and grafting is impressive; a case from this category of extensively burned patients is cited to illustrate this point:

**Case 135.**—A 16-year-old girl reached this hospital two hours after her clothes had been ignited by a blast from a gas stove. The front and right side of the trunk and both arms were burned, areas comprising approximately 25 per cent of the body surface. The major portion of the burn was deep. This was believed due to the intensity with which the material of her brassiere burned, for from just to the right of the midline in the back around front to the midaxillary line on the left was a broad, white parchment-like outline of the garment (Plate IV A and B). The lower half of each nipple and of the skin of each breast was included in the parchment-like area. There was also a smaller, irregular zone of white skin on the left side of the abdomen.

The areas of white parchment-like skin were considered to be of full-thickness destruction because visible circulation and sensation were absent. Excision and grafting were planned for the 7th day; the wounds were wrapped in a petrolatum gauze dressing, with no débridement or cleansing, and penicillin was started intramuscularly. Homeostasis was reestablished and held by maintaining a measured, normal circulating blood volume and renal output. On the 7th day the dressings were removed in the operating room. The initial impression of what constituted full-thickness destruction was confirmed; the necrotic tissue was more moist than on entry but no spontaneous separation was yet apparent (Plate IV C and D). Under gas-oxygen-ether anesthesia, the full-thickness portion of the wound of the right side of the chest was excised. The excision was carried into edematous fat; so edematous was the fat posteriorly that small pools of fluid were cut through. On this base were placed six sheets of split-thickness skin removed with the dermatome from the thighs. The wound was closed without drainage by sewing the sheets together and to the borders of the excised wound. The border was made up of the full-thickness slough medially, and elsewhere, of healing second-degree burn (Plate IV E).

On the 7th day after grafting (14th day after injury) the dressings were removed. The take of the grafts was perfect, including those along the margin of the full-thickness burn in the anterior midline. There was slight separation superiorly where the nipple areola and an unexcised margin of skin on the breast had sloughed. Damaged, but doubtful, full-thickness nipple tissue had not been excised on the chance that it might survive (Plate IV F). Spontaneous separation of the unexcised slough on the left side had already started (Plate IV G).

At this second exposure of the wound (14th day after injury) the full-thickness wound of the left side of the chest was excised. In contrast to the edematous fat uncovered seven days previously on the right side, the subcutaneous fat was now inflammatory. It was thickened, stiff, nonwatery, and vascular. In view of this inflammation, presumably infectious in origin, it was decided not to graft immediately but to treat expectantly with a gauze pack and local penicillin in addition to the systemic penicillin. On the 4th day after excision (18th day after injury) the appearance of the base left after excision had

not significantly changed (Plate IV H). In spite of the slight but deep inflammatory reaction, the area was grafted (Plate IV I). The take of the graft, unlike that of the grafting done on the 7th day, was little more than 50 per cent successful.

Undoubtedly, there were factors other than the slowly progressive infectious inflammation beneath the burn of full-thickness which contributed to the partial failure of the take of the 18th day grafting as compared with complete success of the 7th day grafting. The patient had become uncoöperative, had scratched under the dressing, and had torn the grafts near the midline. She was also not eating well and was at the peak of her metabolic and nutritional imbalance. But the presence of all these factors, in addition to progressive sepsis in such a burn wound, only serves to emphasize the importance of closing any full-thickness burn wound immediately.

Clinical signs of infection were encountered in all of the wounds of this category prior to excision, the administration of penicillin, notwithstanding. In one patient the burns of the legs were so deep that tendons and muscles were necrosed, gas gangrene developed and bilateral amputation was necessary.

The final outcome of the grafts has varied considerably. Deep scarring and contractures have formed in those wounds where there was prolonged infection. Good healing, with minimal scar and keloid formation, has taken place in those wounds which were grafted in the first week after injury.

In the care of all of the patients of this category it was necessary to be vigilant concerning burn shock. In some the period of impending shock passed without incident, in others the control of the electrolyte, fluid and plasma colloid balances was not achieved until several days after admission. In many the adaptation to traumatic insult, protein deficit and malnutrition plagued us. In those patients in whom recovery was prompt the initial discouragement was dissipated. The period from injury to discharge from the hospital varied from 22 to 223 days, the average being 87 days (Table III). If the child whose unhealed donor site delayed discharge until the 223rd day is omitted (Case 137), the average becomes 79 days.

#### TECHNICAL CONSIDERATIONS

The plan of immediate excision and grafting of a full-thickness burn wound will be marred if the surgeon does not appreciate the importance of (1) the assessment of the depth of destruction; (2) chemotherapy as an adjunct; (3) certain details of operative technic (anesthesia, control of hemorrhage, width and depth of excision and the condition of the grafting base); and (4) homeostasis.

1. *Assessment of the Depth of Destruction.*—The surgeon must distinguish the depth of destruction when the patient is first seen in order to treat the full-thickness wounds expeditiously. If the wounds have already been dressed when the patient is seen by the responsible surgeon, the dressings will have to be removed or the surgeon will be blind in his treatment of the wounds and the patient.

The gross appearance of the skin, the state of the circulation and sensation and the position of the burn offer clues for evaluation of the depth of destruction. Charred, tanned, leathery or white, coagulated skin indicates deep destruction. Also, in deeply damaged skin the visible circulation in the small

TABLE III  
EXTENSIVE FULL-THICKNESS BURNS EXCISED AND GRAFTED

Case No.	Wound Extent		Extent of Excision Per Cent	Time-Days Injury to Excision	Type of Closure	Operative Shock and Treatment		Result Graft Take Per Cent	Reason for Failure	Time-Days Injury to Healing	Time-Days Injury to Discharge
	Age (Yr.)	Site of Wound				Moderate	Excision:				
135	25	15 Rt. chest	9	7	Immediate Complete	1000 cc. W. blood	95	Poor immobilization Suture line loss	34	92	
F											
16		Lt. chest Upper abdomen	6	14	Delayed 4 days Complete	Excision: Mild 1000 cc. W. blood Graft: Mild 800 cc. W. blood	50	Poor immobilization Sepsis	92		
137	8	6 Rt. leg	6	6	Delayed 2 days Complete	Excision: None None Graft: Mild 500 cc. W. blood	65	Incomplete excision Inordinate pressure Sepsis	89	223 <sup>1</sup>	
M											
6											
142	8	1.5 Lt. lat. ankle	0.5	8	Immediate Complete "dermal"	Moderate 500 cc. W. blood	25	Sepsis Hematoma Type of graft	46		
M											
52		Lt. lat. calf	0.5		Immediate Complete "epidermal"		85	Sepsis Suture line loss	30		
		Lt. patella	1/6		Delayed 7 days Complete		80	Sepsis	37	123	
		Lt. inf. patella	1/6	15	Immediate Complete	None 1000 cc. W. blood	15	Sepsis	60		
		Lt. med. ankle	0.25		Immediate Complete		10	Sepsis	46		
143	40	34 Ant. rt. thigh	4	11	Delayed 8 days Complete	Excision: Mild 1000 cc. W. blood	100		32		
M											
17		Lt. leg	2	11	Delayed 4 days Complete	1st stage grafting: None 500 cc. W. blood 2nd stage grafting: Mild 500 cc. W. blood 3rd stage grafting: Severe Op. discont. 1000 cc. W. blood 250 cc. plasma	95	Graft overlay bone sequestrum	77	122	
			3		Delayed 22 days Complete		80	Hematomata Sepsis	77		



FULL-THICKNESS BURN WOUNDS

TABLE III—Continued  
EXTENSIVE FULL-THICKNESS BURNS EXCISED AND GRAFTED

Case No.	Wound Extent		Site of Wound	Extent of Excision Per Cent	Time-Days Injury to Excision	Type of Closure	Operative Shock and Treatment	Result Graft Take Per Cent	Reason for Failure	Time-Days Injury to Healing	Time-Days Injury to Discharge
	Per Cent	3°									
149	72	38	Lt. leg	12	7	Immediate	Mild 1000 cc. W. blood	95	Inordinate pressure	54	85
M			Lt. thigh			Complete					
20											
155	41	26	Rt. upper back	8	10	Immediate	Mild 1000 cc. W. blood	75	Tension Sepsis	41	
M			Lt. thigh	9		Complete					
48						85% delayed 10 days	Excision: Moderate 1000 cc. W. blood	100		62	108
			Lt. leg			Complete	1st grafting: Severe. (Op. discont.) 1000 cc. W. blood	100			
						15% delayed 30 days	2nd grafting: None				
						Incomplete	None				
					21						
			Rt. thigh	5		Delayed 14 days	None	100		62	
			Rt. buttock			Incomplete (Refrig. grafts 14 days)	3rd grafting: None				
							None				
							None				
161	12	7	Upper back	7	8	Immediate	Mild 1000 cc. W. blood	80	Poor immobilization Sepsis	53	60
M						Complete					
69											
164	36	7	Upper back	6.5	5	Immediate	Moderate 500 cc. W. blood	60	Suture line loss Sepsis	48	60
M						Complete					
32											
166	17.5	7.5	Rt. thigh	4	21	Immediate	None 1000 cc. W. blood	60	Proteolytic sepsis	68	70
F			Rt. buttock			Complete					
30			Rt. axilla	2.5	31	Delayed 2 days	Excision: None 1000 cc. W. blood	95	Hematoma Suture line loss	Unhealed 70	
			Rt. breast			Complete	Graft: Mild 1000 cc. W. blood				
170	15	13	Lt. shoulder	3.5		65-70%	Excision & 1st grafting: Marked (Op. discont.)	70	Sepsis	29	
M			Lt. axilla			Immediate					

TABLE III—Continued  
EXTENSIVE FULL-THICKNESS BURNS EXCISED AND GRAFTED

Case No. Sex Age (Yr.)	Wound Extent Per Cent		Site of Wound	Extent of Excision Per Cent	Time-Days Injury to Excision	Type of Closure	Operative Shock and Treatment	Result Graft Take Per Cent	Reason for Failure	Time-Days Injury to Healing	Time-Days Injury to Discharge
	Total	3°									
42			Lt. arm	2	9	Complete Delayed 9 days Complete	1000 cc. W. blood None 2nd grafting:	95	Hematoma Suture line loss	66	74
196	15	1	Rt. wrist	1	4	Immediate Complete	None 1000 cc. W. blood	98	Suture line loss	13	22
210	31	25	Rt. arm Rt. shoulder	3	8	Delayed 13 days Incomplete	Excision: Marked (Op. discont.)	100		120	
34			Rt. chest	1.5	8	Delayed 13 days Incomplete	1500 cc. W. blood 500 cc. plasma Grafting: Mild 1000 cc. W. blood	100		102	128
218	18	2	Rt. foot	0.25	14	Delayed 3 days Complete	Excision: None	0	Sepsis	62	
54							None 1st grafting:				
			Lt. foot	0.25	14	Delayed 15 days Complete	None 2nd grafting:	60	Sepsis	103	114
229	9	7	Rt. shoulder Rt. breast	3.5	31.5	Immediate Complete	None 1000 cc. W. blood 500 cc. plasma	85	Inadequate immobili- zation Sepsis	54	64
254	45	5	Rt. thigh	0.5	35	Immediate Complete	None 1500 cc. 5% D/W	98	Suture line loss	42	64
258	5	1	Lt. shoulder	2x3 cm. 3x4 cm.	19	Immediate Complete	None	100		26	28
277	12	11	Rt. leg	11	1	Delayed 2 & 6 days Complete	Excision: None 250 cc. W. blood 250 cc. plasma 1st grafting: None 250 cc. W. blood 2nd grafting: None 250 cc. W. blood	98		38	45
Average.....											
Discharge delayed by infected donor sites and persistence of the malnutrition present on entry (Case 137).....											
											57.8

vessels is obliterated. Sometimes blood coagulated within the superficial vessels gives the appearance of active circulation but pressure fails to dislodge the pigment. In an incomplete-thickness burn wound with intact circulation not only is the pink color displaced with pressure but the flush returns instantaneously with release of the pressure, so open is the arterial bed.

Sensation is lost if destruction of the skin is complete. Superficial and deep incomplete-thickness burns are usually exquisitely tender except in relatively insensitive areas of the body, such as the buttocks and upper thighs. Careful testing for loss of sensation should be made in all burned areas which are suspected of being of full-thickness.

The location of the burn should be taken into consideration when assessing the depth of skin destruction. Where the skin is normally thin and hair follicles do not extend far beneath the derma, as over the dorsum of the hands and feet, the anterior surface of the wrists, the malar bones of the face and around the eyes, minimal coagulation represents full-thickness destruction. In contrast, charred or leathery skin, without either sensation or visible circulation, does not necessarily indicate full-thickness destruction when it lies over the buttocks, sacral portion of the back, upper portion of the back of the thighs, and in the male over the chin, upper lips and cheeks. The skin of the buttocks, upper thighs and lower back is thick and tough; the hair follicles of the male beard extend well-beneath the derma.

No objective method of determining the depth of destruction of a burn has proven of aid to us. Among other methods we have tried the fluorescent ultraviolet lamp, as suggested by Dingwall<sup>9</sup> but since it depends upon the presence of the circulation of the blood at a visible level, it has proved no more useful in our hands than the naked eye.

In practice, any quandary over the depth of destruction can be resolved. In a patient with a burn of limited extent, where there is any doubt as to the depth of destruction, it is wise to err by exaggerating rather than depreciating the depth. If the burn is sufficiently deep to be under consideration as one of full-thickness, much time and disability will be saved by excising and grafting it immediately as a full-thickness burn wound. If one waits for the depth to become distinct, the temporizing may tempt the infection and the auspicious moment for getting the wound healed may be lost. Deep incomplete burns, like those of true full-thickness, are so susceptible to infection if the slough is left that much fibrous tissue proliferation in the derma and ugly and disabling scarring will form with spontaneous healing. The condition of the patient with a burn of limited extent should be such to enable him to stand the operation.

In a patient with extensive burns, some of which are of doubtful full-thickness destruction, it is best to depreciate rather than exaggerate the depth of these areas. They will have to be treated, temporarily at least, as of partial-thickness destruction while the veritable full-thickness areas are excised and grafted since the condition of the patient will be such as to enable him to stand just so much surgery and there will be only a meager amount of skin which will be unburned and available for use in grafting. By the time any doubtful

areas prove themselves to be of full-thickness destruction, the condition of the patient should be such as to enable him to stand further surgery, and more healed skin will be available for use in grafting.

2. *Chemotherapy as a Surgical Adjunct.*—Our appraisal of the value of the chemotherapeutic agents, the sulfonamides and penicillin, as adjuncts to the surgical management of full-thickness burn wounds is the result of a clinical impression and a statistical analysis of the bacterial flora cultured. The effect of these agents upon the bacterial flora will be described in a subsequent paper.<sup>2</sup>

In the partial-thickness burn wound of the skin with blebbing, it was possible to prove free permeation of the sulfonamides into the wound by analyzing the bleb fluid periodically. For as late as five days after injury the concentration of sulfadiazine rose as rapidly in the bleb fluid as in the blood serum following oral administration of the drug.<sup>10</sup> It has not been possible to make such an objective study of the full-thickness wound. The blue dye, T-1824, given intravenously is seen to pass rapidly, within ten minutes, into wounds of partial-thickness but only slowly into deep burns, and then it is found only in the base of the wound. Even after several days the dye has not penetrated far enough through the slough to show at the surface. This dye combines rapidly with the albumin of the serum<sup>11</sup> and its passage in the coagulum may well be retarded by the protein. Ionic radioactive sodium, however, requires many hours to enter the burn slough. (The details of the radioactive sodium studies are recounted in a subsequent paper.<sup>2</sup>) There is indirect bacteriologic evidence suggesting that penicillin does not penetrate the necrotic tissue. Even after prolonged penicillin therapy of high dosage (one to two weeks of 500,000 units per day), the excised slough has been found to contain the same penicillin-sensitive organisms recovered by smear culture at entry. After excision of the slough it has been found possible to eliminate effectively the streptococcus and sometimes the staphylococcus.

From the evidence available, it is suspected that chemotherapeutic agents do not permeate the full-thickness wound to a level comparable to that in the fluid of the partial-thickness wound. Although in neither wound are we sure that the agent enters the damaged cell, in the partial-thickness wound it is in the extracellular space in a therapeutic concentration and may serve to abort the growth of infecting organisms.

Clinical experience bears out the assumption of this difference between the partial- and full-thickness wounds. Infection has proven amenable to control in the partial-thickness wound but ungoverned in the full-thickness. As already stated, all of our full-thickness wounds which were not excised in the first days after inception have become infected in spite of the systemic administration of penicillin or the sulfonamides.

The high incidence of infection in the unexcised full-thickness wound does not mean, however, that penicillin, or the sulfonamides, are without beneficial effect and of no use. The prompt subsidence of invasive infection once penicillin was started in many of the cases in which chemotherapy had been withheld, and the absence of invasive infection in most of the cases in which peni-

cillin was started immediately following injury, indicate that this drug is a valuable adjunct to the surgical management of the deep-burn wound. Only in the cases where the contaminating organisms were not amenable to penicillin or where the depth of tissue destruction was such to damage the blood supply to the limb was invasive infection wholly uncontrolled.

3. *Operative Technic.—Anesthesia:* There is nothing peculiar to burn trauma which has influenced our choice of an anesthetic agent. A normal circulating blood volume and proven normal renal output have been requisites before any anesthetic has been administered. Gas-oxygen-ether, spinal procaine or pantocaine and intravenous pentothal have each been used. In patients with burns of the head and neck we have respected laryngeal edema and have insured an adequate air-way by using an intratracheal tube when administering a general anesthetic.

*Control of Hemorrhage:* During excision of the burn wound, control of hemorrhage has been arduous. If the excision is carried out in the first 48 hours, during the period of the development of edema, the bleeding is localized to a few arteries which can be easily tied. The edema may persist through the first week but later an inflammatory reaction, presumably the result of spreading infection, develops beneath the burn slough. Where the line of excision is carried into this inflammation, bleeding is profuse, there being many actively bleeding vessels. If the wound is extensive, large volumes of whole blood (as much as 1,750 cc.) may be lost at the time of the excision. It may be impossible to tie all of the small bleeders and control of the hemorrhage is achieved only by prolonged pressure.

In spite of meticulous hemostasis of the excised base immediately before laying the grafts and of applying a pressure dressing over the grafts, an occasional small hematoma has formed. Blood has dissected superficially into the graft, encouraged by the pressure holding the graft in place. Surprisingly, the hematomas have not prevented the successful take of the grafts and have only resulted in transient discoloration.

*Width and Depth of Excision:* In the excision of full-thickness burn wounds we have committed two technical errors. Failure to excise widely enough has occasioned delay in healing in three patients. We were too conservative in our interpretation of full-thickness destruction. We failed to excise small portions of the wound immediately adjacent to what was known to be full-thickness. Following spontaneous separation of the slough, additional grafts had to be placed to close the wound. In all three cases a little more radical excision could readily have been accomplished.

Failure to excise deeply enough made a secondary grafting procedure necessary in two patients and jeopardized the life of a third because gas gangrene developed in necrotic tissue in two legs not amputated when they should have been. In the first two cases the slough overlay the ankle and there was fear of damaging the tendons to the foot; an adequate excision would have avoided a granulating wound. In the third instance the necrosis involved tendons, muscles and the periosteum of the tibia, and although this deep

necrosis was recognized at the time of excision, we, unwisely, awaited spontaneous demarcation. The development of frank gas gangrene settled the question—débridement was carried out by amputation of both legs.

*Grafting Base:* The best base upon which to lay grafts is the one left after excision during the first hours after injury. This base may be made up of fatty or areolar tissue, fascia, muscle or periosteum. Even if the base is grossly edematous and exuding water, grafts may be laid directly on it with impunity. The grafts will not take, however, if a thin layer of dead tissue is left, that is, if the excision is not deep enough, or if the base is inflammatory. The longer the delay before excision the greater will be the inflammation.

4. *Homeostasis.*—Homeostasis is precarious in any patient with burns of more than limited extent and it must be effected and maintained not only, as always, to keep the patient alive but also to permit him to go through the surgery required to close his deep wounds promptly and to be in such good condition that his grafted skin will heal. The progress made in achieving homeostasis will be recounted in detail in subsequent papers.<sup>2</sup> Although the problem of achieving homeostasis early has been made more complicated by the operating attending early excision and grafting, this is more than compensated for later on by the elimination of infection, effecting good nutrition and early healing. We have tried staged operations, thinking that a number of short procedures rather than one long one would prove less insulting. We have no proof that this is generally effective.

DISCUSSION.—It is an extraordinary commentary on the passivity of the surgeon that he has been sitting on the sidelines for so many years watching the full-thickness burn wound degenerate into a bacterial quagmire when the means of healing it promptly by excision and grafting, a simple practice of his art, were at hand.‡ Are there any extenuating circumstances for his passivity? We cannot accept a fear of unseating homeostasis by an operation or the lack of chemotherapy as excuses. In patients with burns of limited extent there is no danger of producing shock and yet early grafting was not tried. Moreover, for many years it has been a common practice, in patients with extensive as well as circumscribed burns, to administer a general anesthetic when scrubbing the wounds before spraying tannic acid. It cannot have been the lack of a nontoxic chemotherapeutic agent because, as pointed out in this paper, penicillin is not even given a chance to play a rôle in the immediate closure of cir-

---

‡ This statement does not apply to Dr. Donald B. Wells who in 1929 published an article entitled "The Treatment of Electric Burns by Immediate Resection and Skin Graft" in which he described this treatment of three cases.<sup>12</sup> Dr. Wells' treatment resulted from what was learned in the war of 1914-18. He states, "The complete resection of gunshot wounds, more usually spoken of as débridement, and their immediate closure by primary suture or their delayed closure after a few days of chemical sterilization, was a technic developed and perfected during the World War. The application of this principle of complete resection and immediate closure by suture or skin graft to third degree electrical burns has not been reported in the literature, nor has it apparently ever been successfully applied so far as we have been able to learn after diligent inquiry among surgeons who must come into frequent contact with the results of electrical traumata."

cumscribed wounds. Immediate excision and closure precludes infection. It is only in the extensively burned patient, some of whose wounds must await their turn for closure, that a chemotherapeutic agent is needed.

The only explanations at hand for the failure of the surgeon to appreciate the potentialities of early surgical closure of the full-thickness burn wound are his fear of the loss of blood during the excision and the deep rooted fallacy that an unattached graft would survive only on a bed of granulation tissue. The plastic surgeon, who has for years placed free grafts successfully upon the freshly exposed surfaces left after excision of scars, will not be surprised to learn that the base left after excision of burn skin is just as good for the successful take of a graft.

A loss of blood in excising the burn wound is admitted. The volume lost increases with the age and extent of the wound but is never so large that it cannot be replaced. Hemorrhage, therefore, does not exclude surgical excision as a method of getting rid of burn slough. Doctors Connor and Harvey's chemical method of slough separation obviates the blood loss of excision but exchanges for it the loss of time, precious in preventing infection, and an inflammatory base upon which to lay grafts.

#### SUMMARY

Full-thickness burn wounds of the skin have always presented a challenge to the surgeon. Invariably infected, the patient has languished interminably in the hospital before successful closure has been achieved and, if the wounds were extensive, the patient has suffered from severe malnutrition.

If the challenge is met by prompt surgical excision of the dead tissue and immediate closure of the wound by grafting, infection is precluded, scar tissue with disfigurement and disability are minimized, the period of hospitalization is curtailed, manpower is economized and the outlook of the patient heartened.

The expeditious treatment of 52 full-thickness burn wounds in 38 patients by surgical excision and grafting at the Massachusetts General Hospital is recounted. Circumscribed burns of full-thickness have been excised and closed by grafting within a few hours after injury; the healing is most gratifying. In the wounds where a delay of days between injury and excision was introduced, infection insinuated itself in spite of the administration of systemic chemotherapy and delayed closure was resorted to in half the cases. The results have been surprisingly good. In the patients with extensive full-thickness wounds, homeostasis has been effected and maintained so that areas have been excised and grafted within the first few days. The care of the other areas has had to be postponed because of the precariousness of homeostasis and lack of sufficient donor skin for the grafting. The longer the delay in closure, the greater has been the infection, the less successful the take of the grafts, and the uglier and more disabling the scarring.

It is hard to convince any but the plastic surgeon, with his experience in excising old scars, that the best base upon which to place a graft is the one freshly exposed, even if edematous, after excision of burn slough.

The problem of the recognition of full-thickness destruction resolves itself with experience in practice.

Chemotherapy is a valuable adjunct in holding invasive infection in abeyance in those cases in which the excision and grafting must be delayed and in which the organisms are amenable. Its services are probably superfluous in those patients whose wounds are excised and grafted within the first hours after injury.

## REFERENCES

- <sup>1</sup> Management of the Coconut Grove Burns at the Massachusetts General Hospital. ANNALS OF SURGERY, 117, 801, 1943; and published as a monograph by J. B. Lippincott Company, Phila., 1943.
- <sup>2</sup> Manuscript in preparation for publication.
- <sup>3</sup> Connor, Gervase J., and Harvey, Samuel C.: The Pyruvic Acid Method in Deep Clinical Burns. ANNALS OF SURGERY, 124, 799, 1946.
- <sup>4</sup> Young, Forrest: Immediate Skin Grafting in the Treatment of Burns: A Preliminary Report. ANNALS OF SURGERY, 116, 445, 1942.
- <sup>5</sup> Ackman, Douglas, Gerrie, John W., Pritchard, J. E., and Mills, E. S.: A Report of the Management of Burns Using the Occlusive Compression Dressing, with Sulfathiazole Emulsion. ANNALS OF SURGERY, 119, 161, 1944.
- <sup>6</sup> Saltonstall, Henry, and Lee, Walter E.: Modified Technic in Skin Grafting of Extensive Deep Burns. ANNALS OF SURGERY, 119, 690, 1944.
- <sup>7</sup> McCorkle, H. J., and Silvani, Henry: Selection of the Time for Grafting of Skin to Extensive Defects Resulting from Deep Thermal Burns. ANNALS OF SURGERY, 121, 285, 1945.
- <sup>8</sup> Berkow, Samuel G.: A Method of Estimating the Extensiveness of Lesions (Burns and Scalds) based on Surface Area Proportions. Arch. Surg., 8, 138, 1924.
- <sup>9</sup> Dingwall, James A.: A Clinical Test for Differentiating Second from Third Degree Burns. ANNALS OF SURGERY, 118, 427, 1943.
- <sup>10</sup> Cope, Oliver: The Chemical Aspects of Burn Treatment. J. A. M. A., 125, 536, 1944.
- <sup>11</sup> Rawson, R. W.: The Binding of T-1824 and Structurally Related Diazo Dyes by the Plasma Proteins. Am. J. Physiol., 138, 708, 1943.
- <sup>12</sup> Wells, Donald B.: The Treatment of Electric Burns by Immediate Resection and Skin Graft. ANNALS OF SURGERY, 90, 1069, 1929.