

## MEDIASTINAL TUMORS\*

REPORT OF CASES TREATED AT ARMY THORACIC SURGERY CENTERS  
IN THE UNITED STATES

COLONEL BRIAN BLADES, M.C.

ONE HUNDRED AND NINE PATIENTS have been operated upon for mediastinal tumors at Army Thoracic Surgery Centers in the United States\*\* during a period of approximately three years. Numerically, the series seems meager when the potential patient population made up by millions of men and women in the military service is considered. Undoubtedly, the adoption of routine roentgenologic examination of the chest as a requirement for entrance to military service led to the detection, and immediate rejection, of many individuals with asymptomatic mediastinal tumors.

This report includes only cases in which either the clinical manifestations of an intrathoracic neoplasm or discovery of a mass in the mediastinum by roentgenologic examination after entrance on active duty resulted in surgical exploration of the chest. No attempt has been made to include all patients with mediastinal tumors treated in the United States Army or even in Thoracic Surgery Centers. Descriptions of neoplasms of lymphoid origin, namely, lymphosarcoma, Hodgkin's disease, lymphocytoma, *etc.*, have been omitted unless surgical intervention resulted from erroneous diagnosis.

*Types of Mediastinal Tumors.*—There were 94 benign and 15 malignant tumors in the group (Tables I and II).

### BRONCHIOGENIC CYSTS

Twenty-three bronchiogenic cysts have been removed from the mediastinum. It is of interest that this relatively rare lesion was encountered so often. Hare<sup>1</sup> found no record of bronchiogenic cysts in the mediastinum in 600 cases of mediastinal tumors recorded prior to 1899. In 1937, Alford<sup>2</sup> reported seven cases. Three years later, Heuer and Andrus<sup>3</sup> collected 25 cases from medical literature, and added one of their own. And, in 1945, Laipply<sup>4</sup> found that 34 cases of mediastinal cysts of the bronchial type had been reported, and described another case, making a total of 35 cases. Even if allowance is made for incorrect classification of cysts of the mediastinum, and one assumes that some cysts of bronchiogenic origin have not been so classified, it becomes apparent that these lesions are relatively rare.

---

\* Read before the Fifty-seventh Annual Session of the Southern Surgical Association, December 4-6, 1945, Hot Springs, Virginia.

\*\* Baxter General Hospital, Spokane, Washington; Brooke General Hospital, San Antonio, Texas; Fitzsimons General Hospital, Denver, Colorado; Kennedy General Hospital, Memphis, Tennessee; and Walter Reed General Hospital, Washington, D. C.

The Chiefs of the Thoracic Surgery Sections at these hospitals are, respectively, Major Thomas B. Wiper, Major Donald L. Paulson, Colonel John B. Grow, Lieut. Colonel Richard H. Meade, Jr., and Colonel Brian Blades.

*Location of Bronchiogenic Cysts of the Mediastinum.*—The cysts may be located at almost any site along the tracheobronchial tree. In one case, not included in this series because the tumor was not in the mediastinum, a bronchiogenic cyst was located on the diaphragm, and there was no demonstrable connection between it and the lung or the mediastinum. When the mediastinum is involved, the most common location of the cyst is in the superior mediastinum near the tracheal bifurcation. The tumor may occupy either an anterior or posterior position. A patent lumen communicating with the trachea or bronchi could not be demonstrated in any of our cases.

TABLE I  
BENIGN MEDIASTINAL TUMORS

Type of Tumor	No. of Cases
Bronchiogenic cysts.....	23
Dermoids and teratomas.....	14
Primary nerve tumors.....	29
Pericardial cysts.....	10
Thymomas.....	4
Lymph nodes*.....	4
Lipomas.....	3
Thyroid adenomas.....	2
Esophageal cyst.....	1
Tuberculomas.....	2
Sarcoid*.....	1
Fibroma.....	1
<b>Total.....</b>	<b>94</b>

\* Biopsy of tissue, tumor not removed.

TABLE II  
MALIGNANT MEDIASTINAL TUMORS\*

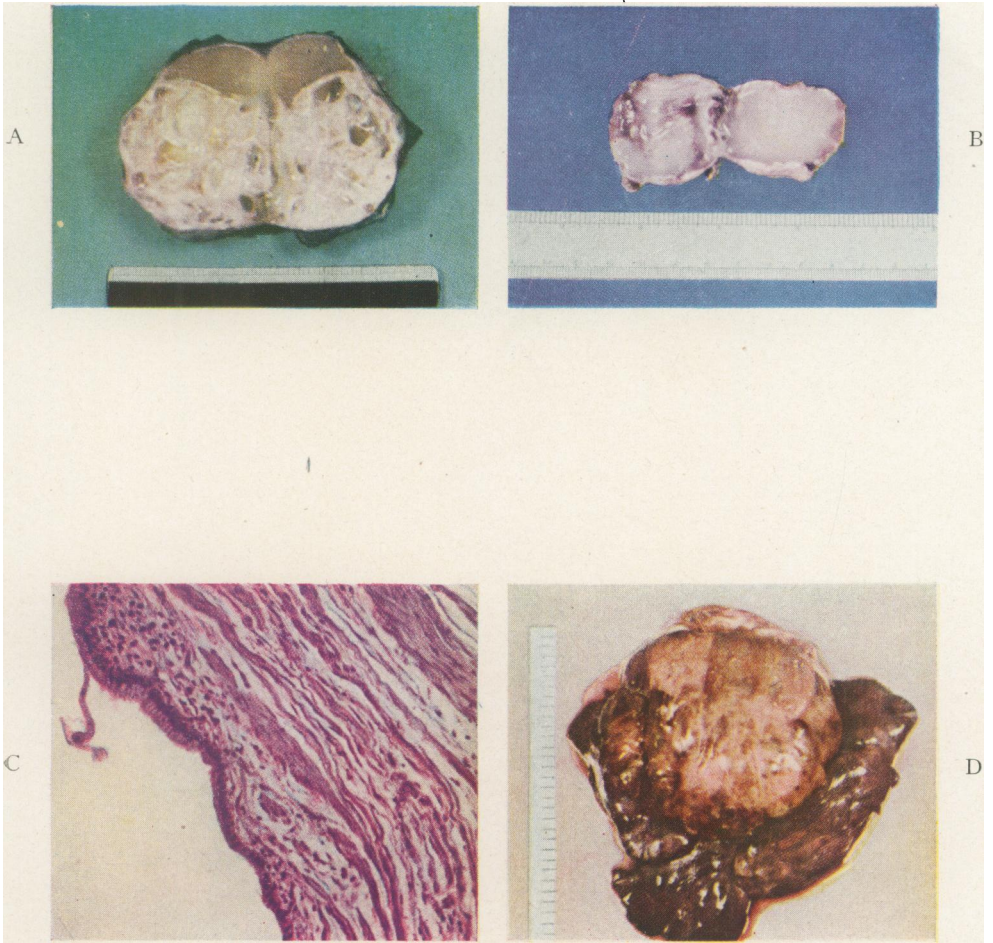
Type of Tumor	No. of Cases
Teratomas.....	6
Thymomas.....	2
Neurosarcoma.....	1
Lymphoblastomas.....	2
Hodgkin's disease.....	4
<b>Total.....</b>	<b>15</b>

\* Extensive invasion of the tumor precluded even partial removal in all except three cases.

*Clinical Manifestations.*—Pain in the chest is the most common symptom of a bronchiogenic cyst. The pain is usually not severe, and its location is often substernal. Another common complaint is cough. Only two of the 23 cases considered in this report had clinical manifestations of intrathoracic disease. The mass was detected on roentgenologic examination in the remainder of the group.

*Roentgenologic Examination.*—An accurate preoperative diagnosis of a bronchiogenic cyst depends almost entirely on roentgenologic examination. Even with careful roentgenologic examination, the true nature of the lesion is

PLATE I



- (A) Photograph of semi-solid bronchiogenic cyst of the mediastinum.
- (B) Photograph of thin-walled bronchiogenic cyst filled with mucus.
- (C) Microscopic appearance of bronchiogenic cyst.
- (D) Photograph of tumor and right middle lobe after removal.

difficult to establish. On the frontal projection the mass may resemble a teratoid tumor or a primary nerve tumor (Fig. 1). The lateral roentgenogram is of more diagnostic significance, however, since the extreme posterior position common in most primary nerve tumors will not be duplicated by bronchiogenic cysts and, usually, the shadow of the mass on the lateral projection is not so distinct as is the case with teratoid tumors. Brown and Robbins<sup>5</sup> have emphasized the importance of examination with the fluoroscope in establishing the diagnosis of a bronchiogenic cyst. Since most bronchiogenic cysts are attached to the trachea, the mass will move with the act of swallowing. This

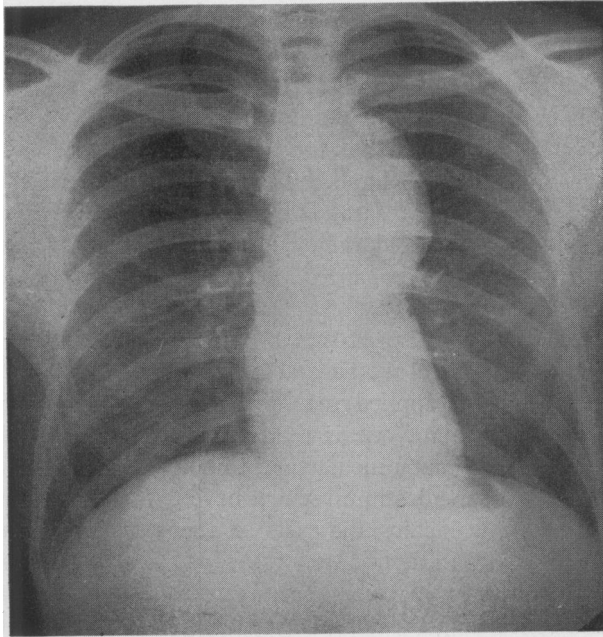


FIG. 1.—Roentgenogram of bronchiogenic cyst.

can be demonstrated during fluoroscopy, and is of some significance as a diagnostic point. Roentgenograms made by the Potter-Bucky technic, visualization of the esophagus with barium sulfate to determine the relationship of the mass to the esophagus, delineation of the bronchial tree with radio-opaque oil, and other methods of roentgenologic diagnosis are sometimes useful.

*Gross Appearance of Bronchiogenic Cysts.*—Bronchiogenic cysts are round or ovoid masses, and may be located in any part of the mediastinum. They are usually attached to the carina or a bronchus by a stalk. It is sometimes very difficult to identify this attachment. The cysts may vary from thin-walled tumors filled with clear fluid to almost solid neoplasms (Plate I, A and B). Other descriptive terms which have been employed for these lesions are ciliated epithelial cysts and reduplication cysts of the respiratory tract.

All evidence suggests that bronchiogenic cysts are the result of developmental abnormalities, either from the pinching-off of a diverticulum of the foregut near the tracheal bud or a secondary development of the tracheal bud itself, resulting in an abnormal division of the tracheobronchial tree as growth proceeds. Similar theories have been suggested to explain the formation of esophageal, gastric and gastro-enteric cysts of the mediastinum. If these theories are accepted, it is understandable that occasionally a bronchiogenic cyst appears to be attached to the esophageal wall. Womack<sup>6</sup> has suggested that available evidence indicates that bronchiogenic cysts represent "a regional disorganization in the vicinity of the developing trachea and foregut."

*Microscopic Appearance.*—Bronchiogenic cysts may contain any or all of the tissues which are normally present in the trachea and bronchi. The walls contain fibrous connective tissue and sometimes mucous glands, cartilage and smooth muscle. Stratified squamous epithelium or more typically ciliated pseudostratified epithelium forms the lining of the cyst. The fluid in the cyst may vary from clear, water-like liquid to viscid gelatinous material (Plate I, C).

*Treatment.*—Unless the age and general condition of the patient precludes a major operation, the proper treatment of bronchiogenic cysts is surgical extirpation. If the cyst is not infected, removal is usually easy. Technical difficulties are increased by the presence of infection, but this complication makes operative interference imperative.

The objection might be raised that if the tumor causes no symptoms, it should be left alone. There are several excellent reasons why the watchful waiting policy cannot be applied safely in the management of mediastinal tumors. The most important one is that it is impossible to make a positive diagnosis of any asymptomatic mediastinal tumor before the mass is removed. Many neoplasms of the mediastinum which have grave potentialities of malignant change resemble bronchiogenic cysts on roentgenologic examination, for example, the teratomas and thymic tumors. There is also the possibility of the cyst becoming infected or increasing in size, producing pressure symptoms. No reliable data concerning the incidence of malignant change in bronchiogenic cysts are available, but these lesions may be considered correctly cell rests. There is no reason, therefore, to believe that malignant changes could not occur. It is quite possible that highly malignant tumors which in the past have been catalogued under the somewhat ambiguous term—"carcinoma of the mediastinum,"—may have originated in bronchiogenic cysts. These neoplasms are at least first cousins of the teratoid tumors, both developmentally and histologically. The frequency of malignant change in dermoids and teratomas is well known.

#### DERMOIDS AND TERATOMAS OF THE MEDIASTINUM

Harrington<sup>7, 8</sup> has simplified the terminology in discussing dermoids and teratomas of the mediastinum by employing the inclusive term—teratoid tumors. He chooses "teratoid" because most of these neoplasms contain elements of three germinal layers.

Twenty patients with teratoid tumors have been operated upon at Army

Thoracic Surgery Centers. In 14 cases the tumor was benign. Far advanced malignant changes were evident in six cases.

Teratomas and dermoids of the mediastinum are relatively common tumors. More than 245 cases are recorded in medical literature. With the exception of tumors of lymphatic origin, which are usually not treated by surgical removal, the teratoid tumors are the most common neoplasms of the anterior mediastinum. Teratoid tumors usually produce sharp and obvious roentgenographic

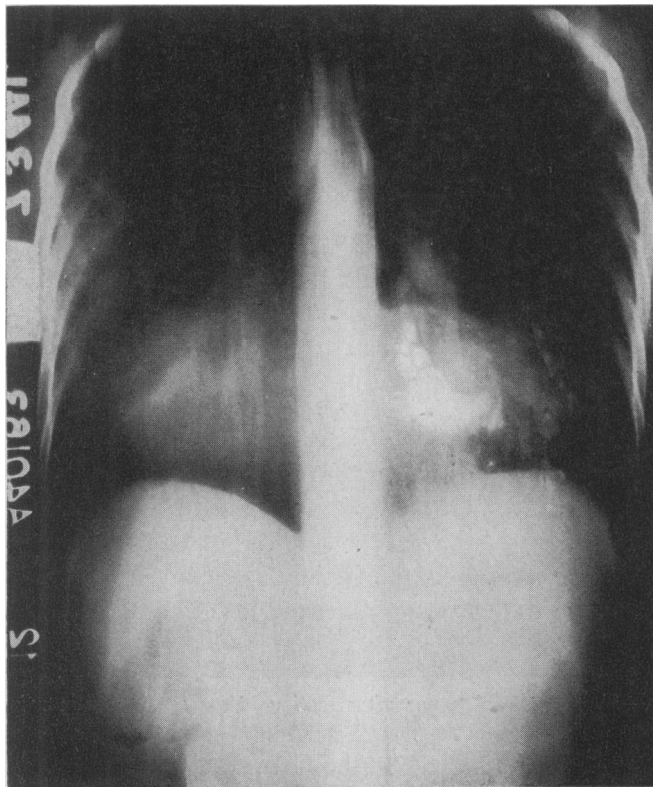


FIG. 2.—Laminogram showing teeth in teratoma.

shadows which are easily detected. The relatively low incidence of teratoid tumors in members of the military service is easy to explain. Discovery of the tumor on roentgenograms of the chest made at the time of induction examinations resulted in immediate rejection.

*Symptoms.*—Cough and chest pain are the most common symptoms. In one of our cases the tumor had invaded the right middle lobe of the lung. The patient was admitted to the hospital for the treatment of hemoptysis.

**Case 1.**—A 28-year-old woman was admitted to the hospital for treatment of hemoptysis. The history revealed that she had coughed up blood over a period of 15 years, and for the past two or three years had occasionally coughed up large amounts of pus. Roent-

genograms of the chest revealed a mass in the right lower chest. Visualization of the bronchi of the right lung revealed some bronchiectasis of the right middle lobe and, on bronchoscopic examination, pus could be seen coming from the middle lobe bronchus.

A diagnosis of teratoma of the mediastinum, with erosion into the right middle lobe, was made. Exploratory thoracotomy revealed a teratoma of the anterior mediastinum attached to the right middle lobe. A right middle lobe lobectomy was performed and the tumor was removed with the lobe. The postoperative course was complicated by the development of suppurative pleuritis. The empyema healed after adequate drainage (Figs. 2 and 3 and Plate I, D).

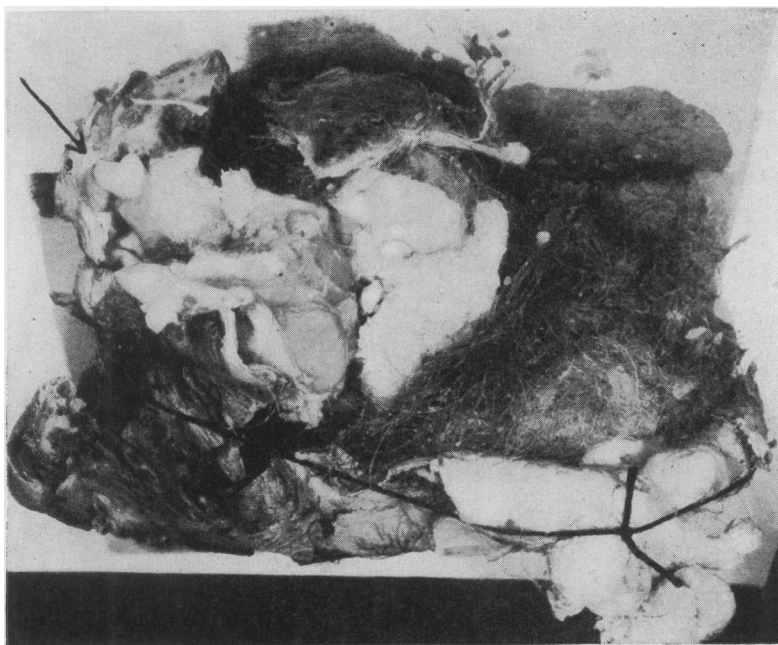


FIG. 3.—Photograph of tumor after section. Note teeth in tumor indicated by arrow.

Other clinical manifestations of teratoid tumors, including symptoms caused by pressure effects, namely, cough, dyspnea, and enlargement of the neck veins, are described in several excellent articles on dermoid cysts and teratomas of the mediastinum.

*Roentgenologic Examination.*—Unless teeth or bone are visible on the films, the exact diagnosis of the teratoid tumor cannot be made by roentgenologic examination. The characteristic anterior position of the mass is suggestive but not conclusive.

*Location and Gross Characteristics of Mediastinal Teratoid Tumors.*—Mediastinal dermoids and teratomas almost always occupy an anterior position. In fact, there are only three cases reported in which the mass was not in the anterior mediastinum. There is nothing particularly characteristic about their size or shape, and, as is the case with bronchiogenic cysts, the structure of

teratoid tumors may vary from thick-walled cysts containing fluid to solid tumors. Ectodermal derivatives, such as hair, skin or teeth, may form part of the tumor. Teratoid tumors are thought to take origin from cell rests. Bronchiogenic elements which are drawn into the thorax by the descent of the heart and diaphragm may account for the development of some of these neoplasms. Complex neoplasms with three embryonal layers, however, cannot be accounted for by this theory. Another popular hypothesis is that there is a second independent embryonal analage existing as a parasitic fetus *in fetu*. This theory would explain the complex teratoma while the monogerminal furnishes a satisfactory concept of the formation of a simple dermoid.

*Microscopic Appearance.*—Elements of the endoderm, ectoderm and mesoderm may be found in teratomas. Varying combinations of tissue from the digestive tract, respiratory system, thyroid or even thymus may be identified.

*Treatment.*—The treatment is surgical extirpation. Roentgenotherapy is of no value in the treatment of benign teratoid tumors and is probably equally ineffectual when malignant changes have occurred. The dangers of malignant degeneration are considerable. Laipply<sup>4</sup> has reviewed the literature and found that 28 (11.4 per cent) of 245 cases of teratoid tumors were malignant. Heuer and Andrus<sup>3</sup> report malignant changes in five of their 13 cases. Six of 20 tumors in this series had undergone malignant change and were hopelessly inoperable. The necessity for surgical extirpation of these neoplasms before they become malignant is obvious. Rusby,<sup>9</sup> in his excellent article on dermoids and teratomas of the mediastinum, has described the various therapeutic endeavors which were employed before radical surgical excision was reasonably safe. He also emphasizes that collective data place the incidence of malignant change at 12.9 per cent and, that once the conversion from benignity to malignancy has taken place, the possibility of successful treatment is remote.

#### PRIMARY NERVE TUMORS

Twenty-nine benign neurogenic tumors of the mediastinum, including neurofibromas, ganglioneuromas, sympathicoblastomas, *etc.*, have been removed successfully. One patient with a neurogenic sarcoma was operated upon, but invasion of surrounding structures precluded removal.

Neoplasms of neurogenic origin are by far the most common posterior mediastinal tumors. Kent and his coworkers<sup>10</sup> were able to collect 105 cases in medical literature.

*Clinical Manifestations.*—Benign primary nerve tumors are usually asymptomatic. Occasionally involvement of certain nerves may cause pain; if the sympathetic chain is involved, Horner's syndrome may be evident. Too often, however, definite clinical manifestations of intrathoracic disease indicate malignant degeneration of the tumor.

*Roentgenologic Examination.*—The roentgenographic shadow of a primary nerve tumor may be round, spherical or lobulated. The typical extreme posterior position of the tumor is characteristic. Roentgenologic examination should include studies of the spine for bone erosion and evidence of so-called dumb-



bell tumor. The shadow on the roentgenogram is usually sharply circumscribed, both on frontal and lateral projections (Fig. 4 and Plate II, A and B).

*Gross Appearance and Location.*—The characteristic extreme posterior position of primary nerve tumors of the mediastinum has already been mentioned in the discussion of the roentgenologic examination. It is of interest that only two examples of primary nerve tumor in an anterior location have been recorded in medical literature.

If the neoplasm arises in the intervertebral foramina and extends both into the spinal canal and out into the posterior mediastinum, there will be an hour-

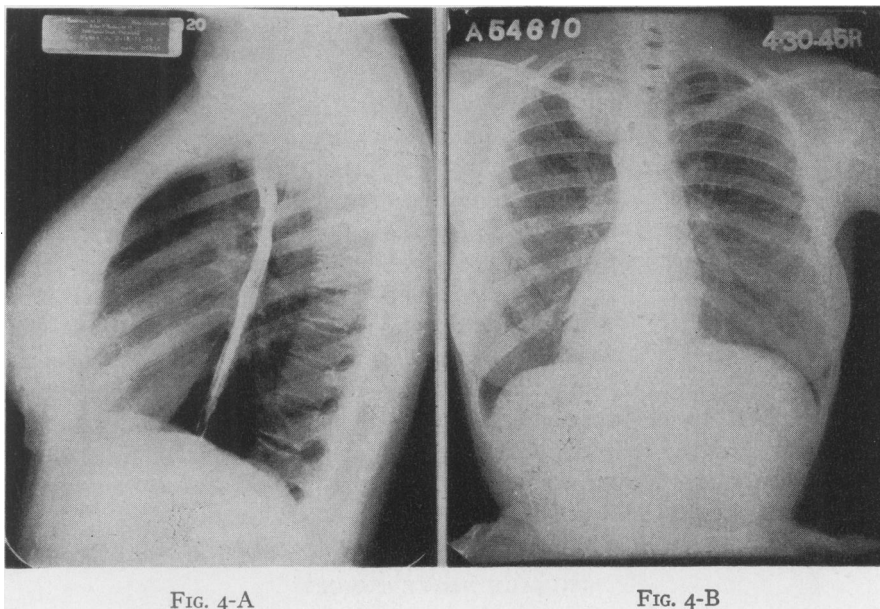
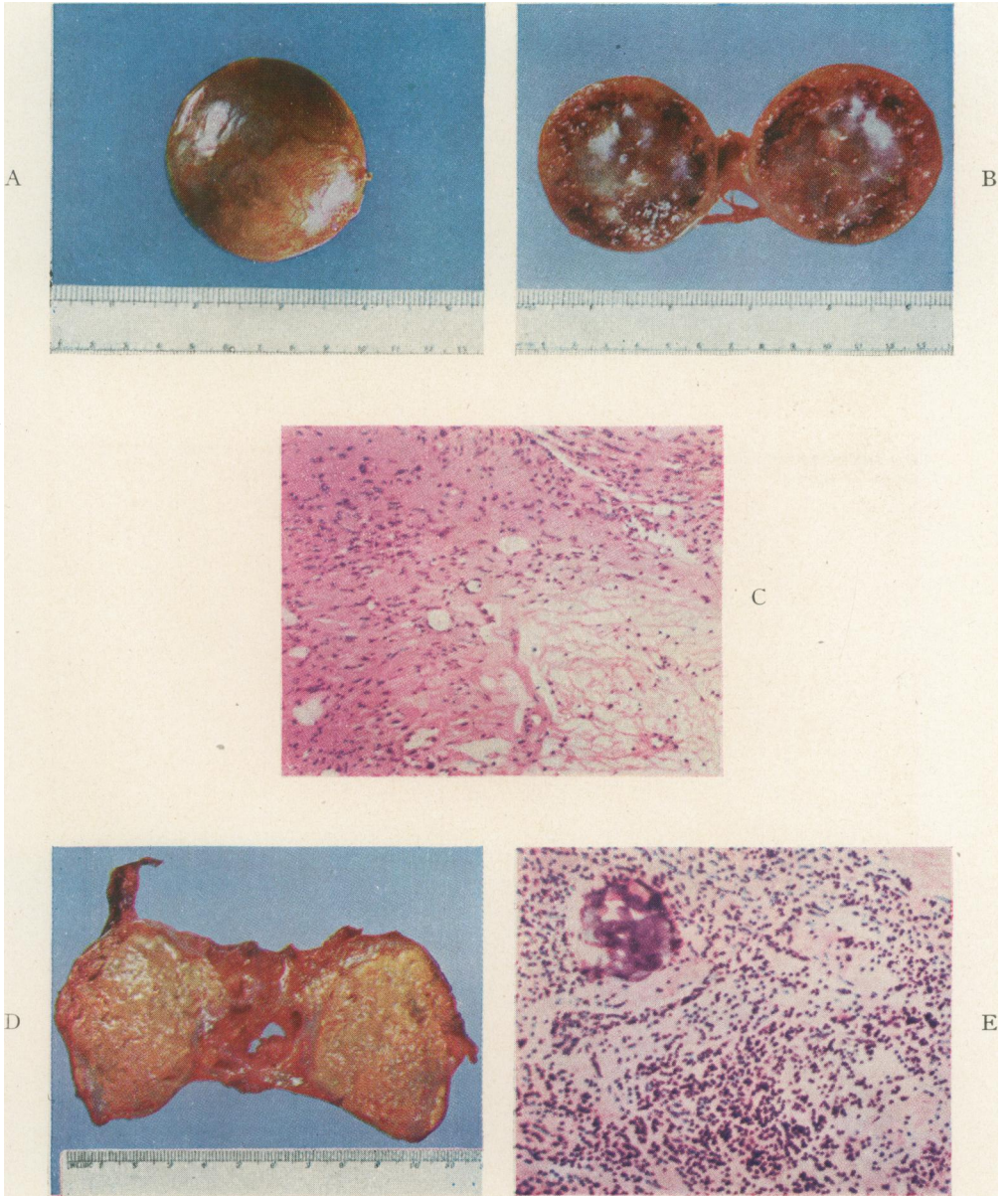


FIG. 4.—Roentgenograms showing typical posterior position of primary nerve tumors of the mediastinum.

glass or dumb-bell configuration. The extension into the spinal canal is seldom evident on roentgenologic examination, and may even be difficult to detect when the tumor is exposed at operation. This possibility must always be given careful consideration. The sites of origin of the tumor are commonly from the intercostal and sympathetic nerves, although any nerve may be involved.

*Microscopic Appearance.*—There is wide variance in the microscopic appearance of primary nerve tumors. Preponderance of fibrous tissue in some has resulted in the descriptive term—ganglioneurofibroma. In others, numerous ganglion cells can be seen, and these tumors are usually called gangliogliomas. Lack of differentiation with cellular reticulomyxomatous tissue may produce a microscopic appearance compatible with myxoid neuromas. Frank malignant degeneration is seen in neurofibrosarcomas. The degree of malignancy is difficult to determine, either on gross or microscopic examination. All

PLATE II



- (A & B) Photograph of neurofibroma of mediastinum after removal.  
(C) Microscopic appearance of neurofibroma of mediastinum.  
(D) Cut section of thymoma.  
(E) Microscopic appearance of thymoma. Note Hassall's corpuscle.

primary nerve tumors of the mediastinum have a tendency to recur with increasing malignant characteristics if incompletely excised (Plate II, C).

*Treatment.*—Kent, et al.,<sup>10</sup> have reviewed the medical literature and studied the cases of neurogenic tumors of the chest seen at Graham's Clinic, in St. Louis. They found that 37 per cent of reported primary nerve tumors of the thorax had undergone malignant change. Forty-one per cent of the cases of primary nerve tumor of the chest seen at the Barnes Hospital, St. Louis, were malignant. Even if one assumes that a large surgical center would attract more difficult and complicated cases and that there has been a tendency to report malignant and complicated cases, it is apparent that primary nerve tumors are dangerous. Once malignant degeneration has occurred, the prognosis is grave and, in most cases, hopeless. The correct treatment is surgical excision before the tumor is malignant. Roentgenotherapy is futile in both benign and malignant varieties of neurogenic tumors.

#### PERICARDIAL CYSTS

Ten pericardial cysts are included in the series.

*Clinical Manifestations.*—Discovery of the tumor in all of the cases resulted from routine roentgenologic examination. The cysts were asymptomatic.

*Roentgenologic Examination.*—Except for their anterior position, there is nothing characteristic about the roentgenographic appearance of pericardial cysts to differentiate them from other mediastinal cysts.

*Location and Gross Appearance.*—Pericardial cysts are thin-walled structures, usually in contact with the anterior chest wall and the parietal pericardium. Occasionally, they may be large enough to impinge on the lung or diaphragm. Anomalous development of the pericardium probably explains their formation.

*Microscopic Appearance.*—The walls of the cysts are made up of fibrous connective tissue lined by a layer of flattened endothelial or mesothelial cells. It is probable that, in the past, some of these cysts have been classified as cystic hydromas or cystic lymphangiomias.

*Treatment.*—Since surgical extirpation is the only means of establishing the benignity of a mediastinal tumor, operation should be recommended. None of the patients included in this report complained of symptoms referable to the cyst. There is only one case reported in the literature in which symptoms were attributed to a pericardial cyst. Pickhardt<sup>11</sup> describes a patient who complained of persistent thoracic pain which was relieved when a pericardial cyst of the anterior mediastinum was removed.

#### THYMOMAS

Six tumors of thymic origin have been studied. In four instances the lesion appeared to be benign. One patient with advanced myasthenia gravis was operated upon by Lieut. Colonel Meade, at the Kennedy General Hospital. A malignant thymic tumor was found, and could not be removed completely.

*Clinical Symptoms.*—Four of the six patients with thymic tumors had no symptoms referable to the mediastinal mass. The neoplasms were discovered on roentgenologic examination.

**Case 2.**—The patient, a young Negro, complained of nervousness and inability to work. A diagnosis of psychoneurosis, anxiety type, had been made overseas and the patient was returned to the United States. A mediastinal tumor was discovered on a roentgenogram made during examination for separation from military service. Unfortunately, the patient's complaints were minimized, and prostigmine tests were not made before the operation. It was not until the neoplasm was removed and the diagnosis of thymic tumor established that my failure to appreciate the possibility of myasthenia gravis in this patient became so painfully apparent (Plate II, D and E).

*Roentgenologic Examination.*—There are no definite criteria for the positive diagnosis of thymic tumors. Hampton<sup>12</sup> has made the important observation, however, that in many cases the tumor has a tendency to maintain the shape of thymus, as seen in roentgenograms of children. Another suggestive finding is that often the tumor is easily seen in the frontal projection but is not so apparent on lateral roentgenograms. The thymus is a flat, thin structure. Even when its dimensions are distorted by tumor formation, the shadow on the lateral projection is difficult to detect.

*Location and Gross Appearance.*—Thymic tumors are usually located in the anterior mediastinum in the substernal position; however, in one case in our series, the neoplasm was situated posteriorly. The gross appearance may vary considerably. Characteristically, the tissue is of reddish-gray color. The tumors originate in the neck, are commonly in the superior mediastinum, but may extend almost to the diaphragm.

*Microscopic Appearance.*—The microscopic appearance of thymic tumors varies greatly. In benign lesions the cells may be composed of somewhat disarranged but otherwise practically normal thymic tissue. Some malignant thymomas may have the appearance of a malignant lymphoma, while others of the reticulum cell variety are made up of endodermal thymic reticulum cells. Still other malignant varieties resemble epidermoid carcinoma or teratoid tumors, depending upon which element of the thymus predominates.

*Treatment.*—Treatment may be either surgical extirpation or radiation therapy, depending upon the type of thymic tumor. The rôle of radiation therapy in the treatment of thymic tumors will be considered in the discussion of therapeutic management of all mediastinal tumors. If the lesion does not respond to radiation therapy, surgical excision should be undertaken.

#### LIPOMAS OF THE MEDIASTINUM

Only four mediastinal lipomas have been removed. This is not surprising, since less than 40 cases have been recorded in medical literature.<sup>13, 14</sup>

*Symptoms.*—Symptoms referable to lipomas of the mediastinum are those common to any mediastinal tumor, namely, pain, dyspnea or cough, depending upon the size and location of the mass. A long history of slowly progressing pressure symptoms may suggest a slowly enlarging fatty tumor.

*Roentgenologic Examination.*—There are no distinctive diagnostic features of the roentgenologic examination for lipoma of the mediastinum. Heuer and Andrus<sup>8</sup> were able to predict the true nature of a mediastinal lipoma in two of their cases because the shadow of the mass on the roentgenograms became less opaque toward the periphery. This finding suggested to them that

the tumor was composed of fat because it was more readily penetrable than the compact tissue of other tumors of the mediastinum.

*Location and Gross Characteristics.*—Lipomas of the mediastinum have been divided into three groups according to their location and form: (1) Tumors confined within the thoracic cage; (2) intrathoracic lipomas which extend upward into the neck; and (3) intrathoracic tumors with an extrathoracic extension forming a dumb-bell configuration. In one case in this series there was extension into the neck.

*Microscopic Appearance.*—The microscopic appearance of a lipoma requires no comment.

*Treatment.*—Lipomas may grow to huge size. Watson and Urban<sup>14</sup> have recorded the successful removal of a lipoma which weighed 6.8 pounds. The same authors mention a case in which an intrathoracic lipoma, weighing 17 pounds and 6 ounces, was discovered at postmortem examination.

#### MISCELLANEOUS TUMORS

Other varieties of mediastinal tumors found in army personnel include: One tumor classified as a fibroma (probably a neurofibroma); one thyroid adenoma; two tuberculomas of the mediastinum; one cyst arising from the esophagus; and an osteochondroma of the mediastinum. In three cases, enlarged inflammatory lymph nodes were discovered when the chest was opened to establish the nature of an intrathoracic mass. And in one instance biopsy of tissue of hilar mass revealed Boeck's sarcoid.

#### MALIGNANT TUMORS OF THE MEDIASTINUM

Fourteen malignant tumors of the mediastinum were found; including six malignant teratomas, two thymomas, one neurosarcoma, two lymphoblastomas and four Hodgkin's disease. With the exception of three cases, it was impossible to remove the tumor. It is surprising, and interesting, that in three cases tumors were removed, which proved, upon microscopic examination, to be Hodgkin's granuloma. In one case, operated upon by Major Paulson, at the Brooke General Hospital, the tumor had invaded the upper lobe and it was necessary to perform an upper lobe lobectomy, when the neoplasm was removed.

In two instances mediastinal tumors of unknown origin were extirpated. Microscopic examination of the tissue revealed Hodgkin's disease. One patient was operated upon by Colonel Grow, at the Fitzsimons General Hospital, the other at the Walter Reed General Hospital.

**Case 3.**—The patient, a 27-year-old white male, had had three years and three months of active military service. He was first admitted to a hospital for the treatment of frozen feet, after evacuation from the combat zone to England. At that time there was no history of chest pain, loss of weight or other indications of intrathoracic disease. The condition of his feet made it necessary for him to be moved to the Zone of Interior. While on furlough after returning to the United States, he lost weight and occasionally had low-grade fever with night sweats. A roentgenogram of the chest revealed a mass in the posterior mediastinum (Fig. 5). The possibility of Hodgkin's disease was not considered seriously.

The thorax was explored through a right posterolateral incision. A large mass was found in the posterior mediastinum. The mediastinal pleura was dissected from the mass and the mass removed by sharp and blunt dissection. The tumor had a lobulated appearance and was obviously of a malignant nature. There were many palpable lymph nodes near the pulmonary hilum (Plate III, A, B and C).

After excision of the mediastinal tumor, which proved to be Hodgkin's disease, radiation therapy was administered as soon as the incision of the chest wall had healed. During the following eight months, the patient gained 20 pounds. He has had no fever. There is no evidence of recurrence of the tumor on roentgenologic examination. He complains of some shortness of breath and occasionally notices a tight sensation in the chest.

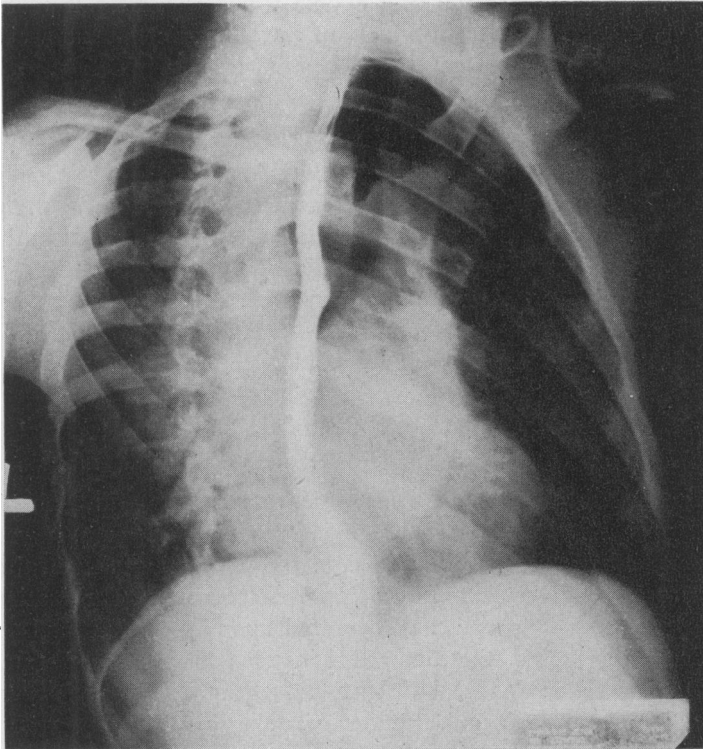
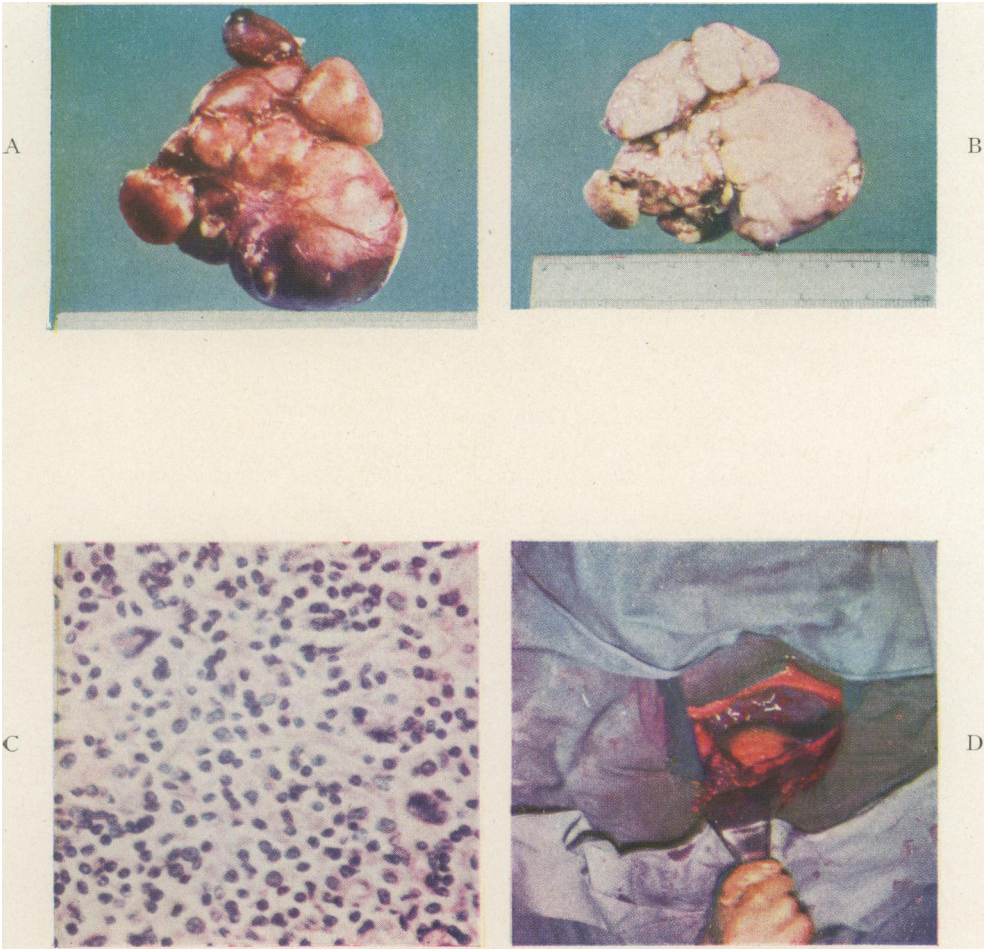


FIG. 5.—Roentgenogram of tumor which proved to be Hodgkin's disease.

In the similar case operated upon by Colonel Grow, at the Fitzsimons General Hospital, radiation therapy was withheld, and it is planned to administer it when there is sign of recurrence. This patient has been under observation for a period of approximately nine months, with no evidence of recurrence of the tumor. It should be emphasized that surgical intervention would not have been recommended in any of these cases had the true nature of the lesion been established. It appears, however, that these patients have not been harmed, and probably have been benefited, by having the visible tumor removed. No



PLATE III



- (A) Photograph of tumor after removal.  
(B) Cut section of mediastinal Hodgkin's disease.  
(C) Microscopic appearance of tissue.  
(D) Photograph taken at the operating table of exposure of a neurofibroma of the mediastinum by the posterolateral approach.

conclusions can be drawn concerning the results in any of the cases until they have been observed for a long period of time.

In the other cases of malignant neoplasms of the mediastinum, the tumor had invaded adjacent structures and the lesions were hopelessly inoperable. Tissue for microscopic study was obtained and the thorax closed.

#### RADIATION THERAPY AND SURGICAL TREATMENT OF MEDIASTINAL TUMORS

Unfortunately, there is no infallible method to determine preoperatively the exact nature of a mediastinal mass. Therapeutic endeavors are limited to radiation therapy and surgical removal. It is apparent, therefore, that the first decision which must be made is the choice between these two methods of treatment. For many years there has been a tendency to treat mediastinal tumors primarily by radiation therapy. If there was no effect upon the neoplasm, radiation therapy was abandoned and the possibility of surgical intervention considered.

Before refinements in operative and anesthetic technics made the exploration of the chest safe, this attitude was understandable. The accumulated reticence of physicians to recommend exploratory thoracotomy has probably resulted, however, in the injudicious use of radiation therapy in many cases.

Surgeons and radiologists experienced in thoracic disease should be able to predict in the majority of cases whether roentgentherapy will be successful. Even if errors in diagnosis occasionally result in thoracic exploration for tumors which will respond to radiation therapy, the danger to the patient from the operation is slight when compared to the deleterious effects of prolonged and ineffectual radiation therapy. Most benign tumors of the mediastinum and some malignant neoplasms are amenable to surgical removal. Radiation therapy will fail to reduce the size or to halt malignant degeneration of mediastinal tumors unless they are of lymphatic origin. Moreover, after prolonged exposure to roentgentherapy, the removal of the lesion will be more difficult and hazardous.

It is usually possible to make a tentative and reasonably accurate diagnosis of a mediastinal tumor of lymphatic origin. With few exceptions these are the only mediastinal tumors which will respond to radiation therapy. Neoplasms of lymphatic origin have a far greater tendency to produce clinical symptoms early and their roentgenographic appearance is fairly characteristic. If, after a test dose of roentgentherapy the neoplasm decreases in size, it can be assumed that it is of the lymphoma group and surgical intervention is not indicated. Properly employed, radiation therapy is invaluable, both as a therapeutic and diagnostic measure. Continued injudicious radiation, however, may be disastrous, and if after a fair trial the tumor is not affected, the method should be discontinued. Friedman,<sup>15</sup> at the Walter Reed General Hospital, recommends an initial test dose of 750 r delivered to the center of the tumor. It should be emphasized, however, that about one-third of malignant lymphomas will require as much as 1500 r to affect the tumor. If, after a period of approximately one month, there is no change in the size of the tumor, thoracic exploration should be performed to determine the exact nature of the lesion.



## EXPLORATORY THORACOTOMY

The choice between radiation therapy and surgical intervention will, of course, depend largely upon the risk of exploratory thoracotomy. It can be stated categorically that the danger of exploration of the mediastinum is trivial provided qualified anesthetists and surgeons are available and if the patient is in reasonably good general condition. If operation is delayed until signs and symptoms of pain, enlargement of the tumor, *etc.*, are apparent, the opportunity for successful extirpation of the lesion will usually have been lost.

The relative safety of a properly performed exploratory thoracotomy is demonstrated by our results, and the experiences of others. It is admitted that the majority of patients in our series are young men and are, therefore, good risks for major operations. In a total of 114 exploratory operations to determine the nature of a mediastinal mass (including five cases of aneurysms in which a correct preoperative diagnosis was not made), there were no deaths which could be attributed to the exploratory operation. There were no post-operative complications in patients upon whom an exploration and biopsy was performed. In three cases in which a tumor was removed, suppurative pleuritis developed. Adequate drainage of the empyema resulted in prompt healing. In one of these cases previously described, it was necessary to remove an infected right middle pulmonary lobe which had been eroded by a teratoma.

## OPERATIVE TECHNIC

Ordinary fundamental principles of surgical technic apply to the extirpation of mediastinal tumors. Adequate exposure and precise, gentle handling of tissues is especially important.

One controversial detail in surgical technic is the route for effecting entry into the thorax. Some surgeons employ routinely the posterolateral approach to remove mediastinal tumors. Others prefer an anterior approach for tumors situated in the anterior mediastinum and reserve the posterolateral approach for lesions situated posteriorly. It is interesting that in the five Thoracic Surgery Centers in the Army there was never complete agreement concerning the preferable method for exposing a mediastinal tumor. Paulson, at the Brooke General Hospital, reflected his early training with Harrington by using a posterolateral approach for practically all mediastinal tumors. At the Fitzsimons, Kennedy and Walter Reed General Hospitals both the anterior and posterior incisions were employed, depending upon the location of the tumor. There is complete agreement, however, that if technical difficulties are anticipated, the anterior approach may provide inadequate exposure and a lateral or posterolateral incision is preferable (Plate III, D).

The surgical removal of benign mediastinal tumors is usually relatively easy. Huge benign tumors occasionally present difficulties. If the neoplasm has undergone malignant change, surgical removal is usually impossible. Even if a malignant tumor can be removed, the operation is often only a palliative measure.

*Anesthesia.*—Details of anesthetic technic and a discussion of the various

anesthetic agents is not in the province of this report. Unhurried and safe surgery in the thorax requires expert anesthesia. The proper administration of intratracheal anesthesia makes the exploration of the chest and mediastinum as easy and as safe as exploration of the abdomen.

SUMMARY AND CONCLUSIONS

One hundred and fourteen explorations of the thorax have been performed at Army Thoracic Surgery Centers to establish the nature of mediastinal masses. In five cases the mediastinal tumors proved to be aneurysms. Biopsies of benign inflammatory lesions were obtained in five instances. Eighty-nine benign tumors of the mediastinum were removed successfully. In three of 15 cases of malignant tumors of the mediastinum, the mass was removed. In the remainder of malignant tumors, extirpation of the neoplasm was impossible. There were no deaths attributable to exploration of the thorax. All patients with benign tumors recovered promptly and returned to full activity.

Mediastinal tumors are relatively rare lesions, yet the routine roentgenologic examination of the chest has led to the detection of 94 of 109 cases of mediastinal tumors in this series. It is apparent that if this large number of neoplasms of the mediastinum were found in apparently healthy young men that the universal application of routine roentgenologic examination of the chest in individuals of all ages would result in the early diagnosis of many intrathoracic tumors. It should be emphasized again that if the diagnosis of a mediastinal tumor must wait until clinical manifestations are obvious, the chances of cure become remote.

REFERENCES

- 1 Hare, H. A.: *The Pathology, Clinical History and Diagnosis of Affections of the Mediastinum other than those of the Heart and Aorta*, Philadelphia, P. Blakiston's Son & Co., 1899.
- 2 Alford, J. E.: Congenital Bronchiogenic Cysts of the Mediastinum. *J. of Pediatrics*, **11**, 515-555, 1937.
- 3 Heuer, George J., and Andrus, William DeWitt: *The Surgery of Mediastinal Tumors*. *The American J. of Surg.*, **50**, 146-212, October, 1940.
- 4 Laipply, T. C.: Cysts and Cystic Tumors of the Mediastinum. *Arch. Pathology*, **19**, 153-161, March, 1945.
- 5 Brown, Robert K., and Robbins, Laurence L.: The Diagnosis and Treatment of Bronchiogenic Cysts of the Mediastinum and Lung. *J. Thoracic Surg.*, **13**, 84-105, April, 1944.
- 6 Womack, Nathan: Personal communication.
- 7 Harrington, S. W.: Intrathoracic Tumors. *Arch. Surg.*, **19**, 1687, 1929.
- 8 Harrington, S. W.: Surgical Treatment in 11 Cases of Intrathoracic Teratomas. *J. Thoracic Surg.*, **3**, 50, 1933.
- 9 Rusby, N. Lloyd: Dermoid Cysts and Teratomata of the Mediastinum. *J. Thoracic Surg.*, **13**, 169-222, June, 1944.
- 10 Kent, Edward M., Blades, Brian, Valle, Anibal Roberto and Graham, Evarts A.: Intrathoracic Neurogenic Tumors. *J. Thoracic Surg.*, **13**, 116-161, April, 1944.
- 11 Pickhardt, O. C.: *ANNALS OF SURGERY*, **99**, 814, 1934.
- 12 Hampton, Aubrey O.: Personal communication.

- 13 McCorkle, R. G., Hoerth, C. J., and Donaldson, Jr., J. M.: Intrathoracic Lipomas. *J. Thoracic Surg.*, 9, 568-582, 1940.
- 14 Watson, William L., and Urban, Jerome A.: Mediastinal Lipoma: A Case Report, *J. Thoracic Surg.*, 13, 16-29, February, 1944.
- 15 Friedman, Milton: Personal communication.

DISCUSSION.—DR. ALTON OCHSNER, New Orleans, La.: It is with considerable trepidation that a civilian discusses a paper dealing with Army experiences. It is heartening to see this material brought to the attention of the medical profession, because in the past these cases have not been treated correctly, largely because we did not know how they should be treated, and we instituted watchful waiting. As Doctor Blades pointed out, many patients developed malignancies, many developed infection, both conditions which greatly interfere with the removal of the tumor. If the mediastinal shadow is bilateral, it is more likely to be lymphoblastic. In the bilateral lesion, one is much more justified in employing roentgenotherapy before exploration. In unilateral shadows thoracic exploration, we feel, is justified early. We have treated four patients with unilateral mediastinal shadows in whom at operation a very small bronchiogenic carcinoma was found and, although the primary neoplasm was too small to be detected preoperatively, the involvement of the mediastinal nodes was massive and produced the mediastinal shadow.

I am happy that Doctor Blades has emphasized that any mass in the mediastinum which cannot be diagnosed definitely ought to be explored, because this is safer than procrastination.

DR. NATHAN A. WOMACK, St. Louis, Mo.: This presentation of Doctor Blades is very modest, and I think needs no comment. This huge series of intrathoracic tumors represents a most unusual experience, and the operative results speak for themselves. There is one point that I should like to make, having to do with the etiology of the so-called teratoma or dermoid of the mediastinum. Doctor Blades has referred to bronchiogenic cysts and bronchiogenic tumors of the mediastinum. I think his terminology is a good one. In times past, the explanation offered for these tumors has been most fantastic. It has been suggested that they have been caused by inclusions of skin into the anterior mediastinum during the formation of the anterior thoracic wall; that they represent misplaced blastomeres; that they were the result of misplaced sex cells. Such explanations are embryologically untenable. I think we have enough evidence now to show that these tumors, for the most part, represent the abnormal development of supernumerary lungs which takes place very early in embryonic life. I shall not offer our proof for this belief at this time, but will reserve that for later publication.

DR. PAUL B. MAGNUSON, Chicago, Ill.: It is quite appropriate that an orthopedic surgeon should discuss this paper, because he cannot be expected to know anything about the subject. However, Doctor Blades' paper was very instructive to me and was beautifully presented. He mentioned that 35 cases of a certain type of mediastinal tumor had been reported in the world literature up to this time, and then reports 23 additional cases operated upon by surgeons in the Army within a period of three years. These were diagnosed in a large percentage of cases, suspected in a small percentage, and produced in all cases at the operating table, with a minimal mortality.

When we consider that this has occurred in what was originally a select group of young men, how many cases have existed that have never been diagnosed nor reported? How many will be found in the millions of men discharged from the Army, to be cared for by the Veterans Administration? The possibilities of saving lives and preventing disability through proper examination radiologically, and otherwise, are perfectly enormous. If we can place these patients into the hands of doctors who know the possibilities, who know how to make an expert examination and who are furnished with the tools with which to work, undoubtedly in all branches of our various specialties there will be found cases which have been considered rare in the past; these will be brought to successful cure by a combination of personnel, equipment and placement, namely, medical schools, properly equipped and properly run hospitals located on the campus