

PROGRESS ATTAINED IN THE SEARCH
FOR THE PRIMARY HEALING OF
GUNSHOT WOUNDS OF THE
EXTREMITIES IN THE ETO
IN WORLD WAR II

CLIFFORD L. KIEHN, M.D.

Emeritus Professor of Plastic Surgery
Case Western Reserve University
Cleveland Ohio

Emeritus Professor of Plastic Surgery
East Carolina University
Greenville, North Carolina

THE HISTORICAL QUEST for primary healing of severely injured extremities accompanied by bone and soft tissue loss has been long and arduous. Of the many contributors striving to prevent and to cure osteomyelitis and other infected structural defects, two are outstanding, namely, Lord Lister and Sir Alexander Fleming.

The first reported case of primary healing of an open fracture of the tibia was made by Lord Lister on August 12, 1867. Previous to this, a high percentage, particularly those with great tissue loss, were amputated.¹ Lister was able to accomplish this feat by the application of his new technique of carbolic acid antiseptis, at that time not wholly accepted as a routine prophylactic technique for primary healing. In spite of the cat calls and stamping of feet during Lister's lectures to medical students, one Alexander Napier took excellent notes describing the technique of carbolic acid treatment of gun shot wounds of the extremities on March 1, 1869 (Figure 1).

Carbolic acid, in various concentrations with water, was applied on a piece of lint to the wound after the wound was washed with water and all obvious devitalized tissue and foreign material were removed. Dressings were changed daily, and the wound allowed to close by secondary intention. No effort was described to close the wound with sutures or skin grafts because of the exceedingly high rate of infection.

With the introduction of this technique, Lister was able to conclude "in a simple comminuted fracture, there is a very extensive injury, yet there is no inflammation or suppuration; this must be from the skin being whole. The

Address for reprint requests: 411 Fairway Drive, New Berlin, N.C. 28560

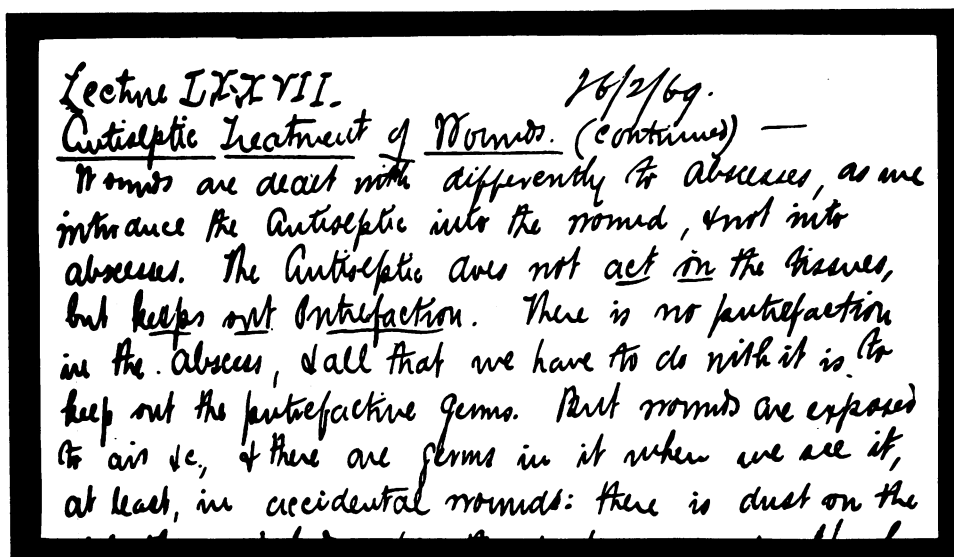


Fig. 1. Napier, A., student of Lister. Lecture notes on the use of carbolic acid treatment to wounds of the extremities. February 2, 1869.

very same result is obtained in compound fractures, in antiseptic treatment. It was exposure to the atmosphere that made inflammation a necessary thing. If you have full trust in your Antiseptic Treatment, Primary Amputation is not necessary" (Figure 2).²

In further notes by Napier, there is considerable discussion as to when amputation is desirable and imperative if the antiseptic technique is not used (Figure 3).³ The death rate of amputations on the service of John Erichsen, a prominent surgeon, reported in 1874, was 25%, which he thought very favorable when compared to other hospitals. Of all the operations compiled by him during the years 1871-73 at the London University Hospitals, 78 major amputations lead the list. The most common cause of death was septicemia and shock.⁴

The Lister era was the successful beginning of prophylactic chemotherapy to produce healing without gross infection by introducing substance into the wound.⁵ This era began to wane with the introduction of asepsis by Pasteur in 1878 at the meeting of the Academy of Sciences in Paris, where he described the sterilization technique of linens, instruments, and water used in surgical procedures.⁶

Not until World War I were serious studies undertaken to investigate the bacterial flora of gunshot wounds.

Sir Alexander Fleming, then a lieutenant in the British Army in France, began to identify, quantify, and locate the bacterial flora in gunshot wounds

same result is obtained, in a compound fracture, in Antiseptic treatment. It was exposure to the Atmosphere that make Infl. a necessary thing. So that, if you have full trust in your Antiseptic treatment, Primary Amputation is not necessary: it is Infl. & Suppuration that cause the danger in waiting, by the ordinary treatment; but as these never come on at all by Antiseptic management, no harm comes by waiting; rather, good is derived by waiting, for the patient will recover from the Shock, gain blood and strength generally, & the system becomes accustomed

Fig. 2. A. Napier, alluding that the cause of suppuration is from exposure to the air and will not occur if antiseptic treatment is used; amputation is not necessary.

Lecture LXXXIX - 2/3/69.
 The effects of a severe injury, such as a railway accident, are the same as those of gunshot wounds. - The Period of Suppuration is from the 3rd or 4th day onward. Which of the 4 periods is the best for Amputation? Some say "Amputate within the first 24 hours"; this being Primary Amputation; others say "Wait till the period of Suppuration. Statistics show most favourably for waiting; but this is fallacious, as the most cases have

Fig. 3. A. Napier, discussion as to when amputation should be done in gunshot wounds of the extremities.

which were more severe than had been encountered in any previous conflict. The high mortality rate was due to septicemia, tetanus, and gangrene.⁷

He proved, bacteriologically, that the application of antiseptic agents, such as carbolic acid, Dakins solution of hypochlorite of soda, and saline were of little value after a few minutes. They had some value for surface bacteria destruction, but could not reach those hidden in the anfractuositities of very severe wounds for better control of the infective process. More radical debridement of the original wound, advocated by Fleming, was then instituted and the mortality rate began to decline (Figures 4,6).⁸

In the interval between the two World Wars, many agents were used to control gross infections so that underlying structures could be repaired, such as nerves or bone alignment, after early wound closure.

One treatment that became very popular was the Orr technique, which combined the retention of bone alignment, while the soft tissue healed by granulation and epithelialization with the application of a cast, and packing the wound with an emollient gauze which could be changed periodically.⁹ This procedure was used if evidence of infection was present in either bone or soft tissue, and closure was not attempted until infection was controlled. In the interim, bone alignment was maintained with through and through pins above and below the bony defect. The pins were long enough to extend into the plaster cast for stabilization.

Many morbid problems developed with this technique. Wound closure was impossible, leading to severe fibrous contractures which immobilized the contiguous joints (Figure 13). Reconstructive procedures could not be instituted on bones, nerves, and tendons because of lack of wound closure. This technique was used by the U.S. Army and civilian hospitals up to and extending into the beginning of World War II in the European Theater of Operations until 1942, when penicillin was introduced for the treatment of mass casualties.

From the time of the discovery of penicillin by Sir Alexander Fleming in 1927, his findings lay fallow in his laboratory for several years before its usefulness in bacteria destruction was applied clinically.¹⁰

Penicillin was issued in December 1942 to the University of Michigan's 298th General Hospital in Frenchay Park, Bristol, England, where the author was stationed during the war. It was utilized in the definitive treatment of gunshot wounds received in the landings of U.S. troops in Oran, Africa on November 8, 1942. These casualties were transported by hospital ship from

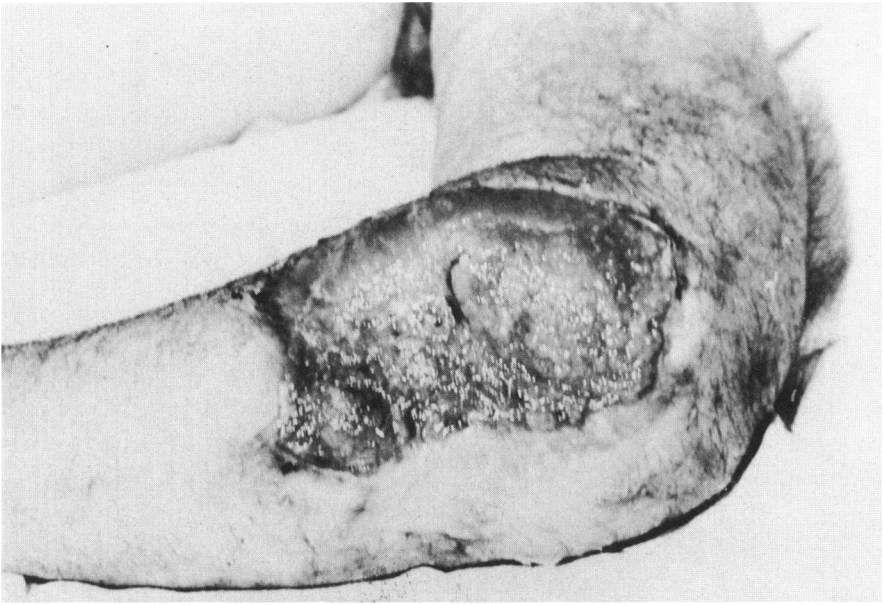


Fig. 4. Granulation and beginning epithelialization of gunshot wound of arm from Normandy invasion.




Fig. 5. Roentgenogram of arm showing bone loss and unstable fragmentation with shortening and no osteomyelitis. Wound is ready for debridement, bone alignment, and pedicle graft.

Africa to Bristol. All patients with gunshot wounds of the extremities were in casts or splints with wounds packed with vaseline or boric acid gauze. The wounds were granulating and many had new epithelium around the edges with very little drainage, indicating that the wound could be closed if there was no roentgenographic evidence of osteomyelitis. This was an excellent clinical sign that the use of penicillin was very effective in controlling infection in gunshot wounds as compared with those acquired in previous conflicts (Figures 4,5).

The only discernible complication of penicillin was severe pain when it was administered intramuscularly, probably due to impurities in the medication which required considerable adjustment in its manufacture to obtain pure penicillin. This could not be done at that time because of the urgency of need. An attempt was made to eliminate the severe pain caused by the intramuscular injections of penicillin. It was applied to the open wound which was to receive a split skin graft in the clinic of Sir Harold Gillies at Rooksdow House near Basingstoke, England. Penicillin was put under skin grafts to evaluate the take of the graft so that it would not have to be given intramuscularly. Sir Alexander Fleming accompanied the surgeons on rounds with great interest. It was decided that penicillin had no usefulness in the primary take of the grafts. This personal concern indicates that the criticism heaped upon Sir Alexander Fleming, that he was not interested in the clinical applications of penicillin, was entirely unfounded.¹¹

WOUND CLOSURE

The plastic surgical techniques and principles of closure of very large defects developed during World War I were particularly applied to facial wounds by Sir Harold Gillies of the British Army because of extensive trench warfare. After this conflict, these principles were applied to larger defects in other areas of the body.¹²

At the beginning of World War II, the U.S. Army was still closing wounds using techniques such as pulling the skin down over the end of amputation stumps with traction and advancing skin with relaxing incisions which had very limited use in closing large tissue defects. Small tissue defects could be closed by utilizing local tissue by wide undermining, rotating pedicle grafts, or split skin grafts if no gross infection was present.

Pedicle grafts are indicated for closure particularly when reconstructive procedures of the underlying structures are needed and, most important, they bring a new blood supply into the wound for more rapid healing until the pedicle is severed. This type of graft will also fill in the defect for restoration of contour.¹³

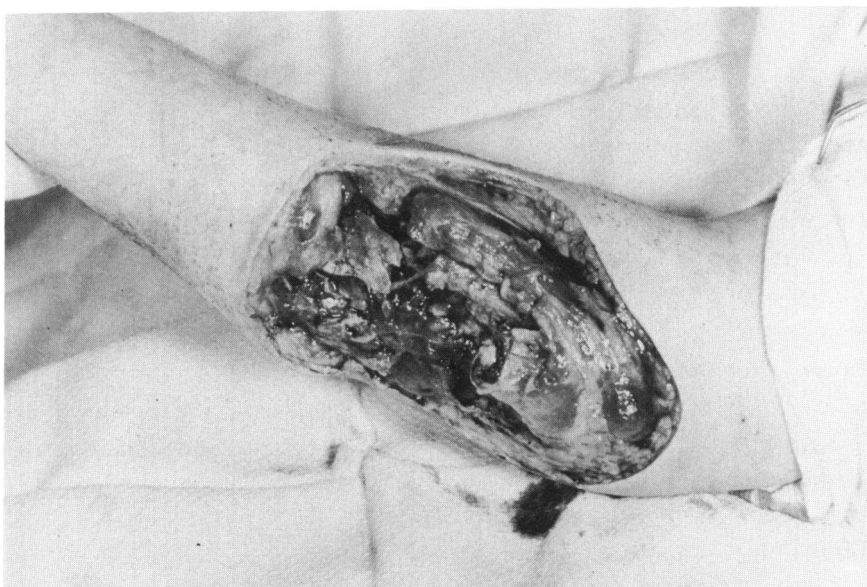

Fig. 6. Wound has been thoroughly debrided, eliminating all anfractuositities, restoring wound to original size and ready to receive external fixation to stabilize the radius and ulna.

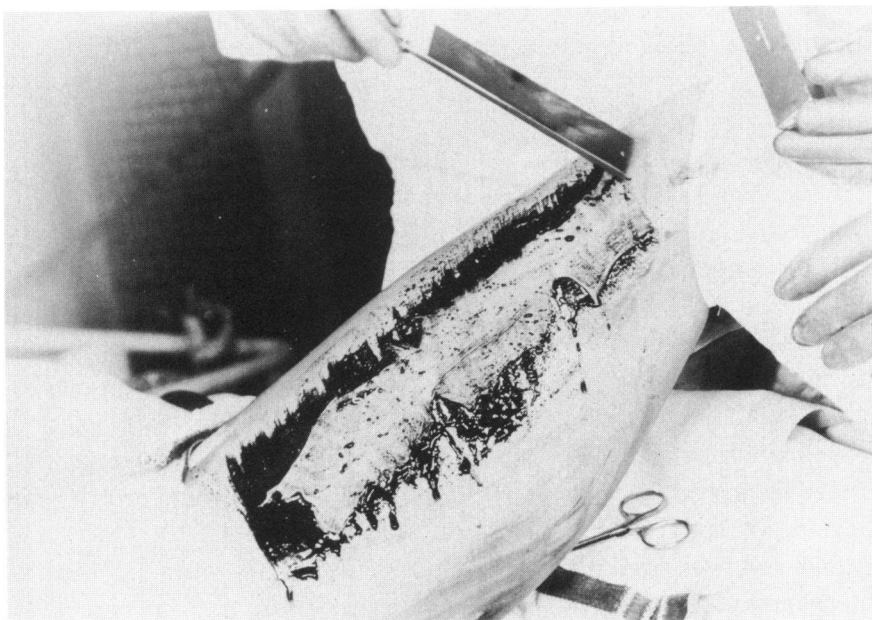


Fig. 7. Cutting split skin graft free hand to cover abdominal donor site that has not been closed with wide undermining or rotation pedicle grafts.

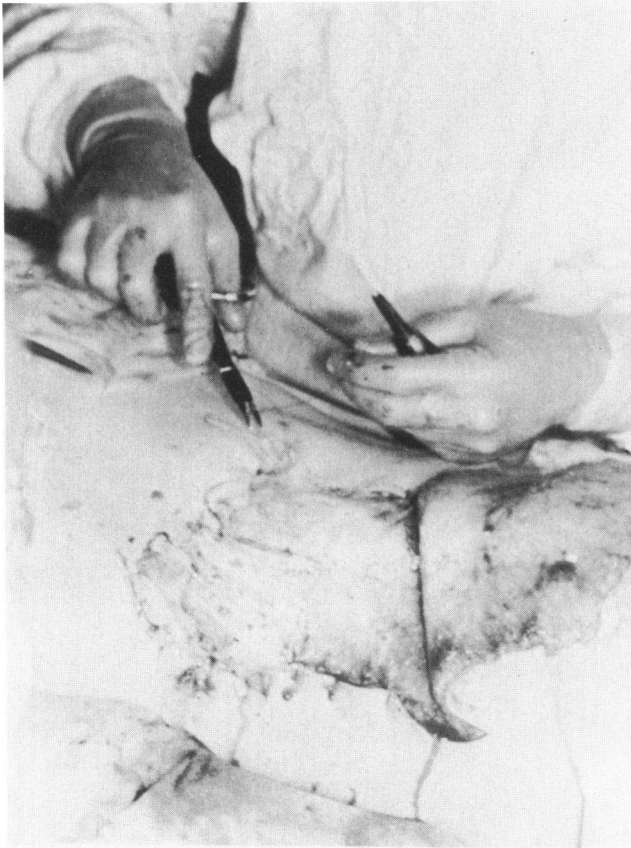


Fig. 8. Suturing split skin graft to donor site with pedicle graft elevated.

The choice of donor sites for procurement of the pedicle grafts to cover the recipient extremity defects is limited. They should be chosen from tissue similar to that which is missing, if possible, such as tissue from the opposite calf of the leg to close a defect on the tibial crest of the injured leg.¹⁴ The flap is then designed to fit the completely debrided defect and long enough to carry an adequate blood supply to nourish the graft (Figure 6). The recipient site is then closed with the pedicle graft and held in place with adequate fixation to the chest wall. The donor site is closed with undermining, rotation pedicle grafts, and/or split skin grafts (Figures 7,8). This technique introduces the problem of maintaining stable bone fragments, particularly if bone loss is so great that it will require bone grafts.

With the introduction of the Stadler external fixation apparatus, the problem of fixation of the distal and proximal fragments was greatly solved (Figures 9,10,11). This offered a greater choice of donor tissue to fill the

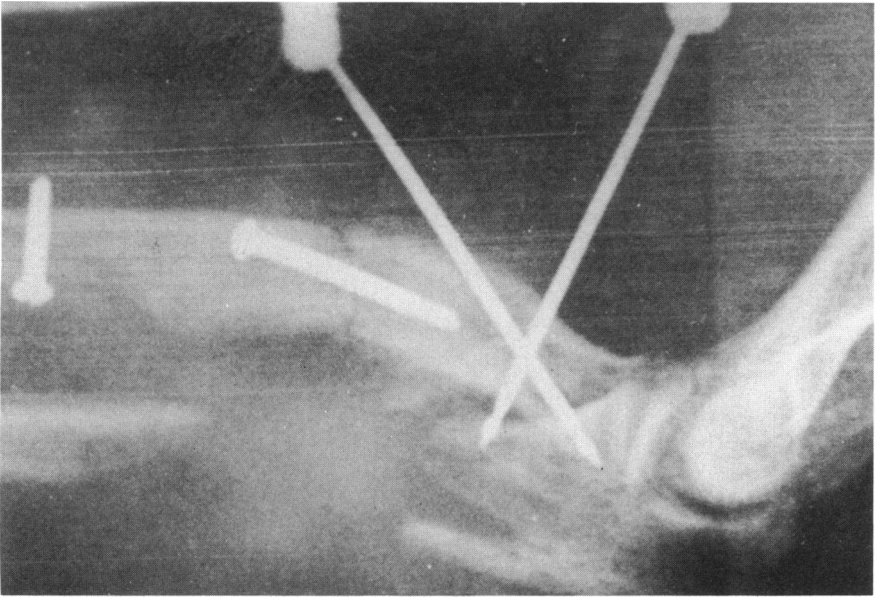


Fig. 9. Roentgenogram showing restoration of radial length and external fixation in place.

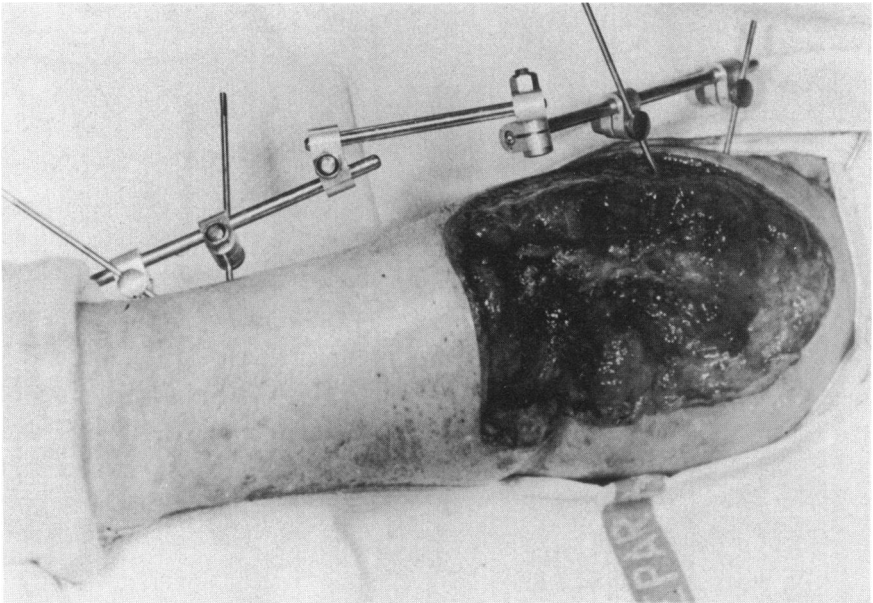


Fig. 10. The wound and external fixation in place ready to receive the abdominal pedicle graft.

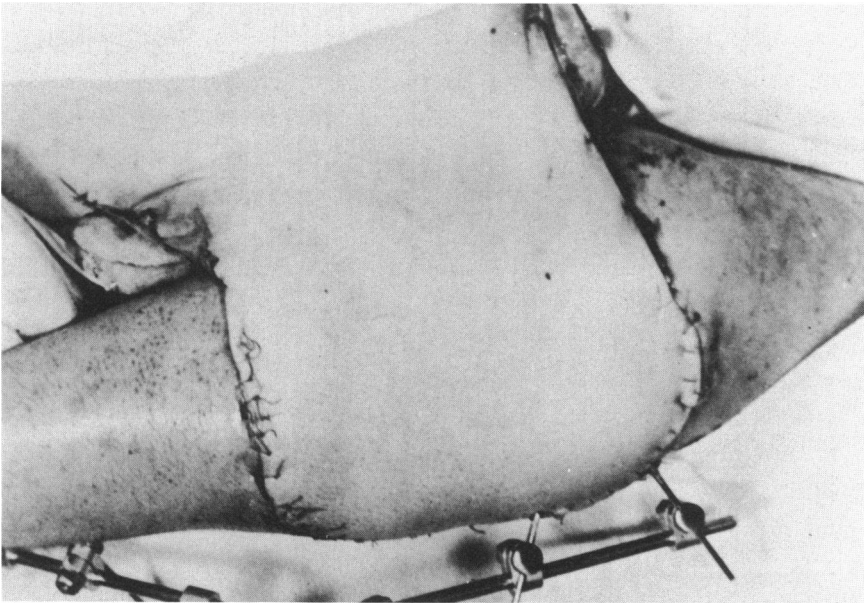


Fig. 11. The pedicle graft sutured to the defect in layers and arm will be held to the abdominal wall for three weeks with adequate dressings after which the pedicle base will be severed.

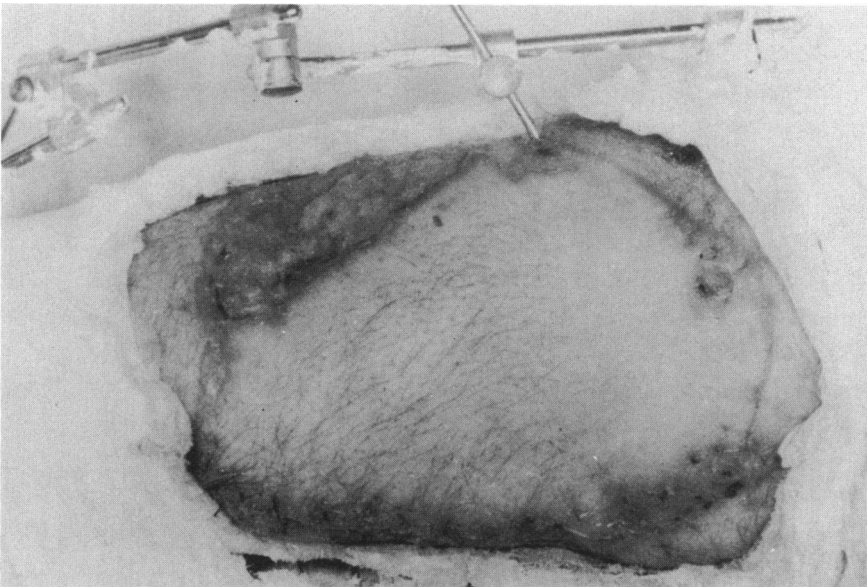


Fig. 12. The pedicle graft is healing, cast applied, and pins about to be removed for transportation to the Zone of the Interior.

defect because the extremity would be more mobile, as the bony fragments were more stabilized than in other techniques. The pedicle grafts could also be applied without restricting plaster splints which were used for so many years. The fixation apparatus was removed approximately three weeks after the base of the pedicle was severed and returned to its source and the wound completely closed with sutures and an appropriate cast applied (Figure 12).

The use of this apparatus in the U.S. Army in the forward hospitals was controversial, and rightly so, because it interfered with the mobile transportation of the wounded to hospitals in the rear for more definitive treatment and, more important, the possibility of pin displacement and bone infection at the pin sites that could lead to more serious complications.

These cases were triaged and moved to selected military installations where this apparatus could be used by surgeons who had acquired experience with it. The plastic surgery center at Bristol, England, was chosen to treat extremity gunshot wounds with the technique of external fixation and pedicle grafts. This installation was then the 117th General Hospital, with Major William Massey in charge of the orthopedic section, which worked very closely with the plastic surgery center for the coverage of these defects.¹⁵

This technique of applying the pedicle graft using external fixation in the same operation was an important step forward in treating gunshot wounds of the extremities because it saved many weeks and sometimes months, as well as further operative procedures to move tissue from one part of the body to the other. This method, thereby, not only prevented infection and fibroses, but allowed bone grafting and nerve repair to be instituted at an earlier date. This technique was not described in detail in the reports of surgical procedures used in the U.S. Army in the European Theater of Operations at the end of World War II.¹⁶

These soldiers were then transported to the United States with standard casts and no external fixation for further reconstructive procedures. These procedures could readily be done by utilizing incisions through the pedicle grafts without compromising their blood supply (Figures 13,14). This type of graft can generally tolerate any exposed metal appliance deemed necessary for fixation.

SUMMARY

Every war offers the opportunity to improve wound healing, applying proved techniques developed since the last conflict. The medical and surgical contributions of World War II, blood transfusions, antibiotics, immunizations and reconstructive procedures, to name a few, allowed wounds to be closed earlier.

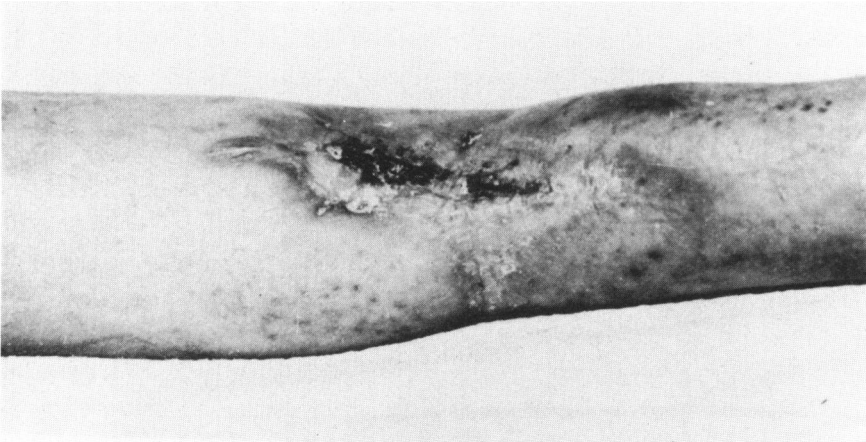

Fig. 13. This civilian wound was treated with the Orr technique and has nearly healed with deep fibroses and scar epithelium with approximately 4 inches of tibia missing. The fibula is intact.

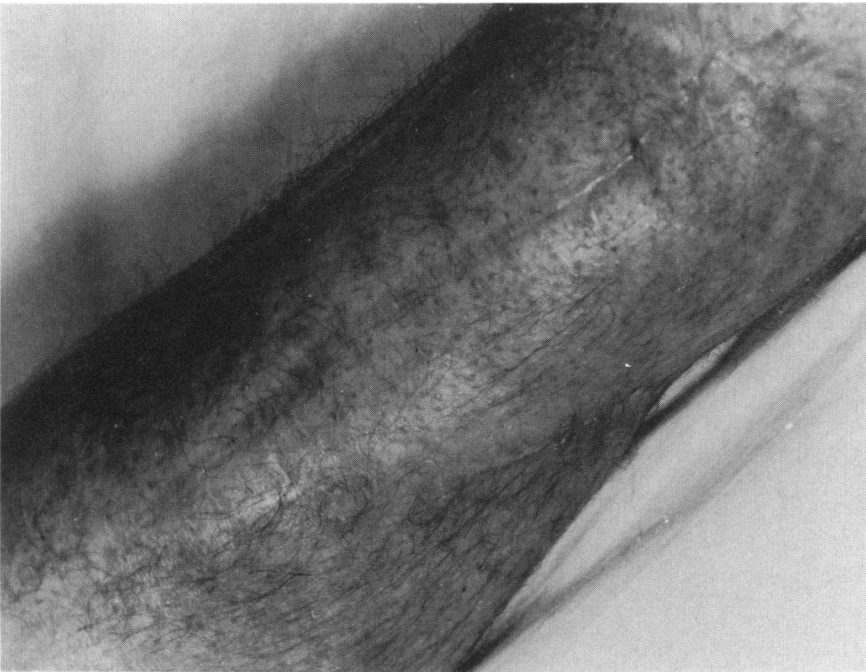

Fig. 14. The wound in Figure 13 was debrided and covered with a cross leg flap and the scar shows that the bone graft was inserted directly through the pedicle.

The simultaneous use of external fixation with the application of pedicle grafts prevented extremity shortening by maintaining good anatomical positioning of bone fragments while the pedicle grafts were healing. The compli-

cation of osteomyelitis from the fixation pins was rarely seen as they were removed within a month when the base of the pedicle was severed. This technique also allowed bone, tendon, and nerve replacement through the pedicle graft without compromising its viability for early functional results in the zone of the interior. This was the first conflict where war wounds were closed by pedicle grafts and external fixation in the field of operations.

In future conflicts wounds such as those seen in World War II will heal with less morbidity because large compound grafts of skin, muscle, and bone will be transplanted en masse, anastomosing arteries and veins in one stage.

REFERENCES

1. Lister, J.: On a new method of treating compound fractures, abscesses etc. with observations of the conditions of supuration. *Lancet* 1:326-29, 1867.
2. Lister, J.: Notice of a new method of treating compound fractures. *Bienn. Ret. Med.*: p 219, 1867.
3. Napier, A.: *Student of Lister, Lectures Notes: When To Amputate*. 1869, p. 377.
4. Erichsen, J.: *Modern Med.* 35:42-51, 1967.
5. Zimmerman, L. M. and Veith I. A.: A century of antisepsis. Homage to Lord Lister. *Mod. Med.* 35:32, 1967.
6. Pasteur, L.: *La theorie des germes et ses applicacions a la medicine et la chirurgie*. Vallery, 1878, Vol. VI, p. 124.
7. Fleming, A.: Removal of necrotic tissue in gun shot wounds. *Lancet*, 1915.
8. Maurois, A.: *The Life of Sir Alexander Fleming*. England. Penguin, 1959, pp. 94-99.
9. Orr, H.: *Handbook of Orthopedic Surgery: Osteomyelitis*. St. Louis, Mosby, 1929, p. 140.
10. MacFarland, G.: *Alexander Fleming, The Man and the Myth*. Cambridge, MA, Harvard University Press, 1984.
11. Fleming, A., Gillies, H., and Kiehn, C.: The effect of penicillin on the healing of gun shot wounds when applied under skin grafts. Personal communication, 1944.
12. Gillies, H.: *Plastic Surgery of the Face*. Oxford University Press, 1920.
13. Brown, J. B.: Direct flap repair of arm and hand: preparation of gun shot wounds for repair of nerves, bones and tendons. *Ann. Surg.* 122:706-15, 1945.
14. Kiehn, C. L. and Schatten, W.: Treatment of traumatic ulcers of the lower extremities. *Am. J. Surg.* 80:854, 1955.
15. Mullins, W. S.: External Fixation. In: *Orthopedic Surgery in the Zone of the Interior*. Dept. of the Army, 1970, p. 632.
16. Bricker, E. M.: *Surgery in World War II: Activities of Surgery Consultants*. Dept. of the Army, 1964, Vol. VII, pp. 511-72.