

METHICILLIN-RESISTANT *STAPHYLOCOCCUS AUREUS* INFECTIONS OF THE EYE AND ORBIT (AN AMERICAN OPHTHALMOLOGICAL SOCIETY THESIS)

BY PRESTON HOWARD BLOMQUIST MD

ABSTRACT

Purpose: To ascertain if methicillin-resistant *Staphylococcus aureus* (MRSA) ophthalmic infections are increasing.

Methods: A retrospective review of all patients with a culture positive for MRSA in the Parkland Health and Hospital System, the urban public healthcare system for Dallas County, Texas, for the years 2000 through 2004 was performed. Patients with ocular, orbital, and ocular adnexal infection were identified, and isolates were categorized as nosocomial or community-acquired (CA).

Results: A total of 3,640 patients with a culture positive for MRSA were identified, with 1,088 patients (30%) considered to have acquired the isolate via nosocomial transmission and 2,552 patients (70%) considered to have CA-MRSA. Forty-nine patients (1.3%) had ophthalmic MRSA involvement. For both ophthalmic and nonophthalmic cases, the number of CA-MRSA patients increased each year, whereas the numbers of nosocomial patients remained fairly constant. Patients with ophthalmic MRSA tended to be younger than other MRSA patients ($P = .023$). The most common manifestation of ophthalmic MRSA infection was preseptal cellulitis and/or lid abscess followed by conjunctivitis, but sight-threatening infections, including corneal ulcers, endophthalmitis, orbital cellulitis, and blebitis, also occurred. Empirical antibiotic coverage was initially prescribed in 48 (98%) of ophthalmic cases and did not adequately cover for the MRSA isolate in 24 (50%).

Conclusions: CA-MRSA is becoming increasingly prevalent, and ophthalmologists will see more ophthalmic MRSA infections. Although ophthalmic CA-MRSA commonly presents as preseptal lid infection and conjunctivitis, sight-threatening infections also occur. Ophthalmologists must identify MRSA patients, adjust empirical treatment regimens where MRSA is endemic, and take steps to control emergence of resistant organisms in both inpatient and outpatient practices.

Trans Am Ophthalmol Soc 2006;104:322-345

INTRODUCTION

Staphylococcus aureus is a versatile and dangerous bacterial pathogen with a genome consisting of a circular chromosome of approximately 2,800 base pairs and additional prophages, plasmids, and transposons.¹ Genes governing virulence and antibiotic resistance reside on both the chromosome and extrachromosomal elements,² and these genes are transferred between staphylococcal strains or other bacterial species via extrachromosomal elements.³ Humans are a natural reservoir of *S aureus*, with 30% to 50% of healthy adults colonized, 10% to 20% persistently so.^{4,5} Persons colonized with *S aureus* are at increased risk for subsequent infections.⁶

S aureus quickly developed resistance to early antibiotics. In 1942, the introduction of benzylpenicillin (penicillin G) temporarily addressed staphylococcal infections, but continued use caused the selection of resistant strains that produced penicillinase (β -lactamase).⁷ Kirby⁸ first described penicillinase-producing strains of *S aureus* in 1944, and most hospital isolates were resistant to penicillin within a few years.⁹ There are a wide variety of β -lactamases that hydrolytically inactivate β -lactam antibiotics like penicillin; β -lactamases can be either plasmid or chromosomally mediated.¹⁰ By 1948, the prevalence of resistant strains had seriously reduced the value of benzylpenicillin in the treatment of *S aureus* infections,¹¹ and by the end of the 1950s, *S aureus* had acquired resistance to virtually all available systemic antibiotics, including erythromycin, streptomycin, and the tetracyclines.⁷ By the 1970s, penicillinase-producing strains were almost as common in the community, but where nosocomial strains were usually resistant to multiple antibiotics, community-acquired isolates were often resistant solely to penicillin.¹²⁻¹⁵ Methicillin, introduced in 1960,¹⁶ is not inactivated by β -lactamase. A host of other β -lactam antibiotics, including oxacillin, nafcillin, dicloxacillin, cephalothin, cephaloridine, and cefazolin, soon followed. Strains of methicillin-resistant *S aureus* (MRSA) were first detected in 1961^{17,18} but initially occurred sporadically and were only resistant to β -lactam antibiotics. Resistant nosocomial strains appeared in Australia in the late 1970s that differed from earlier strains, were resistant to multiple other antibiotics in addition to β -lactam compounds,^{19,20} and subsequently spread to hospitals worldwide. MRSA is now one of the most common causes of bacterial nosocomial infections, responsible for 40% to 70% of *S aureus* infections in intensive care units (ICUs).^{21,22} In the past decade new strains of MRSA have emerged in the community, causing suppurative infection in young, otherwise healthy people,²³⁻²⁸ and the prevalence of community-acquired (CA) MRSA is increasing.²⁹

MRSA constitutes a significant healthcare problem. Because methicillin is rarely used today, the term "MRSA" is used now to describe strains of *S aureus* resistant to all β -lactam antibiotics.³⁰ Colonization with MRSA is more likely to result in infection than colonization with methicillin-sensitive *S aureus* (MSSA).^{31,32} MRSA bacteremia is associated with significantly higher mortality rate³³ and cost to treat³⁴ than MSSA bacteremia. Higher mortality and costs have also been found with MRSA surgical site

From the Department of Ophthalmology, University of Texas Southwestern Medical Center, Dallas, Texas. Supported in part by an unrestricted research grant from Research to Prevent Blindness, Inc, New York, New York. The author discloses no financial interest in this article.

infections.³⁵ Vancomycin, a glycopeptide antibiotic that inhibits the polymerization of peptidoglycan (an essential component of the bacterial cell wall), is the drug of choice for MRSA isolates. Whereas there has been no evidence to suggest that MRSA strains are more virulent than MSSA strains, there is evidence that vancomycin may be inferior to semisynthetic penicillins for treatment of deep-seated *S aureus* infections.^{33,36-42} Vancomycin is less bactericidal against MSSA than are β -lactam agents, and vancomycin has been associated with clinical failure in treatment of MSSA infections.³⁵

Vancomycin was first approved by the Food and Drug Administration in 1958, and resistance first emerged in coagulase-negative staphylococci in 1987.⁴³ In 1996, the first clinical isolate of *S aureus* with reduced susceptibility to vancomycin was identified in Japan.⁴⁴ Risk factors for infection with *S aureus* with reduced vancomycin susceptibility include antecedent vancomycin use and prior MRSA infection.⁴⁵ In June 2002, a strain of *S aureus* fully resistant to vancomycin was isolated from a patient in Michigan.⁴⁶ The DNA sequence of the *vanA* gene responsible for vancomycin resistance in this patient's *S aureus* isolate was identical to the *vanA* sequence from her vancomycin-resistant *Enterococcus faecalis* (VRE) isolate.⁴⁷ Conjugate transfer for the *vanA* gene from enterococci to *S aureus* had previously been demonstrated in vitro.⁴⁸

PREVIOUS REPORTS OF OPHTHALMIC MRSA INFECTION

Reports of MRSA ophthalmic infections are increasing in the literature. Conjunctivitis is the most commonly reported manifestation⁴⁹⁻⁵¹ and has been associated with long-term care units,³⁰ especially in patients with neurologic impairment⁵²⁻⁵⁵; nurseries⁵⁵⁻⁵⁷ and neonatal ICUs^{58,59}; and healthcare workers.⁶⁰ Maskin⁶¹ reported a 63-year-old diabetic man with previous MRSA chronic foot ulcer who developed MRSA infectious scleritis. MRSA keratitis has been described in nursing home patients without prior surgery.^{30,62,63} Sotozono and associates⁶⁴ reported two patients with Stevens-Johnson syndrome with corneal intraepithelial infiltrations with conjunctival swabs that grew MRSA. The infiltrates persisted until treated with topical 1% arbekacin or 1% vancomycin. Inoue⁶⁵ observed cases of MRSA keratitis in keratoconus patients with atopic dermatitis as well as blepharoconjunctivitis with severe erosion of the eyelid skin. Labit and colleagues⁶⁶ reported that two of 13 *S aureus* isolates from patients undergoing vitrectomy for endophthalmitis were methicillin-resistant, but they did not indicate if those isolates were from patients who had recently had intraocular surgery. Saitoh and associates⁶⁷ described an otherwise healthy 62-year-old woman with a history of nasolacrimal duct obstruction who developed MRSA dacryocystitis and who was treated with intravenous vancomycin and minocycline infusions and subsequent dacryocystectomy. Kubo and associates⁶⁸ described an additional four healthy patients with dacryocystitis caused by MRSA treated successfully with dacryocystorhinostomy, and Shanmuganathan and colleagues³⁰ reported three other cases with comorbidities. MRSA orbital cellulitis is rarely reported in the literature. Mehra and colleagues⁶⁹ described a 44-year-old man with odontogenic MRSA sinusitis with orbital extension. Anari and associates⁷⁰ reported a 4-week-old neonate born prematurely at 34 weeks gestation that presented with an orbital abscess.⁷⁰

Of special concern to ophthalmic surgeons are increasing reports of postoperative MRSA infection. Kato and Hayasaka⁷¹ found that 13 of 978 eyes (1.3%) swabbed preoperatively grew MRSA, and patients with nasolacrimal duct obstruction had a higher incidence of harboring MRSA. Fukuda and associates⁵¹ found 6.6% of 1,000 asymptomatic eyes swabbed grew MRSA. In addition, they found that elderly conjunctival MRSA carriers were more likely to have anemia, cancer, liver dysfunction, or dementia; to be status post surgery; or to be chronically bedridden. In a 1991 report, Insler and colleagues⁶³ described central MRSA keratitis after recent uncomplicated phacoemulsification procedure with posterior chamber intraocular lens insertion. More recently, MRSA wound infections have been reported with clear corneal phacoemulsification wounds.^{72,73} One of two patients with MRSA clear corneal wound infections described by Cosar and associates⁷² also had scleral extension of infection and endophthalmitis. Two other cases of postoperative MRSA endophthalmitis following cataract surgery have also been reported.^{67,74} In the most recently reported case, the patient had received moxifloxacin, a fourth-generation fluoroquinolone, for prophylaxis both before and after surgery.⁷⁴ Fukuda and associates⁵¹ reported a case of MRSA endophthalmitis following vitrectomy in a patient with atopic dermatitis.

Refractive surgery has not escaped complications from MRSA infection. MRSA keratitis has been reported after laser in situ keratomileusis^{75,76} and photorefractive keratectomy (PRK),⁷⁷ including a bilateral case after bilateral PRK in a medical resident.^{78,79} Sotozono and associates⁶⁴ reported three cases of MRSA keratitis following penetrating keratoplasty, one case following lamellar keratoplasty, and four cases following epithelial transplantation for Stevens-Johnson syndrome. They felt MRSA keratitis is characterized by superficial keratitis, minimal melting, and minimal scarring. Patients with atopic dermatitis are often colonized with *S aureus* in their skin lesions⁸⁰⁻⁸² as well as having conjunctival and eyelid colonization.⁶⁵ Because these patients frequently use antibiotics for long periods in combination with corticosteroids, the prevalence of MRSA colonization in that population is increasing. Oshima and colleagues⁸³ reviewed their experience of scleral buckle infections after retinal detachment repair and found that six (19%) of 32 eyes of patients with atopic dermatitis undergoing repair developed MRSA buckle infections compared to only one (0.4%) of 261 repairs in patients without atopic dermatitis ($P < .001$). Prompt removal of the infected buckle in combination with vancomycin administration was curative in four eyes; three went on to develop endophthalmitis requiring intravitreal injections or emergent vitrectomies. Osawa and colleagues⁸⁴ reported another two cases of MRSA scleral buckle infection after retinal detachment repair in atopic dermatitis patients who presented with exudative retinal detachment without endophthalmitis after surgery. Resolution occurred after buckle removal and antibiotic administration. Shanmuganathan and associates³⁰ reported an additional case of MRSA infection of a buckle segment with associated preseptal cellulitis. Finally, MRSA socket infections have been reported after enucleation and exenteration.³⁰

To my knowledge, a comprehensive review of all ocular, orbital, and ocular adnexal MRSA infections in a healthcare system has not been reported. A review of all such infections was completed over a 5-year period in an urban county hospital system.

METHODS

The study was approved by the Institutional Review Boards of the University of Texas Southwestern Medical Center and Parkland Health and Hospital System. All patients with a culture positive for MRSA performed in the Parkland Health and Hospital System during the years 2000 through 2004 were identified. The chart was reviewed in detail if the culture source was identified as eye, sinus, head, or cerebrospinal fluid. The Ophthalmology Service’s electronic medical record was searched for the terms “methicillin resistant” and “MRSA” to identify other cases with ophthalmic (defined as ocular, orbital, or ocular adnexal) involvement. To capture patients who may not have had ophthalmology consultation, all hospital admissions with a diagnosis related group covering orbital cellulitis or preseptal cellulitis were also identified. Charts were reviewed in detail for patients uncovered by these methods. Finally, patients seen by the Ophthalmology Service within 30 days before or after a positive culture for MRSA were identified through search of billing records. No additional cases of ophthalmic MRSA infection were discovered.

Data collected included age at time of culture, gender, race, culture source, diagnosis, and laterality of infection. Possible risk factors investigated included recent stay at a long-term care facility, hospital, or jail; dormitory living; homelessness; hemodialysis, diabetes, hypertension, HIV infection, chronic obstructive pulmonary disease, asthma, pregnancy, cancer, liver disease, intravenous drug use, or alcohol abuse; and chemotherapy, systemic or ocular corticosteroid use, or use of other ocular medications. Data were also collected on the following: antibiotics initially prescribed; whether antibiotics were begun empirically prior to culture results; if antibiotics were changed after culture results were known; and any procedures performed, including incision and drainage. Sensitivity (or resistance) of isolates of MRSA to antibiotics tested, including minimal inhibitory concentrations (MICs), was also reviewed. The Parkland Microbiology Laboratory identifies gram-positive cocci as *S aureus* based on response to catalase and coagulase testing. Oxacillin is used instead of methicillin to test for β-lactam antibiotic resistance because oxacillin is more stable in vitro. The MicroScan Dried Gram Positive Panels (Dade Behring Inc, West Sacramento, California) are used to test for oxacillin resistance of *S aureus* isolates, and resistance is confirmed using Mueller Hinton agar with 4% NaCl and 6 µg/mL oxacillin (Remel, Lenexa, Kansas). Minimum inhibitory concentration breakpoints for susceptibility and resistance of isolates to antibiotics are those published by the Clinical and Laboratory Standards Institute.⁸⁵ For example, *S aureus* isolates are considered to be resistant to oxacillin if the MIC is ≥ 4 µg/mL.

Patients were defined as having nosocomial MRSA infection or colonization if they had been hospitalized for 48 hours prior to obtaining the culture, if they had been hospitalized at Parkland Memorial Hospital in the 6 months prior to the date of the culture, or if they were clearly exposed to contaminated medical waste as a result of trauma. Comparison of age distributions to determine statistical significance was performed using the two-tailed Student *t* test. Other comparisons used the one-sided Fisher exact test or chi-square test as appropriate. For comparisons regarding sensitivity to antibiotics, ciprofloxacin and levofloxacin were considered as a single class of drug, and intermediate resistance (reduced susceptibility) on antibiotic testing was treated the same as frank resistance for comparison purposes.

RESULTS

The Parkland Health and Hospital System experiences over 1,000,000 patient visits per year (Table 1). For the years 2000 through 2004, 3,640 patients with a culture positive for MRSA were identified, with 1,088 patients (30%) considered to have acquired the isolate via nosocomial transmission and 2,552 patients (70%) considered to have CA-MRSA. The increase in MRSA patients over the period 2000 through 2004 proportionally exceeds the increase in volume in the Parkland system (*P* < .0001). Whereas the absolute number of nosocomial MRSA patients remained fairly constant each year, the number of CA-MRSA patients steadily increased (Figure 1). The average age of MRSA patients was 38.5 years (SD = 17.8 years) (Figure 2). Age was unknown for 26 patients. For nosocomial MRSA patients the average age was 40.9 years (SD = 19.9 years), and for CA-MRSA patients it was 37.4 years (SD = 16.7 years) (*P* < .0001).

TABLE 1. PATIENT VISITS IN THE PARKLAND HEALTH AND HOSPITAL SYSTEM, 2000 – 2004, BY YEAR

VISITS	2000	2001	2002	2003	2004
Admissions, PMH	41,679	42,426	41,260	41,081	41,425
Emergency department visits, PMH	144,510	160,650	156,870	155,536	148,215
Outpatient visits, PMH	401,669	419,507	447,248	443,639	427,606
COPC visits	308,409	367,230	363,294	384,647	455,927

COPC = community-oriented primary care clinics; PMH = Parkland Memorial Hospital.

Forty-nine patients (1.3%) had ophthalmic MRSA involvement (Table 2), and the ratio of ophthalmic MRSA to all MRSA patients remained fairly constant each year (Table 3). Twenty-eight ophthalmic MRSA patients were men, and 21 were women. Eighteen were Hispanic, 15 were black, 14 were white, and two were Asian in racial origin. The disease process was bilateral in six cases, affected the left side only in 23, and affected the right side only in 18; laterality could not be determined from the chart in two cases.

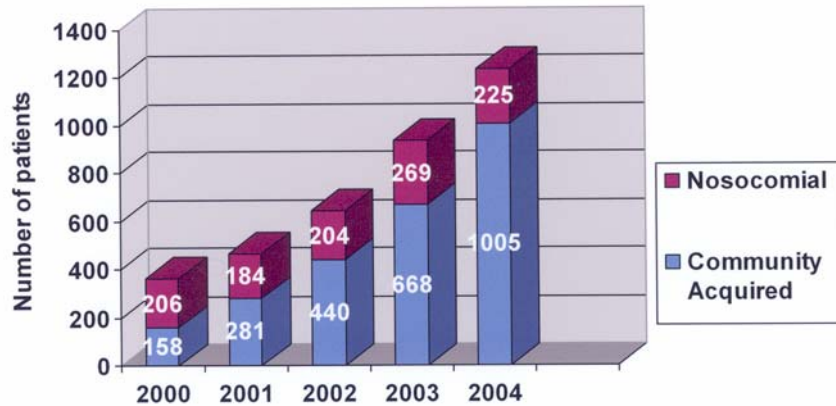


FIGURE 1

Number of MRSA patients in the Parkland Health and Hospital System by year, 2000 - 2004.

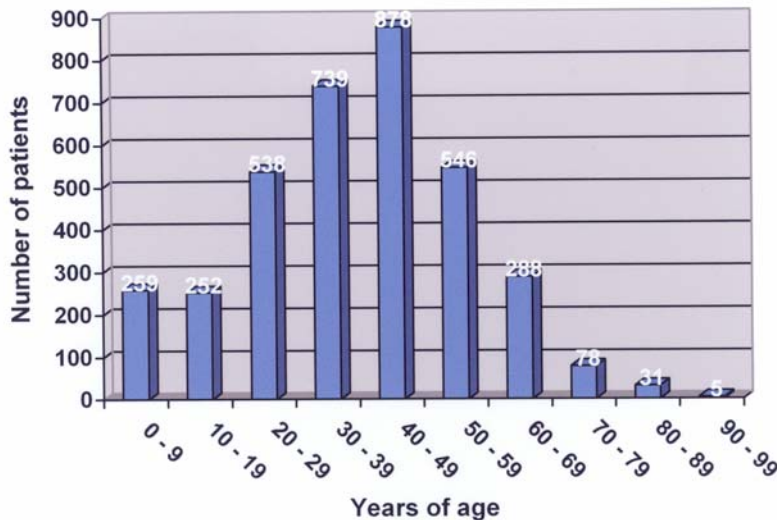


FIGURE 2

Age distribution of MRSA patients in the Parkland Health and Hospital System, 2000 – 2004, by decade of life.

Twelve ophthalmic cases (24%) were nosocomial, and 37 (76%) were community-acquired; this distribution between nosocomial and community-acquired ophthalmic isolates mirrored the distribution for nonophthalmic MRSA patients. Again, as for all MRSA patients, the number of ophthalmic CA-MRSA patients increased each year, whereas the numbers of nosocomial patients remained fairly constant (Figure 3). The average age of patients with ophthalmic MRSA was 32.7 years (SD = 18.1 years) (Figure 4). Patients with ophthalmic MRSA tended to be younger than other MRSA patients ($P = .023$). Unlike nonophthalmic MRSA patients, patients with ophthalmic nosocomial MRSA tended to be younger (average age, 24.0 years with SD of 20.8 years) than patients with ophthalmic CA-MRSA (average age, 35.6 years with SD of 16.2 years) ($P = .056$).

The most common manifestation of ophthalmic MRSA infection was preseptal cellulitis and/or lid abscess (Table 4). Conjunctivitis was next, with six (55%) of the 11 patients with conjunctivitis being newborns; the other five were adults. There were five cases of MRSA keratitis, four cases of endogenous endophthalmitis, two cases of orbital cellulitis associated with endophthalmitis, two cases of blebitis, two cases of dacryocystitis, and an orbital abscess.

TABLE 2. OPHTHALMIC MRSA INFECTIONS IN THE PARKLAND HEALTH AND HOSPITAL SYSTEM, 2000 – 2004

SUBJECT NO.	CULTURE DATE	AGE / RACE / GENDER	DIAGNOSIS	NOSOCOMIAL VS COMMUNITY-ACQUIRED	SOCIAL HISTORY	COMORBIDITIES	PRIOR IMMUNOSUPPRESSIVE TREATMENT	SURGICAL TREATMENT
1	3/6/00	15BF	Blebitis	C			Systemic & topical steroids	
2	3/16/00	32BM	Corneal ulcer	C		Asthma, atopic dermatitis		
3	4/18/00	27WF	Preseptal cellulitis with abscess	N	IVDA	HIV		I&D
4	12/14/00	66HM	Endogenous endophthalmitis	C	LTCF, EtOH	DM, HTN		Vitreous tap / inject
5	5/14/01	46BF	Conjunctivitis	C		Asthma	Systemic steroids	
6	6/12/01	<1HF	Conjunctivitis	N				
7	7/10/01	51WM	Preseptal cellulitis	N		SCC medial canthus & orbit, HTN, Hep C	Chemotherapy	I&D
8	7/13/01	46HF	Preseptal cellulitis	C		DM, HTN		
9	9/16/01	35WM	Conjunctivitis	C				
10	10/14/01	38BM	Endogenous endophthalmitis	C		DM, HTN, osteomyelitis		PPV
11	11/6/01	<1HM	Conjunctivitis	C				
12	2/9/02	54AM	Orbital cellulitis with endophthalmitis	N	LTCF	T cell lymphoma		Enucleation and orbital biopsy
13	3/21/02	20BM	Preseptal cellulitis	C		Asthma	Systemic steroids	
14	4/11/02	<1HM	Conjunctivitis	N			Systemic steroids	
15	5/13/02	55WF	Conjunctivitis	C				
16	5/21/02	46BM	Preseptal cellulitis with abscess	C	IVDA	Hep B, Hep C		
17	8/21/02	40HM	Endogenous endophthalmitis	C	EtOH	Cirrhosis, endocarditis		PPV, repeat intravitreal injection

TABLE 2 (CONTINUED). OPHTHALMIC MRSA INFECTIONS IN THE PARKLAND HEALTH AND HOSPITAL SYSTEM, 2000 – 2004

SUBJECT NO.	CULTURE DATE	AGE / RACE / GENDER	DIAGNOSIS	NOSOCOMIAL VS COMMUNITY-ACQUIRED	SOCIAL HISTORY	COMORBIDITIES	PRIOR IMMUNOSUPPRESSIVE TREATMENT	SURGICAL TREATMENT
18	9/27/02	33WM	Preseptal cellulitis	C		DM, Hep C		
19	11/5/02	<1HF	Conjunctivitis	C				
20	1/3/03	30AM	Corneal ulcer	N		Herpes zoster		
21	1/25/03	<1HM	Conjunctivitis	N				
22	1/27/03	43BM	Conjunctivitis	C		HIV		
23	2/26/03	19BF	Preseptal cellulitis with abscess	C				I&D
24	3/4/03	39WF	Dacryocystitis	C				I&D, DCR
25	4/9/03	18HF	Preseptal cellulitis	N		ALL	Chemotherapy	
26	4/9/03	23HM	Conjunctivitis	C				
27	4/26/03	31HM	Preseptal cellulitis with abscess	C				I&D
28	5/7/03	15BM	Lid abscess	C				
29	8/1/03	16BM	Corneal ulcer	N				
30	8/13/03	8BM	Dacryocystitis	C		Sickle C disease		
31	9/12/03	<1HF	Conjunctivitis	N				
32	9/12/03	54BF	Blebitis	N				
33	9/22/03	52BM	Preseptal cellulitis with abscess	C	EtOH	Laryngeal cancer, cirrhosis		
34	10/8/03	39WM	Preseptal cellulitis with abscess	C	IVDA	Hep C		I&D
35	12/18/03	8HF	Preseptal cellulitis	C				
36	1/26/04	38WF	Corneal ulcer	N	Cocaine			PK
37	2/1/04	64HF	Preseptal cellulitis	C		DM, HTN		

TABLE 2 (CONTINUED). OPHTHALMIC MRSA INFECTIONS IN THE PARKLAND HEALTH AND HOSPITAL SYSTEM, 2000 – 2004

SUBJECT NO.	CULTURE DATE	AGE / RACE / GENDER	DIAGNOSIS	NOSOCOMIAL VS COMMUNITY-ACQUIRED	SOCIAL HISTORY	COMORBIDITIES	PRIOR IMMUNOSUPPRESSIVE TREATMENT	SURGICAL TREATMENT
38	2/28/04	39HF	Preseptal cellulitis	C		DM, HTN		
39	3/6/04	43WF	Orbital abscess	C	IVDA	DM, Hep C		Orbitotomy with drainage of abscess x 3
40	4/6/04	53HF	Preseptal cellulitis with abscess	C		DM, HTN, asthma		I&D
41	4/19/04	37BM	Lid abscess	C				I&D
42	5/1/04	37WM	Lid abscess	C				I&D
43	5/27/04	26BF	Preseptal cellulitis with abscess	C				
44	6/17/04	58WF	Preseptal cellulitis	C				I&D
45	7/1/04	45BF	Corneal ulcer	C	IVDA (crack)	HTN		
46	7/8/04	31WM	Preseptal cellulitis	C		DM, Hep C		
47	7/29/04	43WM	Endogenous endophthalmitis	C	IVDA, EtOH	Hep C		Evisceration
48	11/11/04	45WM	Orbital cellulitis with endophthalmitis	C				Orbitotomy, PPV
49	12/27/04	46HM	Preseptal cellulitis with abscess	C	Jail, EtOH	DM, HTN		I&D

A = Asian; ALL = acute lymphocytic leukemia; B = black; C = community-acquired; DCR = dacryocystorhinostomy; DM = diabetes; EtOH = alcohol abuse; H= Hispanic; Hep = hepatitis; HIV = human immunodeficiency virus infection; HTN = hypertension; I&D = incision and drainage; IVDA = intravenous drug abuse; LTCF = long-term care facility; N = nosocomial; PK = penetrating keratoplasty; PPV = pars plana vitrectomy; SCC = squamous cell carcinoma; W = white.

TABLE 3. NUMBER OF MRSA PATIENTS IN THE PARKLAND HEALTH AND HOSPITAL SYSTEM BY YEAR, 2000 – 2004

YEAR	ALL MRSA PATIENTS	OPHTHALMIC MRSA PATIENTS	% OPHTHALMIC
2000	364	4	1.1
2001	465	7	1.5
2002	644	8	1.2
2003	937	16	1.7
2004	1230	14	1.1

MRSA = methicillin-resistant *Staphylococcus aureus*.

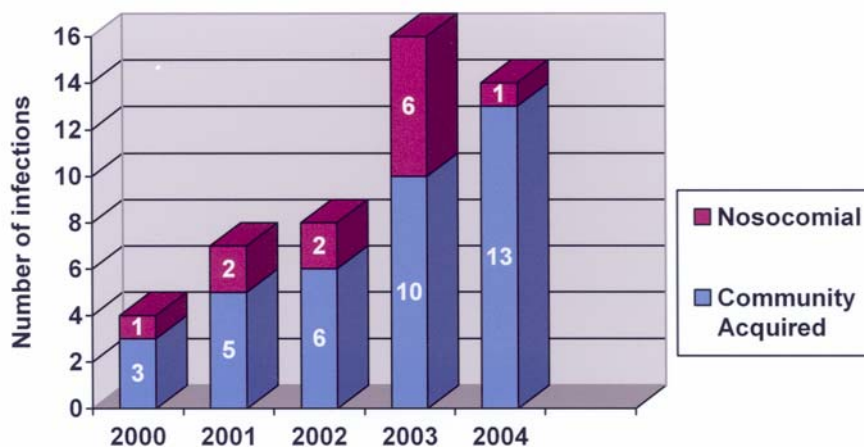


FIGURE 3

Ophthalmic MRSA infections in the Parkland Health and Hospital System, 2000 – 2004, by year.

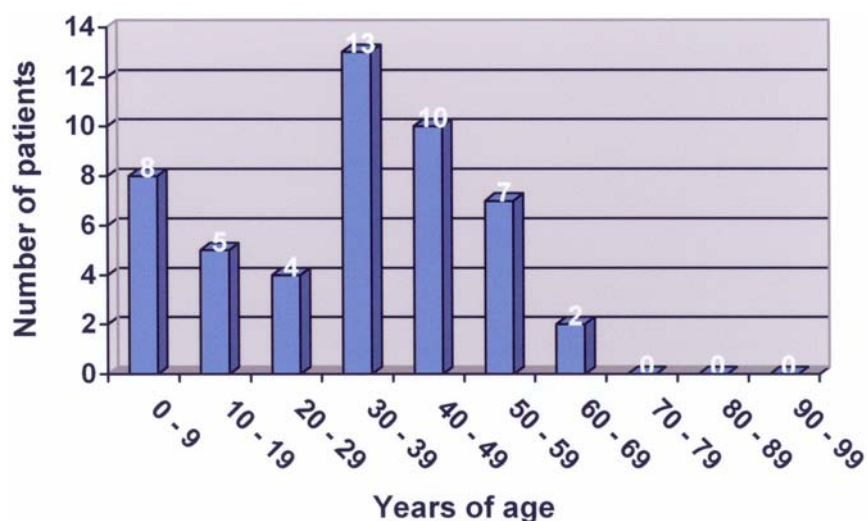


FIGURE 4

Age distribution of ophthalmic MRSA infections in the Parkland Health and Hospital System, 2000 – 2004, by decade of life.

In all but one of the 49 infected ophthalmic MRSA cases, patients were placed on antibiotics after the culture was performed. Inadequate antibiotic coverage for the MRSA isolate was initially prescribed in 24 cases (50%) (Table 5), and the antibiotic was

subsequently changed to one the isolate was sensitive to in only 13 cases (54%). Nosocomial isolates tended to be resistant to more antibiotics than community-acquired isolates (Figure 5). For the six major antibiotics tested (fluoroquinolones, tetracycline, aminoglycosides, rifampin, sulfamethoxazole-trimethoprim, vancomycin), half of nosocomial isolates were resistant to one or more antibiotics. Whereas 11 (30%) of 37 community-acquired isolates were resistant to one or more antibiotics tested, six (50%) of 12 nosocomial isolates were ($P = .175$) (Table 6). Nosocomial isolates were resistant on average to 0.83 antibiotics and community-acquired isolates were resistant to 0.32.

TABLE 4. OPHTHALMIC MRSA INFECTIONS IN THE PARKLAND HEALTH AND HOSPITAL SYSTEM, 2000 – 2004, BY DIAGNOSIS

DIAGNOSIS	NO. OF CASES (%)
Preseptal cellulitis and/or lid abscess	22 (42)
Preseptal cellulitis with lid abscess	10
Preseptal cellulitis without abscess	9
Lid abscess without mention of cellulitis	3
Conjunctivitis	11 (21)
Corneal ulcer	5 (10)
Endogenous endophthalmitis	4 (8)
Orbital cellulitis with endophthalmitis	2 (4)
Blebitis	2 (4)
Dacryocystitis	2 (4)
Orbital abscess	1 (2)

MRSA = methicillin-resistant *Staphylococcus aureus*.

TABLE 5. ANTIBIOTICS USED IN OPHTHALMIC MRSA INFECTIONS WITH INITIAL SUBOPTIMAL COVERAGE

ANTIBIOTIC CLASS	NUMBER*
Penicillin derivatives	12
Cephalosporins	11
Fluoroquinolones	6
Clindamycin	5
Erythromycin	2
Aminoglycoside	1

*Although there were 24 cases of initial suboptimal antibiotic coverage, because combinations of antibiotics were used, there are more than 24 antibiotics in this column.

PRESEPTAL CELLULITIS AND/OR LID ABSCESS

Nineteen (86%) of the 22 patients with preseptal cellulitis and/or lid abscess had CA-MRSA. Seven (32%) of the 22 had diabetes compared to only three (10%) of the other 30 patients with nonlid disease MRSA infection or colonization ($P = .054$). Three (14%) of the 22 patients with lid disease had cancer, compared to only one (3%) of the other 30 patients ($P = .198$). Six (27%) with lid disease had liver disease (usually hepatitis C) compared to three (10%) without lid disease ($P = .105$). An antibiotic regimen that did not cover MRSA was begun empirically in 16 (73%) of the 22 cases with lid disease, and incision and drainage or debridement was performed in 10 cases (45%). In another case the patient lanced the lesion himself, whereas spontaneous drainage occurred in most other cases. Seven cases (32%) resolved despite receiving only β -lactam antibiotics or cephalosporins.

Two patients were initially misdiagnosed as having insect bites. Two other patients developed preseptal cellulitis after surgical procedures. One had MRSA infection after inferior forniceal reconstruction of a constricted orbital socket with alloderm graft 2 weeks previously. The other developed nosocomial MRSA infection after craniofacial resection of a medial canthal basal cell carcinoma with orbital extension.

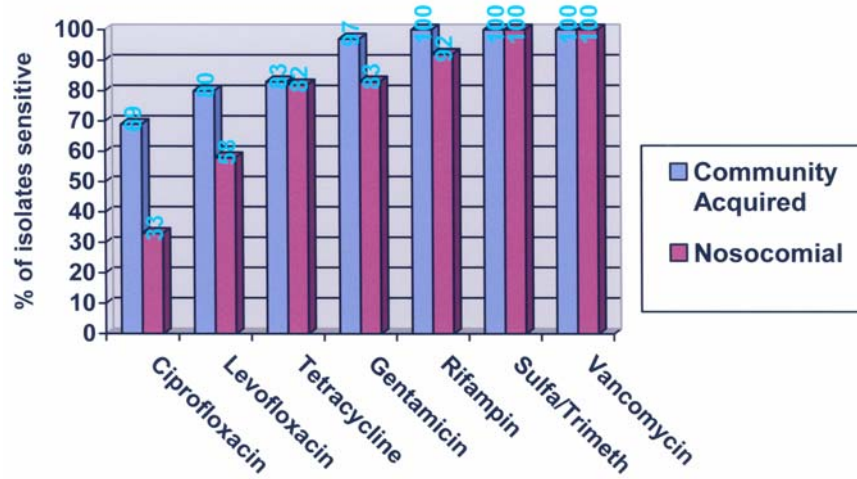


FIGURE 5

Sensitivity of ophthalmic MRSA isolates to antibiotics.

TABLE 6. SENSITIVITIES TO ANTIBIOTICS TESTED* FOR EACH OPHTHALMIC MRSA ISOLATE

SUBJECT NO.	NOSOCOMIAL VS COMMUNITY-ACQUIRED	CIPRO	LEVO	TET	GENT	AMIK	RIF	SULFA/TRIM	VANC
1	C		S	S	S		S	S	S
2	C	R	R	R	S		S	S	S
3	N	S	S	S	S		S	S	S
4	C	R	R	R	R		S	S	S
5	C	S	S	S	S	S	S	S	S
6	N	S	S	R	R	S	R	S	S
7	N	R	I	S	S	S	S	S	S
8	C	S	S	S	S	S	S	S	S
9	C	S	S	S	S	S	S	S	S
10	C	S	S	S	S	S	S	S	S
11	C	R	R	S	S	S	S	S	S
12	N	R	R	S	S	S	S	S	S
13	C	S	S	S	S	S	S	S	S
14	N	R	R	S	S	S	S	S	S
15	C	S	S	S	S	S	S	S	S
16	C	S	S	S	S	S	S	S	S
17	C	S	S	R	S	S	S	S	S
18	C	S	S	S	S	S	S	S	S
19	C	R	R		S		S	S	S
20	N		S	S	S		S	S	S
21	N	R	R		R		S	S	S
22	C		R		S		S	S	S
23	C		S	S	S		S	S	S

TABLE 6 (CONTINUED). SENSITIVITIES TO ANTIBIOTICS TESTED* FOR EACH OPHTHALMIC MRSA ISOLATE

SUBJECT NO.	NOSOCOMIAL VS COMMUNITY-ACQUIRED	CIPRO	LEVO	TET	GENT	AMIK	RIF	SULFA/TRIM	VANC
24	C		S	S	S			S	S
25	N		S	S	S		S	S	S
26	C		S	S	S		S	S	S
27	C		R	S	S		S	S	S
28	C		S	S	S		S	S	S
29	N		I	R	S		S	S	S
30	C		S	S	S		S	S	S
31	N		S	S	S		S	S	S
32	N		S	S	S		S	S	S
33	C		S	S	S		S	S	S
34	C		S	S	S		S	S	S
35	C		R	S	S		S	S	S
36	N		S	S	S		S	S	S
37	C		S	R	S		S	S	S
38	C		S	S	S		S	S	S
39	C		S	S	S		S	S	S
40	C		S	S	S		S	S	S
41	C		S	S	S		S	S	S
42	C		S	R	S		S	S	S
43	C		S	S	S		S	S	S
44	C		S	S	S		S	S	S
45	C		S	S	S		S	S	S
46	C		S	S	S		S	S	S
47	C		S	R	S		S	S	S
48	C			S	S		S	S	S
49	C			S	S		S	S	S

Amik = amikacin; C = community-acquired; Cipro = ciprofloxacin; Gent = gentamicin; I = intermediate (reduced) sensitivity; Levo = levofloxacin; MRSA = methicillin-resistant *Staphylococcus aureus*; N= nosocomial; R = resistant; Rif = rifampin; S = sensitive; Sulfa/Trim = sulfamethoxazole/trimethoprim; Tet = tetracycline; Vanc = vancomycin.

* Not all antibiotics were tested for each isolate.

CONJUNCTIVITIS

Six (54%) of the 11 patients with MRSA conjunctivitis were infants under 1 month of age, and the four cases (36%) of nosocomial infection were in infants; the seven other cases (64%) were community-acquired. In one of the infants classified as having community-acquired infection, culture was performed within 48 hours of birth, and there was no evidence of transplacental transmission. In the other infant, culture was obtained on an outpatient basis, and evidence of prior hospitalization was lacking.

CORNEAL ULCER

Three of the five patients with MRSA keratitis had nosocomial infection. All but one was begun on effective antibiotic coverage empirically. That patient had atopic dermatitis with a history of shield ulcers bilaterally and was started on ciprofloxacin ophthalmic drops. The isolate proved resistant to both levofloxacin and ciprofloxacin. Of the other patients, two had a history of cocaine use (one

with definite crack keratopathy), one had preceding herpes zoster ophthalmicus after decompressive craniotomy for intraparenchymal hematoma due to motor vehicle collision, and one suffered trauma to the eye when a container of medical waste exploded. The latter patient was considered to have nosocomial infection, and the MRSA isolate had reduced susceptibility to levofloxacin and resistance to tetracycline.

ENDOGENOUS ENDOPHTHALMITIS

All four patients with endogenous endophthalmitis had CA-MRSA by our definition; however, one patient presenting with osteomyelitis had been an inpatient in another hospital for 3 days 1 month previously on account of an acute ankle fracture due to a motor vehicle collision. Another patient lived in a long-term nursing home facility, so healthcare-associated infection cannot be ruled out. One had a history of intravenous drug abuse, two were diabetic, two were hypertensive, and three were alcoholic. All four patients had positive blood cultures for MRSA. Three patients received vancomycin and ceftazidime intravitreally after cultures were performed either by means of pars plana vitrectomy (two cases) or vitreous tap (one case). The fourth patient was started on vancomycin and gentamicin intravenously for his bacteremia, and the eye was eviscerated.

ORBITAL CELLULITIS

There were three cases of orbital cellulitis, two accompanied by endophthalmitis. One of these cases was nosocomial involving a 54-year-old man with T-cell lymphoma living in a long-term nursing home facility. Cefuroxime and clindamycin were begun intravenously prior to the culture results, and the eye was enucleated and the orbit biopsied. The other 45-year-old male patient had CA-MRSA, was begun on vancomycin and ceftazidime intravenously prior to culture results, and underwent orbitotomy and pars plana vitrectomy.

A third case of MRSA orbital cellulitis, community-acquired, occurred in a 43-year-old diabetic female intravenous drug abuser with hepatitis C. She had an orbital abscess not involving the globe, and empirical therapy with intravenous ceftriaxone and clindamycin was begun prior to culture results. She ultimately underwent a total of three orbital drainage procedures before resolution.

BLEBITIS

In both patients with MRSA blebitis, topical vancomycin and tobramycin therapy was begun prior to culture results. In one patient, a nosocomial infection developed 12 weeks after bleb revision, and in the other, MRSA blebitis began 4.5 months after trabeculectomy.

DACROCYSTITIS

Both dacryocystitis cases were community-acquired infections. In a 39-year-old woman, empirical therapy with dicloxacillin was begun, and incision and drainage was required prior to dacryocystorhinostomy. In an 8-year-old boy with a history of dacryostenosis and sickle C disease, empirical therapy with cefdinir was begun, and the patient did not require surgery.

DISCUSSION

Penicillin is inactivated by β -lactamase, a serine protease that hydrolyzes the β -lactam ring. Production of β -lactamase is widespread in *S aureus* and may be conferred by the *blaZ* gene.²⁹ Less than 5% of all *S aureus* isolates remain sensitive to penicillin.¹ Methicillin resistance results from one of three known mechanisms⁸⁶: hyperproduction of β -lactamases; modification of normal penicillin binding proteins; or, most commonly, production of an altered penicillin binding protein, PBP2a, which has decreased affinity for most β -lactam antibiotics, including penicillins, cephalosporins, β -lactam/ β -lactamase inhibitor combinations, monobactams, and carbapenems.⁸⁶⁻⁹⁰ PBP2a is encoded by the gene *mecA* on a mobile genetic element, the staphylococcal cassette chromosome (SCC) *mec*.^{87,91} De novo development of MRSA occurs when a strain of MSSA acquires SCC*mec*.^{92,93} The *mec* genes likely originated from a different species of staphylococci.^{94,95} Although antibiotic therapy does not cause the genetic mutation, it rewards the mutation with a selective advantage to survive.⁹⁶ At least five types of SCC*mec* elements have been identified, numbered I to V.^{97,98} Type I SCC*mec* contains the *mecA* gene as the sole resistance determinant, whereas SCC*mec* types II and III also contain determinants for resistance to non- β -lactam antibiotics.²⁹ Because of their larger size, horizontal transfer of SCC*mec* types II and III occurs less easily than with type IV,^{87,99-103} so spread of MRSA strains with SCC*mec* types II and III mainly occurs due to selective pressure of antibiotic exposure over time (vertical spread).⁹⁷ SCC*mec* types II and III are commonly found in multidrug-resistant nosocomial MRSA isolates.²⁹

Genetic analysis of MRSA strains from around the world revealed that transfer of SCC*mec* to a MSSA strain has occurred only a few times, so the emergence of MRSA has resulted from dissemination of only a few clonal types rather than the development of new MRSA clones.^{92,93,95,104-109} Thus virtually all patients with MRSA infection or colonization acquire their strain from an external source.^{93,107,109} The success reported in controlling MRSA with rigorous infection control practices supports the premise that transmission is the major factor contributing to the increasing prevalence of MRSA.⁹⁶ Whereas antibiotic therapy is an important risk factor for MRSA by providing a selective advantage for its survival and spread,¹⁰⁹ there have been no published reports of the eradication of MRSA through antibiotic control programs alone.⁹⁶

DISRUPTING THE TRANSMISSION OF MRSA

The spread of infection from patient to patient by contaminated healthcare workers was noted over 150 years ago by Holmes¹¹⁰ and Semmelweis.¹¹¹ Most transmission of MRSA in hospital inpatients is thought to be via transiently colonized healthcare workers.^{56,112} Environmental contamination may be the source for some spread. Boyce and coworkers¹¹³ found that 73% of hospital rooms with patients infected with MRSA and 69% of rooms with patients colonized with MRSA had some environmental contamination. In the same study, nurses contaminated their gloves 42% of the time despite touching only environmental surfaces in rooms of MRSA patients, whereas another report showed similar contamination of bare hands from surfaces.¹¹⁴ Other potential environmental reservoirs reported include computer keyboards used by clinicians,¹¹⁵ blood pressure cuffs,¹¹⁶ showers,¹¹⁶ and bathtubs.⁵⁶ MRSA may survive for weeks or months on various surfaces.¹¹⁷ Dietz and coworkers¹¹⁸ found that MRSA could survive on the external surfaces of sterile goods packages for over 38 weeks. Hand hygiene may be the single most important measure for controlling transmission of MRSA and other multidrug-resistant organisms.⁹⁶ Overcrowding and understaffing in hospitals are also risk factors for the spread of MRSA.^{119,120} Herr and colleagues¹²¹ found that the construction of more single-bed hospital rooms not only would help prevent spread of MRSA but would eliminate a major source of cost of isolation: the cost of an unoccupied bed when a single patient is isolated in a two-bed room.

Although the high usage of antibiotics in the healthcare environment provides a selective advantage that facilitates spread of MRSA, successful eradication programs have relied primarily on preventing person-to-person spread with less emphasis on antibiotic control.^{58,96,120,122,123} Success in controlling nosocomial MRSA has been greatest in countries that adhere to rigorous infection control policies that include surveillance cultures to identify colonized patients and strict application of barrier precautions for patients colonized or infected with MRSA.¹²⁴⁻¹²⁶ Isolation only of patients detected by routine clinical microbiologic cultures provides little benefit in high-risk areas.¹²² A French study involving 14 ICUs found that over half of patients colonized with MRSA did not have a positive clinical culture and would not have been detected without screening cultures.¹²⁷ The study concluded that it was more cost effective to isolate all ICU patients on admission and remove them from isolation only if admission screening cultures were negative. At Parkland Memorial Hospital, MRSA was endemic in the neonatal ICU from 1987 through 1991, but MRSA has been controlled since then by strict adherence to hand hygiene, contact isolation, and cohorting of culture-positive infants.

Isolation measures are intended to disrupt transmission of MRSA and include isolation wards for known or suspected carriers, nurse cohorting (designated staff assigned to care for MRSA patients segregated from the rest of the ward), single-bed rooms, and barrier precautions (gowns, gloves, and even masks used by healthcare workers to prevent transmission). Cooper and associates¹¹² found that despite the lack of well-designed studies, there was evidence that efforts that include isolation can reduce MRSA even in endemic settings. However, healthcare workers may spend less time with isolation patients, and isolation patients may have higher rates of pressure sores, falls, and fluid or electrolyte disorders than other patients.¹²⁸

EMERGENCE OF MRSA IN THE COMMUNITY

The prevalence rate of MRSA among *S aureus* isolates in US hospitals is now over 50%,¹²⁹ and is greater than 80% in some.¹⁰⁹ MRSA is increasingly prevalent in the Parkland Health and Hospital System. Although Parkland's hospital admissions and emergency department visits have remained relatively constant during the period 2000 through 2004, outpatient visits at the main campus, as well as at community-based outpatient primary care clinics in the system, have increased, yet the increase in MRSA is proportionally greater than the increase in visit volume in the system ($P < .0001$). Whereas the prevalence of MRSA has increased in hospitals worldwide, until recently strains were uncommon in the community. The absence of antibiotic selective pressure favoring their survival and attenuated virulence were thought to make resistant organisms unable to compete in the community.¹³⁰ In the mid-1990s, though, reports began to appear in the United States, particularly among children, of MRSA infection in patients without identifiable risk factors,^{23,131} reminiscent of the appearance of penicillinase-producing strains of MRSA in the community two decades previously.¹²⁹ Since then, CA-MRSA has been on the rise. At Harbor-UCLA Medical Center, 62% of community-associated *S aureus* infections are due to MRSA.¹³² Seventy-six percent of all *S aureus* isolates are methicillin-resistant at San Francisco General Hospital's Integrated Soft Tissue Infection Clinic.¹³³ Among patients presenting to an Oakland county hospital emergency room with community-acquired skin and soft tissue infections, 77% of *S aureus* isolates were methicillin-resistant.¹³⁴ It is not feasible to determine the true background rate of MRSA carriage in the community.^{86,129} Unlike nosocomial strains, CA-MRSA strains usually have the smaller SCCmec type IV cassette, suggesting the possibility of increased mobility and easier transfer via plasmids or bacteriophages.¹³⁵⁻¹³⁷

The two MRSA clones in the United States most closely associated with community outbreaks are pulsed field types USA300 (multilocus sequence type ST8) and USA400 (ST1 lineage).^{132,138-140} These CA-MRSA strains are only distantly related to nosocomial strains and represent novel acquisitions of SCCmec.¹⁴¹ There is some evidence that the acquisition of Panton-Valentine leukocidin, a staphylococcal membrane toxin that targets leukocytes, is the principal virulence factor responsible for the spread of CA-MRSA.^{130,142-144} Panton-Valentine leukocidin causes tissue necrosis and leukocyte destruction and has been linked to recurrent, often severe primary skin infections as well as necrotizing pneumonia.¹⁴⁵ The *pvl* genes that encode for Panton-Valentine leukocidin are rarely found in MSSA or nosocomial MRSA isolates.¹³⁰ These genes, however, are found not only in successful community-acquired clones in the United States^{138,140} but also around the world.¹⁴⁴ It is possible that the *pvl* locus is only a marker for other virulence or fitness determinants.¹³⁰

The most common manifestations of CA-MRSA are skin and soft tissue infections,^{26,132-134,138,140,146} and the lesion may be mistaken for a spider bite.^{26,147} Two of the current series' patients with CA-MRSA preseptal cellulitis were originally diagnosed as having

insect bites. Patients with CA-MRSA are often younger than patients with nosocomial infection.¹³⁸ Prior exposure to antibiotics has been implicated as a risk factor for development of CA-MRSA infection.^{140,148} Other risk factors may include homelessness,^{133,134} low socioeconomic status,^{138,149,150} injection drug use,^{132-134,151,152} previous MRSA infection, diabetes, chronic hepatitis C, cancer, and HIV infection.¹³² Outbreaks have been reported among jail inmates^{25,26,28,153} and among athletes who share equipment.^{27,140} In one study of necrotizing fasciitis caused by CA-MRSA, four of 14 patients had no identifiable risk factors.¹³² Unlike nosocomial MRSA isolates, which are more likely to be resistant to multiple other antibiotics, CA-MRSA isolates are more likely to be sensitive to other antibiotics (other than β -lactams).¹³⁸ For many types of CA-MRSA infections, there is little track record for the use of oral antibiotics to which isolates show in vitro susceptibility, so vancomycin remains, for now, the preferred antibiotic for empirical coverage of suspected CA-MRSA infections.¹³⁰

The lack of standardized criteria for classifying MRSA infection as community-acquired makes it difficult to compare published studies.⁸⁶ Parkland considers MRSA colonization or infection to be nosocomial if the patient had been hospitalized for 48 hours prior to obtaining the culture or if the patient had been hospitalized at Parkland Memorial Hospital in the previous 6 months. All other instances are considered community-acquired. These definitions are based on the Centers for Disease Control and Prevention's definitions of nosocomial infection¹⁵⁴ and serve to help Parkland identify if the hospital has new outbreaks of MRSA but ignore the possibility that the patient acquired MRSA in a healthcare environment beyond the traditional healthcare setting. Salgado and colleagues¹⁵⁵ proposed the term "community onset" for infections seemingly acquired outside the hospital setting. They found a MRSA colonization rate in the community of 1.3% when several studies were pooled. However, among studies that excluded subjects with healthcare contacts, the pooled community MRSA colonization rate was only 0.2%. Friedman and associates¹⁵⁶ suggested that bloodstream infections be classified as hospital-acquired, healthcare-associated, or community-acquired. They labeled an infection healthcare-associated if the patient received intravenous therapy at home, wound care or specialized nursing through a healthcare agency, family, or friends, or self-administered intravenous medical therapy within 30 days before infection; was hospitalized in an acute care hospital for 2 or more days in the preceding 3 months; or resided in a nursing home or long-term care facility. One of the 37 patients considered to have ophthalmic CA-MRSA by the study definition definitely would be considered to have healthcare-associated MRSA infection by the above definition (the patient resided in a long-term care facility and developed bacteremia and endogenous endophthalmitis). Like the healthcare-associated MRSA isolates in a recent report by Lesens and coworkers,¹⁵⁷ the isolate in this study from a nursing home patient with endogenous endophthalmitis behaved more like a nosocomial MRSA isolate in that it was resistant to fluoroquinolones and aminoglycosides. Another case of endogenous endophthalmitis was classified as CA-MRSA by the study definition despite the patient having been hospitalized elsewhere 1 month previously. Other cases possibly could have been missed owing to inadequate documentation in the medical record. Two patients with preseptal cellulitis had undergone day surgery prior to infection (one 2 weeks prior, the other 2 months) and one case of CA-MRSA blebitis occurred 4.5 months after trabeculectomy. These three cases could possibly be considered to have healthcare-associated MRSA infection, though all three isolates were sensitive to the non- β -lactam antibiotics tested.

Because CA-MRSA has a predilection for causing skin and soft tissue infections, it is not surprising that most MRSA infections in our series involved the lids with preseptal cellulitis, lid abscess, or both. Whether initial therapy with an antibiotic active against MRSA even affects the outcome of skin and soft tissue infections is uncertain.¹³⁰ Appropriate drainage is the definitive management of many skin and soft tissue infections and is an important adjunct to antibiotic therapy in deep, closed-space infections.²⁹ Abscesses left without drainage in the setting of antibiotic resistance may promote the emergence of resistance.¹⁵⁸ Data from the surgical literature suggest that, at least with skin and soft tissue infections, adequate surgical drainage allows many CA-MRSA infections to resolve regardless of whether the isolate is susceptible in vitro to the antibiotic chosen.^{133,134} It has been suggested that infections caused by CA-MRSA may be less virulent and have a more subacute onset than similar infections caused by other organisms.¹³² In the current series, 16 (73%) of 22 cases of lid infections had empirical antibiotics started that did not cover MRSA, and seven cases (32%) resolved despite receiving only β -lactam antibiotics or cephalosporins. Thirteen (59%) of the 22 cases formed lid abscesses, and most were incised or spontaneously drained (11 of 13, or 85%). We recently reviewed all cases of preseptal cellulitis seen at Parkland Memorial Hospital (excluding cases only seen in the community outpatient primary care clinics) for the years 2000 through 2004. Although half of the 48 cases were culture-negative, 18 (38%) of the culture-positive cases grew *S aureus*, and 16 of those isolates (89%) were methicillin-resistant (Witherspoon SR, ARVO Meeting, 2006, Abstract). This high prevalence of methicillin resistance combined with the 86% rate of MRSA lid infections being community-acquired in the present study would indicate a high prevalence of methicillin resistance in *S aureus* strains in the Dallas community. I am now more apt to treat community lid infections in Dallas with antibiotics other than with β -lactams or cephalosporins and to recommend incision and drainage of lesions. Zetola and colleagues²⁹ recommend against the use of vancomycin as empirical treatment of furuncles and nonsevere skin and soft tissue infections.

IMPLICATIONS FOR THE PRACTICING OPHTHALMOLOGIST

Ophthalmic MRSA infection appears to be increasingly prevalent in the Parkland System. Although it is difficult to identify all other non-MRSA ophthalmic infections over the 5-year study period, I recently reviewed all culture-positive corneal ulcers, endophthalmitis, and blebitis seen at Parkland (P.H. Blomquist, MD, unpublished data, 2006). All MRSA corneal ulcers, endophthalmitis, and blebitis during the study period had been seen by the Ophthalmology Service. In addition, we had reviewed all preseptal cellulitis and orbital cellulitis seen at Parkland Memorial Hospital (Witherspoon SR, ARVO Meeting, 2006, Abstract).

Combining the two data sets provided the information in Table 7. Whereas non-MRSA ophthalmic infections reviewed remained relatively level, numbers of MRSA ophthalmic infections were generally higher in more recent years ($P = .042$).

TABLE 7. CULTURE-POSITIVE OPHTHALMIC INFECTIONS* AT PARKLAND MEMORIAL HOSPITAL, 2000 – 2004, BY YEAR

Infection	2000	2001	2002	2003	2004
MRSA	3	2	8	3	14
Non- MRSA	23	20	24	27	28

*Includes all corneal ulcers, endophthalmitis, and blebitis seen by the Ophthalmology service at Parkland as well as all preseptal and orbital cellulitis seen at Parkland Memorial Hospital.

To my knowledge, this study includes the first cases reported of MRSA blebitis. Traditionally, streptococci and *Haemophilus influenzae* are the most common pathogens cultured in bleb-associated endophthalmitis.¹⁵⁹⁻¹⁶¹ Whereas *S aureus* has been described as a causative agent in blebitis¹⁶² and bleb-associated endophthalmitis,¹⁶³ methicillin resistance was not reported by the authors. Of seven total cases of blebitis at Parkland during the years 2000 through 2004, two were due to MRSA, two grew MSSA and streptococci, and three were culture-negative. Similarly, although MRSA has been reported as a cause of endophthalmitis after surgery,^{67,72,74} the current series is the first to clearly identify MRSA as a cause of endogenous endophthalmitis. That MRSA can cause such serious ocular infections is worrisome. We recently reviewed all orbital cellulitis cases seen at Parkland Memorial Hospital for the years 2000 through 2004. Of the 29 cases seen during that time, 10 (34%) were culture-negative, and four (14%) grew MRSA (Witherspoon SR, ARVO Meeting, 2006, Abstract). In the fourth case of MRSA orbital cellulitis, the patient had been transferred to Parkland. Because the cultures were done at the outside hospital and not at Parkland, this case was not included in the MRSA infection control database.

What are the implications of an increasing prevalence of MRSA in the community for the practicing ophthalmologist? Just as in the hospital setting, the healthcare worker can unknowingly spread MRSA from patient to patient. Lam and coworkers¹⁶⁴ looked at microbial hand contamination among ophthalmologists in a tertiary care outpatient practice and found an increase in prevalence of transient flora, including MRSA, after patient contact. Hand washing reduced the resident and transient flora load by at least an order of magnitude. Yet, historically, studies assessing compliance with hand hygiene have shown low compliance rates, averaging approximately 40% and ranging as low as 10%.⁹⁶ Chlorhexidine gluconate is frequently recommended for hand washing on account of low toxicity and broad antimicrobial spectrum.^{165,166}

Standard antibiotic regimens that assume that local strains of *S aureus* are sensitive to β -lactams need to be reevaluated in MRSA endemic areas.¹⁶⁷ Vancomycin eyedrops can be prepared by mixing an ampule intended for intravenous use with phosphate-buffered artificial tears. The solution retains in vitro antistaphylococcal activity for at least 2 weeks without refrigeration¹⁶⁸ and is usually used at a concentration of 50 mg/mL,¹⁶⁸⁻¹⁷⁰ though a concentration of 31 mg/mL has been used.⁵⁰ Although vancomycin is certainly the standard for MRSA infections at present, widescale use is a known risk factor for the development of VRE,⁵³ and long-term use is a risk factor for reduced susceptibility and frank resistance in *S aureus*.^{44,46,47} The Hospital Infection Control Practices Advisory Committee strongly advises against the routine use of vancomycin for prophylaxis.¹⁷¹ Yet vancomycin is used, including at Parkland Memorial Hospital, for the prophylaxis of endophthalmitis after open globe injury.¹⁷² Even more patients in the United States routinely receive prophylactic intracameral vancomycin during cataract surgery,¹⁷³ an operation where endophthalmitis is a rare event, occurring in only 2.15 cases per 1,000, according to a recent review of Medicare data from 1994 through 2001.¹⁷⁴ The prophylactic efficacy of intracameral vancomycin has been questioned.¹⁷⁵⁻¹⁷⁷ Studies have failed to demonstrate that vancomycin prophylaxis significantly reduced residual bacteria in the anterior chamber,^{178,179} and vancomycin may not remain in the anterior chamber long enough to have a bactericidal effect.¹⁸⁰ Indeed, a significantly lower rate (0.84 cases per 10,000) of endophthalmitis after cataract surgery performed at the affiliated hospitals of the University of Texas Southwestern Medical Center (including Parkland Memorial Hospital) from 1995 to 2002 has been reported despite not using intracameral antibiotics.¹⁸¹

However, even though there have been worries about the use of vancomycin prophylaxis at the time of cataract surgery on account of cost,¹⁷⁵ potential for dilution error,¹⁸² and adverse effects on the eye (including cystoid macular edema),¹⁸³ Gordon¹⁷⁵ believes that ophthalmic use of vancomycin is unlikely to be a serious selection factor for promoting resistance. Libre and associates¹⁸⁴ believe that the intraocular use of antibiotics is extremely unlikely to promote the development of drug-resistant organisms, because the intraocular environment rarely harbors colonizing organisms. However, it is known that topical antibiotics can cause bacterial resistance at the site of application in the conjunctiva, cornea, and lids,¹⁸⁵ and recently the first report of topical ocular antibiotics inducing bacterial resistance at extraocular sites was reported.¹⁸⁶ Perhaps intraocular surgeons should reevaluate the practice of using vancomycin for prophylaxis.

What changes are necessary in the ophthalmologist's practice in view of increasing bacterial resistance in the community? First, healthcare workers, including those in outpatient settings, must remove transient microorganisms from hands by using hand washing or hand antisepsis between all patient contacts and after contact with inanimate objects in the immediate vicinity of patients.¹⁸⁷ Eye lane surfaces and hand instruments should be cleaned periodically. Contact isolation measures should be instituted for patients known to be harboring resistant organisms like MRSA. Protective gloves and gowns are used in the Parkland ophthalmology outpatient clinics, a dedicated isolation eye lane is used to examine MRSA and VRE patients, and all surfaces and instruments are cleaned after

the patient is discharged from the room.⁹⁶ Although gloves greatly reduce the risk of hand contamination, they do not obviate the need for hand washing after their removal.^{188,189} Use of a mask may be of some benefit in preventing nasal acquisition of MRSA by healthcare workers.⁹⁶ Indeed, the Centers for Disease Control and Prevention has recommended the use of a mask when caring for patients with *S aureus* with reduced susceptibility or resistance to vancomycin.⁴⁶ It is difficult in many outpatient practices to identify MRSA and VRE patients; the establishment of electronic medical record systems may aid in this endeavor. For example, Parkland uses a tracking flag in the electronic patient management system to identify MRSA and VRE patients, thus alerting the healthcare team to take contact isolation precautions. Currently, there are no data to suggest that treatment to eradicate colonized patients with CA-MRSA is necessary or effective in the long term,^{7,138,190} and resistance to antibiotics used for decolonization has evolved rapidly when attempted.¹⁹¹⁻¹⁹³

In the absence of a history of MRSA or VRE, a high level of suspicion is needed when patients have risk factors for nosocomial or healthcare-associated infections. In areas with endemic CA-MRSA, incision, drainage, and culturing of simple lid abscesses should be considered.²⁶ Consider the possibility of CA-MRSA for cases with the appearance of a spider or insect bite; if there is a history of contact with a correctional facility (either as a prisoner or a visitor); if there is a history of playing contact sports or association with a sports facility; or if a skin or soft tissue infection is recurrent.¹⁴⁷ In addition to draining suppurative collections, consider removing foreign devices such as infected scleral buckles,⁸³ because the likelihood of sterilizing an infected site in the presence of a foreign device is low.¹

Empirical antibiotic therapy should include coverage for MRSA in endemic areas; β -lactam antibiotics may not be appropriate for empirical treatment of suspected staphylococcal infections.¹³⁸ It may not be necessary to use vancomycin for coverage, because most CA-MRSA strains are susceptible to other antibiotics, such as tetracycline and aminoglycosides.^{138,167} Resistance to older quinolones is common among MRSA and occurs in as many as 90% of isolates in some hospitals.²² Resistance was found to ciprofloxacin and levofloxacin also in the current study of ophthalmic isolates, especially from nosocomial infections. Chloramphenicol eyedrops have been used to treat MRSA external ocular infections,^{30,51} but chloramphenicol is not widely used on account of the risk of developing aplastic anemia with its use.^{194,195} I tend to avoid clindamycin because of the risk of development of inducible clindamycin resistance in CA-MRSA strains that are erythromycin-resistant by virtue of carrying the *erm* (erythromycin ribosome methylase) gene.^{147,196,197} Inducible resistance to clindamycin may not be apparent on routine susceptibility testing.¹⁹⁸⁻²⁰⁰ Frazee and associates¹³⁴ recommended using the combination of trimethoprim-sulfamethoxazole and cephalexin for oral therapy of moderate to severe skin and soft tissue infections, with cephalexin used to cover for *Streptococcus pyogenes*. For minor infections in adults, they recommended doxycycline.

Prescribed treatment regimens should be appropriate in both dose and duration, because inadequate dose or inadequate or excessive duration of therapy may make development of resistance more likely.^{96,201} Steps should be taken to decrease the occurrence of new resistant strains by adhering to guidelines advocating against the routine prophylactic use of vancomycin in the hospital setting,^{171,177} and strong consideration should be given to eliminating the practice in other healthcare settings. Preoperative povidone-iodine antiseptic of the ocular surface has the most support in the literature for efficacy in preventing bacterial endophthalmitis after intraocular surgery and should be adopted. Although preoperative and postoperative topical application of broad-spectrum antibiotics and postoperative use of subconjunctival antibiotics remain common, the evidence is less clear regarding their efficacy,^{176,202} and prolonged topical postoperative antibiotic administration may predispose to development of antimicrobial resistance.^{177,202} Some investigators suggest avoiding simultaneous bilateral treatment for elective ocular procedures (eg, refractive surgery) on patients colonized with MRSA or who live or work in a healthcare environment,^{78,79} in addition to using a fourth-generation fluoroquinolone or bacitracin for preoperative prophylaxis.⁷⁸ In vitro studies have identified MRSA strains, however, that are resistant to fourth-generation fluoroquinolone antibiotic.^{203,204}

As MRSA increases in prevalence, early and accurate detection of colonized individuals will be important to prevent spread. Traditional antimicrobial susceptibility test methods require at least 24 hours to perform.⁸⁶ Polymerase chain reaction (PCR) analysis of donor eye preservation media for *spa* and *mecA* genes has been used to detect contamination with MRSA more rapidly than conventional culture.²⁰⁵ However, PCR is not routinely used by most clinical diagnostic laboratories.⁸⁶ Newer detection methods for MRSA have been developed, including the BBL Crystal MRSA ID System (Becton Dickinson, Sparks, Maryland), which uses a fluorescent indicator of dissolved oxygen in broth as a marker for bacterial growth in wells containing oxygen; Velogene Rapid MRSA Identification Assay (Alexon-Trend, Inc, Ramsey, Minnesota), a colorimetric enzyme immunoassay utilizing a *mecA* gene probe; and the MRSA-Screen (Denk Deiken Co, Tokyo, Japan), a slide latex agglutination test utilizing a monoclonal antibody against PBP2a.⁸⁶ These tests promise results within 4 hours to as little as 15 minutes.⁸⁶

New antibiotic classes with good activity against gram-positive organisms (such as ketolides and oxazolidinones) show promise in the treatment of MRSA,²⁰⁶ as may new versions of older compounds like streptogramins and quinolones.^{167,196} However, antibiotic resistance even to newer antibiotics like linezolid has already been reported.²⁰⁷ Teicoplanin, another glycopeptide antibiotic, is intrinsically less effective against *S aureus* than vancomycin and is unlikely to be effective in strains with reduced vancomycin susceptibility or frank resistance.^{208,209} In view of increasing antimicrobial resistance worldwide, will physicians need to turn to alternative agents to treat bacterial infections as they did prior to the discovery of antibiotics? MRSA conjunctivitis has been treated with the antiseptic benzethonium chloride 0.02%.⁵⁵ Lysostaphin is a zinc metalloproteinase extracted from *Staphylococcus simulans* that lyses *S aureus* by disrupting its peptidoglycan layer.^{210,211} Lysostaphin has been shown to be effective in treating experimental MRSA keratitis and endophthalmitis.^{212,213} Another potentially useful enzyme, LasA protease (also called staphylolysin), is a staphylolytic endopeptidase secreted by *Pseudomonas aeruginosa* that also targets the peptidoglycan of *S aureus*.²¹⁴⁻²¹⁶ LasA protease was comparable to vancomycin in experimental MRSA keratitis when treatment was started early and was more effective than

vancomycin when treatment was started late.²¹⁷ This suggests that LasA protease can lyse bacterial cell walls during the bacteria's stationary phase of growth, unlike vancomycin.^{212,218} A vaccine for *S aureus* has been evaluated experimentally and clinically.²¹⁹⁻²²¹ Antimicrobial resistance to penicillin, methicillin, and vancomycin is an inevitable consequence of the selective pressure of antibiotic exposure.¹²⁹ Ophthalmologists need to be prepared to identify and treat resistant strains and take steps to control the emergence and spread of resistant strains, both in the hospital and in the community.

REFERENCES

1. Lowy FD. *Staphylococcus aureus* infections. *N Engl J Med* 1998;339:520-532.
2. Novick RP. The staphylococcus as a molecular genetic system. In: Novick RP, ed. *Molecular Biology of the Staphylococci*. New York: VCH; 1990:1-37.
3. Schaberg DR, Zervos MJ. Intergeneric and interspecies gene exchange in gram-positive cocci. *Antimicrob Agents Chemother* 1986;30:817-822.
4. Noble WC, Valkenburg HA, Wolters CHL. Carriage of *Staphylococcus aureus* in random samples of a normal population. *J Hyg (Lond)* 1967;65:567-573.
5. Casewell MW, Hill RLR. The carrier state: methicillin-resistant *Staphylococcus aureus*. *J Antimicrob Chemother* 1986;18(Suppl A):1-12.
6. Wenzel RP, Perl TM. The significance of nasal carriage of *Staphylococcus aureus* and the incidence of postoperative wound infection. *J Hosp Infect* 1995;31:13-24.
7. Brumfitt W, Hamilton-Miller J. Methicillin-resistant *Staphylococcus aureus*. *N Engl J Med* 1989;320:1188-1196.
8. Kirby WM. Extraction of a high potent penicillin inactivator from penicillin resistant staphylococci. *Science* 1944;99:452-453.
9. Barber M, Rozwadowska-Dowzenko M. Infection by penicillin-resistant staphylococci. *Lancet* 1948;1:641-644.
10. Kaye KS, Engemann JJ, Fraimow HS, et al. Pathogens resistant to antimicrobial agents: epidemiology, molecular mechanisms, and clinical management. *Infect Dis Clin North Am* 2004;18:467-511.
11. Barber M, Rozwadowska-Dowzenko M. Infection by penicillin-resistant staphylococci. *Lancet* 1948;2:641-644.
12. Jessen O, Rosendal K, Bulow P, et al. Changing staphylococci and staphylococcal infections. A ten-year study of bacteria and cases of bacteremia. *N Engl J Med* 1969;281:627-635.
13. Ross S, Rodriguez W, Controni G, et al. Staphylococcal susceptibility to penicillin G. The changing pattern among community strains. *JAMA* 1974;229:1075-1077.
14. Hughes GB, Chidi CC, Macon WL. Staphylococci in community-acquired infections: increased resistance to penicillin. *Ann Surg* 1976;183:355-357.
15. Hahn DL, Baker WA. Penicillin G susceptibility of "rural" *Staphylococcus aureus*. *J Fam Pract* 1980;11:43-46.
16. Robinson GN, Stevens S, Batchelor FR, et al. Bacteriological studies on a new penicillin—BRL.1241. *Lancet* 1960;2:564-567.
17. Jevons MP. "Celbenin"-resistant staphylococci. *Br J Med* 1961;1:124-125.
18. Knox R. "Celbenin"-resistant staphylococci. *Br J Med* 1961;1:126.
19. Gedney J, Lacey RW. Properties of methicillin-resistant staphylococci now endemic in Australia. *Med J Aust* 1982;1:448-450.
20. Pavillard R, Harvey K, Douglas D, et al. Epidemic of hospital-acquired infection due to methicillin-resistant *Staphylococcus aureus* in major Victorian hospitals. *Med J Aust* 1982;1:451-454.
21. Sahn DF, Marsilio MK, Piazza G. Antimicrobial resistance in key bloodstream bacterial isolates: electronic surveillance with the Surveillance Network Database—USA. *Clin Infect Dis* 1999;29:259-263.
22. Diekema DJ, Pfaller MA, Schmitz FJ, et al. Survey of infections due to *Staphylococcal* species: frequency of occurrence and antimicrobial susceptibility of isolates collected in the United States, Canada, Latin America, Europe, and the Western Pacific region for the SENTRY Antimicrobial Surveillance Program, 1997 – 1999. *Clin Infect Dis* 2001;32(suppl 2):S114-S132.
23. Herold BC, Immergluck LC, Maranan MC, et al. Community-acquired methicillin-resistant *Staphylococcus aureus* in children with no identified predisposing risk. *JAMA* 1998;279:593-598.
24. Centers for Disease Control and Prevention. Four pediatric deaths from community acquired methicillin-resistant *Staphylococcus aureus*—Minnesota and North Dakota, 1997—1999. *MMWR Morb Mortal Wkly Rep* 1999;48:707-710.
25. Centers for Disease Control and Prevention. Methicillin-resistant *Staphylococcus aureus* skin or soft tissue infections in a state prison—Mississippi 2000. *MMWR Morb Mortal Wkly Rep* 2001;50:919-922.
26. Centers for Disease Control and Prevention. Outbreaks of community-acquired methicillin-resistant *Staphylococcus aureus* skin infections—Los Angeles County, California, 2002—2003. *MMWR Morb Mortal Wkly Rep* 2003;52:88.
27. Centers for Disease Control and Prevention. Methicillin-resistant *Staphylococcus aureus* infections among competitive sports participants—Colorado, Indiana, Pennsylvania and Los Angeles County, 2000 – 2003. *MMWR Morb Mortal Wkly Rep* 2003;52:793-795.
28. Centers for Disease Control and Prevention. Methicillin-resistant *Staphylococcus aureus* infections in correctional facilities—Georgia, California and Texas, 2001 – 2003. *MMWR Morb Mortal Wkly Rep* 2003;52:992-996.
29. Zetola N, Francis JS, Nuermberger EL, et al. Community-acquired methicillin-resistant *Staphylococcus aureus*: an emerging threat. *Lancet Infect Dis* 2005;5:275-286.
30. Shanmuganathan VA, Armstrong M, Buller A, et al. External ocular infections due to methicillin-resistant *Staphylococcus aureus* (MRSA). *Eye* 2005;19:284-291.

31. Muder RR, Brennen C, Wagener MM, et al. Methicillin-resistant staphylococcal colonization and infection in a long-term care facility. *Ann Intern Med* 1991;114:107-112.
32. Leman R, Alvarado-Ramy F, Pocock S, et al. Nasal carriage of methicillin-resistant *Staphylococcus aureus* in an American Indian population. *Infect Hosp Control Epidemiol* 2004;25:121-125.
33. Cosgrove SE, Sakoulas G, Perencevich EN, et al. Comparison of mortality associated with methicillin-resistant and methicillin-susceptible *Staphylococcus aureus* bacteremia: a meta-analysis. *Clin Infect Dis* 2003;36:53-59.
34. Abramson MA, Sexton DJ. Nosocomial methicillin-resistant and methicillin-susceptible *Staphylococcus aureus* primary bacteremia: At what costs? *Infect Control Hosp Epidemiol* 1999;20:408-411.
35. Engemann JJ, Carmeli Y, Cosgrove SE, et al. Adverse clinical and economic outcomes attributable to methicillin resistance among patients with *Staphylococcus aureus* surgical site infection. *Clin Infect Dis* 2003;36:592-598.
36. Korzeniowski O, Sande MA. Combination antimicrobial therapy for *Staphylococcus aureus* endocarditis in patients addicted to parenteral drugs and in non-addicts. *Ann Intern Med* 1982;97:496-503.
37. Chambers HF, Miller RT, Newman MD. Right-sided *Staphylococcus aureus* endocarditis in intravenous drug abusers: two-week combination therapy. *Ann Intern Med* 1988;109:619-624.
38. Small PM, Chambers HF. Vancomycin for *Staphylococcus aureus* endocarditis in intravenous drug users. *Antimicrob Agents Chemother* 1990;34:1227-1231.
39. Levine DP, Fromm BS, Reddy BR. Slow response to vancomycin or vancomycin plus rifampin in methicillin-resistant *Staphylococcus aureus* endocarditis. *Ann Intern Med* 1991;115:674-680.
40. Hartstein AI, Mulligan ME, Morthland VH, et al. Recurrent *Staphylococcus aureus* bacteremia. *J Clin Microbiol* 1992;30:670-674.
41. Wilson WR, Karchmer AW, Dajani AS, et al. Antibiotic treatment of adults with infective endocarditis due to streptococci, enterococci, staphylococci, and HACEK microorganisms. American Heart Association. *JAMA* 1995;274:1706-1713.
42. Gonzalez C, Rubio M, Romero-Vivas J, et al. Bacteremic pneumonia due to *Staphylococcus aureus*: a comparison of disease caused by methicillin-resistant and methicillin-susceptible organisms. *Clin Infect Dis* 1999;29:1171-1177.
43. Schwalbe RS, Stapleton JT, Gilligan PH. Emergence of vancomycin resistance in coagulase-negative staphylococci. *N Engl J Med* 1987;316:927-931.
44. Hiramatsu K, Hanaki H, Ino T, et al. Methicillin-resistant *Staphylococcus aureus* clinical strain with reduced vancomycin susceptibility. *J Antimicrob Chemother* 1997;40:135-136.
45. Fridkin SK, Hageman J, McDougal LK, et al. Epidemiologic and microbiologic characterization of infections caused by *Staphylococcus aureus* with reduced susceptibility to vancomycin, United States, 1997 – 2001. *Clin Infect Dis* 2003;36:429-439.
46. Centers for Disease Control and Prevention. *Staphylococcus aureus* resistant to vancomycin—United States, 2002. *MMWR Morb Mortal Wkly Rep* 2002;51:565-567.
47. Chang S, Sievert DM, Hagerman JC, et al. Infection with vancomycin-resistant *Staphylococcus aureus* containing the *vanA* resistance gene. *N Engl J Med* 2003;348:1342-1347.
48. Noble WC, Virani Z, Cree RG. Co-transfer of vancomycin and other resistance genes from *Enterococcus faecalis* NCTC 12201 to *Staphylococcus aureus*. *FEMS Microbiol Lett* 1992;72:195-198.
49. Ribner BS. Endemic, multiply resistant *Staphylococcus aureus* in a pediatric population. *Am J Dis Child* 1987;141:1183-1187.
50. Ross J, Abate MA. Topical vancomycin for the treatment of *Staphylococcus epidermidis* and methicillin-resistant *Staphylococcus aureus* conjunctivitis. *DICP* 1990;24:1050, 1053.
51. Fukuda M, Ohashi H, Matsumoto C, et al. Methicillin-resistant *Staphylococcus aureus* and methicillin-resistant coagulase-negative *Staphylococcus* ocular surface infection: efficacy of chloramphenicol eye drops. *Cornea* 2002;21(7 suppl):S86-S89.
52. Brennen C, Muder RR. Conjunctivitis associated with methicillin-resistant *Staphylococcus aureus* in a long-term-care facility. *Am J Med* 1990;88(5N):14N-17N.
53. Rubin LG, Tucci V, Cercenado E, et al. Vancomycin-resistant *Enterococcus faecium* in hospitalized children. *Infect Control Hosp Epidemiol* 1992;13:700-705.
54. Spindel SJ, Strausbaugh LJ, Jacobson C. Infections caused by *Staphylococcus aureus* in a veterans' affairs nursing home care unit: a 5-year experience. *Infect Control Hosp Epidemiol* 1995;16:217-223.
55. Horil T, Futamura N, Suzuki Y. Antiseptic treatment of methicillin-resistant *Staphylococcus aureus* conjunctivitis. *J Infect* 2001;42:166-169.
56. Mitsuda T, Arai K, Fujita S, et al. Epidemiological analysis of strains of methicillin-resistant *Staphylococcus aureus* (MRSA) infection in the nursery; prognosis of MRSA carrier infants. *J Hosp Infect* 1995;31:123-134.
57. Hayakawa T, Hayashidera T, Yoneda K, et al. Unexpectedly prolonged colonization of exfoliative toxin A-producing methicillin-resistant *Staphylococcus aureus* in infants. *Eur J Pediatr* 1998;157:781.
58. Jernigan JA, Titus MG, Groschel DH, et al. Effectiveness of contact isolation during a hospital outbreak of methicillin-resistant *Staphylococcus aureus*. *Am J Epidemiol* 1996;143:496-504.
59. Saiman, L, Cronquist A, Wu F, et al. An outbreak of methicillin-resistant *Staphylococcus aureus* in a neonatal intensive care unit. *Infect Control Hosp Epidemiol* 2003;24:317-321.
60. Muder RR, Brennen C, Goetz AM. Infection with methicillin-resistant *Staphylococcus aureus* among hospital employees. *Infect Control Hosp Epidemiol* 1993;14:576-578.

61. Maskin SL. Infectious scleritis after a diabetic foot ulcer. *Am J Ophthalmol* 1993;115:254-255.
62. Eiferman RA, O'Neill KP, Morrison NA. Methicillin-resistant *Staphylococcus aureus* corneal ulcers. *Ann Ophthalmol* 1991;23:414-415.
63. Insler MS, Fish LA, Silbernagel J, et al. Successful treatment of methicillin-resistant *Staphylococcus aureus* keratitis with topical ciprofloxacin. *Ophthalmology* 1991;98:1690-1692.
64. Sotozono C, Inagaki K, Fujita A, et al. Methicillin-resistant *Staphylococcus aureus* and methicillin-resistant *Staphylococcus aureus* infections in the cornea. *Cornea* 2002;21(7 suppl):S94-S101.
65. Inoue Y. Ocular infections in patients with atopic dermatitis. *Int Ophthalmol Clin* 2002;42:55-69.
66. Labit CM, Claeys GW, Verbraeken HE, et al. Methicillin resistance of bacteria isolated from vitreous fluid from patients undergoing vitrectomy. *Eur J Ophthalmol* 2001;11:160-165.
67. Saitoh A, Jinbayashi H, Saitoh AK, et al. Parameter estimation and dosage adjustment in the treatment with vancomycin of methicillin-resistant *Staphylococcus aureus* ocular infections. *Ophthalmologica* 1997;211:232-235.
68. Kubo M, Sakuraba T, Arai Y, et al. Dacryocystorhinostomy for dacryocystitis caused by methicillin-resistant *Staphylococcus aureus*: report of four cases. *Jpn J Ophthalmol* 2002;46:177-182.
69. Mehra P, Caiazzo A, Bestgen S. Odontogenic sinusitis causing orbital cellulitis. *JADA* 1999;130:1086-1092.
70. Anari S, Karagama YG, Fulton B, et al. Neonatal disseminated methicillin-resistant *Staphylococcus aureus* presenting as orbital cellulitis. *J Laryngol Otol* 2005;119:64-67.
71. Kato T, Hayasaka S. Methicillin-resistant *Staphylococcus aureus* and methicillin-resistant coagulase-negative *Staphylococci* from conjunctivas of preoperative patients. *Jpn J Ophthalmol* 1988;42:461-465.
72. Cosar CB, Cohen EJ, Rapuano CJ, et al. Clear corneal wound infection after phacoemulsification. *Arch Ophthalmol* 2001;119:1755-1759.
73. Chiang RK, Rapuano CJ. Recurrent methicillin-resistant *Staphylococcus aureus* wound ulcer after clear-cornea cataract surgery. *CLAO J* 2002;28:109-110.
74. Moshirfar M, Marx DP, Mirzaian G. Endophthalmitis in patients using fourth-generation fluoroquinolones following phacoemulsification. *J Cataract Refract Surg* 2005;31:1669-1670.
75. Rudd JC, Moshirfar M. Methicillin-resistant *Staphylococcus aureus* keratitis after laser in situ keratomileusis. *J Cataract Refract Surg* 2001;27:471-473.
76. Rubinfeld RS, Negvesky GJ. Methicillin-resistant *Staphylococcus aureus* ulcerative keratitis after laser in situ keratomileusis. *J Cataract Refract Surg* 2001;27:1523-1525.
77. Förster W, Becker K, Hungermann D, et al. Methicillin-resistant *Staphylococcus aureus* after excimer laser photorefractive keratectomy. *J Cataract Refract Surg* 2002;28:722-724.
78. Solomon R, Donnenfeld ED, Perry HD, et al. Bilateral methicillin-resistant *Staphylococcus aureus* keratitis in a medical resident following an uneventful bilateral photorefractive keratectomy. *Eye Contact Lens* 2003;29:187-189.
79. Donnenfeld ED, O'Brien TP, Solomon R, et al. Infectious keratitis after photorefractive keratectomy. *Ophthalmology* 2003;110:743-747.
80. Leyden JJ, Marples RR, Kligman AM. *Staphylococcus aureus* in the lesions of atopic dermatitis. *Br J Dermatol* 1974;90:525-530.
81. Hanifin JM, Rogge JL. Staphylococcal infections in patients with atopic dermatitis. *Arch Dermatol* 1993;103:1315-1322.
82. Hoeger PH, Lenz W, Boutonnier A, et al. Staphylococcal skin colonization in children with atopic dermatitis: prevalence, persistence, and transmission of toxigenic and nontoxigenic strains. *J Infect Dis* 1992;165:1064-1068.
83. Oshima Y, Ohji M, Inoue Y, et al. Methicillin-resistant *Staphylococcus aureus* infections after scleral buckling procedures for retinal detachments associated with atopic dermatitis. *Ophthalmology* 1999;106:142-147.
84. Osawa S, Sasoh M, Ito K, et al. Exudative retinal detachment due to methicillin-resistant *Staphylococcus aureus* after scleral buckling in the treatment of retinal detachment accompanied by atopic dermatitis. *Retina* 2002;22:649-651.
85. Clinical and Laboratory Standards Institute/NCCLS. *Performance Standards for Antimicrobial Susceptibility Testing: Fifteenth Informational Supplement*. CLSI/NCCLS Document M100-S15. Wayne, Pennsylvania: CLSI; 2005.
86. Palavecino E. Community-acquired methicillin-resistant *Staphylococcus aureus* infections. *Clin Lab Med* 2004;24:403-418.
87. Chambers HF. Methicillin resistance in staphylococci: molecular and biochemical basis and chemical implications. *Clin Microbiol Rev* 1997;10:781-791.
88. Katayama Y, Zhang HZ, Hong D, et al. Jumping the barrier to beta-lactam resistance in *Staphylococcus aureus*. *J Bacteriol* 2003;185:5465-5472.
89. Asheshov EH, Dyke KG. Regulation of the synthesis of penicillinase in diploids of *Staphylococcus aureus*. *Biochem Biophys Res Commun* 1968;30:213-218.
90. Sabath LD. Mechanisms of resistance of beta-lactam antibiotics in strains of *Staphylococcus aureus*. *Ann Intern Med* 1982;97:339-344.
91. Ito T, Katayama Y, Asada K, et al. Structural comparison of three types of staphylococcal cassette chromosome *mec* in the chromosome of methicillin-resistant *Staphylococcus aureus*. *Antimicrob Agents Chemother* 2001;45:1323-1326.
92. Hiramatsu K. Molecular evolution of MRSA. *Microbiol Immunol* 1995;39:531-543.

93. Hiramatsu K, Cui L, Kuroda M, et al. The emergence and evolution of methicillin-resistant *Staphylococcus aureus*. *Trends Microbiol* 2001;9:486-493.
94. Archer GL, Niemeyer DM. Origin and evolution of DNA associated with resistance to methicillin in staphylococci. *Trends Microbiol* 1994;2:343-347.
95. Enright MC, Robinson DA, Randle G, et al. The evolutionary history of methicillin-resistant *Staphylococcus aureus* (MRSA). *Proc Natl Acad Sci USA* 2002;99:7687-7692.
96. Muto CA, Jernigan JA, Ostrowsky BE, et al. SHEA guideline for preventing nosocomial transmission of multidrug-resistant strains of *Staphylococcus aureus* and *Enterococcus*. *Infect Control Hosp Epidemiol* 2003;24:362-386.
97. Ito T, Okuma K, Ma XX, et al. Insights on antibiotic resistance of *Staphylococcus aureus* from its whole genome: genomic island SCC. *Drug Resist Updates* 2003;6:41-52.
98. Ito T, Ma XX, Takeuchi F, et al. Novel type V staphylococcal cassette chromosome *mec* driven by a novel cassette chromosome recombinase, *ccrC*. *Antimicrob Agents Chemother* 2004;48:2637-2651.
99. Enright MC, Day NP, Davies CE, et al. Multilocus sequence typing for characterization of methicillin-resistant and methicillin-susceptible clones of *Staphylococcus aureus*. *J Clin Microbiol* 2000;38:1008-1015.
100. Ma XX, Ito T, Tiensasitorn C, et al. Novel type of staphylococcal cassette chromosome *mec* identified in community-acquired methicillin-resistant *Staphylococcus aureus* strains. *Antimicrob Agents Chemother* 2002;46:1147-1152.
101. Fey PD, Said-Salim B, Rupp ME, et al. Comparative molecular analysis of community or hospital-acquired methicillin-resistant *Staphylococcus aureus*. *Antimicrob Agents Chemother* 2003;47:196-203.
102. Oliveira DC, Tomasz A, de Lencastre H. Secrets of success of a human pathogen: molecular evolution of pandemic clones of methicillin-resistant *Staphylococcus aureus*. *Lancet Infect Dis* 2002;2:180-189.
103. Charlebois ED, Perdreau-Remington F, Kreiswirth B, et al. Origins of community strains of methicillin-resistant *Staphylococcus aureus*. *Clin Infect Dis* 2004;39:47-54.
104. Kreiswirth B, Kornblum J, Arbeit RD, et al. Evidence for a clonal origin of methicillin resistance in *Staphylococcus aureus*. *Science* 1993;259:227-230.
105. Oliveira DC, Tomasz A, de Lencastre H. The evolution of pandemic clones of methicillin-resistant *Staphylococcus aureus*: identification of two ancestral genetic backgrounds and the associated *mec* elements. *Microb Drug Resist* 2001;7:349-361.
106. Musser J, Kapur V. Clonal analysis of methicillin-resistant *Staphylococcus aureus* from intercontinental sources: association of the *mec* gene with divergent phylogenetic lineages implies dissemination by horizontal transfer and recombination. *J Clin Microbiol* 1992;30:2058-2063.
107. Givney R, Vickery A, Holliday A, et al. Evolution of an endemic methicillin-resistant *Staphylococcus aureus* population in an Australian hospital from 1967 – 1996. *J Clin Microbiol* 1998;36:552-556.
108. Crisostomo MI, Westh H, Tomasz A, et al. The evolution of methicillin resistance in *Staphylococcus*: similarity of genetic backgrounds in historically early methicillin-susceptible and resistant and contemporary epidemic clones. *Proc Natl Acad Sci USA* 2001;98:9865-9870.
109. Farr BM. Prevention and control of methicillin-resistant *Staphylococcus aureus* infections. *Curr Opin Infect Dis* 2004;17:317-322.
110. Holmes O. The contagiousness of puerperal fever. *N Engl Q J Med Surg* 1842 – 1843;1:501-530.
111. Semmelweis I. *The Etiology, the Concept and the Prophylaxis of Childbed Fever*. Pest, Hungary: CA Hartleben's Verlag-Expedition, 1861.
112. Cooper BS, Stone SP, Kibbler CC, et al. Isolation measures in the hospital management of methicillin resistant *Staphylococcus aureus* (MRSA): systematic review of the literature. *BMJ* 2004;329:533-538.
113. Boyce JM, Potter-Bynoe G, Chenevert C, et al. Environmental contamination due to methicillin-resistant *Staphylococcus aureus*: possible infection control implications. *Infect Control Hosp Epidemiol* 1997;18:622-627.
114. Bhalla A, Pultz, NJ, Gries DM, et al. Acquisition of nosocomial pathogens on hands after contact with environmental surfaces near hospitalized patients. *Infect Control Hosp Epidemiol* 2004;25:164-167.
115. Devine J, Cooke RP, Wright EP. Is methicillin-resistant *Staphylococcus aureus* (MRSA) contamination of ward-based computer terminals a surrogate marker for nosocomial MRSA transmission and handwashing compliance? *J Hosp Infect* 2001;48:72-75.
116. Layton MC, Perez M, Heald P, et al. An outbreak of mupirocin-resistant *Staphylococcus aureus* on a dermatology ward associated with an environmental reservoir. *Infect Control Hosp Epidemiol* 1993;14:369-375.
117. Neely AN, Maley MP. Survival of enterococci and staphylococci on hospital fabrics and plastics. *J Clin Microbiol* 2000;38:724-726.
118. Dietz B, Raht A, Wendt C, et al. Survival of MRSA on sterile goods packaging. *J Hosp Infect* 2001;49:255-261.
119. Borg MA. Bed occupancy and overcrowding as determinant factors in the incidence of MRSA infections within general ward settings. *J Hosp Infect* 2003;54:316-318.
120. Haley RW, Cushion NB, Tenover FC, et al. Eradication of endemic methicillin-resistant *Staphylococcus aureus* infections from a neonatal intensive care unit. *J Infect Dis* 1995;171:614-624.
121. Herr CE, Heckrodt TH, Hofmann FA, et al. Additional costs for preventing the spread of methicillin-resistant *Staphylococcus aureus* and a strategy for reducing these costs on a surgical ward. *Infect Control Hosp Epidemiol* 2003;24:673-678.

122. Thompson RL, Cabezudo I, Wenzel RP. Epidemiology of nosocomial infections caused by methicillin-resistant *Staphylococcus aureus*. *Ann Intern Med* 1982;97:309-317.
123. Back NA, Linnemann CC Jr, Staneck JL, et al. Control of methicillin-resistant *Staphylococcus aureus* in a neonatal intensive-care unit: use of intensive microbiologic surveillance and mupirocin. *Infect Control Hosp Epidemiol* 1996;17:227-231.
124. Salmenlinna S, Lyytikäinen O, Kotilainen P, et al. Molecular epidemiology of methicillin-resistant *Staphylococcus aureus* in Finland. *Eur J Clin Microbiol Infect Dis* 2000;19:101-107.
125. Verhoef J, Beaujean D, Blok H, et al. A Dutch approach to methicillin-resistant *Staphylococcus aureus*. *Eur J Clin Microbiol Infect Dis* 1999;18:461-466.
126. Kotilainen P, Routamaa M, Peltonen R, et al. Elimination of epidemic methicillin-resistant *Staphylococcus aureus* from a university hospital and district institutions, Finland. *Emerg Infect Dis* 2003;9:169-175.
127. Lucet JC, Chevret S, Durand-Zaleske I, et al. Prevalence and risk factors for carriage of methicillin-resistant *Staphylococcus aureus* at admission to the intensive care unit: results of a multicenter study. *Arch Intern Med* 2003;163:181-188.
128. Stelfox HT, Bates DW, Redelmeier DA. Safety of patients isolated for infection control. *JAMA* 2003;290:1899-1905.
129. Chambers HF. The changing epidemiology of *Staphylococcus aureus*? *Emerg Infect Dis* 2001;7:178-182.
130. Chambers HF. Community-associated MRSA—resistance and virulence converge. *N Engl J Med* 2005;352:1485-1487.
131. Frank AL, Marcinak JF, Mangat PD, et al. Increase in community-acquired methicillin-resistant *Staphylococcus aureus* in children. *Clin Infect Dis* 1999;29:935-936.
132. Miller LG, Perdreau-Remington F, Rieg G, et al. Necrotizing fasciitis caused by community-associated methicillin-resistant *Staphylococcus aureus* in Los Angeles. *N Engl J Med* 2005;352:1445-1453.
133. Young DM, Harris HW, Charlebois ED, et al. An epidemic of methicillin-resistant *Staphylococcus aureus* soft tissues infections among medically underserved patients. *Arch Surg* 2004;139:947-953.
134. Frazee BW, Lynn J, Charlebois ED, et al. High prevalence of methicillin-resistant *Staphylococcus aureus* in emergency department skin and soft tissue infections. *Ann Emerg Med* 2005;45:311-320.
135. Daum RS, Ito T, Hiramatsu K, et al. A novel methicillin-resistant cassette in community-acquired methicillin-resistant *Staphylococcus aureus* isolates of diverse genetic backgrounds. *J Infect Dis* 2002;186:1344-1347.
136. Wielders CL, Vriens MR, Brisse S, et al. In-vivo transfer of *mecA* DNA to *Staphylococcus aureus*. *Lancet* 2001;357:1674-1675.
137. Baba T, Takeuchi F, Kuroda M, et al. Genome and virulence determinants of high virulence community-acquired MRSA. *Lancet* 2002;359:1819-1827.
138. Naimi TS, LeDell KH, Como-Sabetti K, et al. Comparison of community-acquired and health care-associated methicillin-resistant *Staphylococcus aureus* infection. *JAMA* 2003;290:2976-2984.
139. McDougal LK, Steward CD, Killgore GE, et al. Pulsed-field gel electrophoresis typing of oxacillin-resistant *Staphylococcus aureus* isolates from the United States: establishing a national database. *J Clin Microbiol* 2003;41:5113-5120.
140. Kazakova SV, Hageman JC, Matava M, et al. A clone of methicillin-resistant *Staphylococcus aureus* among professional football players. *N Engl J Med* 2005;352:468-475.
141. Robinson DA, Enright MC. Multilocus sequence typing and the evolution of methicillin-resistant *Staphylococcus aureus*. *Clin Microb Infect* 2004;10:92-97.
142. Dufour P, Gillet Y, Bes M, et al. Community-acquired methicillin-resistant *Staphylococcus aureus* infections in France: emergence of a single clone that produces Pantone-Valentine leukocidin. *Clin Infect Dis* 2002;35:819-824.
143. Ala'Aldeen D. A non-multiresistant community methicillin-resistant *Staphylococcus aureus* exposes its genome. *Lancet* 2002;359:1791-1792.
144. Vandenesch F, Naimi T, Enright MC, et al. Community-acquired methicillin-resistant *Staphylococcus aureus* carrying Pantone-Valentine leukocidin genes: worldwide emergence. *Emerg Infect Dis* 2003;9:978-984.
145. Lina G, Piemont Y, Godail-Gamot F, et al. Involvement of Pantone-Valentine leukocidin-producing *Staphylococcus aureus* in primary skin infections and pneumonia. *Clin Infect Dis* 1999;29:1128-1132.
146. Fridkin SK, Hageman JC, Morrison M, et al. Methicillin-resistant *Staphylococcus aureus* disease in three communities. *N Engl J Med* 2005;352:1436-1444.
147. Dominguez TJ. It's not a spider bite, it's community-acquired methicillin-resistant *Staphylococcus aureus*. *J Am Board Fam Pract* 2004;17:220-226.
148. Baggett HC, Hennessy TW, Leman R, et al. An outbreak of community-onset methicillin-resistant *Staphylococcus aureus* skin infections in southwestern Alaska. *Infect Control Hosp Epidemiol* 2003;24:397-402.
149. Charlebois ED, Bangsberg DR, Moss NJ, et al. Population-based community prevalence of methicillin-resistant *Staphylococcus aureus* in the urban poor of San Francisco. *Clin Infect Dis* 2002;34:425-433.
150. Groom AV, Wolsey DH, Naimi TS, et al. Community-acquired methicillin-resistant *Staphylococcus aureus* in a rural American Indian community. *JAMA* 2001;286:1201-1205.
151. Charlebois ED, Bangsberg DR, Moss NJ, et al. Population-based community prevalence of methicillin-resistant *Staphylococcus aureus* in the urban poor of San Francisco. *Clin Infect Dis* 2002;34:425-433.
152. Fleisch F, Zbinden R, Vanoli C, et al. Epidemic spread of a single clone of methicillin-resistant *Staphylococcus aureus* among injection drug users in Zurich, Switzerland. *Clin Infect Dis* 2001;32:581-586.

153. Pan ES, Diep BA, Carleton HA, et al. Increasing prevalence of methicillin-resistant *Staphylococcus aureus* infection in California jails. *Clin Infect Dis* 2003;37:1384-1388.
154. Horan TC, Gaynes RP. Surveillance of nosocomial infections. In: Mayhall CG, ed. *Hospital Epidemiology and Infection Control*, 3rd ed. Philadelphia: Lippincott Williams & Wilkins; 2004:1659-1702.
155. Salgado CD, Farr BM, Calfee DP. Community-acquired methicillin-resistant *Staphylococcus aureus*: a meta-analysis of prevalence and risk factors. *Clin Infect Dis* 2003;36:131-139.
156. Friedman ND, Kaye KS, Stout JE, et al. Health care-associated bloodstream infections in adults: a reason to change the accepted definition of community-acquired infections. *Ann Intern Med* 2002;137:791-797.
157. Lesens O, Hansmann Y, Brannigan E, et al. Healthcare-associated *Staphylococcus aureus* bacteremia and the risk for methicillin resistance: Is the Centers for Disease Control and Prevention definition for community-acquired bacteremia still appropriate? *Infect Control Hosp Epidemiol* 2005;26:204-209.
158. Lee MC, Rios AM, Aten MF, et al. Management and outcome of children with skin and soft tissue abscesses caused by community-acquired methicillin-resistant *Staphylococcus aureus*. *Pediatr Infect Dis J* 2004;23:123-127.
159. Mandelbaum S, Forster RK, Gelender H, et al. Late onset endophthalmitis associated with filtering blebs. *Ophthalmology* 1985;92:964-972.
160. Greenfield DS, Suner IJ, Miller MP, et al. Endophthalmitis after filtering surgery with mitomycin C. *Arch Ophthalmol* 1996;114:943-949.
161. Kangas TA, Greenfield DS, Flynn HW Jr, et al. Delayed-onset endophthalmitis associated with conjunctival filtering blebs. *Ophthalmology* 1997;104:746-752.
162. Waheed S, Ritterband DC, Greenfield DS, et al. Bleb-related ocular infection in children after trabeculectomy with mitomycin C. *Ophthalmology* 1997;104:2117-2120.
163. Akova YA, Bulut S, Dabil H, et al. Late bleb-related endophthalmitis after trabeculectomy with mitomycin C. *Ophthalmic Surg Lasers* 1999;30:146-151.
164. Lam RF, Hui M, Leung DY, et al. Extent and predictors of microbial hand contamination in a tertiary care ophthalmic outpatient practice. *Invest Ophthalmol Vis Sci* 2005;46:3578-3583.
165. Larson E, Leyden JJ, McGinley KJ, et al. Physiologic and microbiologic changes in skin related to frequent handwashing. *Infect Control* 1986;7:59-63.
166. Doebbeling BN, Stanley GL, Sheetz CT, et al. Comparative efficacy of alternative hand-washing agents in reducing nosocomial infections in intensive care units. *N Engl J Med* 1992;327:88-93.
167. Fraise AP. Guidelines for the control of methicillin-resistant *Staphylococcus aureus*. *J Antimicrob Chemother* 1998;42:287-289.
168. Fleischer AB, Hoover DL, Khan JA, et al. Topical vancomycin formulation for methicillin-resistant *Staphylococcus epidermidis* blepharoconjunctivitis. *Am J Ophthalmol* 1986;101:283-287.
169. Khan JA, Hoover D, Ide CH. Methicillin-resistant *Staphylococcus epidermidis* blepharitis. *Am J Ophthalmol* 1984;98:562-565.
170. Goodman DF, Gottsch JD. Methicillin-resistant *Staphylococcus epidermidis* keratitis treated with vancomycin. *Arch Ophthalmol* 1988;106:1570-1571.
171. Centers for Disease Control and Prevention. Recommendations for preventing the spread of vancomycin resistance. Recommendations of the Hospital Infection Control Practices Advisory Committee (HICPAC). *MMWR Recomm Rep* 1995;44(RR-12):1-13.
172. Mariana MD, Colby KA. Evaluation and initial management of patients with ocular and adnexal trauma. In: Albert DM, Jakobiec FA, Azar DT, et al, eds. *Principles and Practice of Ophthalmology*, 2nd ed. Philadelphia: WB Saunders; 2000:5180-5200.
173. Gills JP. Filter and antibiotics in irrigating solution for cataract surgery. *J Cataract Refract Surg* 1991;17:385.
174. West ES, Behrens A, McDonnell PJ, et al. The incidence of endophthalmitis after cataract surgery among the US Medicare population increased between 1994 and 2001. *Ophthalmology* 2005;112:1388-1394.
175. Gordon YJ. Vancomycin prophylaxis and emerging resistance: Are ophthalmologists the villains? The heroes? *Am J Ophthalmol* 2001;131:371-376.
176. Ciulla TA, Starr MB, Masket S. Bacterial endophthalmitis prophylaxis for cataract surgery. An evidence-based update. *Ophthalmology* 2002;109:13-26.
177. AAO-CDC Task Force on Vancomycin Prophylaxis in Ophthalmic Surgery. The prophylactic use of vancomycin for intraocular surgery. *Quality of Care Publications, Number 515*. San Francisco: American Academy of Ophthalmology; 1999.
178. Ferro J, De-Pablos M, Logrono M. Postoperative contamination after vancomycin and gentamicin during phacoemulsification. *Arch Ophthalmol* 1997;115:165-170.
179. Feys J, Salvaret-Bouccara A, Edmond JP, et al. Vancomycin prophylaxis and intraocular contamination during cataract surgery. *J Cataract Refract Surg* 1997;23:894-897.
180. Kodjikian L, Renaud FN, Roques C, et al. In vitro influence of vancomycin on adhesion of a *Staphylococcus epidermidis* strain encoding intercellular adhesion locus *ica* to intraocular lenses. *J Cataract Refract Surg* 2005;31:1050-1058.
181. McCulley JP. Low acute endophthalmitis rate: possible explanations. *J Cataract Refract Surg* 2005;31:1074-1075.
182. Fry LL. Vancomycin dilution error. *J Cataract Refract Surg* 2005;31:1674.

183. Axel-Siegel R, Stiebel-Kalish H, Rosenblatt I, et al. Cystoid macular edema after cataract surgery with intraocular vancomycin. *Ophthalmology* 1999;106:1660-1664.
184. Libre PE, Della-Latta P, Chin N. Intracameral antibiotic agents for endophthalmitis prophylaxis. A pharmacokinetic model. *J Cataract Refract Surg* 2003;29:1791-1794.
185. Hwang DG. Fluoroquinolone resistance in ophthalmology and the potential role for newer ophthalmic fluoroquinolones. *Surv Ophthalmol* 2004;49(suppl 2):S79-S83.
186. Gaynor BD, Chidambaram JD, Cevallos V, et al. Topical ocular antibiotics induce bacterial resistance at extraocular sites. *Br J Ophthalmol* 2005;89:1097-1099.
187. Boyce JM, Pittet D. Guidelines for hand hygiene in health-care settings: recommendations of the Healthcare Infection Control Practices Advisory Committee and the HICPAC/SHEA/APIC/IDSA Hand Hygiene Task Force. *Infect Control Hosp Epidemiol* 2002;23(12 suppl):S3-S40.
188. Olsen RJ, Lynch P, Coyle MB, et al. Examination gloves as barriers to hand contamination in clinical practice. *JAMA* 1993;270:350-353.
189. Doebbeling BN, Pfaller MA, Houston AK, et al. Removal of nosocomial pathogens from the contaminated glove: implications for glove reuse and handwashing. *Ann Intern Med* 1988;109:394-398.
190. Werheim HF, Vos MC, Ott A, et al. Mupirocin prophylaxis against nosocomial *Staphylococcus aureus* infections in nonsurgical patients: a randomized study. *Ann Intern Med* 2004;140:419-425.
191. Miller MA, Dascal A, Portnory J, et al. Development of mupirocin resistance among methicillin-resistant *Staphylococcus aureus* after widespread use of nasal mupirocin ointment. *Infect Control Hosp Epidemiol* 1996;17:811-813.
192. Torvaldsen S, Roberts C, Riley TV. The continuing evolution of methicillin-resistant *Staphylococcus aureus* in western Australia. *Infect Control Hosp Epidemiol* 1999;20:133-135.
193. Vasquez JE, Walker ES, Franzus BW, et al. The epidemiology of mupirocin resistance among methicillin-resistant *Staphylococcus aureus* at a Veterans' Affairs hospital. *Infect Control Hosp Epidemiol* 2000;21:459-464.
194. Fraunfelder FT, Bagby GC, Kelly DJ. Fatal aplastic anemia following topical administration of ophthalmic chloramphenicol. *Am J Ophthalmol* 1982;93:356-360.
195. Doona M, Walsh JB. Use of chloramphenicol as topical eye medication: Time to cry halt? *BMJ* 1995;310:1217-1218.
196. Marciniak JF, Frank AL. Treatment of community-acquired methicillin-resistant *Staphylococcus aureus* in children. *Curr Opin Infect Dis* 2003;16:265-269.
197. Panagea S, Perry JD, Gould FK. Should clindamycin be used as treatment of patients with infections caused by erythromycin-resistant staphylococci? *J Antimicrob Chemother* 1999;44:581-582.
198. Rao GG. Should clindamycin be used in treatment of patients with infections caused by erythromycin-resistant staphylococci? *J Antimicrob Chemother* 2000;45:715.
199. Drinkovic D, Fuller ER, Shore KP, et al. Clindamycin treatment of *Staphylococcus aureus* expressing inducible clindamycin resistance. *J Antimicrob Chemother* 2001;48:315-316.
200. Siberry GK, Tekle T, Carroll K, et al. Failure of clindamycin treatment of methicillin-resistant *Staphylococcus aureus* expressing inducible clindamycin resistance in vitro. *Clin Infect Dis* 2003;37:1257-1260.
201. Forrest A, Nix DE, Ballow CH, et al. Pharmacodynamics of intravenous ciprofloxacin in seriously ill patients. *Antimicrob Agents Chemother* 1993;37:1073-1081.
202. Kowalski RP, Karenchak LM, Romanowski EG. Infectious disease: changing antibiotic susceptibility. *Ophthalmol Clin North Am* 2003;16:1-9.
203. Ling ML, Tan PL. In vitro activity of moxifloxacin against local bacterial isolates. *Ann Acad Med Singapore* 2001;30:607-610.
204. Abb J. In vitro activity of linezolid, quinupristin-dalfopristin, vancomycin, teicoplanin, moxifloxacin, and mupirocin against methicillin-resistant *Staphylococcus aureus*: comparative evaluation by the E test and a broth microdilution method. *Diag Microbiol Infect Dis* 2002;43:319-321.
205. Tsuji H, Tsuru T, Okuzumi K. Detection of methicillin-resistant *Staphylococcus aureus* in donor eye preservation media by polymerase chain reaction. *Jpn J Ophthalmol* 1998;42:352-356.
206. Michel M, Gutmann L. Methicillin-resistant *Staphylococcus aureus* and vancomycin-resistant enterococci: therapeutic realities and possibilities. *Lancet* 1997;349:1901-1906.
207. Pillai SK, Sakoulas G, Wennersten C, et al. Linezolid resistance in *Staphylococcus aureus*: characterization and stability of resistant phenotype. *J Infect Dis* 2002;186:1603-1607.
208. Hiramatsu K, Aritaka N, Hanaki H, et al. Dissemination in Japanese hospitals of strains of *Staphylococcus aureus* heterogeneously resistant to vancomycin. *Lancet* 1997;350:1670-1673.
209. Linden PK. Clinical implications of nosocomial gram-positive bacteremia and superimposed antimicrobial resistance. *Am J Med* 1998;104(5A):24S-33S.
210. Schindler CA, Schuhart VT. Lysostaphin: a new bacteriolytic agent for the *Staphylococcus*. *Proc Natl Acad Sci USA* 1965;51:414-421.
211. Sloan GL, Robinson JM, Kloos WE. Identification of '*Staphylococcus staphylolyticus*' NRRL B-2628 as biovar of *Staphylococcus simulans*. *Int J Bacteriol* 1982;32:170-174.

212. Dajcs JJ, Hume EB, Moreau JM, et al. Lysostaphin treatment of methicillin-resistant *Staphylococcus aureus* keratitis in the rabbit. *Invest Ophthalmol Vis Sci* 2000;41:1432-1437.
213. Dajcs JJ, Thibodeaux BA, Hume EB, et al. Lysostaphin is effective in treating methicillin-resistant *Staphylococcus aureus* endophthalmitis in the rabbit. *Curr Eye Res* 2001;22:451-457.
214. Kessler E, Safrin M, Olson JC, et al. Secreted LasA protease of *Pseudomonas aeruginosa* is a staphylolytic protease. *J Biol Chem* 1993;268:7503-7508.
215. Kessler E. β -lytic endopeptidases. *Methods Enzymol* 1995;248:740-756.
216. Kessler E, Ohman DE. Staphylolysin. In: Barrett AJ, Rawlings ND, Woessner JF, eds. *Handbook of Proteolytic Enzymes*. London: Academic Press; 1998:1476-1478.
217. Barequet IS, Ben Simon GY, Safrin M, et al. *Pseudomonas aeruginosa* LasA protease in treatment of experimental staphylococcal keratitis. *Antimicrob Agents Chemother* 2004;48:1681-1687.
218. Callegan MC, Hill JM, Insler MS, et al. Methicillin-resistant *Staphylococcus aureus* keratitis in the rabbit: therapy with ciprofloxacin, vancomycin, and cefazolin. *Curr Eye Res* 1992;11:1111-1119.
219. Fattom AI, Sarwar J, Ortiz A, et al. A *Staphylococcus aureus* capsular polysaccharide (CP) vaccine and CP-specific antibodies protect mice against bacterial challenge. *Infect Immun* 1996;64:1659-1665.
220. Lee JC, Park JS, Shepherd SE, et al. Protective efficacy of antibodies to the *Staphylococcus aureus* type 5 capsular polysaccharide in a modified model of endocarditis in rats. *Infect Immun* 1997;65:4146-4151.
221. Shinefield H, Black S, Fattom A, et al. Use of a *Staphylococcus aureus* conjugate vaccine in patients receiving hemodialysis. *N Engl J Med* 2002;346:491-496.