

# Diclofenac poisoning is widespread in declining vulture populations across the Indian subcontinent

Susanne Shultz<sup>1,2</sup>, Hem Sagar Baral<sup>3</sup>, Sheonaith Charman<sup>4</sup>, Andrew A. Cunningham<sup>2</sup>, Devojit Das<sup>5</sup>, G. R. Ghalsasi<sup>6</sup>, Mallikarjun S. Goudar<sup>6</sup>, Rhys E. Green<sup>1,7\*</sup>, Ainsley Jones<sup>4</sup>, Prashant Nighot<sup>6</sup>, Deborah J. Pain<sup>1</sup> and Vibhu Prakash<sup>5</sup>

<sup>1</sup>Royal Society for the Protection of Birds, The Lodge, Sandy SG19 2DL, UK

<sup>2</sup>Institute of Zoology, Zoological Society of London, Regent's Park, London NW1 4RY, UK

<sup>3</sup>Bird Conservation Nepal, PO Box 12465, Kathmandu, Nepal

<sup>4</sup>Central Science Laboratory, Sand Hutton, York YO41 1LZ, UK

<sup>5</sup>Bombay Natural History Society, Hornbill House, S. B. Singh Road, Mumbai 400 023, India

<sup>6</sup>India Poultry Diagnostic and Research Centre, Division of Venkateshwara Hatcheries Private Limited, Pune-Solapur Road, Loni Kalbhori, Pune 412 201, Maharashtra, India

<sup>7</sup>Conservation Biology Group, Department of Zoology,

University of Cambridge, Cambridge CB2 3EJ, UK

\* Author for correspondence (reg29@hermes.com.ac.uk).

Recd 30.04.04; Acceptd 07.06.04; Published online 21.07.04

**Recent declines in the populations of three species of vultures in the Indian subcontinent are among the most rapid ever recorded in any bird species. Evidence from a previous study of one of these species, *Gyps bengalensis*, in the Punjab province of Pakistan, strongly implicates mortality caused by ingestion of residues of the veterinary non-steroidal anti-inflammatory drug diclofenac as the major cause of the decline. We show that a high proportion of *Gyps bengalensis* and *G. indicus* found dead or dying in a much larger area of India and Nepal also have residues of diclofenac and visceral gout, a post-mortem finding that is strongly associated with diclofenac contamination in both species. Hence, veterinary use of diclofenac is likely to have been the major cause of the rapid vulture population declines across the subcontinent.**

**Keywords:** vulture decline; *Gyps*; diclofenac; anti-inflammatory veterinary drug

## 1. INTRODUCTION

Populations of three species of vultures in the Indian subcontinent have declined by more than 95% in *ca.* 10 years across the Indian subcontinent (Gilbert *et al.* 2002; Prakash *et al.* 2003; The Peregrine Fund 2004), leading the International Union for the Conservation of Nature to list oriental white-backed vulture (OWBV; *Gyps bengalensis*), long-billed vulture (LBV; *Gyps indicus*) and slender-billed vulture (*Gyps tenuirostris*) as critically endangered (Hilton-Taylor 2000). Given that these declines affect parts of the

world range of these species that contain most individuals, they are among the most rapid sustained declines in the total population size of a bird species ever documented (Green & Hirons 1991).

Studies that were performed in the Punjab province of Pakistan, during a period when the breeding population of OWBV was declining rapidly, found high mortality and a high proportion of dead vultures with visceral gout, and extensive deposits of uric acid on and within internal organs (Gilbert *et al.* 2002). The kidneys of all dead OWBV with visceral gout were found to contain residues of diclofenac, an anti-inflammatory veterinary drug apparently ingested by vultures when they feed on carcasses of treated livestock (Oaks *et al.* 2004). The kidneys of dead vultures without visceral gout did not contain detectable residues of diclofenac. Captive OWBV fed on tissues of livestock that had been treated with the normal veterinary dose of diclofenac shortly before death showed dose-dependent mortality and those that died had extensive visceral gout (Oaks *et al.* 2004).

Although visceral gout has been reported previously from vultures in India (Mishra *et al.* 2002; Cunningham *et al.* 2003), it is not yet clear whether it and diclofenac poisoning occur widely across the subcontinent. We report that dead OWBV and LBV found in India and Nepal between 2000 and 2004 had a high incidence of gout, consistent with that found for OWBV in Pakistan, and that gout was strongly associated with the presence of diclofenac residues in kidney or liver in both species.

## 2. MATERIAL AND METHODS

Our analysis includes information from 15 OWBV and 13 LBV collected dead, or dying, between August 2000 and February 2004 in India and Nepal at the locations shown in figure 1. The birds were collected opportunistically in states where permits had been issued. Although we cannot be sure that they are a representative sample, we see no reason to believe that there was any appreciable collection bias with regard to cause of death. Eight birds were alive when collected, but *in extremis*. Four of these died within one day of collection and the rest within 3 days. Birds were aged by using plumage characters as juvenile (less than 1 year), subadult (more than 1 year, but not adult) and adult. We performed post-mortem examinations using the methods described in Cunningham *et al.* (2003). Among 13 OWBV and 12 LBV for which the presence or absence of visceral gout could be determined, tissues of 11 OWBV and seven LBV were also analysed for diclofenac residues. In addition, tissues of two OWBV and one LBV, which did not have adequate necropsy information, were analysed for diclofenac.

Diclofenac was extracted from 0.5 g samples of kidney or liver tissue with acetonitrile, by the method described by Oaks *et al.* (2004) and extracts were analysed by HPLC-MS-MS using a PE Sciex API 2000 instrument. Quantification was by means of external calibration standards over a concentration range extending up to 0.1 µg ml<sup>-1</sup>. Data were acquired using three MS/MS channels. Channel 1 used a parent ion of *m/z* = 294 and a product ion of *m/z* = 250; this channel was used for quantification. Channel 2 had a parent ion of *m/z* = 296 and product ion *m/z* = 252, and channel 3 had a parent ion of *m/z* = 294, product ion *m/z* = 214. The relative responses for the different channels were used to confirm identity. Limits of detection ranged from 0.001 to 0.002 µg g<sup>-1</sup>. Kidney and liver were analysed for nine birds; diclofenac was detected from both tissues in five birds, from neither tissue in three birds, and only from liver in one bird. Only one tissue was analysed for the other 12 birds.

## 3. RESULTS

Seventy-two per cent of the birds examined at post-mortem had extensive visceral gout (table 1). Proportions of OWBV and LBV with gout were similar. Diclofenac was detected at concentrations in the range 0.004–0.16 µg g<sup>-1</sup>. Seventy-seven per cent (10/13) of the OWBV and 63%

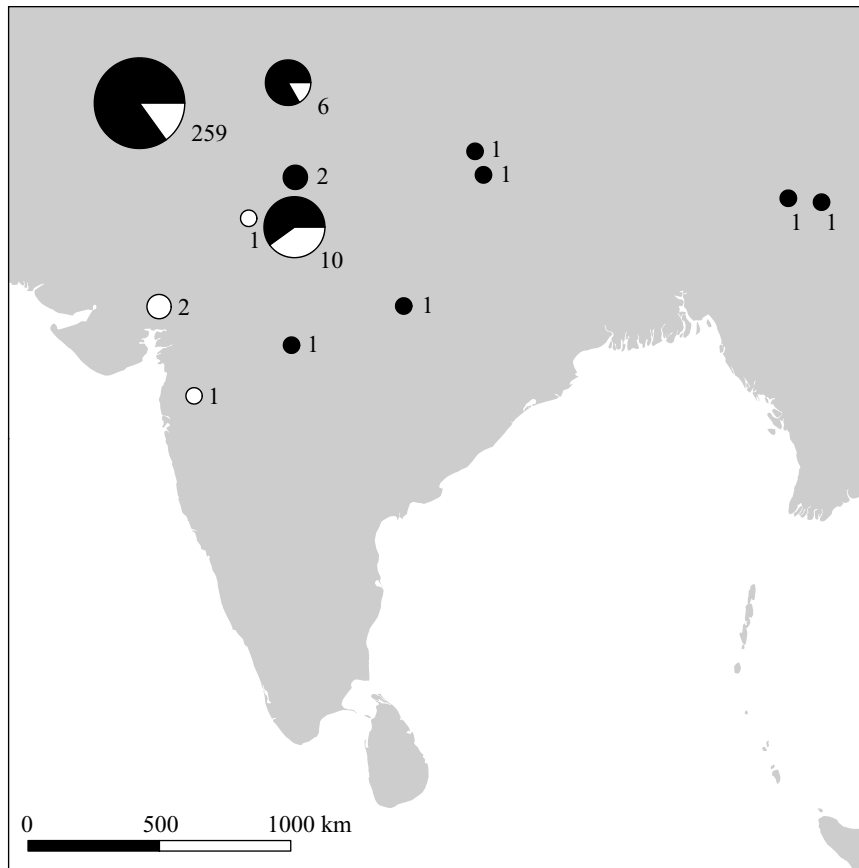


Figure 1. Proportion of vultures with diclofenac residues, visceral gout or both (indicated by the black area of each pie chart) at 13 localities where dead or dying vultures were found. The area of circles is scaled according to the number of birds assessed per site, which is given next to each. The circle furthest to the left represents data from a previous study in Pakistan (Oaks *et al.* 2004).

Table 1. Numbers of dead oriental white-backed (OWBV) and long-billed (LBV) vultures collected in India and Nepal with and without visceral gout. (The table shows numbers of individuals. Subscripts represent numbers of juveniles, subadults and adults, respectively.)

| species      | gout                  | no gout              |
|--------------|-----------------------|----------------------|
| OWBV         | 10 <sub>(1,3,6)</sub> | 3 <sub>(0,2,1)</sub> |
| LBV          | 8 <sub>(2,3,3)</sub>  | 4 <sub>(0,1,3)</sub> |
| both species | 18                    | 7                    |

Table 2. Co-occurrence of diclofenac residues and visceral gout in oriental white-backed (OWBV) and long-billed (LBV) vultures in India and Nepal. (The table shows numbers of individuals. Subscripts represent numbers of juveniles, subadults and adults, respectively.)

|         | species      | diclofenac           | no diclofenac        |
|---------|--------------|----------------------|----------------------|
| gout    | OWBV         | 9 <sub>(1,3,5)</sub> | 0                    |
|         | LBV          | 5 <sub>(2,2,1)</sub> | 0                    |
|         | both species | 14                   | 0                    |
| no gout | OWBV         | 0                    | 2 <sub>(0,1,1)</sub> |
|         | LBV          | 0                    | 2 <sub>(0,1,1)</sub> |
|         | both species | 0                    | 4                    |

(5/8) of the LBV had detectable residues. There was a complete and highly significant association between the presence of diclofenac and that of visceral gout (table 2).

All 14 birds with gout had detectable diclofenac, but diclofenac was not found in the four birds without gout (Fisher’s exact test,  $p = 0.0003$ ). This association was significant for both of the two vulture species when they were considered separately (Fisher’s exact test; OWBV,  $p = 0.018$ ; LBV,  $p = 0.048$ ).

#### 4. DISCUSSION

Our study found a high proportion of OWBV and LBV with visceral gout in India and Nepal, which is similar to that reported previously for OWBV from Pakistan by Oaks *et al.* (2004). Among 259 dead and dying adult and subadult OWBV that they examined, 85% had gout. This is consistent with our data for these age classes of OWBV (75% with gout; Fisher’s exact test,  $p = 0.41$ ).

We found a perfect association between visceral gout and diclofenac contamination in OWBV in India and Nepal, which supports the same finding by Oaks *et al.* (2004) for this species in Pakistan. We also extend the evidence of this association to LBV for the first time. No diclofenac analyses have yet been performed on tissues of the slender-billed vulture, the rarest and most geographically restricted of the three declining species.

Our study extends, by more than 2000 km eastwards, the geographical area within which evidence exists that a high proportion of dead vultures have visceral gout and that gout is strongly associated with diclofenac contamination (figure 1). Taken together, our study and that of

Oaks *et al.* (2004) have found diclofenac residues and gout in vulture carcasses collected across most of the geographical extent of the documented declines in vulture populations. The high proportion of dead vultures with signs of diclofenac poisoning make it probable that this is the major cause of the rapid population declines reported to have occurred across the subcontinent. Extinction of these endemic South Asian vulture species over most of their historical range is likely unless exposure to the new hazard from diclofenac can be prevented.

#### Acknowledgements

The authors thank J. P. W. Scharlemann for drawing the figure, M. I. Avery, A. Balmford, D. W. Gibbons, I. Newton, J. L. Oaks, A. R. Rahmani, R. W. Risebrough and R. T. Watson for comments and advice, Sachin Ranade and S. Saravanan for assistance in the field, and R. D. Jakati for his inspirational efforts to conserve vultures in Haryana State. This work was funded by the UK Government's Darwin Initiative for the Survival of Species, with additional financial support from the Royal Society for the Protection of Birds and the Zoological Society of London.

- Cunningham, A. A., Prakash, V., Pain, D., Ghalsasi, G. R., Wells, G. A. H., Kolte, G. N., Nighot, P., Goudar, M. S., Kshirsagar, S. & Rahmani, A. 2003 Indian vultures: victims of an infectious disease epidemic? *Anim. Conserv.* **6**, 189–197.
- Gilbert, M. (and 10 others) 2002 Breeding and mortality of oriental white-backed vulture *Gyps bengalensis* in Punjab province, Pakistan. *Bird Conserv. Int.* **12**, 311–326.
- Green, R. E. & Hiron, G. J. M. 1991 The relevance of population studies to the conservation of threatened birds. In *Bird population studies: their relevance to conservation and management* (ed. C. M. Perrins, J.-D. Lebreton & G. J. M. Hiron), pp. 594–633. Oxford University Press.
- Hilton-Taylor, C. 2000 *IUCN red list of threatened species*. Gland and Cambridge: IUCN.
- Mishra, S. K., Prasad, G., Minakshi, Malik, Y., Mahajan, N. K. & Prakash, V. 2002 Vulture mortality: pathological and microbiological investigations. *Ind. J. Anim. Sci.* **72**, 283–286.
- Oaks, J. L. (and 12 others) 2004 Diclofenac residues as the cause of population decline of vultures in Pakistan. *Nature* **427**, 630–633.
- Prakash, V., Pain, D. J., Cunningham, A. A., Donald, P. F., Prakash, N., Verma, A., Gargi, R., Sivakumar, S. & Rahmani, A. R. 2003 Catastrophic collapse of Indian white-backed *Gyps bengalensis* and long-billed *Gyps indicus* vulture populations. *Biol. Conserv.* **109**, 381–390.
- The Peregrine Fund 2004 Available at <http://www.peregrinefund.org/vulture>.