

Fetal exsanguination associated with antepartum hemorrhage

M.S. AKHTER, MRCOG, FRCS[C], FACOG; J.F. SAVIOR, FRCS, FRCS, FACOG; I.A. AKHTER, MD; J.S. DEACON, MD, FAAP

Fetal bleeding in utero is infrequent. It is usually life-threatening but can be treated successfully in most cases if recognized early. Four cases are described and it is suggested that screening for fetal blood be done in all instances of antepartum hemorrhage.

Le saignement foetal in utero est peu fréquent. Il met habituellement la vie en danger mais il peut être traité avec succès dans la plupart des cas s'il est diagnostiqué à temps. On en décrit quatre cas et il est proposé de procéder à la recherche du sang foetal dans tous les cas d'hémorragie avant l'accouchement.

The recognized causes of fetal bleeding in utero include the following: fetal-maternal transfusion; bleeding from torn fetal vessels in cases of velamentous insertion of the umbilical cord; tearing of a placenta previa or vasa previa; placental transection at cesarean section; twin-to-twin transfusion; rupture of a hematoma of the umbilical cord; and puncture of the placental or cord vessels during amniocentesis.

The unexpected delivery of an asphyxiated, anemic and often exsanguinated baby, which finds the physician unprepared, is usually associated with a fatal outcome. This complication, though rare, contributes significantly to perinatal morbidity and mortality.

In this paper we present a review of the pertinent literature and four case reports.

Historical review

Kobak and Cohen¹ described in 1939 exsanguination of a twin. Vasa previa had torn at the time of spontaneous rupture of the fetal membranes, and they commented that vasa previa should be suspected whenever bleeding occurs at the time of rupture of the membranes in the presence of a well engaged presenting part, especially in a multiple pregnancy.

The same year Dippel² reviewed 36 cases of hematoma of the umbilical cord; the fetus was born alive in only 19 instances. The only clinical evidence of the presence of a hematoma of the

cord was that of fetal distress or vaginal bleeding.

Russell and Warwick³ in 1955 showed how the obstetrician could be warned of the presence of an anterior placenta by roentgenography and thus avoid tearing through the placenta at the time of cesarean section. Nowadays placental localization by ultrasonography can help to warn the physician of this situation. The risk to the baby's life incurred by damage to the fetal vessels has generally been overcome by this awareness. Mitchell, Anderson and Russell⁴ reported nine such cases in 1957. In six cases fetal distress either was not noted or did not precede the vaginal bleeding by a sufficient length of time to influence management. In one of their cases fetal distress was present for an hour before delivery; the baby received a blood transfusion and survived. Neligan and Russell⁵ had reported 3 years previously that exsanguinated babies may appear deceptively well until shortly before death.

Russell, Smith and Yale⁶ described in 1956 two cases of fetal exsanguination associated with surgical induction of labour by the use of the Drew Smythe catheter to tap the hind waters, a common practice at that time. Their report drew attention to the danger of a bloody tap and the unpredictable chance that the baby would bleed to death in utero without showing clinical evidence of fetal distress. In one of their cases blood transfusion after delivery did not avail; acute tubular necrosis due to hemorrhagic shock claimed the life of the baby.

Misenhimer⁷ in 1966 described five cases of fetal hemorrhage after amniocentesis, in all of which bloody taps were obtained; the only baby to survive was delivered immediately by cesarean section. In these cases massive fetal-maternal transfusion was confirmed by the Kleihauer-Betke technique. Ryan, Ivy and Pearson⁸ reported a similar series; each bloody amniotic fluid sample was positive for fetal cells when the Apt test was applied. Kirschen and Benirschke⁹ reported two cases of amniocentesis by the suprapubic approach in which clear amniotic fluid was obtained. Fetal movements ceased 12 hours after the tap in one case and 2 hours after the tap in the other. In the first case no puncture of the cord or placental vessels was noted, while in the second case a small slit-like tear of the cord with traumatic disruption of a small arterial branch was evident.

Case reports

Case 1

Labour was induced at term with oxytocin infusion in a 19-year-old primigravida because of mild toxemia. The head was engaged in the pelvis and the cervix was 75% effaced and 2 cm dilated. The fetal heart rate was 130 beats/min and regular; it was recorded continuously by an external method. Uterine activity was monitored by an external abdominal transducer. Three hours after the oxytocin infusion was started the membranes ruptured, with the escape of clear amniotic fluid. A spiral electrode was then applied to the fetal head to record the fetal heart rate; it averaged 140 beats/min with good beat-to-beat variation. Uterine contractions were strong and regular.

Seven hours after induction was begun the cervix was fully dilated, and soon afterwards the fetal head appeared at the introitus. From this time onwards the fetal heart rate decreased to 80 beats/min with each contraction but recovered to 140 beats/min at its termination. The pattern of deceleration was variable and was present for some minutes before the child was delivered by low forceps extraction. As the head was delivered there was a gush of bright red blood that bathed the body of the baby. At birth no heart beat was present in the infant and extreme pallor was noticed. When the cord was divided no blood issued from the umbilical arteries.

Intubation was performed in the baby and positive pressure breathing was started. Bicarbonate solution and subsequently 20 mL of 5% dextrose solution were injected into the umbilical vein and adrenalin was injected directly into the heart. No spontaneous respiratory effort or heart beat was ever detected, so resuscitation was discontinued after 1 hour.

The placenta and umbilical cord appeared normal. The cord contained three vessels and was attached 4 cm from the placental margin. A vessel close to the insertion of the cord had ruptured and blood was seen beneath the amnion around the insertion of the cord (Fig. 1). The maternal and fetal surfaces of the placenta looked extremely pale. What caused this rupture was not determined.

Case 2

A 31-year-old woman, gravida 2, para 1, was admitted to the case room with a history of painless vaginal bleeding. The estimated blood loss was about 800 mL. Her pulse rate was 96 beats/min, the blood pressure was 120/75 mm Hg and the hemoglobin value was 12.0 g/dL. Fundal height was compatible with term pregnancy. The lie of the fetus was longitudinal and the head was free at the pelvic brim. No uterine tenderness was evident.

From the departments of obstetrics and gynecology and of pediatrics, University of Calgary

Reprint requests to: Dr. M.S. Akhter, Department of obstetrics and gynecology, Foothills Provincial General Hospital, 1403-29th St. NW, Calgary, Alta. T2N 2T9

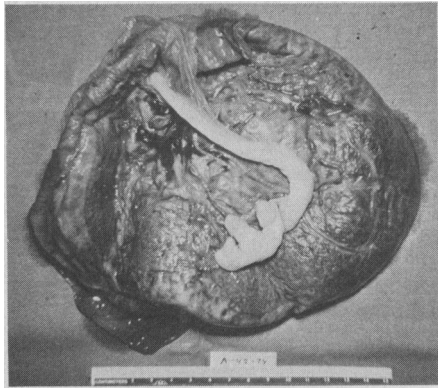


FIG. 1—Hemorrhage beneath membranes due to rupture in blood vessel.

Moderate vaginal bleeding continued after admission. The fetal heart was monitored externally and the rate was recorded as 140 beats/min. One hour after admission the fetal heart rate decreased to 90 beats/min in the absence of a uterine contraction. An emergency lower-segment cesarean section was performed and an anterior placenta previa, type 1 was found.

A rather shocked boy weighing 3.7 kg was delivered about 1½ hours after the mother's admission. The Apgar score was 0 at 1 minute and 2 at 5 minutes and the heart rate was 100 beats/min. The baby was given oxygen by intermittent positive pressure breathing.

The placenta was bilobate and the umbilical cord had a velamentous insertion. A small rupture was noticed in one of the cord vessels. Retrospectively the antepartum hemorrhage was attributed to fetal and placental blood loss, which accounted for the baby's shock.

The infant's hematocrit was 46%. Other blood values were as follows: glucose, 190 mg/dL; pH, 6.93; PCO₂, 14 mm Hg; PO₂, 46 mm Hg; base deficit, 30 mEq/L; and actual bicarbonate, 3 mmol/L. Immediately an infusion of bicarbonate, saline and dextrose solution was given into the

umbilical vein. Fifteen minutes after birth an emergency transfusion of group O, Rh-negative packed erythrocytes was given by catheter into the umbilical vein. In spite of repeated transfusions the baby remained depressed. Convulsions supervened when the baby was about 12 hours of age, requiring large doses of diphenylhydantoin and phenobarbital for their control. However, metabolic acidosis developed on the 2nd day of life and subsequently disseminated intravascular coagulation proved fatal.

At autopsy the cause of death was found to be cerebral ischemia and shock. Had a routine screening protocol been available for detection of fetal blood in all cases of antepartum hemorrhage, earlier cesarean section might have altered the outcome.

Case 3

A 19-year-old primigravida was transferred from another hospital because of failure to progress in labour. Fundal height corresponded to a 34-week gestation and was not compatible with the date of the last menstrual period. An oxytocin infusion had been given and the uterus was contracting mildly every 10 to 15 minutes. The blood pressure was 140/90 mm Hg. Urinalysis showed proteinuria (3+); there was no edema. The fetal heart rate was regular at 140 beats/min. The cervix was dilated 4 cm and the fetal head was deeply engaged.

The rate of oxytocin infusion was increased and the bulging bag of membranes artificially ruptured. Meconium-stained amniotic fluid escaped and internal direct monitoring was begun. The fetal heart rate decreased to 80 beats/min during each contraction but recovered quickly afterwards and maintained a baseline of 140 beats/min. The pattern of dips was variable (Fig. 2) and a diagnosis of cord compression was made.

A girl weighing 2.0 kg was born; the

Apgar score was 7 at 1 minute and 8 at 5 minutes. The placenta was small and normal in appearance except for a membranous insertion of the cord with a blood clot at the site of a ruptured vessel.

The baby was noted to be growth-retarded and post-term by clinical assessment. The heart rate was 180 beats/min 10 minutes after birth. The hematocrit was 36%. Other blood values were as follows: pH, 7.22; PCO₂, 42 mm Hg; PO₂, 46 mm Hg; base excess, 11 mEq/L. Acute fetal blood loss was diagnosed. The baby was depressed but responded after a short period of oxygen therapy and the fetal heart rate decreased to 140 beats/min. A transfusion of 19 mL of group O, Rh-negative packed erythrocytes was given, after which the blood values were as follows: hematocrit, 63%; hemoglobin, 20 g/dL; pH, 7.37; PCO₂, 49 mm Hg; base excess, 5 mEq/L; and actual bicarbonate, 19 mmol/L. The baby's progress in the nursery was satisfactory.

Case 4

A 24-year-old woman, gravida 2, para 1, was admitted in labour to the case room. The gestation was of 38 weeks' duration. The contractions were strong and occurring regularly, the fetal head was well engaged and the cervix was 4 cm dilated. The membranes were ruptured with an amniotomy hook and clear amniotic fluid was noted. A spiral electrode was applied to the fetal head and monitoring begun. The fetal heart rate averaged 140 beats/min.

Because of maternal distress a paracervical block was instituted with 5 mL of lidocaine, 1%. Ten minutes later the fetal heart rate decreased to 90 beats/min, but after the woman was shifted to the left lateral position and given oxygen by mask the rate promptly recovered to 140 beats/min with good beat-to-beat variation. One hour after admission the woman delivered spontaneously a boy weighing 3.09 kg with an Apgar score of 5 at 1 minute. The baby was extremely pale. When the placenta was examined the cord was found to have three vessels, none of which was ruptured. By the Dubowitz score the baby's gestational age was estimated to be 38 weeks. No maternal-fetal blood incompatibility was discovered.

The baby was alert and cried vigorously. No abnormality of the cardiovascular or respiratory system was detected, nor were there signs of congestive heart failure. The hemoglobin value was 4.5 g/dL and the leukocyte count was $33.2 \times 10^9/L$. There were 114 nucleated erythrocytes per 100 leukocytes. The blood group was O, Rh-positive. An unidentified antibody against the baby's blood was discovered in the mother's serum.

A blood film stained by the Kleihauer-Betke technique revealed a large number of fetal erythrocytes in the maternal blood, indicating fetal-maternal transfusion prior to birth. The baby was given a partial exchange transfusion with 90 mL of packed erythrocytes, after which the hemoglobin value was 14.7 g/dL. Jaundice developed and the serum bilirubin reached a maximum value of 14.6 mg/dL 4 days

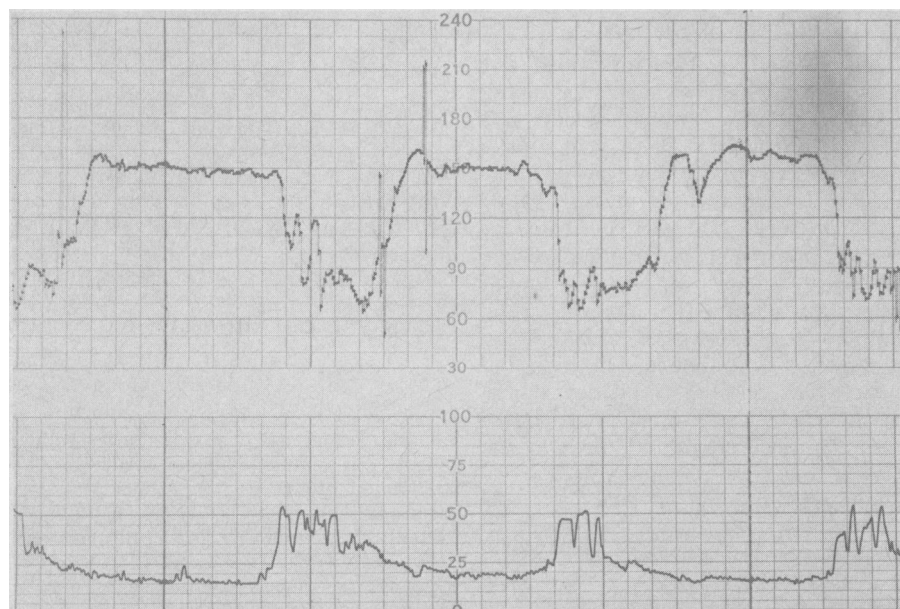

FIG. 2—Variable deceleration pattern of fetal heart rate in case of intrapartum fetal bleeding.

after birth. The concentration later decreased to 12.1 mg/dL and the baby made satisfactory progress.

Discussion

Fetal exsanguination as a cause of perinatal death is rare when delivery takes place vaginally and labour is spontaneous. The fetal vessels may be damaged during cesarean section when the placenta is situated anteriorly. The danger of tearing through an anterior placenta so that the fetus bleeds to death is not always recognized.

In the past, fetal well-being in labour was assessed by clinical criteria alone and this resulted in high fetal mortality. With the advent and increasing use of electronic antepartum and intrapartum monitoring it was hoped that such accidents would be prevented, but this has not been our experience.

The diagnosis of vasa previa may be made before the membranes rupture if, on vaginal examination, pulsating vessels are palpated in the membranes.

Velamentous insertion of the umbilical cord is a relatively rare finding, and unless the location of the vessels is such that they can be either torn or compressed during labour it has no clinical significance. In our hospital there were 28 instances of velamentous insertion in 9079 deliveries between 1972 and 1975, an incidence of 0.3%.

It has been claimed that rupture of a vessel when the cord has a velamentous insertion is more likely to occur when the vessel is in the lower uterine segment. However, in the first case described the placenta was in the upper uterine segment. Kosmak¹⁰ has reported a similar case. In our case there was no change in the recorded pattern of the fetal heart rate until the head appeared at the vulva. One can assume that the vessel ruptured just prior to delivery and that the baby lost most of its blood then. Had there been any early indication of this hemorrhage, immediate blood transfusion along with external cardiac compression and artificial ventilation might have saved the infant's life.

In the second case there was plenty of warning but no attempt was made to test the blood lost before delivery for fetal erythrocytes. Had this been done early, thus permitting the diagnosis of fetal hemorrhage, timely cesarean section might have saved the baby. It is a matter of some concern that monitoring of the fetal heart rate is of little use in estimating the extent or consequences of fetal hemorrhage in utero.

In the third case the timely intervention was due to recognition of fetal distress in the absence of any outward indication of fetal hemorrhage. The

variable deceleration noted in the fetal heart rate was most likely due to the fetal hemorrhage. This has not previously been reported. We strongly recommend that the possibility of fetal hemorrhage in utero be considered when variable decelerations persist.

In the last case it appears that fetal-maternal transfusion had occurred before birth since the maternal serum contained antibodies to the fetal erythrocytes. There was no anatomic or histologic evidence of damage to the cord or placental blood vessels.

Hematoma of the umbilical cord has also been described as a cause of fetal bleeding in utero. Hemorrhage in these cases is usually associated with rupture of the wall of an umbilical artery before delivery.

Because of its contribution to perinatal morbidity and mortality, fetal hemorrhage in utero presents a challenge to today's specialist in fetal-maternal and neonatal medicine. We recommend the more frequent use of a modified Singer's test to screen for fetal erythrocytes in all cases of hemorrhage late in pregnancy. The test is simple and can be performed easily and quickly by a resident or a member of the senior nursing staff in the case room. Five drops of blood are allowed to react over blotting paper with 10 drops of alkali (N/12 NaOH) for 5 minutes. The reaction is then checked by the addition of acid solution — 800 mL of 50% saturated $(\text{NH}_4)_2\text{SO}_4$ plus 2 mL of 10N HCl. In the case of adult hemoglobin a faint brown-amber colour is noted on the paper; with fetal hemoglobin the colour varies from faint pink to distinct cherry red. In doubtful cases the Kleihauer-Betke staining technique for fetal erythrocytes can be used; a smear is made of the suspected blood for staining by the clinical laboratory. The timely discovery of fetal bleeding may be life-saving if cesarean section is undertaken promptly.

After delivery the treatment for intrapartum fetal bleeding and for the accompanying shock of acidosis must be instituted immediately. Since the baby's blood volume and hence its oxygen-carrying capacity are depleted, fresh whole blood of the same group will best serve the baby's needs. If there is any fetal blood left in the placenta this can be drawn under sterile conditions into a heparinized syringe and infused through a filter, thus avoiding the hazards of the use of unmatched blood. It does, however, impose a small risk of infection and embolization of microthrombi. A second choice would be to have available for use in such a case a unit of unmatched group O, Rh-negative blood or packed erythrocytes. This unit could be kept in the

blood bank or in the case room for emergency use only. A third choice would be to have a number of group O, Rh-negative blood donors identified among the hospital personnel, whose blood could be drawn and used immediately without cross-matching. In an emergency, although there is a significant additional risk of the baby becoming sensitized and an extremely rare possibility of a graft-versus-host reaction, the mother's blood might be used for the transfusion.

The need for routine screening for fetal bleeding is obvious from our experience. We believe that no perinatal centre should be without the means of identifying and responding immediately to the consequences of intrapartum fetal blood loss.

References

1. KOBAK AJ, COHEN MR: Velamentous insertion of cord with spontaneous rupture of vasa previa in twin pregnancy. *Am J Obstet Gynecol* 38: 1063, 1939
2. DIPPEL AL: Hematomas of umbilical cord. *Surg Gynecol Obstet* 70: 51, 1940
3. RUSSELL JF, WARRICK CK: Radiology in the management of anterior placenta praevia. *Lancet* 1: 785, 1955
4. MITCHELL APB, ANDERSON GS, RUSSELL JK: Perinatal death from foetal exsanguination. *Br Med J* 1: 611, 1957
5. NELIGAN GA, RUSSELL JK: Blood loss from foetal circulation: hazard of lower segment caesarean section in cases of placenta praevia. *J Obstet Gynaecol Br Emp* 61: 206, 1954
6. RUSSELL JK, SMITH DF, YALE R: Foetal exsanguination associated with surgical induction of labour. *Br Med J* 2: 1414, 1956
7. MISENHIMER HR: Fetal hemorrhage associated with amniocentesis. *Am J Obstet Gynecol* 94: 1133, 1966
8. RYAN GT, IVY R JR, PEARSON JW: Fetal bleeding as a major hazard of amniocentesis. *Obstet Gynecol* 40: 702, 1972
9. KIRSHEN EJ, BENIRSCHKE K: Fetal exsanguination after amniocentesis. *Obstet Gynecol* 42: 615, 1973
10. KOSMAK GW: Intrauterine rupture of a velamentous umbilical cord. *Am J Obstet Gynecol* 4: 619, 1922

BOOKS

continued from page 630

EPIDEMIOLOGY AND HEALTH. Edited by Walter W. Holland and Susie Gilderdale. 221 pp. Illust. Henry Kimpton Publishers, London; Year Book Medical Publishers, Inc., Chicago, 1977. Price not stated. ISBN 0-85313-796-X

THE ETHICAL PHARMACEUTICAL INDUSTRY AND SOME OF ITS ECONOMIC ASPECTS. An Annotated Bibliography. Bibliographic Series No. 13. Compiled at the Addiction Research Foundation by David C. Sevigny. Edited by R.J. Hall. 520 pp. Addiction Research Foundation, Toronto, 1977. \$10, paperbound. ISBN 0-88868-022-8

HANDBOOK OF CLINICAL DRUG DATA. 4th ed. 1978. James E. Knoben, Philip O. Anderson and Arthur S. Watanabe. 464 pp. Illust. Drug Intelligence Publications, Hamilton, IL, 1978. Price not stated. ISBN 0-914768-27-1

IMMEDIATE HYPERSENSITIVITY. Modern Concepts and Developments. Edited by Michael K. Bach. 848 pp. Illust. Marcel Dekker, Inc., New York, 1978. \$47.50. ISBN 0-8247-6602-4

continued on page 662