

# Biofeedback treatment of blepharospasm with spasmodic torticollis

MILTON R. ROXANAS,\* MB, BS; MARTYN R. THOMAS,† MA; MORTON S. RAPP,‡ MD

Blepharospasm and torticollis are both uncommon conditions and they rarely occur in the same person. Blepharospasm may result from localized eye disease or it may be an early symptom of Parkinson's disease. Torticollis has been associated with various organic lesions.<sup>1-5</sup> The psychoanalytic view is that the person with blepharospasm does not wish to look at something,<sup>6</sup> and the person with torticollis has intrapsychic conflict. Yates,<sup>7</sup> however, believes torticollis is a tic resulting from operant conditioning. Blepharospasm could also be considered a tic.

Both conditions tend to be persistent and disabling.<sup>8</sup> Treatment for torticollis includes psychotherapy,<sup>9,10</sup> hypnotherapy,<sup>11</sup> behaviour therapy<sup>12,13</sup> and biofeedback,<sup>14,15</sup> the results of which have varied. There is little in the literature on the treatment of blepharospasm. Brudny and colleagues<sup>15</sup> had some success using biofeedback in two cases of hemifacial spasm but none in one case of blepharospasm.

In the study described below we investigated the efficacy of electromyographic (EMG) biofeedback in the treatment of blepharospasm compounded by torticollis. It was hoped that EMG training would act as "direct muscle retraining".<sup>16</sup>

## Case report

### *Clinical course and findings*

A 60-year-old woman presented with an 18-month history of difficulty in keeping her eyes open and a persistent tilt of her head to the right. The first symptom, twitching of the eyelids, had progressed over a 3-week period to almost total eye closure. During this

period she had felt a swelling on the right side of her neck accompanied by pain and spasm, which had led to persistent tilting of the head to the right. These symptoms made simple self-care difficult. Difficulty in talking and eating followed, and she lost 14 kg. She did not, however, have classic depression.

Detailed neurologic and endocrinologic investigation gave negative results.

The woman had grown up in an unstable home with an aggressive, alcoholic father and a cold, unresponsive mother. Her marriage was unhappy, and her husband deserted her after their second child was born. At the time of admission she was living alone, not far from a married son. Her main diversions were crocheting and watching television. She was shy and tense, dwelt at length on her symptoms, but showed normal content and processes of thought. Affect was appropriate, depression could not be detected and cognitive function was normal.

At this time section of the facial nerve was considered.

### *Biofeedback treatment*

Before treatment three variables were measured: the distance between the patient's eyelids, an indicator of the degree of blepharospasm; the angle of tilt of her head, an indicator of the severity of torticollis; and the EMG activity in the frontalis muscle, measured on a Beckman RM Dynograph (Beckman Instruments Inc., Etobicoke, Ont.). Each 30-minute assessment session consisted of a series of alternating periods in which the eyes were open or closed (for formal measurement), followed by an informal interview. Each session was videotaped and measurements of the three variables were taken simultaneously from the video screen at 2-second intervals throughout the session; the patient was minimally aware that measurements were being taken.

All the pretreatment measurements were repeated immediately after treatment and again after a 6-month period during which treatment was not given.

Treatment began with the recording of baseline measurements. The patient sat in a comfortable chair with her eyes closed and listened to a 30-minute tape-recording of relaxation suggestions. The average EMG activity in the frontalis

muscle was recorded but no information feedback was given.

The EMG feedback procedure\* was started at the second session and continued twice daily for 20 days. During each session the patient was provided with auditory and visual feedback indicating the EMG activity in the frontalis muscle. Auditory feedback consisted of discrete clicks whose frequency varied directly with the EMG potential of the frontalis muscle. Visual feedback was a digital display of the EMG potential in microvolts. Feedback was provided during two 8-minute periods of a 24-minute session. The first five sessions were conducted with the patient's eyes closed. During the remaining sessions the patient was asked to open her eyes for increasing periods as the sessions progressed.

### *Results*

Following treatment the patient reported substantial subjective improvement. She performed all activities of daily living normally and once again enjoyed crocheting and watching television. The improvement was maintained after 6 months without treatment. Objectively there was a striking decrease in the average EMG potential, from 329.6  $\mu$ V before treatment to 9.4  $\mu$ V after treatment, while she was watching an irrelevant tape/slide travelogue.

The percentage improvement in the three dependent variables from before treatment to immediately after treatment and 6 months later is illustrated in Fig. 1. The degree of change in each variable correlated well with the patient's subjective report. The fact that the EMG activity showed the most improvement of the three variables suggests, but does not prove, that the EMG feedback procedure was the most important factor in the patient's improvement.

### *Discussion*

The frontalis EMG activity in this case of refractory blepharospasm and torticollis was reduced after treatment, and this resulted in symptomatic improvement.

Since blepharospasm is common in

From Sunnybrook Medical Centre, University of Toronto

\*Teaching fellow, department of psychiatry

†Behaviour therapist, department of psychology

‡Associate professor, department of psychiatry

Reprint requests to: Mr. Martyn R. Thomas, Coordinator, behaviour therapy, Sunnybrook Medical Centre, 2075 Bayview Ave., Toronto, Ont. M4N 3M5

\*Technical details of equipment, electrode placement and so forth are available on request from Mr. Thomas at the address noted for reprint requests.

persons of this age who are depressed, and since this woman had a weight loss, the question arises whether depression was the underlying problem. However, her eye and head problems had begun 18 months prior to treatment and they diminished rapidly during the 20 days of treatment. Other signs of depression were not evident and antidepressants were not given. Hence, while spontaneous recovery from depression cannot be ruled out, it is unlikely, for such recovery is usually gradual.

It is easy to see a relation between the reduction of EMG activity in the frontalis muscle and the diminishing of blepharospasm. The reason for the reduction in torticollis is not as readily apparent since the frontalis muscle is not directly associated with tilting of the head.

However, Stoyva and Budzynski<sup>17</sup> have described generalization of muscle tension from the frontalis to

other skeletal muscles. As well, Basmajian<sup>18</sup> has reported that surface electrodes placed more than 4 cm apart on the frontalis muscle may record activity from muscles as distant as the lower rib cage. Therefore a reduction in EMG activity recorded from the frontalis muscle may indicate a reduction in tension in any of these other muscle groups, including the sternomastoid group.

Regardless of the specific mechanism, the important result in this case was that surgical intervention was rendered unnecessary. This suggests that EMG biofeedback training should be considered before facial nerve section or other surgical intervention is recommended in the treatment of blepharospasm and torticollis.

### References

1. FOLTZ EL, KNOPP LM, WARD AA JR: Experimental spasmodic torticollis. *J*

*Neurosurg* 16: 55, 1959

2. GUILLAIN G, BIZE R: Sur un cas de sclérose en plaques avec torticollis spasmodique. *Rev Neurol (Paris)* 40: 133, 1933
3. SCHAEFFER H, BIZE R: Torticollis spasmodique avec syndrome cérébello-pyramidal d'origine spécifique. *Rev Neurol (Paris)* 42: 579, 1934
4. FINNEY JMT, HUGHSON W: Spasmodic torticollis. *Ann Surg* 81: 255, 1925
5. HASSIN GB, SCHAUB CF, VORIS HC: Spasmodic torticollis. *Arch Neurol Psychiatry* 26: 1043, 1931
6. FENICHEL O: *Psychoanalytic Theory of the Neuroses*, Norton, New York, 1945, p 318
7. YATES AJ: *Behavior Therapy*, Wiley, New York, 1970, p 201
8. MEARES R: Features which distinguish groups of spasmodic torticollis. *J Psychosom Res* 15: 1, 1971
9. YASKIN JC: Treatment of spasmodic torticollis with special reference to psychotherapy, with report of a case. *J Nerv Ment Dis* 81: 299, 1935
10. WHILES WH: Treatment of spasmodic torticollis by psychotherapy. *Br Med J* 1: 969, 1940
11. FRIEDMAN H: Hypnosis in the treatment of a case of torticollis. *Am J Clin Hypn* 8: 139, 1965
12. AGRAS S, MARSHALL C: The application of negative practice to spasmodic torticollis. *Am J Psychiatry* 122: 579, 1965
13. BRIERLEY H: The treatment of hysterical torticollis by behavior therapy. *Behav Res Ther* 5: 139, 1967
14. CLEELAND CS: Behavioral technics in the modification of spasmodic torticollis. *Neurology (Minneapolis)* 23: 1241, 1973
15. BRUDNY J, KOREIN J, LEVIDOW L, et al: Sensory feedback therapy as a modality of treatment in central nervous system disorders of voluntary movement. *Neurology (Minneapolis)* 24: 925, 1974
16. BLANCHARD EB, YOUNG LD: Clinical applications of biofeedback training: a review of evidence. *Arch Gen Psychiatry* 30: 573, 1974
17. STOYVA J, BUDZYNSKI T: Cultivated low arousal: an antistress response? in *Biofeedback and Self-Control 1974: Aldine Annual on the Regulation of Bodily Processes and Consciousness*, DYCARA LV, BARBER TX, KAMIYA J, et al (eds), Aldine, Chicago, 1975, p 273
18. BASMAJIAN JV: Emerging roles of biofeedback in rehabilitation medicine. Presented at "Biofeedback & Behavioral Medicine", Montreal, Oct 15, 1977

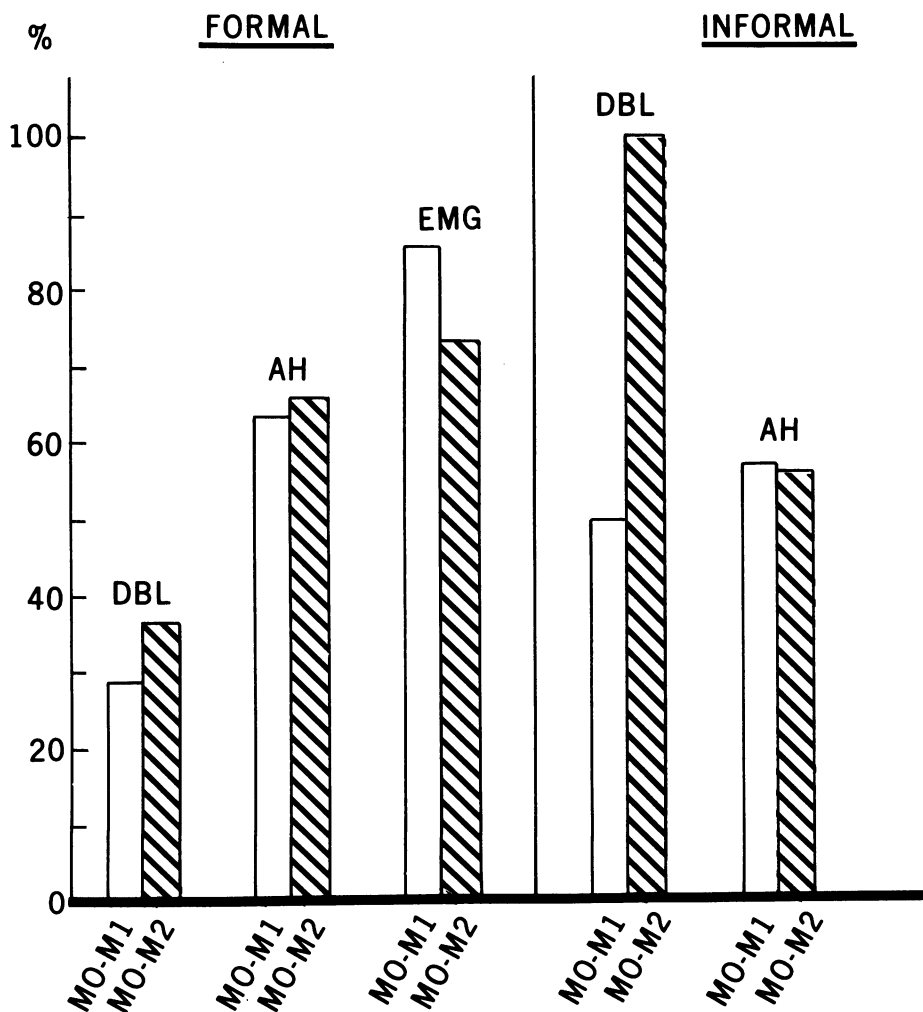


FIG. 1—Percentage improvement in three dependent variables as assessed by formal measurement and informal interview, from before treatment (M0) to immediately after (M1) and 6 months after (M2) treatment. DBL = distance between patient's eyelids; AH = angle of head tilt; EMG = electromyographic activity.