

## TORULOSIS OF THE CENTRAL NERVOUS SYSTEM\*

S. J. HOLMES, M.D. and  
G. H. HAWKS, M.D., Toronto

INFECTION OF MAN with the yeast-like organism, *Cryptococcus neoformans* (*Torula histolytica*) is rare. In the literature are to be found about 195 cases reported from many countries and from all walks of life. The varying difference in incidence, as recorded, is perhaps a reflection of the local facility at recognition, for some cases are very difficult to diagnose.

The first descriptions of *T. histolytica* infection of the nervous system are to be found in the German literature by von Hansemann<sup>1</sup> in 1905 and by Turk<sup>2</sup> in 1907. Rusk<sup>3</sup> in 1912 described the first case on this continent and in 1916 Stoddard and Cutler<sup>4</sup> attempted to correlate the clinical and pathological pictures and, in so doing, felt that the gelatinous cysts produced by the organism were due to histolytic action. However, many conflicting reports have followed, among them Freeman's<sup>5</sup> publication of 8 cases in 1931. In these he concluded that the cysts were the result of pressure necrosis from large colonies of the organism. In 1946 Voyles and Beck<sup>6</sup> reviewed the subject of torulosis and were able to collect 108 cases, to which they added 4 of their own. A comprehensive monograph was published in the same year by Cox and Tolhurst<sup>7</sup> of Australia and they added 12 new cases. Mosberg and Arnold<sup>8</sup> in 1950 summarized 64 cases which had been reported since the review by Voyles and Beck. More recently 14 additional cases have been reported.<sup>9 to 15</sup>

We have been able to find only two cases of yeast infection in the medical literature from Canada. In 1932 R. S. Saddington<sup>16</sup> in Toronto described a fatal pulmonary infection with a yeast-like organism which remained unidentified because cultures were not obtained. The illustrations are compatible with this having been a cryptococcal infection. In 1940, under "Meningite à blastomycès (*Torula Gilchristi*)" H. Nadeau<sup>17</sup> of Quebec City described a case of meningitis treated with potassium iodide with recovery. A yeast-like organism was seen in the cerebrospinal fluid and in material from skin lesions. An encapsulated yeast-like organism, without a fila-

mentous phase, was cultured from the cerebrospinal fluid and was pathogenic for white mice. It was tentatively classified as *T. Gilchristi* but a final identification was not reported. From the description of this microorganism it could well have been *Cryptococcus neoformans*.

So far as the authors are aware the case to be presented is the first case of torulosis of the central nervous system, definitely established as due to *Cryptococcus neoformans*, to be reported from Canada.

### CASE HISTORY

H.M., a 42 year old farmer, developed at the age of 35, a lump in the left side of his neck. A diagnosis of Hodgkin's disease was made by biopsy at that time. He received radiation therapy and remained well until three months before death when he had diarrhoea, which cleared promptly with bed rest. Following this he ran a persistent low-grade fever and complained of headache, loss of visual acuity, dizziness and transient diplopia, which became progressively worse. Two months before death he was a pale, chronically ill man with an enlarged spleen and a palpable liver. He showed a fine horizontal nystagmus and bilateral papilloedema, with recent hæmorrhages in the right retina. A lumbar puncture showed a pressure of 85 mm. of water. The fluid was clear and yellowish with a cell count of 26 (18 polymorphonuclear leucocytes and 8 lymphocytes), and a protein level of 189 mgm. %. A chest film showed slight hilar glandular enlargement. Skull films were normal. Hæmoglobin was 66%, red blood count 3.8 million and white blood count 8,700. A ventriculogram, six weeks before his death, showed that the descending horn of the right lateral ventricle did not fill with air. An exploratory operation was performed, and tissue removed by aspiration biopsy from the right temporal lobe was reported, on quick section, as papilloma of the choroid plexus. No tumour was found on further exploration.

When paraffin sections of the biopsy material were available it was found that there was a granulomatous reaction in the choroid plexus, with areas showing œdema, infiltration with lymphocytes, plasma cells and an occasional giant cell, against a background of proliferating fibroblasts and fibrous tissue thickening. In this tissue a yeast-like organism was seen, which was later identified as *Cryptococcus neoformans*, and the original diagnosis was changed to torulosis of the choroid plexus.

In the microscopic sections (Fig. 1) the organisms took a basophilic stain with hæmotoxylin and eosin. They varied in size and were seen in necrotic as well as in viable tissue. Individual yeast cells were surrounded by clear spaces which, in some areas, appeared confluent. The basophilic wall showed a double contour under the high magnification and, in the centre, some acidophilic staining granules were to be seen in some organisms. In the tissue sections no budding forms were seen. With aniline dyes (cresyl violet, Fig. 2) the organisms showed a spiked exterior which has been described by Hassin<sup>18</sup> as characteristic of torula, but others feel that it is an artifact of staining. The surrounding cellular reaction was composed of lymphocytes, plasma cells and epithelioid cells. Proliferating fibroblasts provide the basic framework for the reaction. Only an occasional giant cell was seen.

Two specimens of spinal fluid, one obtained seven days after exploratory operation and a second sixteen days postoperatively, showed the presence of 3 to 6 encapsulated, budding yeast-like organisms per low power microscopic field. These were morphologically and culturally typical of *Cryptococcus neoformans*.

In the moist India ink preparation of the cerebrospinal fluid (Fig. 3) the organisms were seen to be spherical

\*Presented before the Academy of Medicine, Toronto, March 28, 1950.  
From the Department of Bacteriology and the Division of Neuropathology, University of Toronto.

in shape, single, budding, yeast-like and to vary in diameter from approximately 5 to 15 microns. The cells had a thick wall which appeared doubly refractile according to the level of focus. Inside the individual yeast cells large granules were evident. The character of these was not tested, but they have been identified by others as globules of fat which have the ability to take up the common fat stains.<sup>19</sup> The India ink outlined the very wide, gelatinous capsule, which is an essential characteristic of the *Cryptococcus* species. No mycelium was seen.

Cultures on blood agar and Sabouraud's agar slopes incubated at room temperature and at 37° C. showed a profuse growth of large, moist, glistening, cream-coloured colonies in 4 days. After 10 days these had acquired a light brownish shade and the colonies had run together toward the bottom of the slope, due to the large amount of gelatinous polysaccharide capsular material (Fig. 4). Examination of a moist preparation of the growth from the Sabouraud's agar slope revealed large numbers of budding yeast-like cells. Occasionally cells were seen to produce short germ tubes which, apparently, is an attempt on the part of the organism to form mycelial elements. The amount of capsular material about the cells varied, some having wide capsules and others narrow ones. This is of interest for Neill *et al.*<sup>20</sup> showed

yeast-like bodies each surrounded by a large space (Fig. 5). After the diagnosis had been established, the patient was treated with large doses of penicillin, sulfadiazine and potassium iodide. Two spinal fluid specimens taken 7 and 16 days postoperatively showed the presence of *Cryptococcus neoformans* organisms, but these organisms could not be demonstrated in a further specimen taken on the twentieth day after operation.

The patient showed no response to treatment. Deterioration was slow and relentless with death occurring five weeks after operation. Permission for post mortem examination was not obtained.

#### DISCUSSION

Clinically, torulosis is mainly a disease of adult life in that two-thirds of the reported cases were between 30 to 60 years of age. It occurs in males about twice as frequently as in females and is reported in all walks of life regardless of race, occupation or geographic situation.<sup>21</sup> The central nervous system is affected alone in about

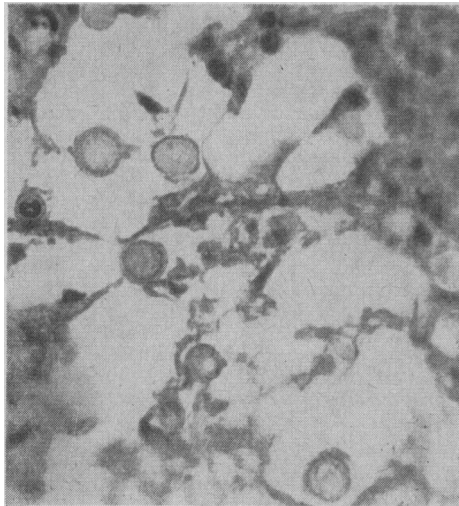


Fig. 1

Fig. 1.—*Cryptococcus neoformans* in choroid plexus. (Hæmatoxylin and Eosin. x 800).

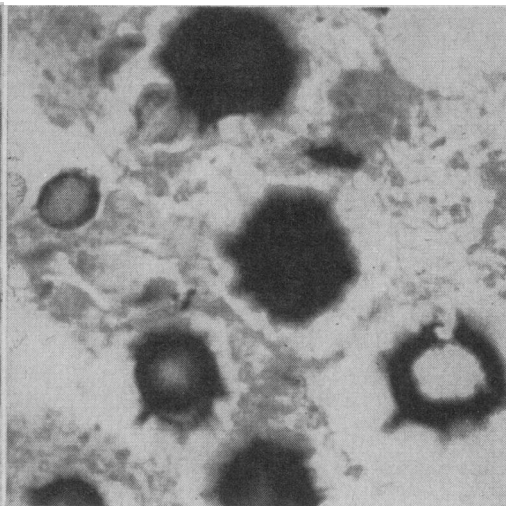


Fig. 2

Fig. 2.—*Cryptococcus neoformans* in choroid plexus. (Cresyl violet. x 2,000).

that the antibody-forming capacity of a culture of cryptococci was related inversely to the size of the capsule.

The fermentative power of the *Cryptococcus neoformans* is weak and variable. The majority of strains have been found to ferment dextrose and saccharose with the production of acid with no gas. The organism isolated in this case produced acid with no gas in dextrose only of the several sugars tested. Gelatin was liquefied after ten weeks. The organism did not form a pseudomycelium, or give rise to a filamentous phase at room temperature, and did not produce ascospores on carrot plug medium. These features, together with the possession of a wide capsule and the weak fermentative powers, serve to differentiate *Cryptococcus neoformans* from the other pathogenic yeast-like fungi and the common yeasts.

Three white mice were injected intraperitoneally with 1 c.c. of a heavy saline suspension of the organism grown on Sabouraud's agar. The mouse is the most susceptible laboratory animal, but there is marked variation in individual resistance. The animal may be infected by almost any route and the infection is invariably fatal. This strain killed all three mice within 18 days and the organism was recovered at autopsy from the sticky, gelatinous peritoneal exudate. On section, the mesentery showed the typical granulomatous reaction and infiltration with lymphocytes and a few polymorphonuclear leucocytes. There were masses of typical round to oval budding

50% of the cases, the lungs and central nervous system in 15% and a general systemic infection in the remaining 35%. The illness may be acute, with death in from one to six months, or more chronic, with attacks and remissions extending over two to four years. Stevenson *et al.*<sup>22</sup> have reported the incidental post mortem finding of torula cysts in brain tissue.

Torulosis of the nervous system shows itself usually as a meningitis or meningoencephalitis but it may produce a space-occupying lesion with focal signs and, in advanced cases, the symptoms of increased intracranial pressure. Some cases have been reported with an onset of symptoms of mental illness, which have continued to dominate the clinical picture for some time. The cerebrospinal fluid findings will depend on the type of infection. In localized lesions

it may be normal, whereas in the typical cases of meningitis or meningoencephalitis there is an elevation of pressure, cells and total protein with a reduction of chlorides and sugar. Lymphocytes usually predominate in the fluid but sometimes the majority of the cells are polymorphonuclear leucocytes. Since other organs are affected in 50% of cases, signs and symptoms referable to them may be the presenting features or occur during the patient's illness.

It is of interest to note that torulosis is preceded by, or is associated with solitary or gen-

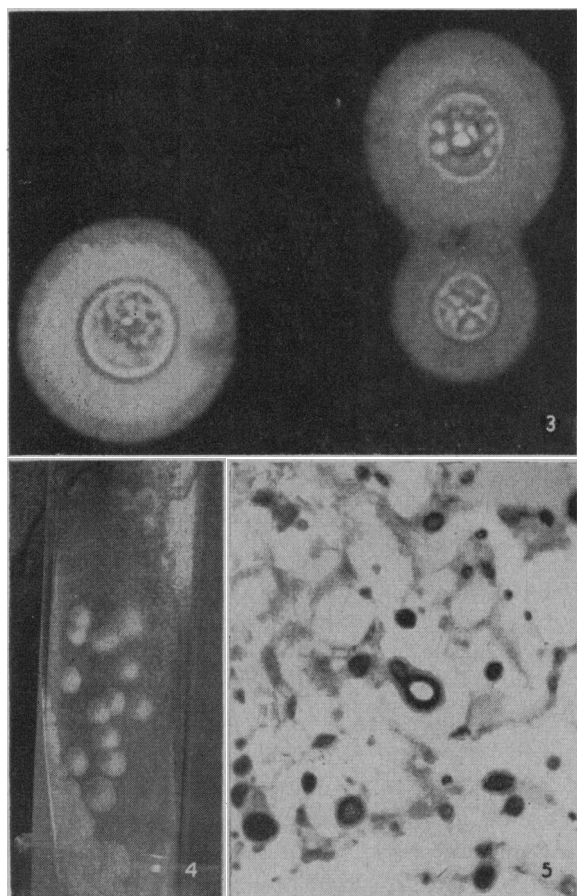


Fig. 3.—*Cryptococcus neoformans* in cerebrospinal fluid. (India ink preparation x 4,000). Fig. 4.—*Cryptococcus neoformans* colonies growing on Sabouraud's agar. Note the tendency for the colonies to run together towards the bottom of the slope. (Actual size). Fig. 5.—Section of mouse mesentery showing the round to oval budding encapsulated yeast-like forms. (Cresyl violet. x 470).

eralized enlargement of lymph glands in about 18% of cases. Biopsy of these glands has not infrequently been diagnosed as Hodgkin's disease. Such an association was seen in the case under discussion. Although experimental animals infected with *Cryptococcus neoformans* may show lymphadenitis, sections of the glands do not resemble Hodgkin's disease.<sup>7, 13, 23, 24</sup>

Pathologically the response of the tissues to invasion by the cryptococcus is very similar to that of tuberculosis, with the formation of lesions which are granulomatous in nature and composed of lymphocytes, plasma cells, epithelioid cells, giant cells and proliferating fibroblast. In contrast to tuberculosis there is little evidence of caseation. In the central nervous system the gross picture may be minimal or very evident. Characteristically, the subarachnoid space is distended with thick, gelatinous material which may extend over both cerebral hemispheres, cerebellum and spinal cord. Often this exudate is limited to the sulci or the basal cisterns and, occasionally, little granulomatous masses resembling tubercles may be seen scattered over the surface. The dura and arachnoid may be thickened and, when the arachnoid is stripped, small gelatinous cysts may be seen varying in size, and apparently confined to the grey matter of the cortex. On section of the brain they may be seen in the basal ganglia, or as small elevations of the ependymal surfaces of the ventricles or in the choroid plexuses. The large lesions are cystic, containing gelatinous material.

No drug has as yet been found to have any marked effect in the treatment of torulosis. The strain isolated from the spinal fluid in this case was found to be resistant to penicillin, aureomycin, and potassium iodide. It was sensitive to 10 mgm. % of sulfadiazine. After treatment of the patient with penicillin, sulfadiazine and potassium iodide, a third specimen of cerebrospinal fluid taken nineteen days before death, was sterile on culture. Conant<sup>25</sup> reports two successfully treated cases of pulmonary torulosis. One patient received a combination of sulfadiazine and autogenous vaccine therapy, while the other was treated with sulfadiazine, potassium iodide and desensitization with vaccines. Torulosis of the central nervous system does not respond so readily, and the reports of treatment with sulfadiazine have so far been disappointing. Reilly *et al.*<sup>26</sup> have reported that *Cryptococcus neoformans* is sensitive to streptothricin, and have shown the drug to be effective in inhibiting growth of the organism in concentrations which can be obtained in body fluids. This drug, however, has a high toxicity which limits its clinical use.<sup>27, 28</sup> Mosberg and Arnold<sup>8</sup> have noted that the cryptococcus is rapidly killed by a temperature of 40° C., and more recently Mosberg and Alvarey-De Choudens<sup>29</sup> report that the organism

is highly sensitive to an alkaline pH. They suggest, therefore, that alkalinization, with hyperthermia, be tried as a form of therapy. So far as we know this has not received a clinical trial.

#### SUMMARY

1. A fatal case of torulosis of the central nervous system due to *Cryptococcus neoformans* has been presented.

2. The clinical, pathological and bacteriological aspects of this infection have been discussed.

3. In this case a diagnosis of Hodgkin's disease, with apparent cure by radiation therapy, was made seven years before his final illness. The association of these two diseases has been reported previously on several occasions.

4. A search of the literature revealed only one previous case report of yeast-like infection of the nervous system from Canada. Since in that instance the causative agent was not definitely established as *Cryptococcus neoformans*, this is, we believe, the first completely proved Canadian case of this infection in the human nervous system.

The authors wish to thank Drs. E. J. Maltby and E. H. Botterell for permission to publish this case, and to acknowledge the valuable assistance of Drs. Mary I. Tom, E. A. Linell and P. H. Greey in the preparation of this paper.

#### REFERENCES

- VON HANSEMAN, D.: *Verhandl. d. deutsch. path. Gesellsch.*, 9: 21, 1905.
- TURK, W.: *Arch. f. klin. Med.*, 90: 335, 1907.
- RUSK, G. Y.: *Univ. California Publ. in Path.*, 2: 47, 1912.
- STODDARD, J. L. AND CUTLER, E. C.: *Studies from the Rockefeller Institute for Med. Res. Reprints*, 25: 1, 1916.
- FREEMAN, W.: *Jahrb. f. Psychol. u. Neurol.*, 43: 236, 1931.
- VOYLES, G. Q. AND BECK, E. M.: *Arch. Int. Med.*, 77: 504, 1946.
- COX, L. B. AND TOLHEURST, J. C.: *Human Torulosis. A monograph.* Melbourne University Press, 1946.
- MOSBERG, JR. W. H. AND ARNOLD, JR. J. G.: *Ann. Int. Med.*, 32: 1153, 1950.
- DE WAN, C. H., LEFFLER, R. J. AND COLLETTE, T. S.: *Guthrie Clin. Bull.*, 19: 75, 1949.
- ALDERMAN, L. W.: *M. J. Australia*, 2: 914, 1949.
- FISHER, A. M.: *Bull. Johns Hopkins Hosp.*, 86: 383, 1950.
- RATCLIFFE, H. E. AND COOK, W. R.: *U.S. Armed Forces M. J.*, 1: 957, 1950.
- GÜNDEL, B. R., ENDE, M. AND NORMAN, S. L.: *Am. J. Med.*, 9: 343, 1950.
- PARILLO, O. J.: *J. A. M. A.*, 144: 747, 1950.
- GLOBUS, J. H., GANG, K. M. AND BERGMAN, P. S.: *J. Neuropath. & Exper. Neurol.*, 10: 208, 1951.
- SADDINGTON, R. S.: *Canad. M. A. J.*, 26: 544, 1932.
- NADEAU, H.: *Laval Médical*, 5: 364, 1940.
- HASSIN, G. B.: *J. Neuropath. & Exper. Neurol.*, 6: 44, 1947.
- BENHAM, R. W.: *Arch. Dermat. & Syph.*, 30: 385, 1934.
- NEILL, J. M., ABRAHAMS, I. AND KAPROS, C. E.: *J. Bact.*, 59: 263, 1950.
- Zinsser's Textbook of Bacteriology, Appleton-Century-Crofts, Inc., p. 846, 1948.
- STEVENSON, L. D., VOGEL, F. S. AND WILLIAMS, V.: *Arch. Path.*, 49: 321, 1950.
- CUSTER, R. P. AND BERNHARD, W. G.: *Am. J. M. Sc.*, 216: 625, 1948.
- FITCHETT, M. S. AND WEIDMAN, F. D.: *Arch. Path.*, 18: 225, 1934.
- CONANT *et al.*: *Manual of Clinical Mycology*, Philadelphia, W. B. Saunders, 1944.
- REILLY, H. C., SCHATZ, A. AND WAKSMAN, S. A.: *J. Bact.*, 49: 585, 1945.
- MOLITOR, H.: *Bull. New York Acad. Sc.*, 48: 101, 1946.
- MUSHETT, C. W. AND MARTLAND, H. S.: *Federation Proc.*, 5: 194, 1946.
- MOSBERG, W. H. AND ALVAREY-DE CHOUDENS, J. A.: *Lancet*, 1: 1259, 1951.

#### COMPLICATIONS OBSERVED DURING ACTH AND CORTISONE THERAPY\*

J. R. MARTIN, M.D., M.R.C.P.(Lond.),† and  
C. J. PATTEE, B.A., M.Sc., M.D., C.M.,‡  
Montreal

SINCE THE SUMMER of 1950, 130 patients have been treated with parenteral or oral cortisone and ACTH at the Queen Mary Veterans' Hospital, with 30 patients developing complications. Of this group of 130 patients, 4 were females. Boland *et al.*<sup>1</sup> have remarked on the greater tendency of females to develop complications than males. In his series of 60 patients, there were 24 with complications of whom 17 were females. Age also seems to be an important factor in the development of complications. Kuzell<sup>2</sup> found that of 32 patients who developed

such complications during cortisone therapy, 21 were over 40 years of age.

The size of the daily dose is also important. Boland *et al.*<sup>1</sup> and Ward<sup>3</sup> believe that the incidence of complications goes up sharply when cortisone is administered in daily doses of 75 mgm. or more. Partridge *et al.*<sup>4</sup> have shown that patients on a high fat, low carbohydrate diet have a smaller incidence of side effect complications than those on other regimens, whilst Liddle *et al.*<sup>5</sup> state that a daily intake of 150 to 350 mEq. of potassium prevents the onset of sodium retention. At the Queen Mary Veterans' Hospital, the average daily diet consists of 3,272.3 calories. This contains 101.9 gm. of protein, 141.8 gm. of fat and 417.1 gm. of carbohydrate. The sodium content is 177.5 mEq. and the potassium is 88.80 mEq.

#### CARDIOVASCULAR COMPLICATIONS

There is an increase in the frequency of attacks of angina pectoris in patients with this

\*From the Queen Mary Veterans' Hospital, Montreal.  
†Research Fellow, Clinical Investigation Unit.  
‡Director, Clinical Investigation Unit.