

The history of this case suggests that the lipoma may have been present from birth or shortly thereafter. There are a few reports in the literature of congenital intracerebral lipomas, but most of these have been multiple and frequently associated with other congenital lesions.<sup>14</sup> These lesions are probably developmental heterotopias or hamartomas. The presence of fibrous, hæmangiomatous and osteoid elements in some of the reported examples of lipomas supports such a concept. The lipoma that is reported here may actually be of a similar nature although there were no other congenital lesions.

Most of the intracranial lipomas reported were symptomless and produced no significant changes in the brain or skull. This lipoma is a relatively large one and by obstruction of the ventricular system in the region of the midbrain caused hydrocephalus with marked thinning of the skull. The severe headaches and the possible increase in size of the head for approximately one year before death may be attributed to increased intracranial pressure and to the internal hydrocephalus. The automobile accident which caused death was a very minor one, but sufficient to produce many fractures in a very thin skull and severe laceration of the cerebral cortex.

#### SUMMARY

A lipoma of the dorsal midbrain in a 25-year-old male is reported. This is believed to be the ninth recorded case of a lipoma in this location. It obstructed the aqueduct of Sylvius at its junction with the fourth ventricle and caused internal hydrocephalus. The tumour may have been present from birth. Death occurred after a very minor automobile accident and was due to extensive cerebral laceration and multiple fractures in a very thin atrophic skull.

Fasciculi of the trochlear nerves, glial tissue, and several ganglion cells were present in the lipoma. They were not considered a component of the tumour but were thought to have become included by growth and infiltration. Present evidence indicates that this type of tumour develops from the primitive mesenchyme in or close to the pia mater, and that it may be of a hamartomatous nature.

#### REFERENCES

1. VONDERAHE, A. R. AND NIEMER, W. T.: *J. Neuropath. & Exper. Neurol.*, 3: 344, 1944.
2. SPERLING, S. J. AND ALPERS, B. J.: *J. Nerv. & Ment. Dis.*, 83: 13, 1936.
3. BAILEY, P. AND BUCY, P. C.: *Am. J. Cancer*, 15: 15, 1931.
4. EHNI, G. J. AND ADSON, A. W.: *Arch. Neurol. & Psychiat.*, 53: 299, 1945.
5. EWING, J.: *Neoplastic diseases*, 4th ed., W. B. Saunders Company, Philadelphia, 1940.
6. LIST, C. F., HOLT, J. F. AND EVERETT, M.: *Am. J. Roentgenol.*, 55: 125, 1946.
7. NORDIN, W. A., TESLUK, H. AND JONES, R. K.: *A.M.A. Arch. Neurol. & Psychiat.*, 74: 300, 1955.
8. BARBER, M. R.: *Canad. M. A. J.*, 63: 495, 1950.
9. WELLS, H. G.: *J. A. M. A.*, 114: 2177, 1940.
10. EHNI, G. AND LOVE, J. G.: *Arch. Neurol. & Psychiat.*, 53: 1, 1945.
11. ADAIR, F. E., PACK, G. T. AND FARRIOR, J. H.: *Am. J. Cancer*, 16: 1104, 1932.
12. CROSBY, R. M. N., WAGNER, J. A. AND NICHOLS, P., JR.: *J. Neurosurg.*, 10: 81, 1953.
13. STOUT, A. P.: Tumors of the peripheral nervous system, Atlas of tumor pathology, Section II, Fascicle 6, Subcommittee on Oncology of the Committee on Pathology of the National Research Council, Armed Forces Institute of Pathology, Washington, D.C., 1949.
14. BAKER, A. B. AND ADAMS, J. M.: *Am. J. Cancer*, 34: 214, 1938.

## SYNCOPAL ATTACKS FOLLOWING QUINIDINE ADMINISTRATION

F. GERARD ALLISON, F.R.C.P.[C],  
Winnipeg, Man.

A WOMAN of 40 with pure mitral stenosis and auricular fibrillation had a successful commissurotomy in November 1956. She was discharged on digitoxin 0.1 mg. daily and maintained on this dosage. In March 1957, her doctor attempted conversion to normal rhythm with quinidine. Small doses were given without effect except for mild vomiting. On the evening of March 15, a total of 25 grains (1.6 g.) of quinidine was given, the last dose at 10:30 p.m. She vomited all night and had some diarrhoea. In the morning she had three brief episodes of unconsciousness without convulsion.

She was admitted at 11:00 a.m. to St. Boniface Hospital where a further attack of unconsciousness was observed; pulse and blood pressure disappeared but rapid heart sounds could still be heard. Pronestyl (procaine amide) 150 mg. was given intravenously.

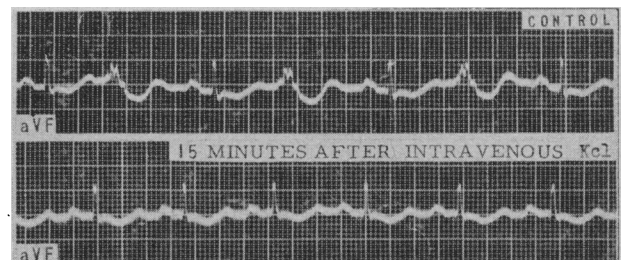


Fig. 1.

When I saw her at 12:30 p.m., she was confused, presumably because of episodes of cerebral anoxia, but not dyspnoeic; B.P. 120/80 mm. Hg; E.C.G. showed a normal rhythm of 40, plus an equal number of ventricular extrasystoles (pulsus bigeminus). Comparison with the preoperative E.C.G. showed marked reduction of the right ventricular hypertrophy. There was sagging of ST intervals, due to digitalis or a low potassium level. A striking feature was prolongation of the QT or QU interval to 0.44 second, normal QT being about 0.34 at this rate. Digitalis shortens the QT interval, quinidine prolongs it. Hypopotassemia occasionally lengthens the QT interval slightly, but frequently gives apparent lengthening, as the U wave is increased in size and may blend with the T wave.<sup>9</sup>

As the last dose of quinidine had been taken 14 hours previously, 70% of the absorbed quinidine should have left the blood, apart from what was lost in vomitus and stool. Studies<sup>1</sup> have shown that eight hours after ingestion of quinidine the blood level is down 50% from its peak, which is attained in two hours. It was concluded that the patient had hypopotassemia brought on by the quinidine-induced diarrhoea and vomiting, and that this had caused digitalis intoxication which led to episodes of ventricular paroxysmal tachycardia with syncope. Unfortunately the laboratory was closed for the week-end, so that blood levels of potassium could not be determined. The following treatment was instituted: 750 mg. Pronestyl was given orally; chlorpromazine (Largactil) 25 mg. intramuscularly for nausea, and

20 mEq./l. of potassium chloride was given in 500 c.c. saline intravenously. Intake of fruit juice and broth was encouraged because of their potassium content. During the afternoon the patient remained without syncope. She received 250 mg. of Pronestyl orally at 2:30 p.m. and 5:00 p.m.

At 9:00 p.m. another attack of syncope occurred. A direct-writer cardiograph at the bedside showed the tracing to be unchanged. Infusion of another 20 mEq./l. of potassium in saline was started, and a small strip of lead AVF was taken every few minutes. In 15 minutes the extrasystoles disappeared, never to return. Another 20 mEq./l. potassium was given two hours later, followed by oral tablets of potassium chloride. The QT interval and sagging ST interval remained unchanged until the following morning.

There were no further symptoms and the patient was discharged 48 hours later. She remains well, in normal rhythm, and takes no medication.

In recent years it has been recognized<sup>2</sup> that digitalis intoxication can be readily induced in a fully digitalized patient by potassium loss, e.g. after a mercurial diuresis, or by reducing the plasma level of potassium by a high carbohydrate meal, intravenous glucose or insulin. In fact, E.C.G. control after 25 g. of glucose intravenously is a test for borderline digitalis toxicity. Six of seven patients so tested<sup>3</sup> developed extrasystoles within 90 minutes, and one had paroxysmal ventricular tachycardia which was controlled by intravenous potassium.

Administration of potassium and procaine amide has been recognized<sup>4</sup> as the best treatment for digitalis intoxication. Very recently a new method of treating digitalis intoxication with EDTA (ethylenediamine tetra-acetic acid) was introduced.<sup>5</sup> Sodium or magnesium ethylenediamine tetra-acetic acid, a chelating agent given intravenously, lowers blood calcium and rapidly abolishes arrhythmias due to digitalis. There is a synergistic relationship between digitalis and calcium. The chelation treatment should be followed by potassium administration to prevent recurrence of symptoms.

This patient had been on a maintenance dose of digitoxin (Crystodigin, Purodigin, etc.). The incidence of cases of digitalis poisoning increased enormously after introduction of these drugs.<sup>6</sup> Frequently arrhythmias were the first sign of overdosage.<sup>7</sup> Toxicity persists longer than with other digitalis bodies.

When a patient reacts with vomiting or diarrhoea to a small dose of quinidine, it is wise to prevent these symptoms by giving paregoric (camphorated opium tincture) before larger doses are administered.<sup>8</sup> This not only makes administration of therapeutically effective doses possible but prevents unpleasant side effects, and also prevents loss of potassium in vomitus or stool.

## REFERENCES

1. DELEVETT, A. F. AND POINDEXTER, C. A.: *Am. Heart J.*, 32: 697, 1946.
2. LOWN, B. *et al.*: *Proc. Soc. Exper. Biol. & Med.*, 76: 797, 1951.
3. PAGE, E.: *Am. J. Med.*, 19: 169, 1955.
4. LOWN, B. AND LEVINE, S. A.: *New England J. Med.*, 250: 866, 1954.
5. GUBNER, R. S. AND KALLMAN, H.: *Am. J. M. Sc.*, 234: 136, 1957.
6. FLAXMAN, N.: *Ibid.*, 216: 179, 1948.
7. DEGRAFF, A. C., BATTERMAN, R. C. AND ROSE, O. A.: *J. A. M. A.*, 138: 475, 1948.
8. GOLDMAN, M. J.: *Am. J. M. Sc.*, 222: 332, 1951.
9. SURAWICZ, B. *et al.*: *Circulation*, 16: 750, 1957.

417 Medical Arts Bldg.

## SHORT COMMUNICATIONS

TREATMENT OF SUPERFICIAL  
EPITHELIOMATOSIS WITH AN  
OINTMENT CONTAINING  
DEMECOLCIN

ROBERT JACKSON, M.D.,\* *Regina, Sask.*

SUPERFICIAL EPITHELIOMATOSIS is a type of basal cell carcinoma. Clinically it usually occurs on the trunk as multiple, superficial, circular, scaly or crusted lesions. Careful examination reveals a fine, pinhead-sized, pearly border. This indurated border can be more easily felt than seen. The tumour grows very slowly and only rarely becomes true invasive basal cell carcinoma. It may be one of the late cutaneous sequelæ to prolonged arsenic ingestion. Confusion with a patch of chronic dermatitis may easily occur. Histologically, there are multiple flask-shaped buds of basal cell carcinoma arising from the overlying epidermis. These buds rarely penetrate deeper than the upper half of the corium, i.e. about 0.6 mm.

Treatment by ordinary radiotherapy or surgical excision is not the treatment of choice, because there will be destruction or removal of much more tissue than is necessary. Also, as the lesions frequently are multiple (up to 100) and large (up to 5 cm. in diameter), extensive areas of radio-dermatitis or numerous unsightly scars will result.

Destruction of these tumours by carbon dioxide snow or slush, liquid nitrogen, very superficial radiotherapy or electrodesiccation and curettage has given satisfactory results, with less or none of the aforementioned sequelæ.

Colchicine has long been known to have an inhibiting action on mitoses by blocking cell division during metaphase. It was only natural that it would be tried in neoplastic conditions which have a high rate of mitotic activity. However, colchicine was also found to affect normal tissues. An alkaloid of colchicine, demecolcin, was isolated in 1950 by Santavy and Reichstein<sup>1</sup> and was found

\*From the Division of Dermatology, Medical Arts Clinic, Regina, Saskatchewan  
Author's present address: 310 O'Connor St., Ottawa.