

months without treatment. When last seen one year after operation, she was in good health and no abnormality was noted on pelvic examination.

These two patients were seen in the department of obstetrics and gynaecology, Stobhill General Hospital, Glasgow. The third patient was referred from the Alberta Cancer Clinic, Edmonton.

CASE 3.—This patient, aged 60 and para 10, had her last menstrual period nine years previously. She complained of vaginal bleeding for eight months, intermittent at first but continuous for three months and increasing in amount. She had recently lost 8 lb. in weight.

She was an obese woman with a blood pressure of 160/90 mm. Hg and a hæmoglobin value of 10 g. per 100 ml. Pelvic examination was difficult owing to her obesity but the uterus was felt to be considerably enlarged and soft.

On November 7, 1958, fractional curettage and cervical biopsy were performed and large quantities of friable-looking material were obtained from the uterine cavity. These curettings showed endometrial hyperplasia and cystic glandular dilation but no malignant changes.

A week later, total hysterectomy and bilateral salpingo-oophorectomy were performed. At operation the left ovary was noted to be the seat of a firm, pale yellow tumour.

Pathological report.—The uterus measured 11 by 8 by 6 cm. and weighed 250 g. The myometrium was considerably thickened and the cavity showed evidence of recent curettage and contained friable grey material at the fundus.

Histology.—The left ovary was 4 cm. in diameter and consisted of interlacing bundles of broad spindle cells separated by bands of connective tissue. Mitoses were rare. Fat stains showed fat granules scattered in the cytoplasm of some of the spindle cells and this finding suggested a diagnosis of thecoma rather than fibroma.

The patient's recovery was delayed by a ruptured abdominal wound which healed satisfactorily after resuture.

SUMMARY

Three patients are described, all of whom presented with the leading symptom of post-menopausal bleeding. In each case it appeared that this symptom was the end result of œstrogen production by an ovarian theca cell tumour.

REFERENCES

- LÖFFLER, E. AND PRIESEL, A.: *Beitr. z. path. Anat. u. z. allg. Path.*, 90: 199, 1932.
- FALLS, F. H., RAGINS, A. B. AND GOLDENBERG, M.: *Am. J. Obst. & Gynec.*, 57: 1107, 1949.
- BANNER, E. A. AND DOCKERTY, M. B.: *Surg. Gynec. & Obst.*, 81: 234, 1945.
- WEINER, I. D.: *Memphis M. J.*, 25: 44, 1950.
- REINER, W. C.: *West. J. Surg.*, 56: 205, 1948.
- ROGERS, W. S., GORDON, R. E. AND MARSH, M. R.: *Am. J. Obst. & Gynec.*, 64: 1289, 1952.
- DIDDEL, A. W.: *Cancer (N.Y.)*, 5: 215, 1952.
- GORDON, V. H. AND MARVIN, H. N.: *J. Pediat.*, 39: 133, 1951.
- WEBB, C. F. AND GOUGH, J. A.: *Am. J. Obst. & Gynec.*, 65: 211, 1953.
- STERNBERG, W. H. AND GASKILL, C. H.: *Ibid.*, 59: 575, 1950.
- SHIPP, S.: *J. Obst. Gynec. Brit. Emp.*, 57: 362, 1950.
- Ibid.*, 62: 321, 1955.
- ALEXANDER, W. S. AND BERESFORD, O. D.: *Ibid.*, 60: 252, 1953.
- NOVAK, E.: *Gynecologic and Obstetric Pathology*, 3rd ed., W. B. Saunders, Philadelphia, 1952, p. 417.
- SUTHERLAND, A. M. AND McBRIDE, J. M.: *J. Obst. Gynec. Brit. Emp.*, 61: 238, 1954.

CAVERNOUS TRANSFORMATION OF THE PORTAL VEIN IN POLYCYTHÆMIA VERA*

A. A. RITZEN, M.D.,
W. B. LEACH, M.D., M.Sc. and
D. M. WHITELAW, M.D., F.R.C.P.[C],
Vancouver, B.C.

POLYCYTHÆMIA vera is frequently complicated by vascular accidents. These may be hæmorrhagic or thrombotic. The cause of hæmorrhage is obscure. Low fibrinogen levels and defects of clot retraction have been demonstrated. It is possible also that mechanical distension of blood vessels and impairment of nutrition of the intima may play some part.¹ The cause of thrombosis is equally obscure. Increased number of platelets, increased viscosity of the blood and impaired nutrition of the vascular endothelium due to mechanical distension may all contribute. Clinical evidences of thrombosis are usually associated with obstruction of larger arteries in the brain, heart or intestinal tract.² Less frequently, venous thrombosis may be the cause of intra-abdominal complications.³ The present case report concerns a patient with polycythæmia vera who during the course of her illness developed symptoms of portal obstruction and who at operation and autopsy was found to have cavernous transformation of the portal vein.

A 40-year-old white woman was referred to us by Dr. McMurtry of Vernon, B.C. She had first noted a painful mass in the right upper quadrant of her abdomen in 1955. The pain was worse after walking and working but not after eating. It was constantly relieved by aspirin and codeine. For five years before the onset of this pain she had noticed that a warm bath would induce burning and itching of her skin which would persist for up to 30 minutes.

There was no family history of blood disease. She had had five pregnancies of which three were stillbirths after six months' gestation. During her second pregnancy, she had one convulsion and after her last she had a moderately severe hæmorrhage. From early adolescence, she had suffered from migrainous headaches.

It was found on initial examination that her liver extended 15 cm. below the right costal margin at the lateral border of the rectus, and her spleen extended a similar distance below the left costal margin. The retinal veins were engorged. The hæmoglobin value was 16.8 g. %. The red blood cell count was 6.27 million per c.mm. The white cell count was 15,650 per c.mm. and the erythrocyte sedimentation rate was 2 mm. in one hour. Venesection performed five times over a three-month period partially relieved her pain and lowered her hæmoglobin level to 9.3 g. %.

On admission to the Vancouver General Hospital the above findings were confirmed and she was found also to have slight œdema of her lower legs. Results of liver function tests were normal. The hæmoglobin level was 11.2 g. % and the red cell count 5.4 million.

*From the Department of Pathology, Vancouver General Hospital, and the Department of Medicine, The University of British Columbia, Vancouver, B.C.

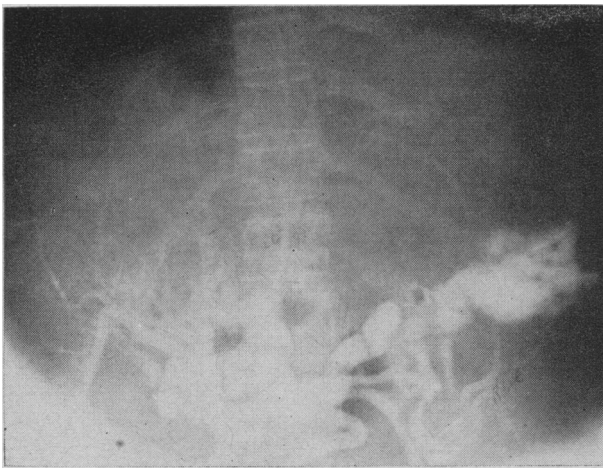


Fig. 1.—Splenoportography showing dilated collateral portal vessels. No single portal vein is evident.

The red cells were microcytic and hypochromic. The platelets numbered 780,000 per c.mm. The white blood cell count was 13,800 and the sedimentation rate was 10 mm. in one hour. The bone marrow showed increased cellularity and many megakaryocytes. The red cell mass determined with chromium⁵¹ was 1280 ml. compared with an expected normal of 1320 ml., and the plasma volume was 3070 ml. compared with an expected normal of 1830 ml. These findings were interpreted as indicating polycythæmia with the red cell mass reduced by venesection. Splenic aspiration showed no abnormality. X-ray examination of the œsophagus, stomach and duodenum was negative. She was treated with 600 r of x-irradiation over her spleen, with some relief of discomfort.

During the next six months her hæmoglobin level rose to 12 g. % and her red cell count to 6.2 million. Her white cell count varied between 10,000 and 20,000. By October 1956, the red cell mass had risen to 1630 ml. and the plasma volume had fallen to 2060 ml. She was again treated by x-irradiation over both liver and spleen and was given iron by mouth.

For the succeeding 12 months her clinical condition was stationary and the pain, while almost constant, was bearable. Her hæmoglobin level was maintained at about 12 g. % by monthly venesections. An examination of blood and bone marrow in October 1957 was essentially unchanged. Results of blood volume studies were similar to those of a year before. X-ray examination of œsophagus, stomach and duodenum was again negative. Splenic aspiration now yielded megakaryocytes and other myeloid elements. A punch biopsy of the liver showed normal liver tissue. A cone biopsy of the cervix showed chronic cervicitis. After this procedure she bled briskly for two days.

In April 1958, she contracted an upper respiratory infection and over a period of one week her weight increased by 8 lb. accompanied by a 3 inch (7.5 cm.) increase in girth. She was found to have ascites and œdema of her lower extremities. She had no dyspnoea, cardiomegaly or increase in venous pressure. Re-examination of her blood and bone marrow showed no significant changes from those noted previously. Except for a serum globulin of 2.5 g. %, results of liver function tests were normal. She was considered to have developed a splenic or portal vein obstruction. With bed rest, salt restriction and diuretics she lost 11 lb. and felt improved.

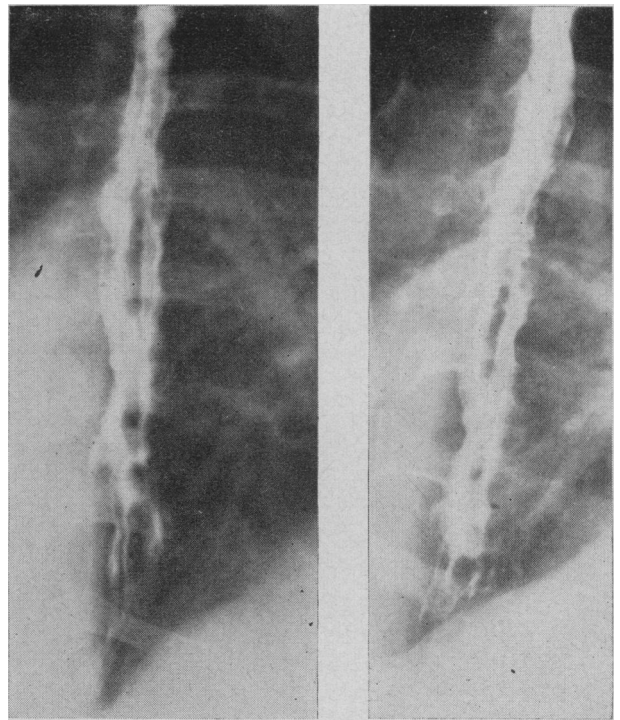


Fig. 2.—Barium swallow showing extensive œsophageal varices.

For the next four months she was able to resume her household activities, but in August 1958 the ascites rather abruptly increased in amount and she was readmitted to hospital. She was now obviously wasted. The distension of the abdomen interfered with breathing but there were no signs of heart failure. The liver extended 8 cm. below the right costal margin and the spleen 9 cm. below the left costal margin. Both were firm.

The hæmoglobin level had risen to 17.1 g. %, the red cell count to 6.9 million. The cells were slightly microcytic. The packed cell volume was 56%. The white cell count was 16,450, of which 16% were staff cells. The platelets numbered 1,120,000. The bone marrow was again hypercellular. Liver function tests were unchanged. The venous pressure measured in the right antecubital vein was 10 cm. of citrate and rose briefly to 11 cm. with pressure over the liver.

Visualization of the portal bed was accomplished by injection of 70% Diodrast into the spleen (Fig. 1). This showed remarkable hypertrophy and tortuosity of the veins in the portal area, without revealing any one vein which could be interpreted as the portal vein itself. The Diodrast remained in the liver for eight seconds, indicating intrahepatic obstruction. The films were interpreted as showing cavernous transformation of the portal vein. Injection of Diodrast into the inferior vena cava outlined an apparently normal vessel. X-ray examination of the œsophagus with barium showed large and numerous varices (Fig. 2).

Her ascites did not respond to treatment, and in October 1958 a laparotomy was undertaken with the hope of effecting an anastomosis between the portal and caval systems. Many large tortuous venous channels were encountered but none was suitable for establishing a shunt. The spleen, which weighed 740 g., was removed.

Her postoperative course was satisfactory for about one week. Her platelet count rose to 3.6 million and her white cell count to 51,800. She then developed

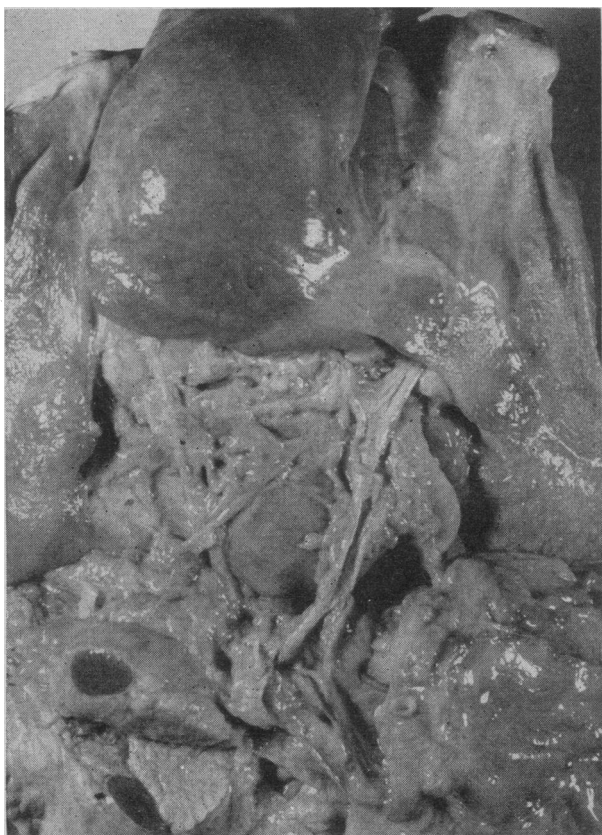

Fig. 3.—Collateral portal veins are shown around the fibrosed, stenotic portal vein. The left lobe of the liver exhibits a granular surface over the fibrotic tissue. An accessory spleen is present in the tail of the pancreas.

signs of mesenteric thrombosis and, in spite of vigorous therapy designed to maintain fluid and electrolyte balances, she died on the 21st postoperative day.

Autopsy Findings:

General examination showed the left paramedian surgical incision to be intact despite severe abdominal distension. The body appeared pale but the sclerae showed a faint icteric tinge.

Each pleural space contained about a litre of straw-coloured fluid. The lungs were crepitant and slightly oedematous. The peripheral branches of the pulmonary arteries to both lungs contained numerous small antemortem thrombi, measuring 2 to 3 mm. in diameter and 1 to 2 cm. in length. No evidence of pulmonary infarction was seen.

The heart weighed 200 g., and both it and the pericardium were normal. The coronary vessels showed minimal atheroma and were patent.

The abdominal cavity contained four litres of clear yellow ascitic fluid. The vessels of the abdominal wall were dilated and thin-walled, especially around the umbilicus and falciform ligament. Large submucosal oesophageal varices were present, but there was no evidence of ulceration or rupture in this vicinity. There was no ulceration in the stomach or duodenum. Just distal to the third part of the duodenum, the jejunum was dark blue in colour and friable in consistency, and contained jelly-like blood clot in the lumen for a distance of 26 cm. The proximal and distal aspects of this infarcted area were sharply delineated. The mesenteric veins along the border of the affected area contained firm, grey, antemortem thrombus. The larger venous branches in the mesentery appeared

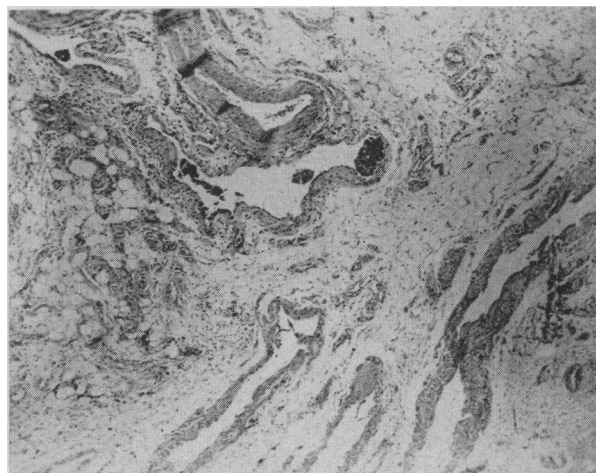


Fig. 4.—Photomicrograph of cavernous tissue showing thin-walled dilated collateral channels. $\times 30$.

normal. Internal haemorrhoids were the only other feature of note in the bowel. The greater omentum was adherent to the umbilicus and showed dilated veins over its entire extent.

The liver weighed 1200 g. The left lobe and peripheral edge of the right lobe presented a nodular or granular surface. The central area of the liver appeared smooth and was of normal colour. On cut section the left lobe of the liver showed a dense thick band of fibrous tissue, pale grey in colour, 3 cm. wide around the periphery. The central area of the liver was spared and appeared normal. The liver parenchyma underlying the nodular surface was composed of dense fibrous tissue. The gall-bladder was small and empty but the wall was thick and fibrotic. The bile ducts were patent. The large hepatic veins were patent.

The portal vein was represented by a fibrotic cord with isolated occlusions separated by small but patent vein lumina. The wall was thickened along the entire length. In the lesser omentum and the porta hepatis there was a network of tortuous, thin-walled veins which collapsed as dissection was attempted, making isolation impossible. These vessels surrounded the portal vein and entered the liver at the porta hepatis. Large branches were traced to the stomach and duodenum. The splenic vessels were occluded distally by a ligature and contained antemortem thrombus (see Fig. 3).

A fibrotic accessory spleen 3 cm. in diameter was found in the tail of the pancreas, which was otherwise normal. Both adrenals appeared normal, and no pathological entities were found in the kidneys or lower urinary system. The pelvic vessels contained no thrombi. The genital system was normal. The inferior vena cava was patent. Antemortem thrombi were present in the popliteal veins.

Microscopic Examination:

Sections through the lungs disclosed only severe congestion but no evidence of pulmonary infarction. The proximal jejunum, however, showed evidence of infarction with antemortem thrombi adherent to the intima of the mesenteric veins.

Section through the portal vein and collaterals disclosed fibrous thickening of the vessel wall with organizing thrombus in the lumen. The collaterals were thin-walled, empty and in various stages of collapse (Fig. 4).

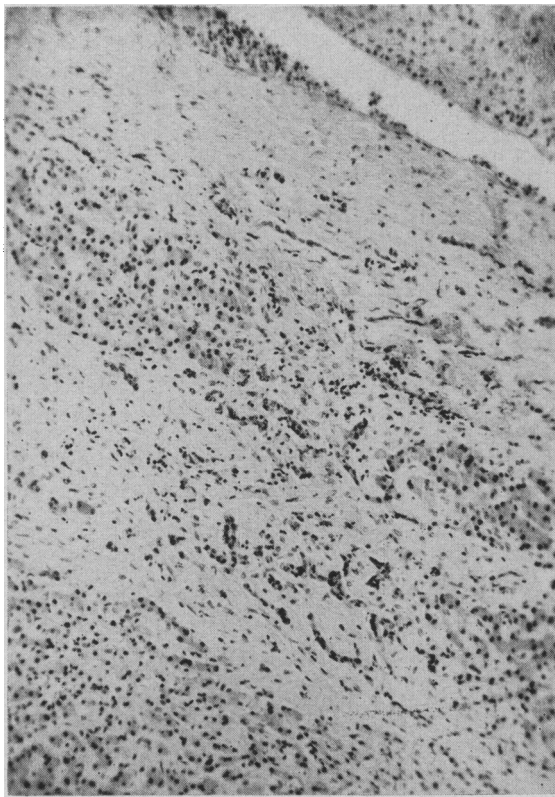


Fig. 5.—Photomicrograph of liver showing a thrombus in the hepatic vein in upper right-hand corner. Fibrosis and proliferating bile ducts are clearly shown. $\times 110$.

The liver showed dense, fibrous bands separating groups of liver cells and proliferation of bile ductules. Some of the hepatic veins contained antemortem thrombi (Fig. 5).

DISCUSSION

The diagnosis of polycythæmia vera in this instance rests on the following points. The presence of polycythæmia is attested by the high hæmoglobin value and red cell count and the high circulating red cell mass. No cause for secondary polycythæmia such as severe heart or lung disease was discovered. Finally the abnormal proliferation of the marrow elements and the persistent leukocytosis and thrombocytosis indicate that the hæmatopoietic mechanism was generally affected, and the disease was a manifestation of a diffuse myeloproliferative process.

Cavernous transformation of the portal vein refers to the replacement of the main portal venous channel into the liver by a mass of tortuous veins situated in the free margin of the lesser omentum and the porta hepatis.³

The condition is usually seen in infants and young children without intrinsic liver disease and, in such circumstances, it may represent an angiomatous abnormality.⁴ Various pathogenetic mechanisms of portal vein occlusion are referred to in the literature. In general, they concern the production of extrahepatic portal bed blockage and, as a result of this, cavernous transformation of the portal vein may develop. An extension of the normal obliterative process of the umbilical vein and

ductus venosus may occur at the time of birth to include the portal vein or there may be congenital hypodevelopment of the portal vein system (Cruveilhier-Baumgarten syndrome).⁵ Other possibilities include congenital abnormalities or angiomata of the portal vein or inferior vena cava,⁶ occlusion of the portal vein following abdominal trauma, pylephlebitis or splenectomy,⁴ tumours or inflammation of the pancreas or the lymph nodes causing extra-luminal compression of the portal vein,⁷ thrombocythæmia or polycythæmia vera with thrombosis of the portal vein³ and thrombosis of the portal vein in cirrhosis.⁸

Gibson and Richards,⁹ in a detailed report, present cases where no doubt exists that cavernous transformation may be the end result of acquired occlusion of the portal vein. Our case seems more readily explained by this hypothesis than by postulating a developmental anomaly or a hamartoma.

The mass of thin-walled vessels of which the cavernous tissue is composed results from compensatory dilatation of the accessory portal veins from Glisson's capsule, the lesser omentum, the gall-bladder, the bile ducts and the hepatocolic ligament. Ordinarily, these small veins empty into the portal sinus. Just as collaterals develop elsewhere in the body when the main venous channel is occluded, so the accessory portal veins develop to by-pass the obstructed area. The marked distension of the accessory portal veins is due to their anatomically exposed position. There is no firm supporting tissue in the porta hepatis to prevent the wide dilatation. Part of the cavernous tissue may be due to recanalization of thrombus in the portal vein proper. Despite the massive enlargement of the collateral channels, the efficiency of a functioning portal vein is not approached. Application of Poiseuille's law indicates that the collateral bed has to be enormous to achieve the functioning capacity of a normal portal vein.^{9, 10}

The evidence of the cases of Gibson and Richards indicates that considerable time may elapse between occlusion of the portal vein and formation of the cavernous mass.⁹ However, with complete occlusion of the portal vein, œsophageal varices develop in a few days to several weeks.⁸ In cavernous transformation of the portal vein, there does not appear to be one massive obstruction but, rather, a series of small thrombotic episodes. These are usually not accompanied by any dramatic clinical event, if indeed they cause symptoms at all. This also is borne out by our case in which œsophageal varices were not present initially and yet, a few months later, were shown to have developed without the patient's having experienced any new symptoms.

The portal vein may be represented as a firm fibrotic functionally closed vessel, as in our case, or it may be a spongy recanalized vessel contributing to the cavernous tissue.⁹

Ascites is not a usual accompaniment of cavernous transformation of the portal vein.^{9, 10} It has

been shown experimentally, by Schilling *et al.*, that simple occlusion of the portal vein in dogs is not attended by the formation of ascites. Even partial and complete occlusion of the portal vein and inferior vena cava just below the liver but above the kidneys did not produce ascites. If the inferior vena cava is partially occluded above the liver, ascites forms but does not persist. However, stasis in the hepatic veins may cause the formation of ascites which persists over a long period of time, associated closely with sodium retention, the mechanism of which is not yet clear.¹¹

It has also been shown clinically that extra-hepatic blockage of the portal system does not cause ascites. Ascites, when it occurs with portal hypertension, usually indicates intrahepatic fibrosis and damage.¹¹ Fig. 5 shows the extensive liver fibrosis and the thrombi of the hepatic vein found in the left lobe of the liver. This fits in well with the previously mentioned considerations regarding the cause of the ascites.

Patients having portal hypertension due to extra-hepatic portal occlusion have a normally functioning liver and are good risks for shunt procedures. The most serious surgical risks are those cases in which the plasma albumin level is below 3 g. per 100 ml. with ascites that fails to respond to medical therapy, and which also have 3+ to 4+ cephalin flocculation tests and a depressed prothrombin activity that does not respond to vitamin K therapy. The good surgical risks have plasma albumin levels above 3 g. per 100 ml., no ascites, bromsulphalein retention below 10% in 30 minutes and a prothrombin activity within four seconds of normal (50%).

This case showed no impairment of liver function and so, except for the hazard imposed by the polycythæmia, should have been a good risk.

Portal venography has been used as a diagnostic adjunct in cases of portal vein occlusion since 1951.¹² Two methods are currently in use. In splenic portography, the dye is injected directly into splenic sinusoids and a series of films is taken at intervals of 3 to 10 seconds. Portal portography, the alternative method, requires a small laparotomy with exposure of a portal vein radicle into which the dye is injected. This is followed by a series of rapid films as in splenic portography. Splenic portography was done in our case, and the many tortuous vessels of the cavernous mass are clearly shown in Fig. 1. The œsophageal varices do not appear in this film and were demonstrated with subsequent barium swallow examination (Fig. 2).

SUMMARY

A case of polycythæmia vera in which ascites, portal hypertension and cavernous transformation of the portal vein developed is presented.

After splenectomy, the patient developed terminal mesenteric thrombosis with infarction of the bowel.

Current concepts of cavernous transformation of the portal vein are discussed.

REFERENCES

1. WHITELOW, D. M., AND THOMAS, G. C.: *Canad. M. A. J.*, 72: 128, 1955.
2. PIKE, G. M.: *New England J. Med.*, 258: 1250, 1958.
3. MACPHERSON, A. I. S., INGRAM, G. I. C. AND MACLEAN, N.: *J. Roy. Coll. Surgeons Edinburgh*, 2: 191, 1957.
4. PATTON, T. B. AND JOHNSTON, C. G.: *Am. J. M. Sc.*, 236: 239, 1958.
5. HOLLENBERG, H. G. AND BRIGGS, B. P.: *Ann. Surg.*, 141: 648, 1955.
6. JORDAN, P., JR., PATTON, T. B. AND BENSON, C. D.: *A.M.A. Arch. Surg.*, 72: 879, 1956.
7. WILCOX, A. Y., JR., BOVILL, E. G. AND OLIVETTI, R. G.: *Gastroenterology*, 21: 375, 1952.
8. Case Records of the Massachusetts General Hospital Weekly Clinics—Pathological Exercises: Case 43031, *New England J. Med.*, 256: 134, 1957.
9. GIBSON, J. B. AND RICHARDS, R. L.: *J. Path. & Bact.*, 81: 1955.
10. PARKER, R. A. AND SEAL, R. M. E.: *Ibid.*, 70: 97, 1955.
11. SCHILLING, J. A. *et al.*: *J. Clin. Invest.*, 31: 702, 1952.
12. HALLENBECK, G. A. AND BRUWER, A.: *Proc. Staff Meet. Mayo Clin.*, 29: 333, 1954.

SHORT COMMUNICATION

INBORN ERRORS(?) OF METABOLISM

HARRY BAKER, M.D., Vancouver, B.C.

MEDICAL TEACHING and medical practice are based on a miscellany of knowledge which has accumulated through the ages. There is a modicum of homogeneity to this knowledge because it relates to one factor, man, the organism within his environment. This is the only factor which lends it any cohesive quality. The actual knowledge of how man functions within his environment and how these functions relate to each other is sparse. More recently, with the influence of scientific disciplines, factual knowledge has been added more rapidly than ever before. The searchers concentrate so much on the tiny bit they seek that they tend to forget that the ultimate goal of all this searching is the biological understanding of a special organism—man, and how he functions in his environment. This ecological concept must be seen not only in space but also in time. It took man a long time to travel the various stages he did before he arrived in his present form.

Man's descent as a biological phenomenon is seldom considered seriously enough in medical teaching or medical thinking. Some medical researchers seem to ignore it. Recently with the newer knowledge of genetics and body chemistry and their various possible functions, we have begun to hear more about new diseases and their probable underlying causes. It is becoming more obvious as a result of this intensive research that we are hearing for the first time about previously unknown diseases in man. These diseases are probably due to a lack or malfunction of recently discovered enzymes. The illnesses described in this group are inherited and are present in the individual from birth or early infancy. The name applied to this group of illnesses is "inborn errors of metabolism." Garrod first used this title over 50 years ago to describe a group of rare conditions which he had studied. His clinical understanding